COLUMBIA LIBRARIES OFFSITE
HEALTH SCIENCES STANDARD
HX00043834

Columbia University
in the City of New York
School of Dental and Oral Surgery

Reference Library

DONATED BY Prof. Gillett

Digitized by the Internet Archive
in 2010 with funding from
Columbia University Libraries

http://www.archive.org/details/textbookofoperat00john

A TEXT-BOOK
OF
OPERATIVE DENTISTRY

LIST OF CONTRIBUTORS.

J. P. BUCKLEY, PH. G., D. D. S.,
Professor of Materia Medica and Therapeutics, Chicago College of Dental Surgery.

W. A. CAPON, D. D. S.,
Lecturer and Instructor of Dental Ceramics, Dental Department, University of Pennsylvania.

GEORGE W. COOK, D. D. S.,
Dean of the College of Dentistry, University of Illinois, Chicago.

FERDINAND J. S. GORGAS, A. M., M. D., D. D. S.,
Dean and Professor of Principles of Dental Science, Oral Surgery and Dental Prosthesis in the University of Maryland, Dental Department; Author of "Dental Medicine."

ELLISON HILLYER, D. D. S.,
Professor of Prosthetic Dentistry and Orthodontia, New York College of Dentistry.

GEORGE EDWIN HUNT, M. D., D. D. S.,
Dean of the Indiana Dental College, Indianapolis.

C. N. JOHNSON, M. A., L. D. S., D. D. S.,
Professor of Operative Dentistry in the Chicago College of Dental Surgery; Editor of "The Dental Review."

C. EDMUND KELLS, JR., D. D. S.,
New Orleans.

GARRETT NEWKIRK, M. D.,
Member of the California State Board of Dental Examiners, Former Dean and Professor of Operative Dentistry, College of Dentistry, University of Southern California.

JOHN EGBERT NYMAN, D. D. S.,
Chicago.

ALFRED OWRE, D. M. D., M. D., C. M.,
Dean and Professor of Operative Dentistry and Metallurgy, College of Dentistry, University of Minnesota.

JOHN DEANS PATTERSON, D. D. S.,
Professor of Dental Pathology, Kansas City Dental College.

HERMANN PRINZ, M. D., D. D. S.,
Professor of Materia Medica, Therapeutics and Pathology, Dental Department Washington University, St. Louis.

HERBERT A. PULLEN, D. M. D.,
President of the American Society of Orthodontists, 1906-07; Instructor in the Angle School of Orthodontia, Session of 1900; Member of the New York State Dental Society, Buffalo Dental Association, National Dental Association, etc.

CHARLES R. TURNER, D. D. S., M. D.,
Professor of Mechanical Dentistry and Metallurgy, Department of Dentistry, University of Pennsylvania.

A. E. WEBSTER, L. D. S., D. D. S., M. D.,
Professor of Operative Dentistry and Dental Pathology in the Royal College of Dental Surgeons of Ontario; Editor of "The Dominion Dental Journal," etc.

GEORGE H. WRIGHT, D. M. D.,
Former Assistant in Embryology and Histology, Harvard Medical School.

A TEXT-BOOK OF

OPERATIVE DENTISTRY

BY VARIOUS AUTHORS

EDITED BY

C. N. JOHNSON, M. A., L. D. S., D. D. S.

PROFESSOR OF OPERATIVE DENTISTRY IN THE CHICAGO COLLEGE OF DENTAL SURGERY;
EDITOR OF THE "DENTAL REVIEW"

WITH SIX HUNDRED AND EIGHTEEN ILLUSTRATIONS

PHILADELPHIA
P. BLAKISTON'S SON & CO.
1012 WALNUT STREET
1908

RK501
J62

Copyright, 1908, by P. Blakiston's Son & Co.

Printed by
The Maple Press
York, Pa.

PREFACE.

In preparing this book for the profession the aim has been to condense the latest thought on the various subjects into the closest possible limit consistent with a clear elucidation of the ideas presented. It has been the constant effort to bring the work strictly up to date, and with the rapid evolution of dental thought in progress at the present time this has been no small task. As an illustration it is only necessary to mention the circumstance that one entire chapter—that by Dr. Nyman on the gold inlay—was wholly rewritten after it was in type and the illustrations made for it. The original article was discarded as being out of date the moment the cast method became a demonstrated fact. This is only indicative of the great care taken by the various authors in the revision of their work, and for which the editor wishes at this time to express his great appreciation.

Particular attention is called to the illustrative character of the work. Most of the cuts were made specially for the book, and many of them are striking in their originality. Those, for instance, illustrating Dr. Turner's chapter on "The Anatomy of the Human Teeth" were made from photographs of natural teeth, a typical specimen of each tooth being selected for this purpose and photographed on its different surfaces. The effect has been to present something perfectly true to nature.

Mention might be made of distinguishing features in each chapter in the book, but this would appear unnecessary with the work in the reader's hands. It seems appropriate, however, to call attention to Dr. Pullen's chapter on "Orthodontia" which we believe is one of the most concise and practical presentations of this important subject that has yet appeared.

To the contributors the editor feels under deep obligation for their cordial coöperation in preparing the work, and to the publishers for their uniform courtesy and painstaking care in every detail of publication.

C. N. J.

Chicago, August, 1908.

CONTENTS.

PAGE

INTRODUCTION, ... xi
BY C. N. JOHNSON, M. A., L. D. S., D. D. S.

CHAPTER I.

The Anatomy of the Human Teeth, ... 1
BY CHARLES R. TURNER, D. D. S., M. D.

CHAPTER II.

The Histology of the Human Teeth, ... 59
BY CHARLES R. TURNER, D. D. S., M. D.

CHAPTER III.

Hygiene and Arrangement of Light in the Operating Room, ... 85
BY C. N. JOHNSON, M. A., L. D. S., D. D. S.

CHAPTER IV.

Asepsis in the Operating-Room, ... 89
BY A. E. WEBSTER, M. D., L. D. S., D. D. S.

CHAPTER V.

Hygiene of the Mouth, ... 97
BY GEORGE H. WRIGHT, D. M. D.

CHAPTER VI.

Dental Caries, ... 117
BY C. N. JOHNSON, M. A., L. D. S., D. D. S.

CHAPTER VII.

Examination of Teeth for the Finding of Carious Cavities, ... 127
BY GARRETT NEWKIRK, M. D.

CHAPTER VIII.

Separation of Teeth Preparatory to Operating on Cavities in the Proximal Surfaces, ... 133
BY GARRETT NEWKIRK, M. D.

CHAPTER IX.

Exclusion of Moisture from the Teeth during Operations, ... 145
BY GEORGE EDWIN HUNT, M. D., D. D. S.

CHAPTER X.

PAGE

Preparation of Cavities for Fillings, ... 161
BY A. E. WEBSTER, M. D., L. D. S., D. D. S.

CHAPTER XI.

The Treatment of Sensitive Dentin, ... 215
BY J. P. BUCKLEY, PH. G., D. D. S.

CHAPTER XII.

Filling Materials: Their Characteristics, Indications for Their Use and the Methods of Manipulation, ... 225
BY ALFRED OWRE, M. D., C. M., D. M. D.

CHAPTER XIII.

The Use of the Matrix in Filling Teeth, ... 255
BY GARRETT NEWKIRK, M. D.

CHAPTER XIV.

Inlays, ... 263
BY C. N. JOHNSON, M. A., L. D. S., D. D. S.

CHAPTER XV

Preparation of Cavities for Inlays, ... 267
BY C. N. JOHNSON, M. A., L. D. S., D. D. S.

CHAPTER XVI.

The Porcelain Inlay, ... 277
BY W. A. CAPON, D. D. S.

CHAPTER XVII.

Construction of Gold Inlays, ... 301
BY JOHN EGBERT NYMAN, D. D. S.

CHAPTER XVIII.

The Treatment of Exposed or Nearly Exposed Pulps, ... 311
BY J. P. BUCKLEY, PH. G., D. D. S.

CHAPTER XIX.

The Anesthetization and Devitalization of Pulps, Their Removal and the Subsequent Treatment, ... 317
BY J. P. BUCKLEY, PH. G., D. D. S.

CHAPTER XX.

The Treatment of Ordinary Pericementitis, ... 335
BY J. P. BUCKLEY, PH. G., D. D. S.

CHAPTER XXI.

The Chemistry of Pulp Decomposition, ... 341
BY J. P. BUCKLEY, PH. G., D. D. S.

CHAPTER XXII.

PAGE

The Treatment of Putrescent Pulps; Acute and Chronic Alveolar Abscess, with Complications; and the Filling of Root Canals, ... 347
BY J. P. BUCKLEY, PH. G., D. D. S.

CHAPTER XXIII.

The Causes and Treatment of Discolorations of Teeth, ... 367
BY J. P. BUCKLEY, PH. G., D. D. S.

CHAPTER XXIV.

The Treatment of Children's Teeth, ... 377
BY C. N. JOHNSON, M. A., L. D. S., D. D. S.

CHAPTER XXV.

Local Anesthesia, ... 385
BY HERMANN PRINZ, M. D., D. D. S

CHAPTER XXVI.

The Extraction of Teeth, ... 399
BY FERDINAND J. S. GORGAS, A. M., M. D., D. D. S.

CHAPTER XXVII.

The Planting of Teeth, ... 439
BY C. EDMUND KELLS, JR., D. D. S.

CHAPTER XXVIII.

Pyorrhea Alveolaris, ... 451
BY JOHN DEANS PATTERSON, D. D. S.

CHAPTER XXIX.

Erosion, ... 471
BY GEO. W. COOK, D. D. S.

CHAPTER XXX.

The Management of an Office Practice, ... 483
BY ELLISON HILLYER, D. D. S.

CHAPTER XXXI.

Orthodontia, ... 505
BY HERBERT A. PULLEN, D. M. D.

INDEX 747

INTRODUCTION.

Operative Dentistry may be defined as the science and art which aims at the preservation of the natural teeth in a state of health and beauty. Its highest office is to prevent disease or deformity, but where either of these has already occurred it is then its function to remedy the evil, and check its further progress. The dentist who does the best for his patient is the one who, in addition to the development of the highest manipulative skill, studies most carefully the conditions surrounding the field of his operations. To fill a cavity in a tooth in the most perfect manner possible, when the surrounding tissues are in an abnormal condition, without a recognition of this fact and the most careful attention to the abnormality, is far from good practice. To attempt to remedy any disorder in the mouth by confining attention solely to the immediate seat of the trouble is frequently to court failure. The human economy is so complicated that cause and effect are often remote from each other, and the practitioner who does the best service to his patient is the one who in addition to being an acute observer extends his observation over the widest field.

The conscientious dentist, when he finds himself baffled in discovering the cause or relieving the symptoms of any affection of the mouth will not hesitate to call in consultation a specialist in dentistry or medicine as the case indicates, and particularly is it desirable in instances of peculiar idiosyncrasies to consult with the family physician of the patient.

No individual practicing a profession like dentistry should think lightly of his obligations, and no practitioner can properly fulfil his obligations without developing the habit of painstaking care in all his work whether of diagnosis or treatment. It should early be recognized by the young practitioner that dentistry demands of those who aim to excel in its practice a more diversified order of talent than any other calling. To be a good dentist an individual should develop the scientist's attitude toward the intimate and sometimes intricate relationship between cause and effect, he should be a close observer of phenomena, a mechanician of the first order, an artist with the sense

INTRODUCTION.

Operative Dentistry may be defined as the science and art which aims at the preservation of the natural teeth in a state of health and beauty. Its highest office is to prevent disease or deformity, but where either of these has already occurred it is then its function to remedy the evil, and check its further progress. The dentist who does the best for his patient is the one who, in addition to the development of the highest manipulative skill, studies most carefully the conditions surrounding the field of his operations. To fill a cavity in a tooth in the most perfect manner possible, when the surrounding tissues are in an abnormal condition, without a recognition of this fact and the most careful attention to the abnormality, is far from good practice. To attempt to remedy any disorder in the mouth by confining attention solely to the immediate seat of the trouble is frequently to court failure. The human economy is so complicated that cause and effect are often remote from each other, and the practitioner who does the best service to his patient is the one who in addition to being an acute observer extends his observation over the widest field.

The conscientious dentist, when he finds himself baffled in discovering the cause or relieving the symptoms of any affection of the mouth will not hesitate to call in consultation a specialist in dentistry or medicine as the case indicates, and particularly is it desirable in instances of peculiar idiosyncrasies to consult with the family physician of the patient.

No individual practicing a profession like dentistry should think lightly of his obligations, and no practitioner can properly fulfil his obligations without developing the habit of painstaking care in all his work whether of diagnosis or treatment. It should early be recognized by the young practitioner that dentistry demands of those who aim to excel in its practice a more diversified order of talent than any other calling. To be a good dentist an individual should develop the scientist's attitude toward the intimate and sometimes intricate relationship between cause and effect, he should be a close observer of phenomena, a mechanician of the first order, an artist with the sense

of harmony highly cultivated, a physician in his diagnosis of disease, a humanitarian in his ministrations to others, and above all a cultured gentleman of the highest mental and moral fiber.

This does not imply that in the beginning he must be endowed with great brain capacity or natural attributes of an unusual character. The encouraging thing about dentistry is that most of the qualities necessary for achievement are capable of cultivation, and the man who will apply himself with sufficient zeal and perseverance is certain of at least a reasonable measure of success. The chief requisite is the patience to plod.

If every dentist would bring to his work a real sincerity of purpose to serve his patients to the highest possibilities of his art, the future of the profession would be secure. There would be less need than there is today of artificial teeth, and the full functional use of the natural organs in mastication and in harmony of expression would be more generally recognized and appreciated. As we develop dentistry along the lines of prevention and conservation we shall bring it nearer and nearer to its highest mission. To do the greatest good to the largest number, to do this good without thought of self advancement, to work for the love of it and for the benefit it brings to humanity—this is the acme of faithful service and the only kind of effort which will bring permanent satisfaction. Unless a dentist is willing to do this he will fall short of all that his profession has to offer him, if he does it he may be certain of an encouraging measure of attainment.

But to accomplish anything of note he must be progressive. The methods of yesterday will not suffice for today. No profession is developing more rapidly than dentistry and he who would give the best service must ever be alive to the latest advances. The foremost thinkers of the profession are constantly placing their ideas before their fellow practitioners, and the man who keeps abreast must be alert to avail himself of the results of their matured thought. It is with the purpose of presenting this thought in the most condensed form as it relates to the different departments of operative dentistry that the present volume is issued.

OPERATIVE DENTISTRY.

CHAPTER I.

THE ANATOMY OF THE HUMAN TEETH.

BY CHARLES R. TURNER, D. D. S., M. D.

The teeth of man are hard masses of calcified tissue attached to the mandible and maxilla and having as their chief function participation in the work of his masticatory apparatus. His food, as introduced into the mouth, the beginning of the digestive tract, consists of articles of various degrees of physical consistency. In order that this may be prepared for subsequent stages in the digestive process, much of it must be mechanically subdivided into particles of convenient size to go through the alimentary canal and be acted upon by the digestive ferments and solvents. Such subdivision is performed in the mouth by the act of mastication and it is with this function that the teeth are chiefly concerned. They afford hard opposed surfaces which are brought into contact in the approximation of the jaws by the muscular apparatus and by this means the food is cut or crushed into particles of the desired size.

The teeth also have a functional relationship with the apparatus by which voice and speech are produced and bear a cosmetic relation to the features of the face.

The adult human denture consists normally of thirty-two teeth which are divided in number equally between the upper and the lower jaw. These are known as the permanent teeth, in contra-distinction to the temporary or deciduous teeth which serve for purposes of mastication during the earlier years of life and are subsequently exfoliated to give place to their permanent successors.

The permanent teeth are divided anatomically into classes and these divisions largely correspond with their functions as portions of the masticatory apparatus. Thus, there are eight incisors, which

NOTE.—The author desires to acknowledge his indebtedness for Figs. 1 to 84 inclusive to Dr. George J. Paynter, of the Department of Dentistry, University of Pennsylvania, who selected and dissected the specimens, and to the Department of Dentistry, University of Pennsylvania, for whom the photographs were made, for permission to reproduce them.

serve in the incising of the food; four cuspids, whose chief function in the carnivorous animals is to pierce and hold the food, a function wholly rudimentary with man; eight bicuspids, which are intermediate in position and function between the cuspids and the molars, and lastly twelve molars which are the crushing and grinding teeth proper. The formula for the permanent human dentition is expressed:

$$I\ \frac{2-2}{2-2},\quad C\ \frac{1-1}{1-1},\quad B\ \frac{2-2}{2-2},\quad M\ \frac{3-3}{3-3} = 32$$

The deciduous denture consists of twenty teeth—eight incisors, four cuspids and eight molars.

As all the teeth possess certain characteristics in common it will be well to refer to these before undertaking a description of the individual teeth.

The *crown* of a tooth is that portion which projects beyond the gum margin and is normally covered with enamel. The *root* or *roots* of the tooth are imbedded in the alveolar process and are attached thereto by a fibrous membrane, the pericementum. The root and crown of a tooth unite at its *neck*, a point which corresponds to the point of juncture of the enamel and the cementum. This is also called the *cervix* and also the *gingival margin* of the crown. The sharpened extremity of a root is known as its *apex*, and this is the seat of an opening which transmits the nerves and blood vessels of the pulp of the tooth and is known as the *apical foramen*. The surface of a tooth which comes into contact with the corresponding surface of teeth in the opposing jaw is referred to as the *occlusal* surface. This term is also applied to the analogous portion of the incisor teeth although strictly speaking it should only apply to that of the lower incisors, inasmuch as this edge of the incisors of the upper jaw does not touch the teeth of the lower jaw, when the teeth are in occlusal contact, but normally is only brought into this relationship when the mandible is protruded. This is also referred to as the *incisive edge* of the incisors. Molar and bicuspid teeth have large tubercles upon their occlusal surfaces and these are known as *cusps*. The adjoining surfaces of teeth are known as their *proximal* surfaces, the most prominent point of which is called the *angle of the tooth*. If a vertical plane is passed between the central incisors of both jaws, those proximal surfaces of the teeth which are directed toward this are known as *mesial* surfaces, while those proximal surfaces directed away from it are known as *distal* surfaces. The surfaces of the six anterior teeth of each series which are in relation with the lips are called *labial*, while the corre-

sponding surfaces of the remaining teeth which are in relation with the cheeks are called *buccal* surfaces. Those surfaces of the teeth which are directed inward toward the cavity of the mouth are known as their lingual surfaces.

The surface-form and internal anatomy of the permanent teeth will now be given in detail.

THE UPPER CENTRAL INCISOR.

The crown of this tooth is wedge-shaped; the base of the wedge is at its cervical margin from which the broad labial and lingual surfaces converge to a straight cutting edge.



FIG. 1.—Left Upper Central Incisor. Labial Surface.

FIG. 2.—Left Upper Central Incisor. Lingual Surface.

The Labial Surface (Fig. 1).—Irregularly quadrilateral in shape, this surface has four margins. The incisive edge which forms its lower margin is nearly straight; it is marked in the newly erupted tooth by two developmental grooves which disappear early in life because of the wearing down of the three tubercles which are found on this edge. The mesial margin is nearly straight or may be a long

curve; the cervical border is convex rootward, while the distal margin is more convex than the mesial and is a little shorter. The surface itself is convex from the cervix to the incisive edge, the lower portion of it being, however, nearly flat, while that portion near the cervix is more curved and is marked by a *cervical ridge*. This face of the crown is convex from side to side and is marked by two longitudinal grooves which correspond to the lines of union of the three developmental lobes of the crown.

The Lingual Surface (Fig. 2).—This is irregularly triangular, the mesial and distal margins uniting with the cervical to form a rounded

FIG. 3.—Left Upper Central Incisor. Mesial Surface.

FIG. 4.—Left Upper Central Incisor. Distal Surface.

apex, while the base of the triangle is formed by the incisive margin. The mesial and distal margins are marked by rounded ridges of enamel which extend from the angles of the crown in a graceful curve rootward to unite with the *cervical ridge*. The mesial is slightly the longer of these two. The cervical is more pronounced than the other marginal ridges. It is sometimes cut near its center by a fissure and sometimes it is the seat of a rounded elevation of enamel, the *cingulum*. The

lingual surface is concave occluso-gingivally and mesio-distally. Its center is occupied by a pronounced fossa, the *lingual fossa*, which is traversed by two longitudinal grooves. Occasionally a *lingual pit* is present and this occupies a position at the juncture of the cervical ridge and the lingual fossa.

FIG. 5.—Left Upper Central Incisor. Occlusal View.

The Mesial Surface (Fig. 3).—Being shaped like a spear-head or irregularly triangular in outline, this surface has three margins. The labial presents a long curve ending in the mesial angle of the tooth and is shorter than the lingual which it meets at this point. Both are bowed in a labial direction and the labial margin is the more pronounced, the lingual being rounded and marking less distinctly the boundary of the surface. The cervical margin is concave in an occlusal direction and at its terminations unites with both the labial and lingual borders at an acute angle. Near the incisive edge the surface is convex but this convexity decreases as the root is approached and the surface becomes either a plane or is marked by a slight depression at the gingival margin. The most prominent point of the surface is located one-third the distance from the mesial angle and this establishes the point of contact with the central incisor of the opposite side.

FIG. 6.—Left Upper Central Incisor. Longitudinal section cut labio-lingually showing pulp cavity.

The Distal Surface (Fig. 4).—While this is of the same general shape as the mesial surface, it is slightly smaller because of the location of the distal angle nearer to the cervix. Its margins are less distinct and the surface is more rounded and the point of contact with the lateral is relatively nearer the cervix.

The Incisive Edge (Fig. 5).—The incisive edge is formed by the intersection of the planes of the labial and lingual surfaces of the crown. These do not meet at an acute angle but their line of intersection is somewhat rounded. This edge extends from

the *mesial* to the *distal angle*, usually almost in a straight line. In young subjects it is marked by the developmental grooves, but these usually disappear from the wearing of the surfaces. When the crown is viewed from below, the line of the incisive edge is occasionally bowed in a labial direction.

Fig. 7.—Left Upper Central Incisor. Cross-section at cervix showing pulp chamber in crown. Looking crownward.

The Cervical Margin.—Beginning at the mesio-labial portion of this line, it extends with an upward curve upon the labial surface, downward on the distal, upward on the lingual, and downward again on the mesial to the point of beginning. It is marked by the bulging of the cervical ridge on the labial and lingual surfaces. While there is usually a well-defined constriction on the tooth at this point, the *neck* of the tooth is not so marked as in some of the distal teeth.

Fig. 8.—Left Upper Central Incisor. Cross-section at cervix showing small pulp cavity in old tooth. Looking crownward.

The Root.—This is conical in shape, and when viewed from the labial surface (Fig. 1) its sides converge in almost straight lines to a rounded point; but viewed from the mesial (Fig. 3) or distal side the outlines of the root curve to a rounded point. When viewed in cross-section at the neck the labio-lingual diameter of the root is greater than the mesio-distal and the root outline is that of a rounded triangle with its sides corresponding to the labial, mesial, and distal faces of the root. Of these the mesial is the longest and nearly straight, the labial and lingual being approximately equal in length but the labial is the most curved of all.

Fig. 9.—Left Upper Central Incisor. Cross-section made at middle of crown (looking rootward) showing form of pulp chamber.

The Pulp Cavity.—The form of the pulp cavity of the central incisor corresponds in general with the external form of the tooth itself (Fig. 6). It is divisible into the *pulp chamber* and the *pulp canal*, but the line of division is not clearly marked. The pulp chamber occupies the crown of the tooth and, as seen in a labio-lingual section of the tooth (Fig. 6) follows the form of the crown closely. The pulp canal is conic in form, with its base joining the pulp chamber and its apex

reaching the apex of the root where it terminates in the apical foramen. In a mesio-distal section of the tooth the flattening out of the occlusal end of the pulp chamber to follow the incisive edge of the tooth, is seen. (Fig. 9.) The portions extending in the direction of the angles of the tooth are known as the "horns" of the pulp. In the young subject there are three concavities in its occlusal end, correspond-

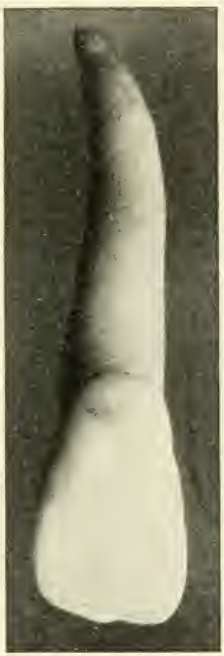

FIG. 10.—Right Upper Lateral Incisor. Labial Surface.

FIG. 11.—Right Upper Lateral Incisor. Lingual Surface.

ing to the three tubercles and the three developmental centers of the incisive edge of the crown. A cross-section of the root at the cervix shows the pulp cavity almost circular in outline (Fig. 7), and this form characterizes it to the end of the root. The pulp cavity of this, as of all the teeth, diminishes in size from the time of completion of the root through old age because of the deposit of dentin upon its walls (Fig. 8).

THE UPPER LATERAL INCISOR.

The Labial Surface (Fig. 10).—This surface is somewhat similar in outline to that of the central incisor except that it is smaller, being narrower from side to side and shorter, and its distal angle is more rounded. It is bordered by four margins. The incisive margin is

almost straight, being, however, inclined slightly downward in the direction of the median line and in the young tooth is marked by developmental grooves which are less prominent than those of the central incisor. The mesial margin is nearly straight from the mesial angle to the cervix, being sometimes, however, slightly concave which causes a hook-like appearance to this surface of the tooth. The cervical margin is markedly convex rootward since the tooth is narrower than the central incisor, while the distal margin is also made convex

FIG. 12.—Right Upper Lateral Incisor. Mesial Surface.

FIG. 13.—Right Upper Lateral Incisor. Distal Surface.

from the projection of its distal angle. The latter is longer than the mesial margin circumferentially, but a straight line drawn from the distal angle to the cervix shows that this portion of the face is shorter than the mesial portion. The labial surface is more rounded in every way than that of the central. The *cervical ridge* and developmental grooves are present but are not so pronounced.

The Lingual Surface (Fig. 11).—Like that of the central incisor, this surface is usually slightly concave, which is due to the projection of the mesial, distal and cervical marginal ridges. In outline it is nearly triangular. The incisive margin is the same shape as that de-

scribed for the labial surface. The *mesial and distal marginal ridges* are well marked and unite with the cervical. Both the mesial and distal margins are usually convex although the mesial may be almost straight. The distal is much shorter. The cervical margin is formed by the *cervical ridge* and is more frequently the seat of a *cingulum* than that of the central incisor. While the surface is usually concave in all directions, in some instances it may be almost flat. There is normally a well-defined *fossa* and in some cases this latter is marked with a *longitudinal ridge* corresponding to that on the labial face.

The Mesial Surface (Fig. 12).—Shaped like an arrow-head, the cervical margin being concave, the labial margin of this surface is convex with a long curve. The lingual margin is less distinctly marked, is concave, and unites with the labial at the mesial angle of the crown. The surface is convex in its lower two-thirds but becomes flattened toward the cervix where sometimes a pronounced depression may exist. The point of contact with the central is about one-third the distance from the cutting edge.

FIG. 14.—Right Upper Lateral Incisor. Occlusal View.

The Distal Surface (Fig. 13).—This has the same general outline as the mesial but is more rounded in every way. The cervical margin is similar to that on the mesial face but the labial and lingual are shorter, meeting at the distal angle which is less sharp and nearer the gingival margin than the mesial angle. The prominence of this surface makes this tooth quite different from the other incisors and it is more nearly the shape of that of the cuspid with which it is in contact.

The Cervical Margin.—Although like the central in general characteristics, the labial and lingual portions of this line are more convex rootward, the latter being a sharper curve and extending proportionately higher than the labial. The mesial and distal portions are concave rootward, are similar in general form, and are quite angular.

The Incisive Edge (Fig. 14).—This is proportionately shorter than that of the central, is often a nearly straight line between the angles of the crown and is usually slightly curved in a labial direction as the tooth, is viewed from below. Like the central incisor, at the time of its eruption it displays usually three developmental tubercles which indicate the three points at which calcification begins, but these are soon worn off.

The Root.—The root of the lateral incisor has a general conical form, is often slightly longer than that of the central incisor, and is

flattened mesio-distally. Its extremity usually has a slight distal bend. At the neck of the tooth it is almost circular in cross-section and is again at the apex, but the intervening portion exhibits the flattening above referred to and in some instances pronounced grooves upon the mesial and distal surfaces. In the center of its length the root is approximately one-third greater in labio-lingual diameter than mesio-distally.

The Pulp Cavity.—This corresponds in form to that of the tooth and differs but little except in size from that of the central incisor.

FIG. 15.—Right Lower Central Incisor. Labial Surface.

FIG. 16.—Right Lower Central Incisor. Lingual Surface.

THE LOWER CENTRAL INCISOR.

This is the smallest tooth in the mouth. Its crown is wedge-shaped (Fig. 17).

The Labial Surface (Fig. 15).—In outline this face of the crown is nearly triangular, the incisive margin being the base while the mesial and distal margins converge to the rounded apex formed by the cervical margin. The incisive edge is nearly straight and almost at right angles with the long axis of the tooth. The mesial and distal margins are

long curves, the distal being very slightly shorter and more curved. The cervical border is very short; the surface is convex from incisive edge to cervix, and, when seen in profile, almost exactly the arc of a circle. Near the incisive edge the surface is nearly straight, the division between it and the mesial distal surfaces being marked by fairly well-defined angles; as the cervix is approached, however, it becomes

FIG. 17.—Right Lower Central Incisor. Mesial Surface.

FIG. 18.—Right Lower Central Incisor. Distal Surface.

more rounded. Like the upper incisors it is sometimes marked by two developmental grooves but these are normally poorly discernible except in young teeth.

The Lingual Surface (Fig. 16).—Like the labial this is nearly triangular in outline but the rounded apex formed by the cervical margin is more nearly an acute angle. The surface is concave from incisive margin to the cervical ridge when this latter causes it to be marked with a convexity which ends abruptly by a well-defined margin at the neck of the tooth. The mesial and distal marginal ridges are usually poorly defined, the cervical ridge in which they unite corresponding with them in this particular except that it is usually somewhat

more easily traced. The occlusal third of this surface is usually slightly bowed in a labial direction, making it concave mesio-distally, but this concavity gradually disappears before the center of the surface is reached.

FIG. 19.—Right Lower Central Incisor. Occlusal View.

The Mesial Surface (Fig. 17).—This is triangular in outline, but unlike the labial and lingual surfaces the base of the triangle is directed rootward and is formed by a concave cervical margin. The sides of the triangle formed by the labial and lingual margins are curved in a labial direction, the labial being shorter and more curved and meeting the lingual at the mesial angle of the tooth. This surface is slightly convex, being most markedly so at its center just above which point it is in contact with its fellow of the opposite side.

The Distal Surface (Fig. 18).—This is similar in outline and contour to the mesial surface, except that it is slightly shorter and is more convex in its incisive third because the labial and lingual margins meet in a more rounded eminence the distal angle. Near the cervical margin it is often slightly concave, in which instance the concavity in commonly continued up the root as a longitudinal depression.

The Incisive Edge (Figs. 15 and 19).—Like those of the upper jaw the lower central incisor at the time of its eruption is usually characterized by the presence of three tubercles upon its incisive edge. These are soon worn off and the edge is then straight. It occupies a line at right angles to the long axis of the tooth, terminating in the mesial and distal angles of which the former is slightly the more pronounced.

FIG. 20.—Right Lower Central Incisor. Labio-lingual longitudinal section showing bifurcation of pulp canal.

The Cervical Margin.—This is similar in outline to that of the upper incisors except that it is more angular. On the mesial and distal surfaces it is markedly concave in the direction of the crown and extends rootward on the lingual and the labial surface. The lingual portion is short and angular, which

latter characteristic is caused by the projection downward of the abrupt cervical ridge of this surface of the crown. The labial portion of the cervical margin is concave rootward but less sharply so than the lingual.

The Root.—The root on this tooth is more delicate than that of any other in the mouth. It is conical in shape, being much flattened upon its mesial and distal sides (Figs. 17 and 18) at the cervix from which point these surfaces slope in almost straight lines to the apex. This latter is sometimes slightly deflected in a distal direction. These sides of the root are frequently marked with longitudinal grooves which extend almost to the apex. The labial and lingual aspects of the root are narrow, the former being the wider and they converge gradually to within a short distance of the apex when they rapidly approach each other and give the root a rounded appearance which is observed when it is viewed from the mesial or distal side. The labial surface of the root continues the line of that surface of the crown, making with it almost a perfect arc of a circle.

FIG. 21.—Right Lower Central Incisor. Cross-section of crown near its middle looking rootward.

The Pulp Cavity.—This cavity follows the general form of the exterior of the tooth and only a few points need to be touched upon in its description. The horns of the pulp chamber extend well toward the mesial and distal surfaces, but the cavity is very narrow labio-lingually at its extremity. There is no perceptible line of division between this and the pulp canal. The latter is flattened and narrow in its beginning at the cervix (Fig. 20) and occasionally divides into two canals which usually unite near the apex and terminate in a single foramen. In most instances, however, it exists as a small, slightly flattened canal.

THE LOWER LATERAL INCISOR.

This tooth so nearly resembles the lower central incisor that separate description seems superfluous, therefore only its differentiating characteristics will be pointed out. It is wider mesio-distially than the lower central incisor; its distal angle is more rounded and its distal surface slightly more convex. Its root is somewhat longer than that of the lower central incisor and at its apex is often bent distally. The pulp chamber is similar in all respects to that of the lower central incisor except that it is slightly larger in its coronal portion in correspondence with the greater size of the crown.

THE UPPER CUSPID.

The crown of this tooth presents for examination four surfaces and a cusp.

The Labial Surface (Fig. 22).—The outline of this surface shows that it is bounded with five margins. The incisal portion provides two, the mesial and distal incisive edges. The former of these extends from the point of the cusp to the mesial angle, being either concave because of the presence of a developmental

FIG. 22.—Right Upper Cuspid. Labial Surface.

FIG. 23.—Right Upper Cuspid. Lingual Surface.

groove or it may be slightly convex. The distal incisive margin which extends from the cusp to the distal angle is usually longer than the mesial incisive and more frequently marked with a slight convexity. The wearing down of the cusp in adult teeth usually results in making the point of separation between these margins less distinct. The mesial margin of the labial surface is convex, as is also the distal which descends from the distal angle of the crown. The cervical margin follows very much the same curve as that of the central incisor, the highest portion of its convexity, however, being a little nearer its mesial

end. The surface is convex from cusp to cervix and also from the mesial to the distal angle but is sometimes marked by two longitudinal developmental grooves. These, beginning nearer the mesial and distal angles than the cusp of the crown, ascend toward the cervix, gradually disappearing about the upper third of the surface. The labial ridge ascends from the cusp, being located nearer the mesial than the distal surface of the crown, and gradually blends with the rounded convexity of the upper third of this surface. When the developmental grooves

FIG. 24.—Right Upper Cuspid. Mesial Surface.

FIG. 25.—Right Upper Cuspid. Distal Surface.

are not marked the labial surface mesial to the ridge is more convex than that distal to it.

The Lingual Surface (Fig. 23).—With much the same outline as the labial face, this surface is slightly smaller, but is proportionately longer from cusp to cervix, and has a shorter and more convex cervical margin. The surface has a general convexity and is marked by a lingual ridge which ascends from the cusp and does not fade away until it reaches the cervical marginal ridge. It corresponds in position to the labial ridge of the opposite face of the crown. In distinctly marked teeth there is a groove on either side of this ridge.

The cervical marginal ridge is usually a pronounced, rounded elevation affording a distinct line of demarcation between the crown and root of this tooth. It is frequently the seat of an elevation at or near its center, and may have a fissure dividing the ridge on either or both sides of the cingulum. The mesial and distal marginal ridges are less well marked than the cervical from which they extend to the mesial and distal angles of the crown. The mesial is the longer and better defined.

FIG. 26.—Right Upper Cuspid. Occlusal View.

The Mesial Surface (Fig. 24).—Shaped like an arrow-head, the labial boundary convex and the lingual usually concave, the outline of this surface is completed by the concave cervical margin. The highest portion of this latter is slightly nearer its junction with the labial than with the lingual margin. The mesial angle which is the meeting ground of the labial and lingual margins is just below the point at which this tooth is in contact with the lateral incisor. It is not quite so near the cervix as is the distal angle. The surface is nearly convex in its lower two-thirds but above this point may be flat or slightly concave.

The Distal Surface (Fig. 25).—This is similar in shape to the mesial but is somewhat smaller in extent and more convex. The distal angle is more protuberant than the mesial and just above it is a rounded point with which the tooth is in contact with the first bicuspid. The cervical margin is less concave than the mesial and its highest portion is nearer the labial than the lingual margin.

FIG. 27.—Right Upper Cuspid. Longitudinal section cut antero-posteriorly showing pulp cavity.

The Cusp (Fig. 26).—This is the prominent point of the cutting edge and is formed by the union of the mesial and distal cutting edges and the labial and lingual ridges. It is sharp in well-marked teeth at the time of eruption but the point is soon worn down and may be blunt or rounded.

The Cervical Margin.—Convex labially and lingually and concave

mesially and distally, this margin corresponds closely to that of the upper central incisor.

The Root.—Like that of all single-rooted teeth the root of the upper cuspid is conical. On all its four sides it gradually tapers from the cervix to the apex. In cross-section at the cervcial margins (Fig. 28) it is ovoid or may be almost circular. In the former instance the labial side is the segment of a larger circle than the lingual. The mesial and distal aspects of the roots are often flattened, in which case their centers sometimes present poorly marked longitudinal grooves. At the apex the root is usually inclined in a distal direction or the whole root may have a slight distal curve.

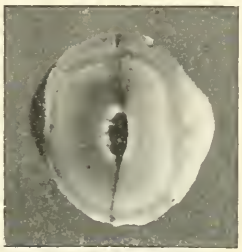

FIG. 28.—Right Upper Cuspid. Cross-section at cervix looking crownward, showing shape of pulp cavity.

The Pulp Cavity (Figs. 27 and 28).—In the young tooth there is a pronounced projection of the pulp chamber wall toward the cusp of this tooth, but as it becomes more mature the pulp cavity becomes more flattened here. Otherwise it is very much like the external form of the tooth, extending well toward the mesial and distal angles, and closely resembling that of the central incisor. At the level of the cervix it is oval in cross-section and extends gradually diminishing in size to the apex. There is no line of demarcation between the root and coronal portion of the cavity.

THE LOWER CUSPID.

The crown of the cuspid of the lower series is very similar to that of its upper, except that it is narrower, more delicate and slightly longer, and usually not so well marked.

The Labial Surface.—The markings of this surface are not so pronounced as those of the upper cuspid. The outline is less angular than that of the upper, with the exception of that portion formed by the mesial and distal incisive edges, for its cusp is more pointed than that of the upper cuspid. The developmental grooves are usually poorly defined, the labial ridge being the most prominent marking of this surface and giving to it a marked convexity. This ridge, as in the upper cuspid, is located decidedly nearer the mesial than the distal margin. The mesial margin is more pronounced than the distal, the labial surface meeting the mesial somewhat more abruptly than the distal into which it passes by a rounded curve without definition.

The Lingual Surface.—The outline is more rounded and the surface markings less bold than those of the upper cuspid. The marginal ridges are usually poorly defined, that at the cervix being more prominent than the mesial or distal. The lingual ridge extends from the cusp to the cervix, dividing this surface and forming two very shallow grooves or fossæ, the lingual grooves; but the surface is less convex than that of the upper, especially at the occlusal end, which is sometimes flat mesio-distally.

The Mesial Surface.—Similar in shape to that of the upper, yet differing from it in some particulars, this surface of the lower cuspid possesses the peculiarity of being almost flat and being continuous as an almost plane surface with the root. At the cervix it is slightly concave or it may be simply flat, but it assumes a convex character as the mesial angle is approached. The cervical outline is much less concave rootward than that of this face of the upper cuspid, but similarly it extends to a lower level lingually than labially. The lingual margin is well defined but the labial is rounded.

The Distal Surface.—The convexity characteristic of this surface of the upper cuspid is observed here, except that the cervical portion is sometimes slightly concave. The surface is smaller in extent than the mesial, a fact due to the lower location of the distal angle. The cervical margin is pronounced, the surface of the root usually forming a decided angle with that of the crown. The lingual margin is more marked than the labial, but by comparison they are less clearly defined than those on the mesial surface.

The Cusp.—The prominent point of the tooth occupies a line almost in its long axis. From it descend the mesial and distal incisal edges of which the latter is slightly longer, but the difference is not so marked as in the upper cuspid.

The Cervical Margin.—This is concave in the direction of the root on the labial and lingual sides and convex on the mesial and distal. On the lingual and distal sides the root and crown join more abruptly than on the mesial and labial.

The Root.—The root is shorter than that of the upper cuspid and is flattened on its mesial and distal sides. Viewed in profile from any of the four surfaces its sides slope gradually to the apex which is frequently inclined to the distal.

The Pulp Cavity.—This resembles that of the upper cuspid except that it is narrower mesio-distally, a difference in form likewise observable in the crowns of the two teeth. It has no horns of the pulp chamber but terminates in a pointed extremity beneath the cusp.

The pulp canal is flattened mesio-distally at the cervix but becomes circular in its apical portion.

THE UPPER FIRST BICUSPID.

The crown of this tooth presents for examination five surfaces, namely, occlusal, buccal, lingual, mesial and distal. It is irregularly cuboidal in shape.

The Occlusal Surface (Fig. 29).—When viewed from the occlusal surface the crown appears ovoid in outline, whereas the occlusal surface proper is trapezoidal, the oval appearance being due to the projection of the upper portion of the buccal face of the tooth. The most prominent features of this surface are the two cusps surmounting its buccal and lingual portions, the buccal and lingual cusps, which are separated by the central groove and which give to the tooth its distinguishing character (bicuspid). The margins are formed by the buccal cusp with its descending mesial and distal inclines, the mesial and distal marginal ridges, which are well-defined ridges of enamel joining the ridges of the buccal cusp at the mesial and distal angles of the crown and converge to join descending ridges from the lingual cusp and the lingual cusp itself.

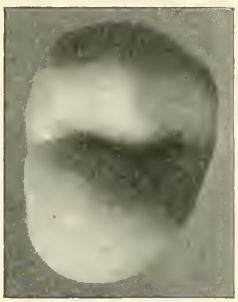

FIG. 29.—Left Upper First Bicuspid. Occlusal Surface.

The *buccal cusp* is the larger, sharper and more prominent. From its summit four ridges descend; the buccal ridge, which is partly responsible for the prominence of the buccal surface of the crown; the triangular ridge, which extends downward toward the central groove and usually terminates there; and one each mesially and distally to reach the mesial and distal angles respectively. Of these latter two, the distal is usually the larger and the more inclined, the point of the cusp being usually nearer the mesial than the distal face of the crown.

The lingual cusp is lower and much more rounded than the buccal and the three ridges descending from it are less pronounced. The triangular ridge is often missing but when present it descends toward the central groove to meet the ridge from the buccal cusp. Occasionally these two triangular ridges unite and form the transverse ridge, but usually they are separated by a fissure in the central groove. The ridges descending mesially and distally from this cusp join and are continuous with the marginal ridges, being curved so that the lingual outline of the occlusal surface is much rounded. The lingual aspect

of the lingual cusp is convex and rounded and gradually blends with the lingual surface.

The mesio-distal groove separates the cusps and extends from the mesial to the distal marginal ridges. It is sometimes extended at each extremity into the mesial and distal developmental grooves which when present are fine lines crossing the marginal ridges to reach the mesial and distal surfaces of the crown. The triangular grooves are short, cross the central groove at its terminations at right angles, ex-

FIG. 30.—Left Upper First Bicuspid. Buccal Surface.

FIG. 31.—Left Upper First Bicuspid. Lingual Surface.

tend toward the angles of the crown, and separate the mesial and distal marginal ridges from the triangular ridges. The junctions of these grooves with the central groove are often spoken of as the mesial and distal pit.

The Buccal Surface (Fig. 30).—This closely resembles in form and outline the labial surface of the cuspid tooth, being smaller and more compressed occluso-gingivally. It is bounded by four margins, the occlusal, the cervical, the mesial and the distal. The occlusal is formed by the mesial and distal inclines of the buccal cusp and is well defined. The mesial incline is usually a straight line or is slightly convex,

while the distal may be marked with a concavity caused by the distal buccal groove. The mesial border is more sharply defined than the distal. It descends from the mesial angle to the cervical border, which latter is nearly straight or may be slightly convex rootward and is not distinctly marked by an abrupt termination of the enamel. The distal margin is usually shorter and more rounded than the mesial, because of the lower position of the distal angle, and the fact that the buccal surface rounds into the distal without a sharp line of definition. The buccal

FIG. 32.—Left Upper First Bicuspid. Mesial Surface.

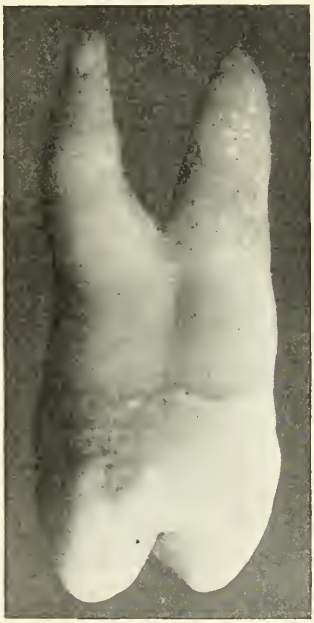

FIG. 33.—Left Upper First Bicuspid. Distal Surface.

ridge, descending from the buccal cusp and flanked by the buccal developmental grooves, which are forced well towards the angles of the crown, contributes towards the convexity of this surface. It usually disappears by blending with this convexity about the center of the surface, but occasionally in well-marked teeth it extends almost to the cervical margin. The greater mesio-distal diameter of the crown at the level of the angles than at the cervical margin gives to the crown its characteristic bell-shape, which may be well observed when looking at the buccal surface.

The Lingual Surface (Fig. 31).—This face is smaller than the buccal, being both shorter and narrower. It is convex mesio-distally

and rounds into the mesial and distal face without line of demarcation. Its occlusal margin is also rounded, being formed by the lingual cusp and the ridges descending from it, while the gingival margin is either nearly straight or is only slightly convex rootward. The surface is curved from the summit of the lingual cusp, which is slightly nearer the mesial face of the crown, to the cervix, its outline when seen in profile being a long gentle curve. It is usually quite smooth and without grooves.

FIG. 34.—Left Upper First Bicuspid. Bucco-lingual longitudinal section, showing pulp chamber, its horns, and the pulp canals.

The Mesial Surface (Fig. 32).—Irregularly quadrilateral in shape, this face of the crown is bordered occlusally by the mesial marginal ridge and a portion of the ridge from the lingual cusp, and gingivally by the cervical line which is usually nearly straight or slightly concave in the direction of the root. The occlusal margin is concave, the concavity being about midway between the cusps. Frequently this margin is broken by the mesial developmental groove which reaches this face from the occlusal surface and usually terminates about its center. The buccal margin is fairly well defined and extends from the mesial angle to the cervix, while the lingual is so rounded by the gradual joining of the lingual surface as to be indistinguishable. Near the occlusal margin the surface is full and rounded, giving a point of contact for the proximal side of the cuspid, but it flattens out as the cervix is approached and in this location is usually the seat of a depression which is continued up the face of the root.

The Distal Surface (Fig. 33).—While this is much like the mesial surface, it is smaller in extent and more convex. The buccal margin is not so pronounced as that of the mesial face and is usually shorter. The cervical, lingual and occlusal margins are very much like those of the mesial face and the lingual is poorly defined and much rounded. In its occlusal third the surface is quite convex in all directions and this usually extends in decreasing degree to the cervix, although the corresponding portion of the mesial face is usually concave bucco-

lingually. The distal developmental groove sometimes crosses the upper margin from the occlusal surface and disappears about the center of the surface.

The Cervical Margin.—This is more nearly straight around the tooth than that of any of the teeth so far described, usually having, however, a slight curve rootward on both buccal and lingual surfaces and being curved toward the occlusal surface on the mesial and distal faces.

The Root.—The upper first bicuspid usually has two roots (Fig. 32) or two branches of its root, which are located beneath its two cusps and are called the buccal and lingual roots. Occasionally the tooth has only one root or the division may occur very near its apex. In the former instance the central portion of the root between the two pulp canals is thin and usually consists only of cementum. The occurrence of two separated roots is most frequently noted and in this instance the roots are delicate and taper gradually to a somewhat sharp apical extremity and are usually curved in several directions. These curves are usually first in a buccal and lingual direction, serving to separate the roots which again approach each other at their terminations. There is often a gentle distal curve in both roots. The bifurcation is usually located about one-third the distance from the cervix, and is accomplished by a meeting of the groove noted on the mesial face of the root and originating in the crown, with one which develops above the cervix on the distal side of the root.

FIG. 35.—Left Upper First Bicuspid. Cross-section of root near cervix, showing shape of pulp canal.

The Pulp Cavity.—The pulp chamber and the pulp canal are usually differentiated in this tooth (Fig. 34), the chamber corresponding to the general shape of the crown, the canals to the form of the roots. The chamber is a cavity with flattened mesial and distal walls and curved buccal and lingual walls. In the mature tooth these latter are nearly parallel and terminate occlusally in the buccal and lingual horns of the pulp chamber, which are cone-shaped projections of the cavity penetrating the two cusps. The occlusal wall of the chamber is marked by a projection corresponding to the central groove of the occlusal surface of the crown. In horizontal cross-section at this level, the cavity is larger than at the cervix, the mesial and distal walls converging to this point in correspondence with the external surface of the crown.

The floor of the pulp chamber, which is usually about on a level with the cervix, differs in character in accordance with the root formation of the tooth. In teeth with two roots or in those with two root canals, the buccal and lingual walls of the chamber are continued as the corresponding walls of the two pulp canals, but in old teeth a line of definition between the two is caused by an inward projection of the wall. The openings to the two canals are funnel-shaped and are separated by a ridge corresponding to the root bifurcation. The canals are usually about circular in cross-section, and follow the directions of the roots, occupying their centers. When the tooth has only one root, it sometimes has only one pulp canal (Fig. 35), which is flat and ribbon-like in its gingival portion, becoming more nearly round as the apex is reached. Often in single-rooted teeth there are two pulp canals, which either terminate in separate foramina close together or coalesce just before reaching the apex, a single canal making exit at the apex.

THE UPPER SECOND BICUSPID.

This tooth so closely resembles the upper first bicuspid that it will only be necessary to point out the differences between the two. The crown of the tooth is smaller and its prominences are more rounded than those of the first bicuspid. It is always shorter from cusps to cervix but the bucco-lingual diameter at the cervix is sometimes slightly greater than that of the first. On the occlusal surface (Fig. 36) both cusps are more rounded, and, unlike the first bicuspid, are usually of equal length. The lingual cusp is usually equal in size to that of the first bicuspid while the buccal is smaller, in consequence of which facts the two cusps of this tooth are approximately equal in size. The triangular ridges usually unite to form a transverse ridge, the central groove is shortened mesio-distally, and usually terminates in pits instead of well-marked triangular grooves. The buccal (Fig. 37) and lingual (Fig. 38) faces of the crown are smaller and more rounded than those of the first bicuspid, the mesial (Fig. 39) and distal (Fig. 40) faces being similar to those of the first except that the concavity on its mesial face near the cervical margin is missing. This is one of the chief distinguishing features of the tooth. The cervical margin more nearly occupies a horizontal plane than that of the first bicuspid, being

Fig. 36.—Right Upper Second Bicuspid. Occlusal Surface.

FIG. 37.—Right Upper Second Bicuspid. Buccal Surface.

FIG. 38.—Right Upper Second Bicuspid. Lingual Surface.

FIG. 39.—Right Upper Second Bicuspid. Mesial Surface.

FIG. 40.—Right Upper Second Bicuspid. Distal Surface.

slightly curved rootward on buccal and lingual surfaces and being almost straight on the mesial and distal sides. A single root is char-

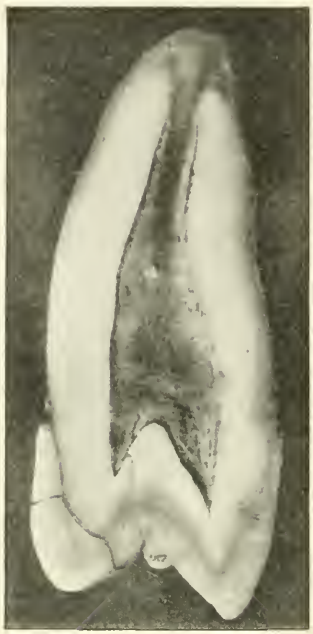

FIG. 41.—Right Upper Second Bicuspid. Bucco-lingual longitudinal section, showing pulp cavity.

FIG. 42.—Right Upper Second Bicuspid. Mesio-distal longitudinal section, looking buccally. Showing pulp cavity.

acteristic of this tooth. It is much flattened on its mesial and distal sides and is usually marked with a longitudinal groove on each of these surfaces. Its extremity is usually rounded and occasionally bifid. Its buccal and lingual surfaces converge much more in reaching the apex than do its mesial and distal. The root sometimes has a curve in a distal direction near its termination.

FIG. 43.—Right Upper Second Bicuspid. Cross-section of root above cervix, showing pulp canal.

Inasmuch as this tooth normally has but one root, the pulp cavity consists of a pulp chamber corresponding in shape to that of the crown and a single pulp canal (Fig. 41). While the pulp chamber is similar in form to that of the first bicuspid, the horns of the chamber are less pointed and penetrating, because of the differences in the cusps of these two teeth. The pulp canal has its walls continuous with those of the chamber, no definite demarcation be-

tween the two existing. It is narrow mesio-distally and ribbon-like at the cervix but is usually easy to enter (Fig. 43). Occasionally this tooth has two roots, in which case two root canals can be found, and their existence should be considered among the rare possibilities in the treatment of these teeth.

THE LOWER FIRST BICUSPID.

While partaking of the characteristics of the upper bicuspid teeth, the lower first bicuspid departs from the typical bicuspid design in the rudimentary development of its lingual cusp. The great variation in the development of this cusp accounts for the variations in form so commonly observed in this tooth.

The Occlusal Surface (Fig. 44).—Viewed from the occlusal surface the outline of the crown appears almost circular or ovoid but this is due to the fact that the upper portion of the bulging buccal face is visible. The surface presents for examination a buccal cusp, either a lingual cusp or a lingual ridge, a mesial and distal pit and marginal ridges bordering the surface. The summit of the buccal cusp is nearly in the line of the long axis of the crown. Four ridges descend from it, one each in a buccal, lingual, mesial and distal direction. The two latter unite at the mesial and dista angles with the marginal ridges. The buccal extends upon the buccal face of the crown and the lingual is more strongly developed, is not crossed by a groove, reaches the lingual ridge or lingual cusp, and separates the mesial and distal pits. The mesial and distal marginal ridges converge to unite and form a semicircle with a lingual prominence of enamel, which when much elevated above the adjoining margin ridges is considered the lingual cusp and when only existing as a ridge is called the lingual marginal ridge.

FIG. 44.—Left Lower First Bicuspid. Occlusal Surface.

The Buccal Surface (Fig. 45).—This corresponds so closely to that of an upper bicuspid that detailed description would be superfluous. The cusp is not so pointed, the buccal developmental grooves are poorly developed, the crown is shorter and narrower than its fellow of the upper series, the cervical line is almost straight, and the surface is convex and slopes inward to the summit of the buccal cusp which is usually in line with the long axis of the root.

The Lingual Surface (Fig. 46).—This is small because of the small

FIG. 45.—Left Lower First Bicuspid. Buccal Surface.

FIG. 46.—Left Lower First Bicuspid. Lingual Surface.

FIG. 47.—Left Lower First Bicuspid Mesial Surface.

FIG 48 – Left Lower First Bicuspid. Distal Surface.

size and low position of the lingual cusp. The occlusal margin is well defined and the surface is nearly straight from this point to the cervix and in many instances is continued without marked division into the surface of the root or it may make an obtuse angle with this face of the root. Mesio-distally it is much rounded passing into the proximal surfaces with a gentle curve.

The Mesial Surface (Fig. 47).—Irregularly quadrilateral in outline, with only its occlusal margin well defined by the marginal ridge,

FIG. 49.—Right Lower First Bicuspid. Mesio-distal longitudinal section, showing pulp cavity.

FIG. 50.—Right Lower First Bicuspid. Bucco-lingual longitudinal section, showing pulp cavity.

this surface is generally convex. The most prominent point of the convexity is located centrally just below the occlusal margin from which the surface inclines inward toward the central axis of the tooth, contributing thereby to give the bell-shape which is observed of this crown as it is viewed from the buccal or lingual side. At the cervix the surface is flattened.

The Distal Surface (Fig. 48).—This is almost similar to the mesial except that its convexity is usually less pronounced.

The Cervical Margin.—The juncture between enamel and cementum in this tooth occupies nearly a horizontal plane, being continued

around the tooth in almost a straight line. There is frequently a dip rootward on the buccal face.

The Root.—A single root normally characterizes the lower first bicuspid although in rare instances two roots are found. When single it is conical, the buccal and lingual sides being uniformly inclined toward each other and continuing these faces of the crown. The lingual is the narrower, which is caused by the fact that the flattened mesial and distal faces converge in passing lingually. These latter are usually slightly convex and uniformly taper to the apex, but occasionally they are marked with a shallow longitudinal depression. The end of the root is sharply pointed and is frequently deflected distally. The cervical portion of the root is oval in cross-section.

FIG. 51.—Right Lower First Bicuspid. Cross-section at cervix showing pulp canal.

The Pulp Cavity.—As in all single rooted teeth there is no sharp division between the pulp chamber and canal (Fig. 49). The chamber has one well-defined horn situated beneath the buccal cusp and when a lingual cusp exists there is a small projection of the cavity in its direction (Fig. 50). At the level of the gingival margin the cavity is oval in cross-section whence it continues diminishing in bucco-lingual diameter to the apical foramen (Fig. 51). It is usually small and thread-like in the apical third of the root.

THE LOWER SECOND BICUSPID.

While this tooth bears a close resemblance to the lower first bicuspid tooth in many particulars, in some details it is quite different. These chiefly pertain to the lingual portion of the occlusal face of the crown and the adjacent surfaces which are related therewith. In general the crown of the tooth is smaller and more rounded than the first. Viewed from the occlusal face it will be seen that this surface is larger and even more nearly circular in outline than the first. In some instances this is due to the presence of a well-developed lingual cusp and prominent marginal ridges mesially and distally. In other instances the same rounded outline is caused by the presence of two lingual cusps, a fissure dividing the lingual portion in its center. The buccal cusp is less prominent than that of the first bicuspid, and has a well-defined triangular ridge which seldom unites with that of the lingual cusp. When present the lingual cusp is smaller than and

not so prominent as the buccal and is usually separated from it by a mesio-distal groove. This latter terminates in pits, the mesial and distal pits, and is curved lingually. When the face presents three cusps the groove has three branches meeting in a contral pit or fossa. The angles of the crown are not well marked.

The buccal surface is more rounded and shorter and wider than that of the first bicuspid. The lingual surface is proportionally larger than the lingual of the lower first bicuspid, being longer occluso-gingivally because of the lingual cusp at the base of which it is also wider mesio-distally. The mesial and distal faces of the crown are similar to those of the first bicuspid except that they are wider bucco-lingually and are both slightly more convex. The cervical margin encircles the tooth almost in a horizontal plane, but a curve rootward may usually be made out on the buccal face. The single root is conical, proportionately longer than that of the first bicuspid, flattened on its mesial and distal sides, and usually bent distally in its lower portion. The pulp cavity is larger than that of the first bicuspid, the chamber being shaped to correspond with the external surface of the crown and having the rudimentary lingual horn better developed. The canal is oval or circular in cross-section at the cervix from whence it tapers gradually to the apical foramen.

THE UPPER FIRST MOLAR.

The crown of the upper first molar is roughly cuboidal in shape and offers for examination five surfaces—occlusal, buccal, lingual, mesial and distal.

The Occlusal Surface (Fig. 52).—This is irregularly rhomboidal in outline as may be seen when the crown is viewed from this surface. The mesial and distal margins are nearly straight and parallel; the buccal and lingual margins are curved. At the mesio-buccal and disto-lingual juncture of these margins acute angles are formed while the angles at the disto-buccal and mesio-lingual juncture are obtuse. The surface is marked by the presence of four cusps, four marginal ridges, two fossæ, and several developmental grooves. The mesial marginal ridge is a rounded and well-defined elevation of enamel extending from the summit of the mesio-buccal cusp to that of the mesio-lingual cusp, and is curved rootward between these points. It is often crossed near its center by the mesial developmental groove which extends from the occlusal to the mesial surface. The buccal marginal ridge unites with the mesial at the mesio-buccal angle of the tooth. It

extends from this point to the point of the mesio-buccal cusp, then in a slightly lingual direction to the bottom of the buccal groove, then buccally to the point of the disto-buccal cusp and then to the disto-buccal angle, being curved latterly in a lingual direction to unite with the distal marginal ridge. It is the sharpest of the marginal ridges, a fact in large part due to the sharpness of the buccal cusps.

The distal marginal ridge is similar to the mesial in that it is curved rootward between its terminations and is a rounded ridge of enamel. It is marked to the buccal side of its center by the distal groove, which passes over upon the distal face of the crown. The lingual termination is well rounded and consequently less easily differentiated from the disto-lingual cusp in which it terminates. The lingual marginal ridge completes the periphery of the occlusal surface, extending from the disto-lingual to the mesio-lingual angle of the crown. From its mesial end it curves lingually to the summit of the mesio-lingual cusp, then buccally to the point where it is divided by the disto-lingual cusp and then lingually again to the top of the disto-lingual cusp. It is the most rounded of the marginal ridges.

FIG. 52.—Left Upper First Molar. Occlusal Surface.

The Cusps.—The upper first molar may be said to possess four cusps normally but in a large number of cases it has five. The mesio-buccal cusp, located near the mesio-buccal angle of the tooth, is sharp and from its summit descend four ridges. These latter are the buccal, which continues upon the buccal surface of the crown, the triangular which descends into the central fossa, and the two ridges descending mesially and distally forming portions of the buccal marginal ridge. The disto-buccal cusp is somewhat smaller than the one just described, but like it is sharp and has four ridges descending from its point. The buccal ridge descends upon the buccal face, the mesial and distal ridges are portions of the buccal marginal, while the fourth ridge unites with one from the mesio-lingual cusp to form the oblique ridge. The disto-lingual cusp is usually the smallest (except the fifth) and is rounded. But two ridges descend from it, one each in a mesial and lingual direction to form the marginal ridge of these boundaries. Its lingual and distal aspects fade off into these respective faces of the

crown without demarcation. It is separated from the oblique ridge by the disto-lingual groove. The mesio-lingual cusp is frequently the largest cusp of this tooth. It is much rounded and has ridges descending from it as follows: one to the mesial to join the mesial marginal ridge and one distally forming a portion of the lingual marginal ridge, while one passes in the direction of the disto-buccal cusp, meeting a ridge from the latter to form the oblique ridge. The buccal

FIG. 53.—Left Upper First Molar. Buccal Surface.

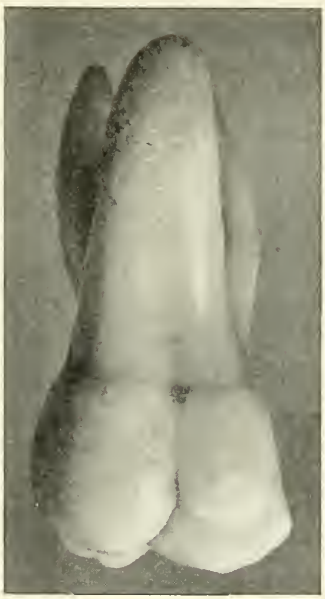

FIG. 54.—Left Upper First Molar. Lingual Surface.

aspect of the cusp forms a wall of the central fossa, while the lingual side is rounded and descends without demarcation into the lingual surface of the crown, or in teeth with a fifth cusp descends into the groove dividing the latter from the crown. The fifth cusp, or lingual cingule as it is sometimes called, varies much in size and occurrence. When present it is an elevation of enamel on the lingual surface of the crown, near and just distal to the mesio-lingual angle and at the lingual base of the mesio-lingual cusp from which it is separated by a groove, the mesio-lingual.

The Fossæ and Grooves.—The central fossa is triangular in shape and occupies the space between the mesio-buccal, disto-buccal and mesio-lingual cusps, its walls being formed by the central inclines of

these cusps and the mesial marginal ridge. In its center is the central pit from which radiate the mesial developmental groove, which passes forward over the mesial marginal ridge to the mesial face of the crown, the buccal groove which divides the mesio-buccal from the disto-buccal cusp and reaches the buccal surface of the crown, and the distal which is less well marked and passes distally over the oblique ridge. Each of these grooves may be the seat of a fault or fissure, the buccal exhibiting it more commonly and the distal less commonly than the others. The distal fossa is smaller than the central and is located between the disto-lingual and disto-buccal cusps and the distal marginal and oblique ridges. Its longest dimension is disto-lingually in which direction it is traversed by the disto-lingual groove. This latter has its terminations in the lingual pit near the center of the lingual surface and a pit in the distal fossa. It is parallel to the oblique ridge, dividing the disto-lingual cusp from this, and is usually the seat of a fissure, the result of faulty union of the developmental lobes of the crown. The distal groove passes through this fossa, crossing the oblique ridge anteriorly and the distal marginal ridge posteriorly.

Fig. 55.—Left Upper First Molar. Mesial Surface.

The Buccal Surface (Fig. 53).—This is bounded by four margins, of which the occlusal is irregular, sharp and prominent, being formed by the buccal marginal ridge and the two buccal cusps, the cervical is almost straight, while the mesial and distal are not well marked, the distal being less so than the mesial. The two latter are rounded and fade into the respective faces of the crown. They converge from the occlusal surface to the cervix, so that when the tooth is viewed from the buccal face the bell-shape of its crown is noticeable. For the most part the surface is slightly convex having, however, a depression near its center in which is frequently located a buccal pit. The buccal groove divides it into two lobes and usually terminates in the

buccal pit, but the depression is sometimes continued rootward and is continuous with that between the two buccal roots. At the cervix there is a ridge of enamel, the cervical ridge, which gives prominence to this line.

The Lingual Surface (Fig. 54).—This is somewhat similar in outline to the buccal, but is narrowed mesio-distally at the cervix as the sides converge to a single root instead of two as upon the buccal surface. The surface is more convex than the buccal, but, like it, is often the seat of a pit near its center, the lingual pit, in which the disto-lingual groove terminates. The depression caused by this groove is often continued rootward, dividing the surface into two lobes, and being continuous with a longitudinal depression upon the lingual root. The distal lobe is rounded in every direction, its distal portion being continuous with the distal face of the crown without demarcation. The mesial lobe resembles this in character except that its anterior margin is more defined. In those teeth with five cusps this lobe presents near the occlusal margin a rounded cingule, whose lingual side is continuous with the lingual face of the crown, but which is separated from the mesio-lingual cusp by a groove, the mesio-lingual groove. This latter often terminates distally by uniting with the disto-lingual groove, but frequently at each extremity it fades away into the surface of the tooth. The cervical line is almost straight, the mesial and distal margins are curved and converge toward the cervix, while the occlusal margin resembles that of the buccal face except that the cusp points are not so sharp and the marginal ridge is more rounded.

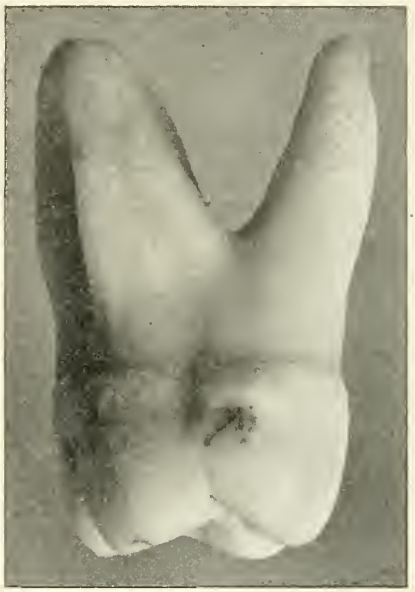

Fig. 56.—Left Upper First Molar. Distal Surface.

The Mesial Surface (Fig. 55).—While this is generally convex bucco-lingually near the occlusal margin, in its gingival two-thirds it is either flat or it may be slightly concave. It is either convex or nearly flat occluso-gingivally, and the most prominent point is

slightly above the occlusal margin where the tooth is in contact with the second bicuspid. The surface is bounded by four margins—the cervical is usually concave in an occlusal direction, while the occlusal is concave in a cervical direction because of the mesial groove which is sometimes continued for a short distance upon this surface. The buccal and lingual margins are convex and converge to the occlusal surface. They are rounded, the former being better defined than the latter. The lingual margin is modified by the presence or absence of the lingual cingule, the location of the notch caused by the mesio-lingual groove varying according to the height of the cingule.



Fig. 57.—Right Upper First Molor. Cross-section below cervix, showing the pulp chamber and entrances to the pulp canals.

The Distal Surface (Fig. 56).—Four sided, this surface resembles the mesial in general outline. It is generally convex, except that often the distal groove is continued and makes a slight longitudinal depression near its center. The occlusal margin is more deeply notched than that of the mesial surface, the cervical line is nearly straight or concave occlusally while the buccal and lingual margins are rounded, the former being less well defined than the latter.

The Roots (Figs. 53 and 54).—These are three in number and are named from their location, the mesio-buccal, disto-buccal and lingual. They are not given off directly from the base of the crown, but the division which results in them occurs usually about one-third the distance from the cervix to the root apices.

The mesio-buccal root (Fig. 55) is flattened antero-posteriorly, and is next to the lingual in size and length. Viewed from its mesial side, it is nearly equal in width to half the crown and its sides slowly converge to near its end when they meet in a blunt, rounded point. From this view the root is inclined buccally, while viewed from the buccal side, it is seen to have a mesial inclination in its first third, curving then in a distal direction to its extremity. It is thin and flat mesio-distally.

The disto-buccal root (Fig. 56) is the smallest. It is narrower bucco-lingually than the mesio-buccal and is short. Its sides gradually incline to a more or less pointed apex, and it is slightly flattened mesio-

distally. In its first third it is inclined distally, but in the remainder of its extent it is usually inclined mesially, approaching the mesio-buccal root.

The lingual root (Fig. 54) is the largest and usually the longest of the three roots. It is somewhat flattened bucco-lingually, and it is either nearly straight or slightly curved, in which latter instance its extremity is inclined buccally. It diverges markedly from the buccal roots in a lingual direction. Viewed from the lingual face the sides of the root are markedly convergent, sloping from the base of the crown to a somewhat rounded apex. This face of the root often presents a longitudinal depression which is continuous with that on the lingual side of the crown.

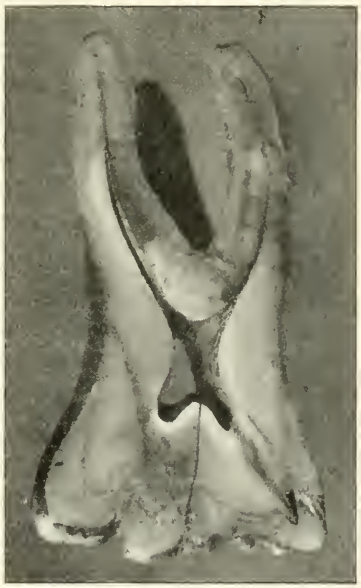

Fig. 58.—Right Upper First Molar. Longitudinal section cut through the pulp canals of the buccal roots, showing the pulp chamber and its horns.

The Pulp Cavity (Fig. 57).—The pulp cavity is easily separable into the pulp chamber and the pulp canals, of which the former is approximately the shape of the exterior of the crown of the tooth, while the latter, which are three in number, correspond to the general external shape of the roots. The pulp chamber is characterized by four horns or depressions in its occlusal wall, one entering each of the four cusps. Its four lateral walls are parallel to the sides of the crown and are generally flat. In bell-shaped teeth they converge from the occlusal wall to the floor (Fig. 58) which is much smaller than the occlusal wall, while in teeth whose crown walls are nearly parallel without constriction at the neck, the lateral pulp chamber walls are similarly disposed.

The horns of the pulp chamber are marked and penetrating and often persist in mature teeth as deep recesses in the dentin. The floor of the pulp chamber presents the three openings for the pulp canals. In the young adult tooth these are in the form of funnel-shaped openings. As age increases, the size of the pulp chamber decreases. The thickening of the lateral walls encroaches upon the pulp chamber, the

funnel-like openings to the canals become simply small apertures and the canals are much reduced in size.

The lingual canal (Fig. 57) is the largest and most accessible. It does not conform to the flattened shape of the root but is usually circular, decreasing gradually in caliber to the apex, and following the curvature of the root already noted. The entrance to it is directly under the middle of a line drawn from the summit of one lingual cusp to the other. The mesio-buccal canal (Fig. 58) is next in size and length. The entrance to it is very near the mesio-buccal angle of the tooth, slightly anterior to the summit of the mesio-buccal cusp. It is flat and ribbon-like and follows the curvature of the root. The disto-buccal canal (Fig. 58) is small and thread-like. Its entrance is approximately under the disto-buccal cusp. It is short and difficult to enter.

THE UPPER SECOND MOLAR.

The crown of this tooth differs from the first molar in any given denture in that it is flattened mesio-distally, with a rounding of the mesio-lingual and disto-buccal angles; its cusps are not so long and their summits are nearer the center of the tooth; it almost never possesses a fifth cusp or cingule, and the disto-lingual cusp is relatively smaller than that of the first molar.

Fig. 59.—Left Upper Second Molar. Occlusal Surface.

The Occlusal Surface (Fig. 59).—When the crown is viewed from the occlusal surface this latter is seen to be rhomboidal in outline but with the angles more rounded than those of the first molar and with the lingual margin almost semicircular. The mesial marginal, the distal marginal, the buccal and the lingual marginal ridges are formed as they are in the first molar. In this tooth they are more rounded. The mesio-buccal cusp has four ridges descending from its summit, one each in a buccal, lingual, mesial and distal direction. It is smaller and less sharp than the corresponding cusp of the first molar. The disto-buccal cusp is usually small and pressed in toward the center of the crown by the rounding of the disto-buccal angle. Its buccal ridge is absent or barely distinguishable. The mesio-lingaul cusp is usually the largest cusp and is well rounded and without a clearly

defined point. It has ridges which pass mesially, distally and buccally, the latter is heavy and strong and assists in forming the oblique ridge. The lingual surface of the cusp is much rounded. The disto-lingual cusp varies much in size and form. It is usually relatively smaller than that of the first molar. Often it is little more than an enlargement of the distal marginal ridge, with which its buccal ridge is continuous. Its distal and lingual faces are much rounded. The central fossa is not so deep as that of the first molar, though similarly its walls are formed by the two buccal cusps and the mesio-lingual together with

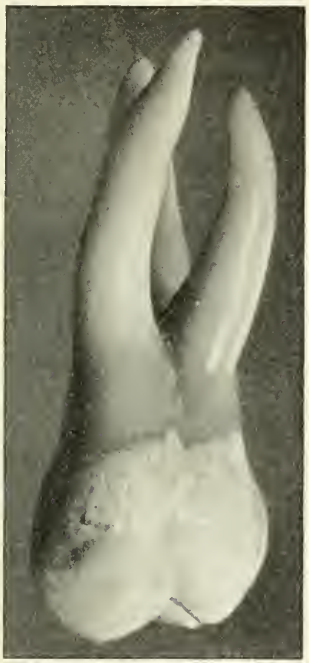

FIG. 60.—Left Upper Second Molar. Buccal Surface.

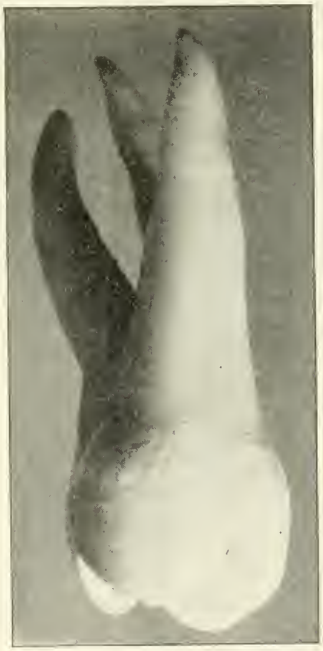

FIG. 61.—Left Upper Second Molar. Lingual Surface.

the mesial marginal and oblique ridges. The mesial groove, the buccal groove and the distal groove all pass from it in these respective directions. It has a pit, the central pit, in its center, and the distal fossa has, similarly, the distal pit. From the latter fossa the distal groove passes to the distal surface and the disto-lingual to the lingual surface, ending on the latter usually in the lingual pit.

The Buccal Surface (Fig. 60).—This resembles that of the first molar so closely that only their points of difference need to be pointed out. The occlusal margin has the same outline as that of the first

FIG. 62.—Left Upper Second Molar. Mesial Surface.

from that of the first molar except that it is much more convex and the fifth cusp is almost never present to modify the form of its mesial portion.

The Mesial Surface (Fig. 62).—This resembles closely the corresponding surface of the upper first molar, but is relatively smaller and is often concave from buccal to lingual side. Its lingual margin is less well defined than its mesial.

The Distal Surface (Fig. 63).—Usually more convex than this surface of the first molar, and relatively shorter occluso-gingivally, the distal surface of this tooth resembles in other respects molar except that the smaller proportionate size of the disto-buccal cusp causes this portion to be slightly altered. The distal margin is more rounded and less pronounced than that of the first molar, but the other two margins are similar. The buccal groove continues upon the buccal face, from the occlusal surface, sometimes to the point of bifurcation of the roots, less rarely ending in a buccal pit. The lobe of the crown mesial to the depression is always larger than the distal lobe. The cervical ridge is not so frequently marked.

The Lingual Surface (Fig. 61).—This differs in no wise

FIG. 63.—Left Upper Second Molar. Distal Surface.

its mesial neighbor. The varying size and portion of the disto-lingual cusp influence the exact form of this face of the crown.

The Roots.—Alike in number and general form to those of the first molar, the roots of the second differ in some respects from them. The mesio-buccal (Fig. 62) is flattened antero-posteriorly, the disto-buccal (Fig. 63) is nearly conical, while the lingual root (Fig. 61) is longest, largest and flattened bucco-lingually but seldom exhibits the depression observed on this root of the first molar. The two buccal roots have a distinct distal inclination and tend to converge at their apices. The disto-buccal root occupies a position relatively more lingual than that of the first molar because of the flattening of the disto-buccal angle of the crown.

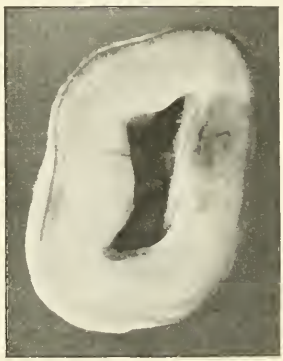

FIG. 64.—Right Upper Second Molar. Cross-section at cervix showing pulp chamber.

FIG. 65.—Right Upper Second Molar. Longitudinal Section cut through mesio-buccal root canal, showing pulp chamber.

The Pulp Cavity.—The differences between the form of this and that of the first molar correspond to the differences in the surface forms of the two teeth.

The pulp chamber is flattened mesio-distally (Fig. 64) and the entrances to the canals are relatively nearer together and that of the disto-buccal canal is more lingually located. The horns of the pulp chamber are four in number but are smaller and less penetrating than those of the first molar. The root canals have the same shape as those of the first molar but are smaller and more difficult to enter (Fig. 65).

THE UPPER THIRD MOLAR.

Greater variation occurs in the form of this tooth than in that of any other in the dental series. In its typical form it has only three

cusps, the disto-lingual cusp having disappeared, while in its most strongly developed form this is present but is much reduced in size by comparison with the other cusps of the tooth. Many atypical teeth are observed in which the cusp development is difficult to classify. A description will be given of the typical tooth.

The Occlusal Surface (Fig. 66).—This is marked by the presence of a mesio-buccal, a dicto-buccal and a mesio-lingual cusp. The disto-lingual is represented only in the distal marginal ridge, or may be entirely absent when the oblique ridge forms the posterior margin of the surface. The buccal cusps are like in form to those of the first and second molars except that they are shorter and smaller. The mesio-

FIG. 66.—Left Upper Third Molar. Occlusal Surface.

FIG. 67.—Left Upper Third Molar. Buccal Surface.

lingual cusp is large and rounded and the central fossa is well defined; usually many small ridges descend from the cusps into it. The mesial marginal ridge is well defined, the buccal depends in character upon the buccal cusps and the lingual is usually poorly discernible. The posterior margin may be either formed by the triangular ridge or the distal marginal ridge may be present.

The Buccal Surface (Fig. 67).—In typical teeth this resembles the buccal face of the second molar but is smaller in extent, more rounded, and its distal lobe is poorly defined.

The Lingual Surface (Fig. 68).—Variations in the form of this surface are caused by the presence or absence of the disto-lingual cusp —when present, this cusp surmounts a lobe of this surface which is partially divided from the mesial lobe by the disto-lingual groove. In this event the mesial lobe resembles that of the second molar but

is even more convex. When the lingual side is surmounted only by one cusp, it is much rounded and convex and joins the mesial and distal faces almost without line of demarcation.

The Mesial Surface (Fig. 69).—This resembles that of the second molar in being flat and sometimes concave from buccal to lingual sides, but it is smaller in extent of surface.

The Distal Surface (Fig. 70).—While it is usually rounded from buccal to lingual side, being always so when the disto-lingual cusp is absent, this surface may also be flat or even concave, when the crown has four cusps. It is always smaller in area than the mesial surface or than the distal surface of the first and second molars.

FIG. 68.—Left Upper Third Molar. Lingual Surface.

FIG. 69.—Left Upper Third Molar. Mesial Surface.

The Roots.—These vary much even in teeth which are typical in regard to thier crowns. There are sometimes three roots, a mesio-buccal, a disto-buccal and a lingual, which are usually short and have a distal and a lingual curvature. These are sometimes fused together throughout most of their length. Occasionally only one root is seen caused by the complete fusion of the roots. Occasionally also four roots may be found (Fig. 71).

The Pulp Cavity.—The external form of the crown largely determines the form of the pulp cavity, so that in trituberculate teeth this cavity is triangular in cross-section while in quadrituberculate teeth, it has the general form of the pulp chamber of the other upper molars. Its lateral walls converge more to the floor of the pulp chamber which is situated at a higher level than that of the pulp chamber of the second molar. The horns of the pulp chamber are less well defined and are

shorter than those of the other upper molars and correspond in number to the number of cusps in any given tooth. The pulp canals usually correspond in number with the number of roots except that in teeth in which the roots have fused into a single one, there may be three or even four root canals, which sometimes have separate apical foramina, or again may unite before this is reached and have a common

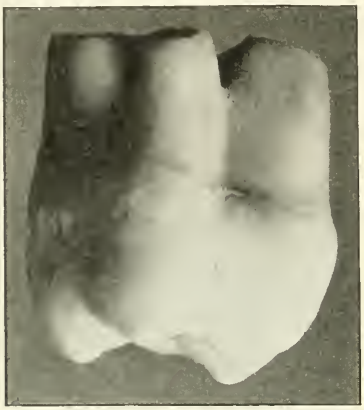

FIG. 70.—Left Upper Third Molar. Distal Surface.

FIG. 71.—Left Upper Third Molar. With roots not completely developed and atypical in having four roots. Showing large patulous openings into root canals.

termination. Occasionally in the single rooted tooth there is only one large canal, the walls of which are continuous with those of the pulp chamber and converge to a small foramen at the root apex. Where more than one canal exists, they are small and thread-like, quite short as the roots are short, and the openings from the pulp chamber into them are very close together.

THE LOWER FIRST MOLAR.

The largest tooth of the human series is the lower first molar, which is longer mesio-distally than the upper first molar, and is of about equal width. The five surfaces of its crown may be described.

The Occlusal Surface (Fig. 72).—This is irregularly trapezoidal in outline, its four margins usually being rounded. The buccal and lingual are more convex than the mesial and distal which may be almost straight. These latter converge toward the lingual side in consequence of which this is shorter than the buccal. Five cusps are usually present, three upon the buccal side and two upon the lingual. A central fossa is formed and occupies nearly the center of the surface and from this radiate grooves separating the cusps. Four ridges

bound the surface. The mesial marginal ridge is the best defined of these. It passes from the mesio-buccal to the mesio-lingual angle of the crown, is concave rootward and is usually crossed near its center by the mesial groove. It is continuous at its buccal and lingual extremities with the marginal ridges of these names. The buccal marginal ridge is poorly defined, is bowed in a buccal direction, and is made up of the ridges descending mesially and distally from the three buccal cusps. The distal marginal ridge is not so prominent as the mesial but is like it in other respects. It is commonly crossed by the distal groove. The lingual marginal ridge is made up of the ridges descending anteriorly and posteriorly from the two lingual cusps. It is cut near its center by the lingual groove and is somewhat sharper than the buccal marginal ridge.

FIG. 72.—Right Lower First Molar. Occlusal Surface.

The mesio-buccal cusp is usually the largest and sometimes the longest cusp of this tooth. It is a rounded elevation with ridges descending mesially, buccally, and distally, and sometimes two or more toward the central fossa from its lingual sides. The names of these ridges correspond to the direction in which they descend from the point of the cusp, except that the lingual ridge is usually spoken of as the triangular. It is the most sharply defined of all.

The buccal cusp is next in size of the buccal series of cusps, being intermediate in size and position between the mesio-buccal and the disto-buccal cusp. It has also four ridges which pass in a buccal, lingual, mesial and distal direction respectively. The lingual ridge descends into the central fossa and is called the triangular ridge. The disto-buccal cusp is separated from the last described cusp by the disto-buccal groove. It varies in size and position. It is more prominent buccally where it is of greatest size, but when found of small size it is located nearer the distal face of the tooth and there is a corresponding increase in the size of the buccal cusp.

The disto-buccal is always the smallest cusp. Three ridges, a mesial, a distal and a triangular, may usually be observed, but its buccal surface is rounded and convex.

The lingual cusps are sharper than the buccal cusps. The mesio-

lingual is sharp and prominent in the unworn tooth and its summit is near the mesio-lingual angle. Its lingual surface is continuous with that of the crown but ridges descend mesially, distally, and buccally. The triangular ridge passes into the central fossa and terminates at the mesial groove opposite the triangluar ridge from the mesio-buccal cusp. These two ridges are separated from the mesial marginal ridge by a shallow depression running bucco-lingually. The disto-lingual cusp is usually smaller than the mesio-lingual,

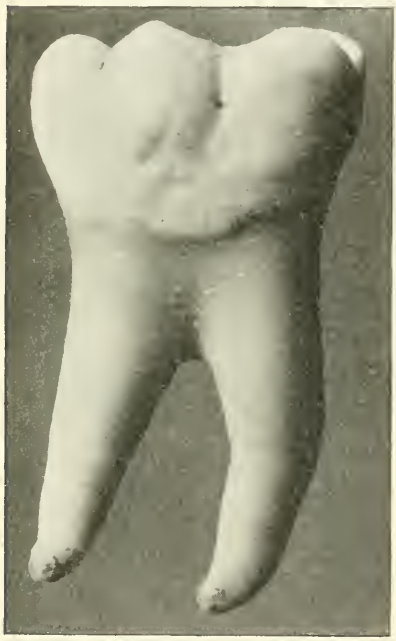

FIG. 73.—Right Lower First Molar. Buccal Surface.

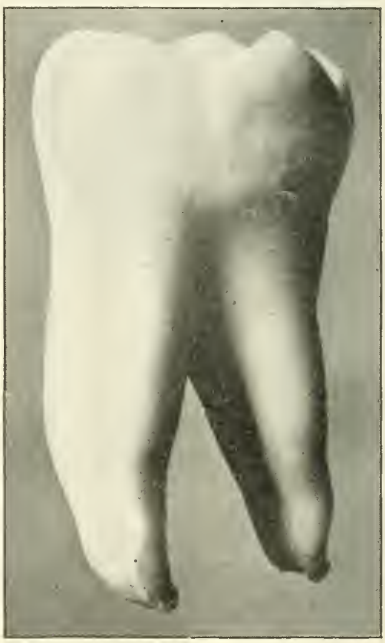

FIG. 74.—Right Lower First Molar. Lingual Surface.

but like it, is pointed and has three ridges descending from its summit, and otherwise resembles it in shape.

The central fossa occupies approximately the center of the occlusal surface, and is broad and shallow. The mesial and distal marginal ridges and the five cusps contribute to form its walls. The mesial groove passes from it to the mesial surface, the buccal groove is well marked, usually the seat of a fissure, and passes buccally between the mesio-buccal and buccal cusps; the disto-buccal groove, also frequently the seat of a fissure, passes between the buccal and disto-buccal cusps; the distal groove crosses the disto-marginal ridge and the lingual groove

passes between the lingual cusps, although in some instances it is very poorly marked. The floor of the central fossa is flat and frequently small tubercles of enamel are found divided from each other by fine grooves. The central pit, a fault in the enamel, is usually found where the buccal and lingual grooves meet and a distal pit often at the occlusal termination of the disto-buccal groove.

The Buccal Surface (Fig. 73).—This is trapezoidal in shape, and is convex mesio-distally and occluso-gingivally. The mesial and distal

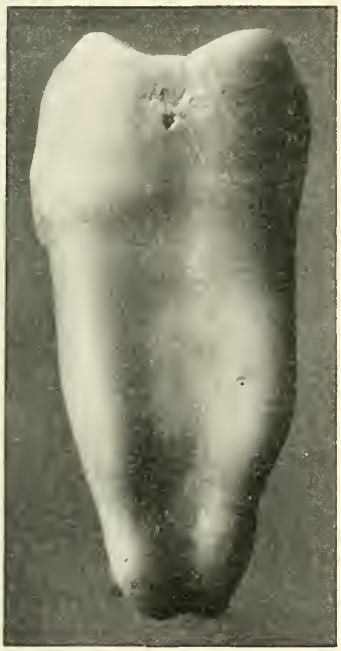

FIG. 75.—Right Lower First Molar. Mesial Surface.

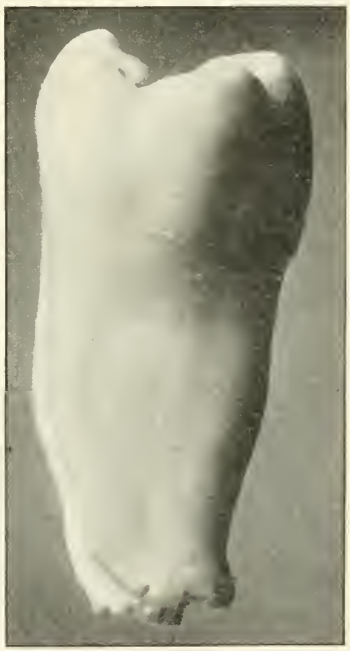

FIG. 76.—Right Lower First Molar. Distal Surface.

margins are much rounded and ill defined, the occlusal margin is marked by three elevations, the cusps, and two grooves, and the cervical is usually convex rootward and marked with a prominent ridge of enamel, the cervical ridge. The buccal groove crosses the surface a little mesial to its center and, decreasing in depth, is continuous with the depression caused by the bifurcation of the roots, or it terminates half way between the occlusal and cervical margin in a well-defined depression, the buccal pit.

The disto-lingual groove is less deep at the occlusal margin and

terminates by disappearing about half way from the cervix. These grooves divide the buccal surface into lobes of which the mesial is most strongly marked, the central and distal being more rounded and usually uniting at the cervical portion, being separated at their occlusal portion by the disto-buccal groove.

The Lingual Surface (Fig. 74).—This is convex in all directions but is less so occluso-gingivally than the buccal because of the sharpness of the lingual cusps. Its mesial and distal margins are much rounded and converge to the cervical which is convex rootward. The occlusal margin is marked by the two cusps and the lingual groove. The latter is often poorly marked although it is occasionally deep, but usually disappears about the center of the surface, and the division of this surface by it into two lobes is not usually distinct.

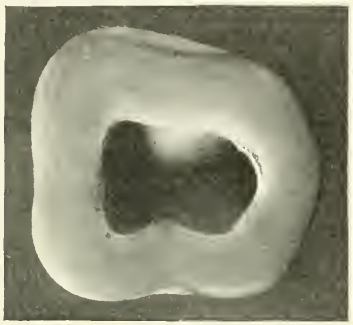

Fig. 77.—Right Lower First Molar. Cross-section at cervix, showing the pulp chamber and entrances to the pulp canals.

The Mesial Surface (Fig. 75).—While it is generally convex and usually so near the occlusal margin where it affords a point of contact with the second bicuspid, this surface is sometimes flat and usually a concavity may be noted near the cervical line. The occlusal margin is notched by the mesial groove between the two mesial cusps, the lateral margins are rounded and convex in an occlusal direction.

The Distal Surface (Fig. 76).—This resembles the mesial face of the crown in outline, but is more convex. Its cervical and lingual margins are like those of the mesial but the varying size and position of the disto-buccal cusp determine the occlusal and buccal margins. The latter is rounded and the former is marked by the distal groove. These unite at the disto-buccal cusp, the position of which determines whether the occlusal margin is long or short.

The Roots.—There are two roots (Fig. 73), named from their positions, mesial and distal. They are both broad and much flattened mesio-distally. The point of bifurcation is about one-fourth the distance from the cervix to the root apices. The mesial root when viewed from the mesial surface (Fig. 75) is seen to be flat, its sides converging but slightly to a blunt apex. On both its mesial and distal surfaces a longitudinal depression running the length of the root may be observed. The mesial and distal sides are nearly parallel until the apex

is reached. The root is curved mesially so that its lower third has a decided distal turn. The distal root is usually straight and is flattened also mesio-distally. It is not marked by longitudinal depressions on its mesial and distal sides, terminates in a sharper apex than the mesial root, and is not so long.

The Pulp Cavity.—The chamber corresponds in general to the shape of the crown, being quadrilateral in horizontal cross-section (Fig. 77). The occlusal wall of the chamber in young teeth has five horns which are in relation with the five cusps, but these are very poorly marked because of the shortness of the cusps. The lateral walls are four in number, the buccal wall being of greatest extent. These converge to the floor (Fig. 77) which is concave bucco-lingually and convex mesio-distally. The buccal and lingual walls meet in a trough-like depression which dips down anteriorly and posteriorly to the entrance into the pulp canals. In any but old teeth the mesial and distal walls (Fig. 78) are continuous with the walls of the pulp canals. The openings to the latter are funnel-like. There are usually two canals in the mesial root which are fine and thread-like and round. They occasionally meet before the apex of the root is reached and terminate in a common foramen although they usually make exit by separate foramina. The distal pulp canal is larger and ovoid in cross-section and easily entered.

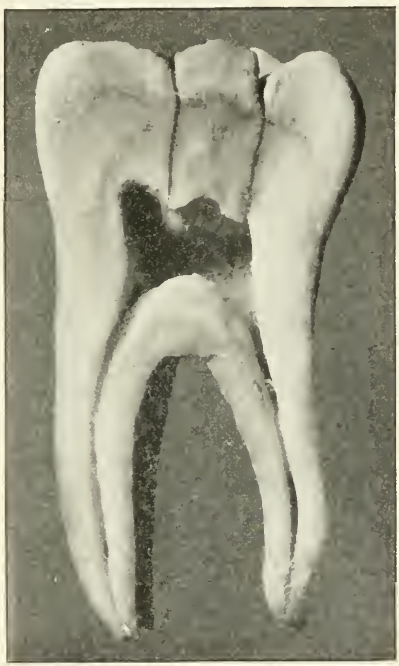

FIG. 78.—Left Lower First Molar. Mesio-distal longitudinal section cut through the buccal cusps and the pulp canals, showing pulp chamber and canals.

THE LOWER SECOND MOLAR.

The crown of the lower second molar differs from that of the first in that it has four cusps of nearly equal size instead of five. In other particulars its surface form is very similar.

The Occlusal Surface (Fig. 79).—The occlusal surface presents

for examination four cusps of nearly equal size, situated near its four angles. The summits of the cusps are nearer the center of the crown than are those of the first molar and are more rounded. The outline of this surface is more rounded than that of the first molar, the mesial and distal margins being of equal length and convex. The buccal and lingual are also usually of equal length but in some instances that of the former is greater. The mesial and distal marginal ridges are similar to those of the first molar, and the surface has a central fossa from which a mesial, distal, buccal, and lingual groove pass to these respective borders. The central fossa is well defined but shallower than that of the first molar. The triangular ridges from the cusps are well marked and between these the grooves meet forming a cruciform sulcus. Occasionally the tooth has five cusps when the anatomy of this surface is similar to that of the first molar.

FIG. 79.—Right Lower Second Molar. Occlusal Surface.

The Buccal Surface (Fig. 80).—This has the same general form of that of the first molar, but is less complicated because of the absence of the fifth cusp. It is more convex than that of the first molar, is relatively smaller in extent and is not so definitely divided into lobes by the buccal groove. This latter usually terminates by blending with the buccal surface about its center and rarely terminates in a buccal pit.

The Lingual Surface (Fig. 81).—Except that it is smaller, this resembles the lingual face of the first molar crown so closely as to require no separate description.

The Mesial Surface (Fig. 82).—This is more convex than that of the first molar but is like it in other respects.

The Distal Surface (Fig. 83).—The absence of the fifth cusp is responsible for the dissimilarity between this and the distal surface of the first molar. It resembles, however, the mesial surface of the second molar, being slightly more rounded.

The Roots.—These are two in number and closely resemble the roots of the first molar. They are not quite so long, do not exhibit the longitudinal depressions seen upon the roots of the first molar,

FIG. 80.—Right Lower Second Molar. Buccal Surface.

FIG. 81.—Right Lower Second Molar. Lingual Surface.

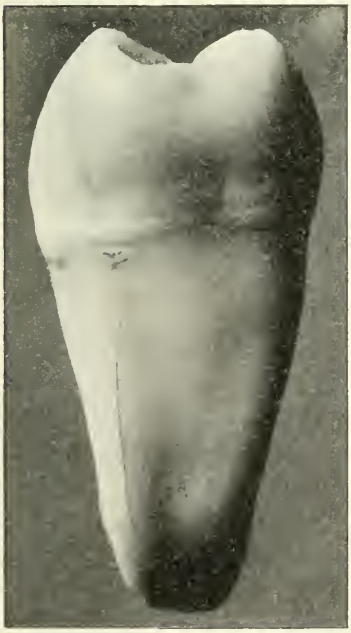

FIG. 82.—Right Lower Second Molar. Mesial Surface.

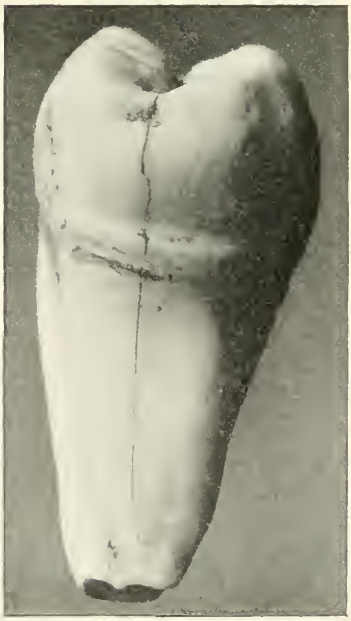

FIG. 83.—Right Lower Second Molar. Distal Surface.

terminate in sharper apices and are usually inclined to the distal at their extremities.

The Pulp Cavity (Fig. 84).—The occlusal wall of the pulp chamber has only four rudimentary horns, the floor of the chamber is smaller and the openings into the pulp canals are closer together but in other particulars this is similar to the chamber of the first molar.

THE LOWER THIRD MOLAR.

No tooth in the human denture is subject to greater variation than the lower third molar. The form most commonly found is that with four cusps, in which instance the crown much resembles the second molar. Rarely it is possessed of five cusps, being somewhat similar to the first molar in form. Often its occlusal surface is much broken up and exhibits a fossa surrounded by a number of cusps and is nearly circular in outline.

FIG. 84.—Left Lower Second Molar. The roots have not been completely developed. Longitudinal section through mesial root showing pulp cavity and method of its division into two pulp canals.

The Surfaces.—When four cusps are present, and this is the commonest form, the occlusal surface resembles that of the second molar except that the cusps are shorter, the fossa is shallower and the outlines of the surface are more rounded. When several cusps exist the grooves separating them radiate from the central fossa. The buccal, lingual, mesial and distal surfaces resemble those of the second molar if the tooth has four cusps, or those of the first if it has five. In other forms of the tooth the tendency to roundness of these surfaces is to be noted and it is usually difficult to perceive any line of demarcation between them.

The Roots.—There are two which usually resemble the other lower molar roots except that they are shorter in proportion to the size of the crown, and generally have a marked distal curve which complicates the extraction of the tooth. Often the roots are fused and sometimes throughout their whole extent, giving thus only one actual root.

The Pulp Cavity.—It can only be said concerning this that the chamber corresponds to the external form of the crown, being similar to this cavity of the first or second molar according as the crown re-

sembles one or the other of these teeth. In other instances it is usually a rounded cavity resembling the external form of the crown. The pulp canals are similar in number to those of the first molar and may be found separated even if the roots of the tooth are fused. In rare instances a single large canal terminating in a single small apex is found.

THE DECIDUOUS TEETH.

The temporary or deciduous teeth serve for purposes of mastication during the earlier years of life and are exfoliated between the fifth and the twelfth years to give way to their permanent successors.

FIG. 85.—The permanent teeth in occlusion. External View. (American Text-book of Prosthetic Dentistry.)

They are less highly developed for functional purposes than the permanent teeth but entirely satisfy the requirements of the food habit of these early years. They are necessarily smaller than the permanent teeth and are but twenty in number.

They resemble in many respects the permanent teeth as regards external form and internal anatomy, but differ in some particulars and these latter must be pointed out. They are in general less well developed as to surface markings. They have relatively longer roots but these are relatively smaller than those of the permanent teeth.

This latter fact accounts for the constricted neck and bell-shaped crown characteristic of the deciduous teeth. The crowns of the teeth are shorter in relation to their width than are those of the permanent teeth.

The Upper Central Incisor (Fig. 88).—In addition to being much smaller than the permanent central incisor, the crown of this tooth is less well marked upon its surface. The labial grooves, the lingual marginal ridge and fossa and the distal angle are especially lacking

FIG. 86.—The Occlusion of the Teeth. Lingual View.
(American Text-book of Prosthetic Dentistry.)

in development. Its surfaces are much rounded and its neck is constricted. The root is relatively longer and smaller than that of the permanent tooth but resembles it in other particulars.

The Upper Lateral Incisor (Fig. 88).—This resembles both the permanent lateral and the deciduous central incisor. It has the characteristics of the former except in a modified degree. Its surface markings are less pronounced than are those of the permanent lateral and it resembles the deciduous central except that its width is less and its distal angle is more rounded. It is a more delicately shaped tooth but is usually equal in the length of its crown to the central and frequently its root is longer. The latter resembles that of the permanent

lateral incisor in other particulars except of course that it is relatively smaller.

The Upper Cuspid (Fig. 88).—The resemblance between this tooth and that of the permanent series is marked, but sufficient differences exist between them to easily differentiate the two teeth.

The crown of this tooth is proportionately shorter and more rounded than that of the permanent cuspid. The labial surface presents a marked labial ridge ascending from the point of the cusp, and the labial grooves are much nearer the angles of the tooth. The angles of the crown are much nearer the cervical line than those of the permanent cuspid in consequence of which the mesial and distal cutting edges are relatively longer and the mesial and distal surfaces are smaller. The lingual surface has a marked lingual ridge and the surface is generally rounded and convex. The root is proportionately smaller than that of the permanent cuspid and the pulp canal is small in consequence, but the pulp chamber, like that of all the deciduous teeth, is relatively large.

FIG. 87.—Occlusal surface of the upper deciduous teeth.

The Upper First Molar.—The molar teeth of the deciduous series are totally unlike their successors, the bicuspids, and partake chiefly of the characteristics of true molar teeth. The crown of the first upper molar usually has three cusps, two on the buccal and one on the lingual side. (Fig. 89.) The surface is almost quadrilateral because the large size of the lingual cusp serves to balance the two buccal on the opposite side. The corners of the figure are much rounded, the sharpest corner being the mesio-buccal while both the lingual corners are much rounded. The buccal cusps are sharper than the lingual which is full and rounded, although all are more pointed than those of the upper permanent molars. A central fossa occupies the space between the cusps. It is broad and shallow. A groove passes from it to the buccal, mesial and distal sides respectively, and these serve to separate the cusps from each other.

The buccal surface resembles that of the upper molars except that the occlusal margin is sharp, the surface is more rounded, the buccal groove is very shallow and poorly defined, and at the cervical margin a ridge of enamel passes from the mesial to the distal border.

The lobe of this surface mesial to the buccal groove is proportionately larger than that of the permanent molar, as it is both wider and larger from occlusal to cervical margin than the distal lobe.

The lingual surface is full and convex in every direction and passes into the mesial and distal faces without demarcation. These latter resemble those of the upper permanent molars, the mesial being flattened with a convexity near the occlusal margin, the distal being rounded.

Three roots are possessed by this tooth. They are mesio-buccal, disto-buccal and lingual. The buccal roots are flattened mesio-distally,

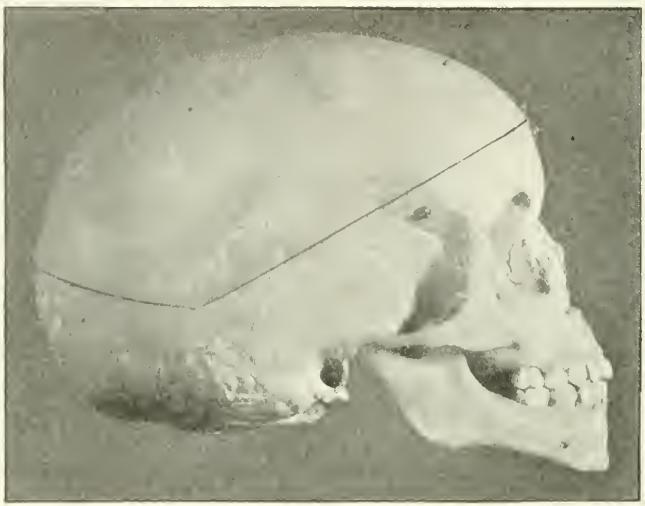

FIG. 88.—Skull showing deciduous teeth in occlusion.

the lingual being flattened bucco-lingually, and they diverge markedly in order to give a space for the permanent tooth which succeeds.

The pulp chamber is rounded and large, corresponding with the general external form of the crown. The root canals are small and thread-like and difficult to enter.

The Upper Second Molar (Fig. 89).—This tooth is larger than the first temporary molar and resembles the first permanent molar so exactly that a separate description is unnecessary. It has not the lingual cingule or fifth cusp, it is smaller, more constricted at the neck and its roots are widely separated at their apices, but in other particulars the description of the permanent tooth will suffice.

The Lower Central Incisor.—Except for the fact that the tooth is smaller, has more rounded angles, and has its labial and lingual grooves

poorly defined, the description of the permanent tooth would equally apply to this. It must be added, however, that its root is relatively smaller than that of its successor.

The Lower Lateral Incisor.—The resemblance between this and the upper deciduous lateral incisor is marked. It is wider than the lower central and its distal angle is rounded like that of the upper lateral. Its various surfaces and its root are like those of its upper opponent and further description is unnecessary.

The Lower Cuspid.—The upper and lower deciduous cuspids are much alike. The latter is narrower mesio-distally and its surfaces

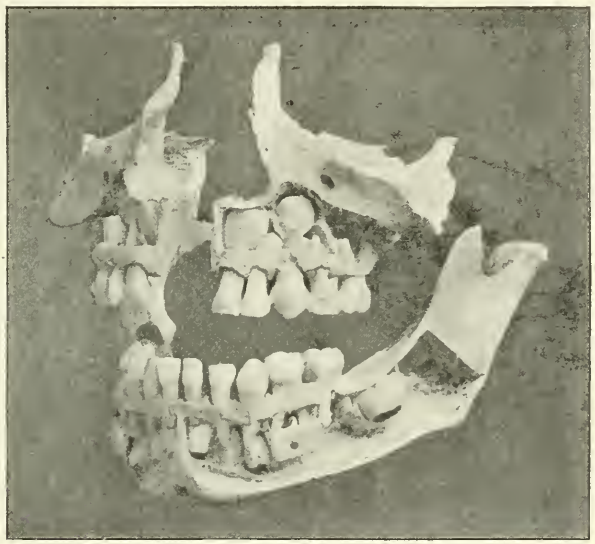

FIG. 89.—Dissected specimen of maxillæ and mandible showing the deciduous teeth.

are not quite so convex but in other particulars its anatomy is identical with that of the former.

The Lower First Molar (Fig. 89).—This tooth has the general molar form but a detailed description is necessary for its identification. Its crown is a much rounded cuboid and exhibits four cusps, one near each of its rounded angles. On the occlusal surface these four cusps are seen to be divided by grooves which unite in the fossæ. The mesio-buccal cusp is the largest. A ridge descending from it anteriorly curves and meets one from the mesio-lingual cusp to form a mesial marginal ridge. Triangular ridges from these two cusps meet at the bottom of a mesial groove, and a small depression is formed between these and the mesial marginal ridge. This is often called

the mesial fossa but is very small as compared to the distal fossa which is located between the two distal cusps and these triangular ridges.

A distal, a buccal and a lingual groove, all poorly defined, emanate from the distal fossa in these several directions. The buccal and lingual grooves are not continuous because the greater size of the mesio-buccal cusp carries the former too far distally. The disto-buccal cusp is small, the mesio-lingual is usually the sharpest and longest, and the disto-lingual is not well defined as the lingual groove is always shallow. The distal marginal ridge is cut by the distal groove.

The buccal surface is convex and has near its cervical margin a pronounced ridge of enamel, the cervical ridge. The mesial margin is longer than the distal in consequence of the greater size and length of the mesial lobe, a condition similar to that of the first upper deciduous molar. The buccal groove is shallow and either terminates in a pit or disappears upon the center of the surface.

The lingual surface is convex, and the lingual groove marks its occlusal portion about the center when it is present but often it is almost indistinguishable on this surface. The mesial and distal surfaces are very similar to those of the second permanent molar. The mesial is flat with a pronounced occlusal edge; the distal is more rounded and the distal groove usually marks decisively its occlusal margin. The tooth has two roots which are similar to those of the first permanent molar except that they are smaller and quite divergent to give space for the bicuspid which follows. The pulp chamber corresponds in shape with the external surface of the crown. The entrances to the three canals are near together, the two mesial ones being small and very difficult to enter, the distal canal being more accessible.

The Lower Second Molar (Fig. 89).—Beside the constriction of its neck, the divergence of its roots, and its smaller size, this tooth resembles the first permanent molar in almost every particular. The description of the latter tooth will apply to the deciduous tooth and the reader is referred to it.

CHAPTER II.

THE HISTOLOGY OF THE HUMAN TEETH.

BY CHARLES R. TURNER, D. D. S., M. D.

A knowledge of the minute anatomy of the tissues of the human teeth is as important as an acquaintance with their surface forms, for it paves the way to an understanding of their several physiological relationships in the tooth, to a knowledge of the pathological conditions arising in them, and to a rational conception of the various operative and therapeutic measures used in the treatment of these conditions.

The tissues of the human tooth are the enamel, which is the hard external covering of the crown; the dentin, which composes the bulk of the tooth and largely determines its form; the cementum, which forms the external covering of the root and to which is attached the pericementum, a membrane intervening between the tooth and its bony socket in the alveolar process; and finally the dental pulp, a mass of soft tissue occupying the internal chamber of the tooth called the pulp-cavity.

A clearer understanding of the relationships of these tissues may be had if we first become acquainted with the method of their development in the embryo. This also confers a better knowledge of their structure.

About the fortieth to the forty-fifth day of intra-uterine life, there is a thickening of the stratum Malpighii of the oral epithelium over the site of the future jaw. This forms a band of epithelial cells extending from one end to the other in each jaw. About the forty-eighth day a budding is seen to take place from the under surface of this *tooth-band*, and ten rounded buds appear attached to it, marking the beginning of the tooth-germs for the deciduous teeth. These buds dip further into the substance of the underlying connective tissue, and becoming invaginated upon their advancing surfaces, finally enclose in this invagination a mass of mesoblastic connective tissue and become the tooth-germ. This epithelial cup which has descended from the mucous membrane remains connected with it for some time by a cord of epithelial cells, *the epithelial cord*, but this cord soon disappears, and the tooth-germ is enclosed by a fibrous membrane developed from the

surrounding tissue. The epithelial cup becomes *the enamel organ* of the future tooth, the connective tissue enclosed by it becomes *the dentin organ or papilla.* The whole tooth-germ enclosed in its sac is known as *the dental follicle.* (Fig 90.)

The enamel organ takes on the form peculiar to the tooth which it is to assist in forming, and its cells begin to alter in character. Those

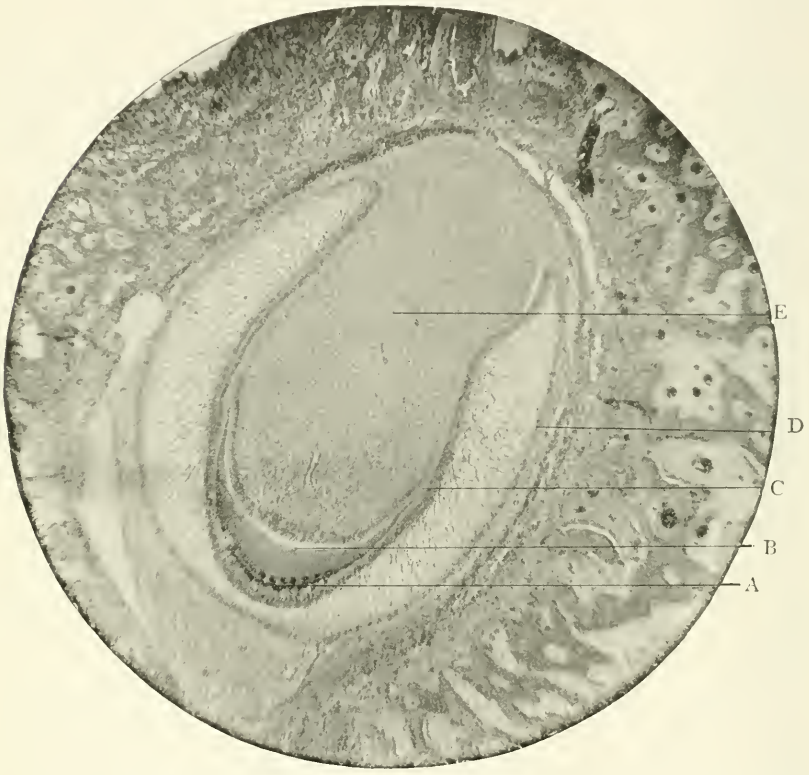

FIG. 90.—Section of upper jaw of human embryo near the seventh month of fetal life, showing development of temporary cuspid. A. Ameloblasts showing beginning of enamel formation. B. Dentin. C. Showing beginning of dentin formation. D. Walls of tooth sac. E. Dentinal papilla. × 50. (Williams. *Dental Cosmos.*)

next to the dentinal papilla become columnar in form, those on the exterior disappear by atrophy, while the intervening ones are changed from polygonal to stellate cells and become *the stellate reticulum.* This latter finally almost entirely disappears, leaving however next to the inner columnar layer a small layer of cells which now comes to be known as *the stratum intermedium.* The inner columnar cells now become enlarged and elongated, their nuclei move to their outer ends

and they become *the ameloblasts*, which are the cells directly concerned with the formation of the enamel.

The dentin organ which occupies the space within the enamel organ, and which is formed from the mesoblastic connective tissue, is composed of embryonal connective tissue cells of various kinds; spindle shaped, round, and stellate cells are scattered through its substance, while over its entire periphery there is a layer of specialized club-shaped cells, *the odontoblasts*, which are specifically concerned in the formation of the dentin.

In the development of the tooth, a deposit of dentin initiates the process, a layer of dentin being calcified about the external surface of the odontoblastic layer of the papilla. The function of the odontoblasts in this process is imperfectly made out. It is known that lime salts are deposited about their external processes and that these become the dentinal fibrils. Furthermore, as said by Broomell, they are believed to superintend the dentin formation, but just what is their relation to the deposition of the lime salts is not known. After the dentin cap is begun it grows by additions to its interior, while upon its periphery enamel formation begins. This is by a process of secretion in which globular masses of calco-globulin are formed in the ameloblastic cells; these escape from the external ends of the ameloblasts and, becoming packed together one after another, form the enamel prisms. An albumen-like substance, according to Williams, is secreted in the stratum intermedium, and flows about the partially formed prisms, "supplying the cement substance and probably the mineral matter for the calcification of the whole."

Cementum is formed upon the completed dentin root of the tooth by specialized odontoblastic cells, *the cementoblasts*, which have developed in the wall of the tooth follicle. Its growth is similar to that of subperiosteal bone.

The pulp is what remains of the dentin papilla, after the latter has been reduced in size by the growth of the dentin walls. The peripheral layer of odontoblasts persists during the life of the pulp, but after the mature tooth is formed, these cells remain inactive unless called into activity by some pathologic stimulation from without.

THE ENAMEL.

The enamel constitutes the external covering of the crowns of the teeth. It is by far the hardest of the animal tissues and for this reason it is particularly suited to resist the wear incident to the use of the teeth in the comminution of food. Its distribution over the crown

of a tooth is not uniform, as it is thinnest at the cervical margin, where it is slightly overlapped by the cementum; from this margin it increases in thickness, until over the cusps and cutting edges of the teeth, where it is most exposed to wear, it is thickest of all. It is also slightly thicker at the site of the elevations and ridges upon the crowns of the teeth. In the newly erupted tooth it is faintly and delicately ridged transversely, and in some teeth it presents other evidences of its development, but it soon wears smooth and lustrous. When a tooth is erupted the enamel is entirely completed over the whole of its crown. No portion of the tooth is erupted until the enamel covering it is fully formed. When once formed enamel is a fully completed substance, and no physiologic change in its structure or composition ever occurs thereafter. Williams remarks, "Enamel is a solid mineral substance, and the finest lenses reveal not the slightest differences between enamel ground moist from a living tooth, and that which has laid in the earth for a hundred centuries."

Defects in the structure of the enamel, in consequence of which the value of its protective office is lessened, are commonly observed at the site of the fissures and pits upon the surface of the tooth-crown which marks the points of union of the several centers from which calcification began. These faults are frequently found in the sulci of the molar and bicuspid teeth, in the buccal pits of the molar teeth, and in the lingual fossæ of the upper lateral incisors. These defects are favorable sites for the beginning of caries, the break in the integrity of the enamel affording lodgment for the bacteria and a favorable starting point for their activity.

While enamel is formed in an organic matrix, not the least trace of this remains chemically in the completed enamel. This accounts for the lack of sensitivity of this structure, for it is not capable of transmitting physiologically any sensations whatever. These facts demonstrate its value as a vital protective covering for the teeth.

Chemically it consists chiefly of the phosphate and carbonate of calcium as the following analysis by von Bibra shows:

	Man.	Woman.
Calcium phosphate and fluorid,	89.82	81.63
Calcium carbonate,	4.37	8.88
Magnesium phosphate,	1.34	3.55
Other salts,	.88	.97
Cartilage,	3.39	5.97
Fat,	.20	a trace
Organic,	3.59	5.97
Inorganic,	96.41	94.03

Charles Tomes has shown that the organic matter obtained in this and the older analyses is simply the water which is combined with the lime salts. He has proven that it will be suddenly given off upon ignition of the specimen under analysis.

Enamel is not a homogeneous mass of calcified tissue but, under the microscope may be seen to consist of a collection of prisms or rods,

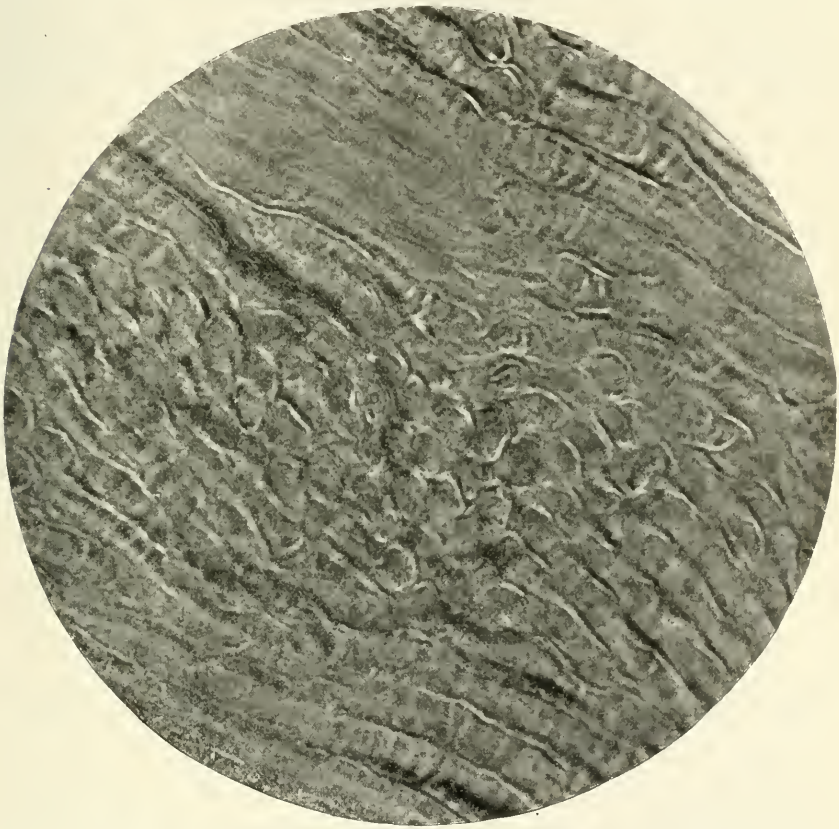

FIG. 91.—Section of enamel of human tooth near line of dentin. Shows enamel rods in cross- and longitudinal section. × 1000. (Williams. *Dental Cosmos.*)

five and six sided, which are united together by means of a cementing substance. (Fig. 91.) As it contains no organic matter whatever and has resulted from the completed calcification of the matrix in which it is formed, we find no chemical remains of the matrix, but the tissue exhibits structural evidences of its mode of formation. Generally speaking the enamel rods are arranged so that they begin at right angles to the surface of the dentin, from which they extend to the external surface of the tooth. In the cervical region they incline somewhat

downward in the direction of the root, but as the lower third of the crown is reached they pass horizontally outward, becoming more inclined occlusally as the cusps and the cutting edges of the teeth are reached, in which positions they are largely parallel to the long axis of the tooth. (Fig. 92.) The ends of the prisms are thus exposed to the wear of these surfaces.

While a majority of the rods extend from dentin to surface, it will be seen that as the surface area of the latter is greater than that of the former, and as the rods are practically of the same diameter at each end,

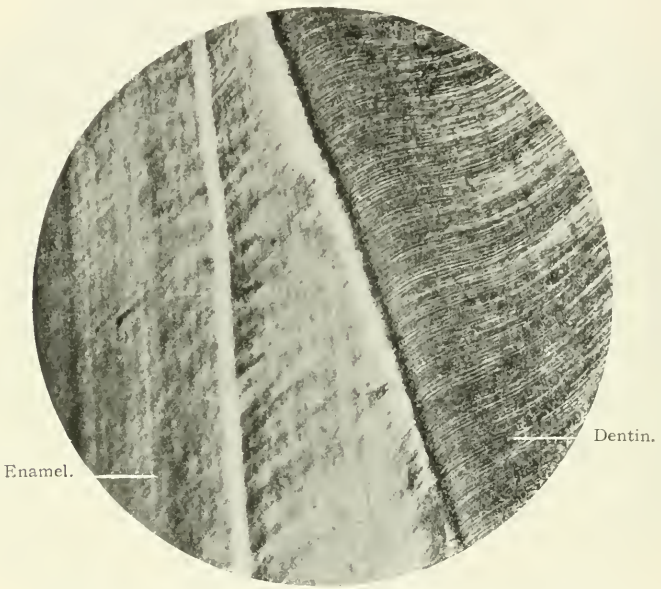

FIG. 92.—Section showing dentino-enamel juncture, the direction of the enamel rods and primary curvatures of dentinal tubules. (Broomell.)

additional rods are required to fill in the interspaces in this fan-like arrangement. These additional rods begin between the other long rods and extend outward toward the surface of the tooth. While the rods pursue in general an almost straight course, in all instances they are slightly curved and in some cases they are much contorted and twisted, and when this is marked the enamel is usually spoken of as "gnarled."

The rods are not of uniform diameter throughout their whole extent, as each rod presents a number of varicosities which increase its size. (Fig. 93.) These varicosities vary in different specimens of enamel but they are present in all. The enlarged portion of one rod is opposite to that of the adjacent rods, and they do not alternate as

would seem the more natural arrangement. The reason for this, is the fact that the globules, of which the rods are made and which are responsible for the varicosities, were deposited simultaneously. The varicosities do not as a rule appear so pronounced in the enamel next the dentin, but elsewhere in any given specimen they are of about uniform occurrence. The space between the rods is filled in with a more transparent but not more highly calcified cement substance. Williams has shown a specimen in which the globules composing the rods do not appear continuous but seem united with this cement substance as the rods are united to each other. It is very probable that this is

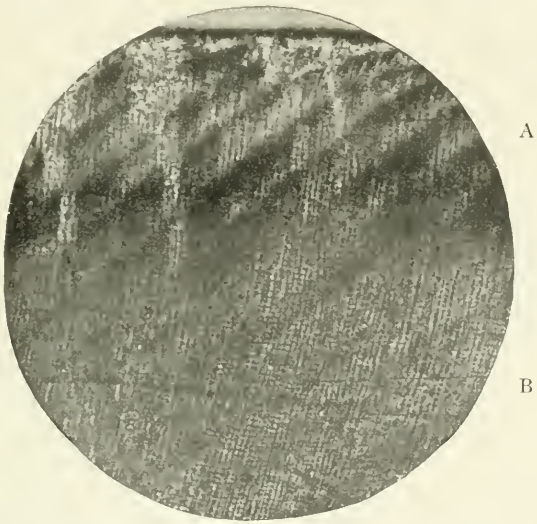

FIG. 93.—Enamel rods showing varicosities and striæ of Retzius. A. Brown striæ of Retzius. B. Enamel rods showing varicosities. × 200. (Williams. *Dental Cosmos.*)

due to the refraction of the light by the rod substance, as longitudinal sections of the rods normally exhibit under the microscope a series of light bands, the so-called "striation" of the rods, which may be brought into view or made to disappear by slightly changing the focus and were formerly believed to have some structural significance.

Another appearance presented by the enamel rods under the microscope is illustrated in Figure 94. In this it will be seen that bands of darker enamel alternate with those of lighter, thus dividing it into strata. This stratification of the enamel is due to the fact that small quantities of pigment have been laid down at various stages in its development, and they simply mark the exterior of the crown at the time they were laid down. They are in reality incremental lines and mark successive stages in the growth of the enamel. They are usually spoken of as the

"brown striæ of Retzius." They begin at the summit of the already formed dentin and extend in curves toward the cervix. The addition of more dentin at the developing end of the tooth gives more surface for enamel to be deposited upon, and another stratum of enamel is formed covering the already formed enamel. The enamel formation at the occlusal end of the crown is completed before that at the cervix.



FIG. 94.—Longitudinal section of human enamel showing globules. Polarized light. × 300. (Williams. *Dental Cosmos.*)

These facts explain why the incremental lines are neither parallel to the external surface nor to that of the dentin.

The "lines of Schreger" are another characteristic of fully formed amel. They are not visible by transmitted light but can be seen by enflected light as Fig. 95 shows. They are said to be edu "to thevarious reections assumed by the contiguous groups of enamel rods." *
dir The physical characters of enamel, which are interesting from

*Broomell: Anatomy and Histology of Mouth and Teeth, 1902, p. 395.

the standpoint of filling operations upon the teeth, are more readily understood when they are viewed in the light of the histology of the tissue. Mature enamel forms a hard covering for the crowns of the teeth which will resist a large amount of force upon it. The enamel rods fit closely together and the intervening tissue is highly calcified and binds them together. Thus they give each other lateral support, and unless there is a break in the enamel surface, it is very difficult to fracture or crush them. In addition, their inner ends rest upon the dentin, a slightly elastic tissue, which gives them a firm support. It is upon these two facts that the ability of the enamel to resist physical force

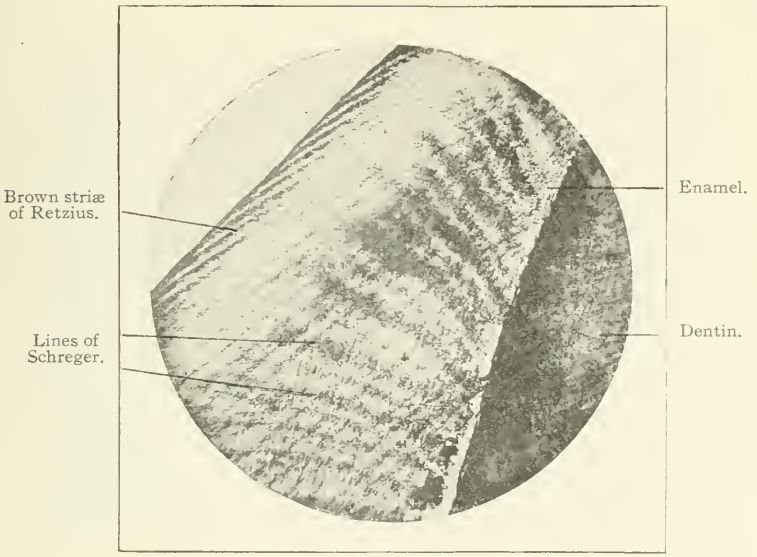

FIG. 95.—Section showing striæ of Retzius or incremental lines of the enamel and the lines of Schreger. (Gysi. Broomell.)

largely rests. If, however, there is a break in the enamel surface, then it is an easy matter to split off the enamel rods immediately adjacent to the break, and especially is this true if the enamel so split is not supported upon mechanically sound dentin. While the enamel is intrinsically of a high degree of hardness, yet it has a natural cleavage, and the line of this is along the interprismatic substance, so that the line of cleavage is approximately parallel to the direction of the prisms. Occasionally it breaks transversely through a prism here and there, but never along the central axis of the prism. The lesson these facts teach in the preparation of cavities for filling operations is that the enamel at their margins must be supported upon dentin, and that these

margins must be formed so that no prisms which do not reach the dentin are allowed to remain. This requires that the cavity margins be beveled at the expense of prisms which are firmly seated upon the dentin, and a knowledge of the direction of the enamel prisms is necessary in preparing the cavity margins.

Black* has shown that enamel possesses less strength than the dentin, as to resistance to both tensile and crushing strains. Therefore the retentive portions of cavities should be made in the dentin, and the mechanical force used in the insertion of gold fillings should be slight upon enamel margins. He has also shown that where several thicknesses of gold were placed between the instrument and the enamel, that the crushing effect of impact is greatly reduced.

THE DENTIN.

The dentin composes the bulk of the tooth, and contributes to its form and strength. It surrounds the pulp and protects this from injury, it gives support to the enamel covering the crown, and upon its root portion is deposited the cementum which affords attachment to the retentive tissues of the tooth. Normally no part of it appears upon the external surface of the tooth, and when here present is exposed from some error in the development of the tooth or from some break in the enamel or cementum. It is light yellow in color, although it varies slightly in shade in different specimens, and it has somewhat the appearance of ivory or bone.

Histologically it is a highly developed connective tissue, and consists of a partly calcified organic matrix traversed by a system of tubules, the contents of which is protoplasmic in character. As it is impossible to remove the contents of the tubules no chemical analysis has been obtained of the matrix proper. Von Bibra gives the following as the constituents of a specimen of thoroughly dried dentin:

Organic matter (tooth cartilage),	27.61
Fat,	0.40
Calcium phosphate and fluorid,	66.72
Calcium carbonate,	3.36
Magnesium phosphate,	1.08
Other salts,	0.83

When the tissue is decalcified by the use of strong acids, the remaining organic matrix yields gelatin on boiling, while that portion immediately surrounding the tubules which differs from the body of the matrix in resisting strong acids and alkalies, yields elastin on boiling

*The *Dental Cosmos*, Vol. xxxvii, page 414.

(Noyes). Opinion differs as to whether this is more highly calcified than the surrounding matrix. Under the microscope it has a different refractive action upon light as the accompanying high-power field shows (Fig. 96). These are known as "*the sheaths of Neumann*," and surround the protoplasmic contents of the tubules.

The matrix itself is practically structureless and homogeneous in character. The tubules traverse it from the pulp-cavity, to the external surface of the dentin. (Fig. 97.) They begin by a funnel-like opening in the pulp-cavity wall, and extend in curves outward to near the surface of the dentin where they usually branch and anastomose freely. They are of practically uniform caliber from beginning to end,

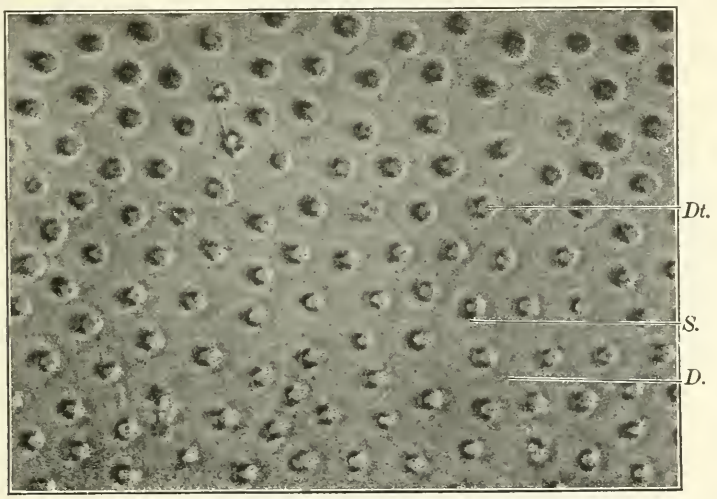

FIG. 96.—Dentin showing tubules in cross-section. Dt. Dentinal tubules. D. Dentin matrix. S. Shadows of sheaths of Neumann. (Noyes. *American Text-book of Operative Dentistry.*)

and as the external surface-area of the dentin is greater than that at the pulp-cavity, the tubules are closer together at their beginning from the latter than at the external surface, and diverge almost imperceptibly in passing outward. They exhibit long graceful curves in their course outward. In the crown of the tooth the tubules exhibit what have been designated their *primary and secondary curvatures*. The tubules begin at right angles to the surface of the pulp, and reach the surface of the enamel at a right angle to it. Between these points they present a reversed curve or ogee. The secondary curvatures are perceptible throughout the extent of the tubule and are due to the fact that the tubule has a general spiral direction through the dentin. In the root

portions of the teeth the tubules pursue almost a straight course from the pulp to cementum, which in general is perpendicular to the long axis of the tooth. In the apical region they are arranged radially. At or near the external end they branch out and anastomose freely. Inasmuch as it is along the line of the tubules that the infection travels in caries, this arrangement explains how caries may progress along the dento-enamel juncture and how the enamel is undermined. This also explains the greater sensitivity of the tooth at the dento-enamel juncture, a clinical fact of common knowledge.

The dentinal tubules contain a protoplasmic mass, the dentinal fibrils, which extend from the odontoblastic layer of cells on the ex-



FIG. 97.—Transverse section through root of human molar showing the curvature of the dentinal tubules about the pulp canal. × 40. (Broomell.)

ternal surface of the pulp. These are usually called *the fibers of Tomes*. Beyond the fact that the fibrils are processes of the odontoblastic cells, nothing yet is definitely known about the manner of their connection with the nerves of the pulp, nor about the way in which sensory impulses are transmitted by them. Unlike the enamel the dentin is a sensitive tissue and has physiologic connection with the organism. The dentinal fibrils conduct sensory impulses and it is believed that in some way the dentin is nourished through the contents of the tubuli. One reason for a belief in the latter is the fact as brought out by Black that the dentin of old teeth has a higher percentage

of lime salts than that of young teeth. The growth of the dentin is not completed with the eruption of the tooth, for all of its root is not formed at this period, but continues for some time afterward. The root is completed and the pulp becomes reduced in size, successive layers of dentin encroaching on the pulp-cavity. In the mature tooth the process of dentin formation remains at a standstill until old age, when it will be found that the pulp-cavities are reduced to very small dimensions.

The odontoblasts may be stimulated into activity by irritation from the encroachments of carious cavities or by a wearing away of the

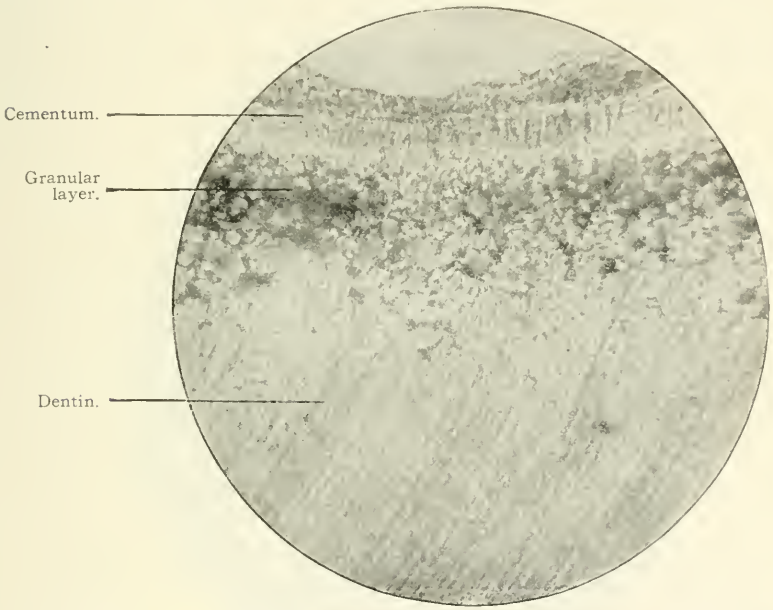

FIG. 98.—Interglobular spaces in the dentin. × 60. (Broomell. *Dental Cosmos.*)

tooth substance from abrasion or erosion. Dentin is deposited on the pulp-cavity wall immediately in relation with the site of the irritation and is an expression of a self-protective activity of the pulp. Dentin thus deposited is known as *secondary dentin.* It is of poorer structure than normal dentin and not typical in the arrangement of its tubules, which present many interruptions.

At the dentino-cemental juncture the dentin presents under the low powers a somewhat granular appearance, and this area is known as *the granular layer of Tomes.* (Fig. 98.) It consists of the so-called *interglobular spaces,* which are erroneously so named as in the fresh

specimen they are not spaces but are areas of imperfectly calcified dentin. They are filled with protoplasmic tissue through which the dentinal fibrils may be made out. In the dried specimen they appear as spaces because of the desiccation and contraction of their protoplasmic contents. These so-called interglobular spaces are often found elsewhere scattered through the dentin, usually occupying positions corresponding to a stage in the development of the dentin.

THE CEMENTUM.

Histologically considered cementum is very closely related to subperiosteal bone both in its structure and development. It forms the external covering of the roots of the teeth, serving as a medium of attachment between the pericementum and the dentin. At the cervical

FIG. 99.—Cementum from cervix of adult tooth. × 40. (Broomell.)

margin, it abuts upon the edge of the enamel or slightly overlaps it, and at this point is thinly distributed over the surface of the root. It increases in thickness as the apex of the root is reached and the mature tooth is of considerable thickness in this region.

While its structure resembles that of bone in many particulars, it differs in having no Haversian system and is easily distinguished from it under the microscope. It presents for examination a *matrix* of partially calcified organic material containing *lacunæ* and *canalic-*

uli. The *matrix or ground-substance* is similar in structure and composition to that of bone. The lacunæ are spaces scattered through the matrix which are occupied in the recent specimen by *the cement corpuscles*, which are cement-forming cells or cementoblasts which have become encapsulated during the calcification of the tissue. The canaliculi extend from the lacunæ and transmit the processes of the cement corpuscles. Beside these elements the tissue contains the *cement fibers* which are calcified fibers of the pericementum. It is developed by the deposit of successive lamellæ upon the dentin surface and these are visible under the microscope as its incremental lines.

FIG. 100.—Cement corpuscles of the outer strata. × 40. (Broomell.)

The character of the tissue varies with its position upon the root and with the period of tooth development at which it is formed.

The matrix next to the dentin is more nearly homogeneous than elsewhere. Under the microscope it appears somewhat granular and is characterized by the absence of lacunæ and canaliculi. (Fig 99.) This is also largely true of the whole thickness of the cementum near the cervical margin as lacunæ are infrequent there. The lamellæ making the successive additions to the tissue increase both in number and thickness as the apex of the tooth is approached, and the lacunæ become more abundant in them.

The cement corpuscles which occupy the lacunæ are masses of protoplasmic tissue which are the remains of cementoblasts. They

are most abundant in the middle layers of the cementum, are absent in the portion next the dentin, and are infrequent in the outermost layers. (Fig. 100.) Their processes are usually directed toward the outer surface of the tooth, and these occupy the canaliculi above referred to.

Another element of the cementum which is the most variable of its histological constituents is the cement fibers. (Fig. 101.) These, according to Black, are principal fibers of the pericementum which have been caught in the developing tissue and calcified. In some rare instances they may be observed to extend from the innermost

FIG. 101.—Cemental fibers of the middle strata. × 60.
(Broomell. *Dental Cosmos.*)

layer uninterruptedly through to the surface, but they are usually of much shorter extent. Sometimes they correspond in length only to the thickness of one lamella and sometimes to that of two or more. This variation is due to the manner of growth of the cementum and to the fact that the attachment of the pericementum is constantly varying, the fibers being frequently cut off and reattached at different positions. Thus the cement fibers which terminate at the surface of a lamella are those whose attachment has been altered at the completion of the lamella. The fibers are of most frequent occurrence in the apical two-thirds of the tissue and in the central strata of this re-

gion. Broomell has called attention to the presence of fibers in bundles in the oldest lamella, the bundles being arranged radially to the long axis of the tooth. The fibers which extend from the dentin do *not* have any direct connection with it, but usually terminate here by breaking up into fibers which run more or less parallel to its outer surface. This is to be expected when the method of cemental developement is remembered.

In some of the multi-rooted teeth the cementum bridges over the gap from one root to the other, building in the space solidly. Usually some evidence in the way of cement cells or mesoblastic tissue remains to show where the extensions from each root have united. In this type of tissue the lamellæ are poorly marked.

The formation of cementum goes on more or less constantly during life, as cementoblasts are constantly present in the pericementum next to the tooth. In youth the cementum is thin as compared to that found in adult life and in old age.

The cementoblasts are sometimes called into activity after the tooth is formed by some pathological excitant, and this condition is known as a *hyper-cementosis* of the tooth. The tissue thus formed may be of such extent as to complicate the extraction of the tooth, or it may press upon the nerves leading to the pulp or to that of some other tooth and cause obscure pains which are difficult to recognize clinically. The pathologic cementum is usually upon the apical portion of the tooth, and is not typical histologically.

Union occasionally occurs between the roots of different teeth by a fusion of the cementum in a manner somewhat similar to that in which the roots of a tooth unite. This gives rise to the so-called fused teeth which are occasionally found.

THE PULP.

The dental pulp consists of the soft tissues occupying the central cavity of the tooth known as the pulp-cavity. It is the somewhat changed remains of the dental papilla, the formative organ of the dentin. It is composed of soft embryonal connective tissue, odontoblastic cells, blood vessels, and nerves. No lymphatics exist in the pulp—a fact of pathologic interest. It has two functions, the formation of the dentin, a function practically quiescent in the adult tooth, and the nutrition and innervation of the dentin.

The odontoblasts, through the medium of which the dentin is formed, are a layer of cells occupying the entire periphery of the pulp and in close relation with the dentin. (Fig. 102.) They exist as a single layer

of cylindrical cells during the formative period of the tooth and until late life, when they become rounded or spheroid. They possess three kinds of processes which are usually referred to as *dentinal, lateral,* and *pulpal.* The dentinal processes, of which there is only one to an odontoblast (occasionally two may be found), are the dentinal fibrils or fibers of Tomes which enter the dentinal tubules; the lateral processes

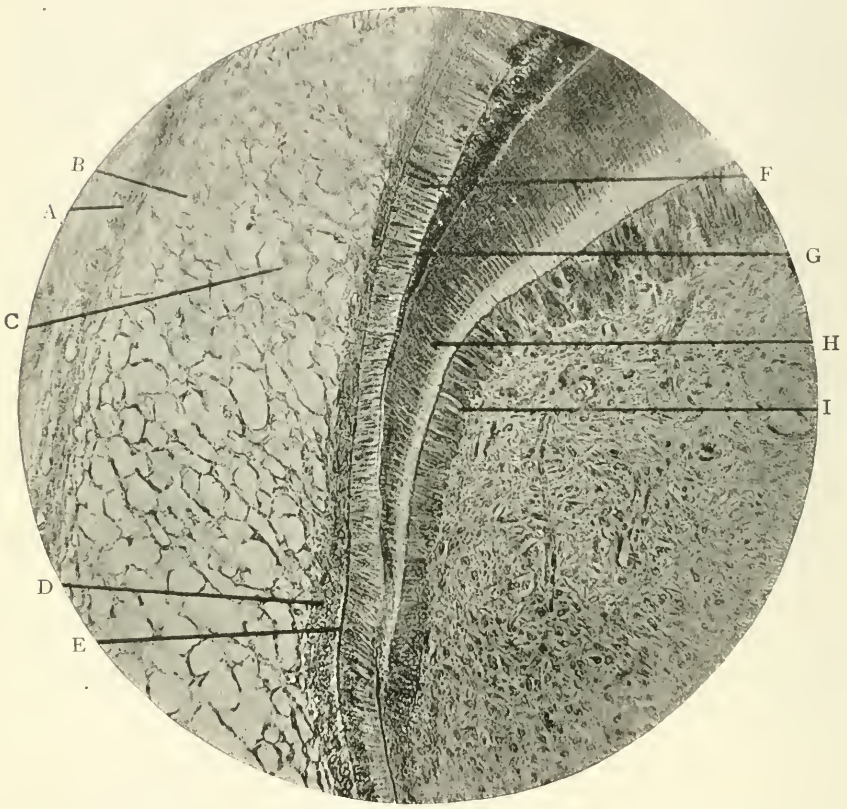

FIG. 102.—Section of developing tooth of human embryo near seventh month o fetal life. F. Ameloblasts. H. Dentin. I. Odontoblasts. B. and C. Cells of reticulum of enamel organ. D. Stratum intermedium. × 175. (Williams. *Dental Cosmos.*)

are numerous and by this means the odontoblasts are connected to each other; the pulpal processes extend into the "layer of Weil", a transparent layer of tissue in relation with the pulpal ends of the odontoblasts, and there become lost to view. The odontoblastic cells have large, oval, deep-staining nuclei situated near the pulpal extremity of the cells. This layer of odontoblasts is often called the *membrana eboris.*

The layer of Weil, situated just below the odontoblasts, is a transparent layer of tissue containing very few connective tissue cells, and then below this comes the main body of the pulp tissue. (Fig. 103.) This is composed of connective tissue cells, which may be either stellate or spindle-shaped, with a large mass of intercellular substance.

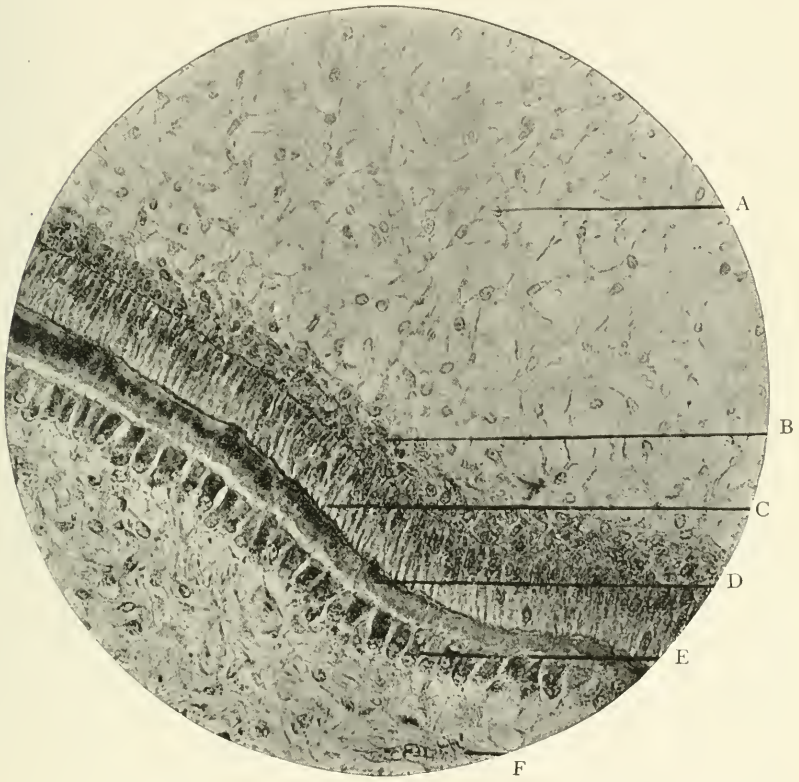

FIG. 103.—Section of developing tooth of embryo calf. A. Stellate reticulum. B. Stratum intermedium. C. Ameloblasts. D. Dentin. E. Odontoblasts. F. Blood vessels with corpuscles in situ. × 275 (Williams. *Dental Cosmos.*)

together with a few round cells which Noyes says "are probably young cells which have not yet acquired the adult form."

The blood vessels of the pulp communicate with the general circulation through the apical foramen or foramina of the tooth. One or more small arterial trunks enter the pulp-cavity at the apex and, coursing occlusally through the center of the tissue, give off many branches. Near the occlusal end of the pulp they further divide into capillaries and form a fine plexus around the peripheral portion of the pulp. The blood vessels are generously distributed through the tissue

The veins form a similar plexus and a contral vein analogous to the artery receives the blood from these many venules and conducts it through the apical foramen.

Especial interest attaches to the thinness of the walls of the pulpal vessels. The arteries are almost entirely without the external fibrous coat and the muscular layer is represented by a single involuntary fiber, while the veins have only a single layer of endothelial cells to form their walls. For this reason the pulp is particularly unable to resist any tendency to hyperemia, and as the tissue is confined in a cavity with unyielding walls, the pulp-cavity, and as the apical exit from it is small and easily blocked, hyperemia of the pulp is attended with a greater amount of pain than in any part of the body, because the nerves are easily stimulated by the pressure of the blood in the pulp-cavity. When inflammation supervenes and inflammatory products are to be removed, the absence of lymphatics further adds to the difficulties of the situation. These facts explain the observed clinical experience associated with pathological conditions of the pulp.

The nerves of the pulp are transmitted through the apical foramina together with the blood vessels. Several bundles of medullated nerve fibers enter the foramen and break up into a plexus of nerves which are widely distributed through the pulp tissue. Just below the layer of Weil, the fibers may be seen to lose their medullary sheath, when they penetrate this and are lost between the odontoblasts. None have been traced into the dentinal tubules. The sensory nerves of the pulp are only capable of transmitting sensations of pain, which may arise from mechanical, thermal, or chemical stimuli. It is not possible to localize these sensations to any particular tooth, so that one is not able to refer them to the tooth in which they arise. Pain originating in one tooth may be referred to any other in either the upper or lower series.

It has been said that the pulp had for its function the nutrition and innervation of the dentin. While dentin is of course a non-vascular tissue, the physical differences in new dentin and that which is found in an old tooth are often so great as to warrant the belief that in some way it may be changed after it has formed. This of course can only be through the medium of the protoplasmic contents of the tubuli, but how this occurs if at all is still only a matter of conjecture.

This is also true of the sensory innervation of the dentin. The dentin is sensitive to stimuli of a chemical, mechanical or electrical nature, and the dentinal fibrils are instrumental in delivering these. No nerve fibers have been traced into the tubules, but nerve endings are closely associated with the odontoblasts. It is believed that the

dentinal processes of these cells in some way transmit the stimuli. Of course with the removal or death of the pulp, all sensitivity of the dentin ceases.

THE PERICEMENTUM.

The fibrous membrane intervening between the root of the tooth and the alveolus is known as the *pericementum* or *peridental membrane*. While not a tissue of the tooth proper, it serves to connect it with the osseous skeleton and performs so many functions associated with the tooth that it deserves especial attention.

It is composed chiefly of white fibrous connective tissue, and besides containing the blood vessels and nerves necessary for its proper functioning, contains a variety of other cellular elements, the functions of which will be discussed later. The chief office performed by the pericementum is the retention and support of the tooth in its socket, in addition to which it has a developmental and nutritive relation to the cementum and the alveolus, and serves as the touch-organ of the tooth. Inasmuch as the fibrous elements of the membrane are in predominance and as they are related to its chief function, they will be described first.

The fibrous tissue of the pericementum is of two kinds—first, the principal fibers, so called by Black because they were greatest in number and most important in function, which extend from the cementum to the alveolar wall or into the gum tissue and are attached to each; and second, the interfibrous tissue, which is the fibrous tissue composed of spindle-shaped and stellate cells which intervenes between the principal fibers themselves and between these and the other pericemental elements. These fibers pass from the tooth to the alveolar wall in all portions of the socket, their ends are firmly built into the cementum at one end, in which they are spoken of as Sharpey's fibers, and into the bone of the alveolar process at the other, and they mechanically support the tooth in its socket. Their arrangement is somewhat different in different parts of the membrane and so it will be necessary to give their direction in its various portions. In the gingival portion of the membrane, where they are thickest, they extend from the cementum in three directions. (Fig. 104.) One set passes occlusally into the gingivus to support this and make it hug the neck of the tooth, and another passes over the alveolar border to blend with the fibers of the muco-periosteum of the alveolar process. These two sets of fibers are in greatest abundance on the lingual side of the teeth, serving to protect this against violence from food in mastication.

The third set of fibers passes almost horizontally outward and they are either attached to the alveolus, or on the proximal sides in young subjects they pass over to the adjoining tooth and become continuous with its pericemental fibers. Of this third set of fibers, some pass radially directly to the alveolar bone, and on the lingual side these are most numerous, while others after leaving the cemental surface pass tangentially in bundles, and are attached to the process at points mesial or distal to where a radial direction would have taken them.

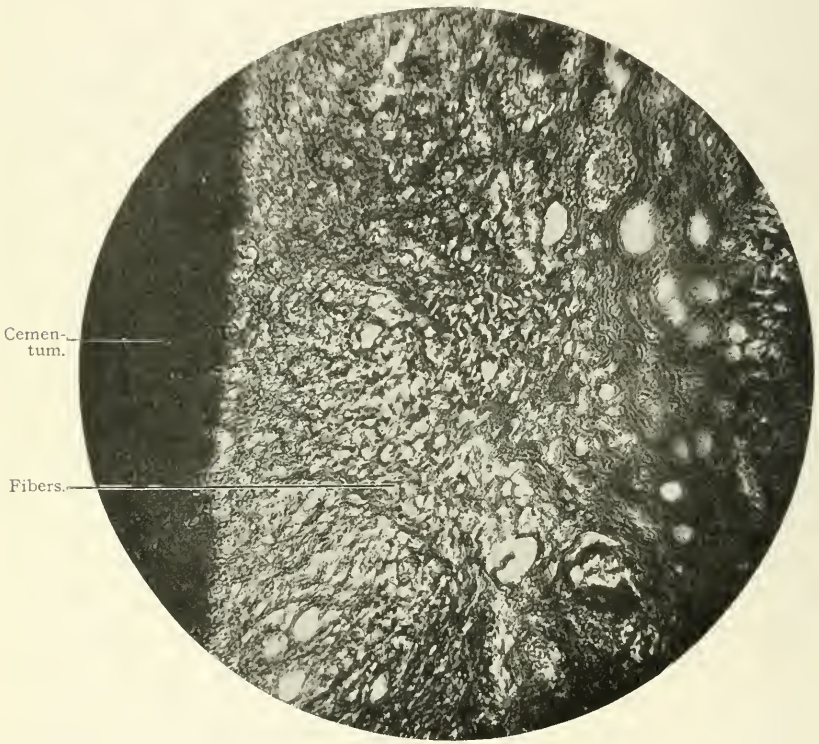

FIG. 104.—Section showing pericemental fibers attached to the cementum. (Broomell.)

These fibers serve to prevent the rotation of the tooth about its long axis, while the radial fibers resist force tending to move it laterally.

In the membrane intervening between the gingivus and the apex of the root, the principal fibers pursue either a straight horizontal course from cementum to bone or they are directed occlusally. The effect of this arrangement is to swing the tooth in its socket, as it were, and it enables the tooth to resist the force of mastication or any other which tends to depress it in its socket. (Fig. 105.)

In the apical region the principal fibers extend radially from the root, spreading out from it in all directions to the alveolar socket.

The interfibrous tissue fills in the spaces between the principal fibers which is not occupied by the blood vessels and nerves and the special cellular elements presently to be described.

This arrangement of the fibers of the pericementum is remarkably adapted to hold the tooth in its socket, to enable it to resist stress placed

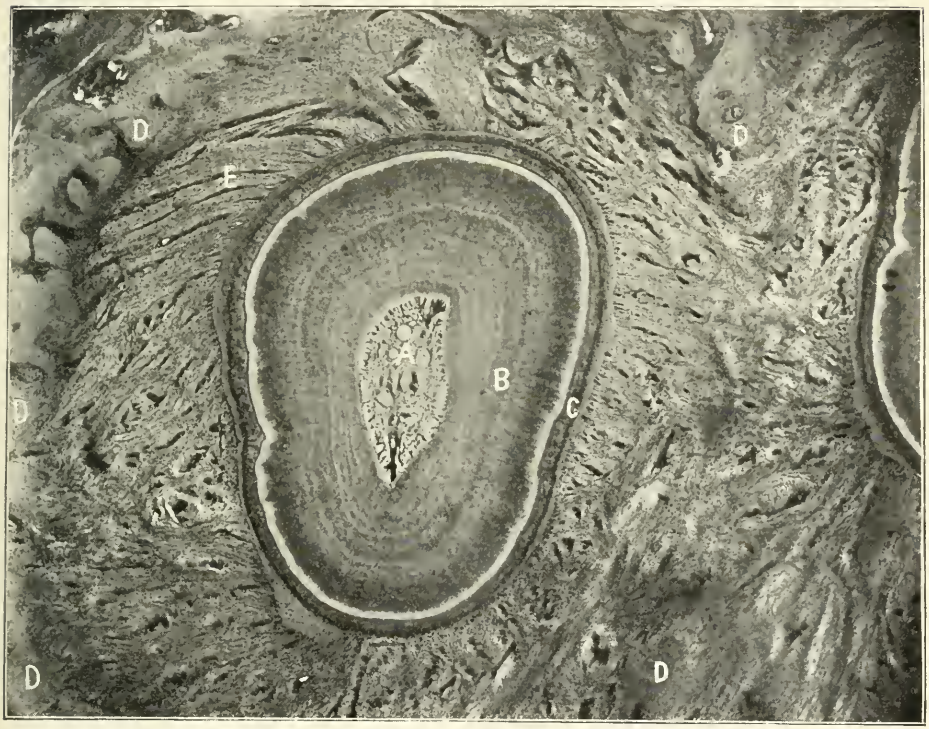

FIG. 105.—Section through alveolus and root of lateral incisor near the gingivus showing direction of fibers of pericementum. A. Pulp with blood vessels and nerves. B. Dentin. C. Cementum. D. Alveolar process. E. Interfibrous portion of pericementum. (Noyes. *Angle's Orthodontia.*)

upon it, and yet to yield slightly to the stress and thus to break the force of the latter. While the fibrous tissue is of the inelastic variety, the fibers are not on tension all the time, and thus permit a certain elasticity to the tooth. This elasticity is contributed to in the young membrane by the blood vessels, which are very numerous, a condition which has a cushioning effect upon the tooth. This elasticity permits the slight movement of teeth when separating them for operative procedures and in the beginning of their orthodontic treatment.

The cellular elements are fibroblasts, cementoblasts, osteoblasts, osteoclasts, and certain epithelial structures.

The *fibroblasts* are long, spindle-shaped cells found in greater numbers in the young membrane and almost absent in that of old age, and are for the repair of the fibrous tissue. They may be observed in the bundles of principal fibers.

The *cementoblasts* which are concerned with the formation of the cementum, are flat, scale-like cells found on the surface of the cementum occupying spaces between the principal fibers. They are irregular in outline as is shown by Fig., a drawing by Black of cementoblasts isolated by teasing. The depressions in their periphery are occupied by fibers. They have oval nuclei and are difficult to find in longitudinal sections.

The *osteoblasts* are situated upon the alveolar wall which they assist in forming. They are spherical cells with round nuclei like odontoblasts elsewhere found in periosteum. They build the bone around the fibers of the pericementum, thus strongly attaching it to the bone, and the calcified fibers are here also known as Sharpey's fibers.

The *osteoclasts* are not constantly present in the pericementum, but are found when absorption of the calcified tissues is in progress. They are often spoken of as "giant cells" because of their size and the great number of their nuclei of which as many as twenty-five are sometimes found. They are capable of acting upon bone, cementum or dentin. Although the exact manner in which they remove the calcified tissue is not known, it is necessary for them to be in contact with it and they are found in the bay-like excavations which they have produced. These excavations are known as "Howship's lacunæ."

The *epithelial structures* of the pericementum were first described by Black, who referred to them as the glands of this tissue. While their glandular character has not been demonstrated, they resemble the glandular tissue in that they are chains of cells epithelial in all characteristics which are distributed throughout the membrane. Occasionally they appear arranged in a tubule having an imperceptible lumen, but no connection with the oral epithelium has been traced. They are fairly uniformly distributed through the membrane according to a diagrammatic plan by Dr. Black.

The *blood vessels* of the pericementum are numerous and are derived from three sources. Two or three branches are given off by the artery of the pulp before it enters the apical foramen. These anastomose with branches of arteries from the alveolar process and with others from the mucous membrane at the gingival margin, forming a

plexus of arteries which bountifully supplies the membrane. These are more numerous in the young specimen and occupy approximately the center of the tissue, but decrease in number and size as life advances and in old age are found in channels upon the alveolar wall.

The *nerves* are derived in a similar manner from those entering the pulp, from the bone itself and from the mucous membrane at the gingivus. They unite and give the tissue an abundant nerve supply. The medullated fibers terminate without special nerve endings. They transmit sensations of pain and ordinary sensation and thus the pericementum is the touch-organ of the tooth.

CHAPTER III.

HYGIENE AND ARRANGEMENT OF LIGHT IN THE OPERATING ROOM.

BY C. N. JOHNSON, M. A., L. D. S., D. D. S.

The hygiene and control of light in an operating room is a very important matter, affecting as it does the health and comfort of the practitioner. In an office where the dentist is confined chiefly to operating, as is the case in so many today, it is essential that some attention be given to the room where the working hours are mainly spent. It is undoubtedly true that many dentists have seriously impaired their health and shortened their years of usefulness by confining themselves in an abnormal environment, and the subject is worthy the careful study of every operator.

The first essential in an operating room is good ventilation and sunlight. The operator should not stand in a draft but he should have plenty of fresh air and not breathe the vitiated atmosphere so frequently found in dental offices. The admission of sunlight is very important if it can be so arranged without taxing the operator's eyes, though this is not always possible with the location of many of our offices. Sunshine is a great purifier and is worthy of more consideration in this respect than it usually receives.

There is a difference of opinion among practitioners as to which is the preferable light for operating, very many urging the advantage of a north light, but this has the limitation of not admitting the sun. It would seem that the best arrangement was to have a corner room for operating with two windows in it one for the operating chair and the other to admit sunlight. A north-west room lets in the sun only in the afternoon and in the summer is very hot, and the same may be said of a south-west exposure. A north-east room is better, having the chair face the north window with the east window at the operator's back. But this room admits very little sunshine in the winter months when it is most needed. What is probably the best arrangement is to have a south-east exposure with the chair facing the east. The sun is usually so high by the time operating begins that it does not interfere with the work, and in summer it is so far north that it

does not shine in the south window sufficiently to cause undue heat. During the winter months it pours into this window, flooding the operating room, coming in at the operator's back, and therefore not injuring his eyes by causing too bright a light to shine in front of him.

This is a very important consideration which many practitioners overlook—the avoidance of too much light for the operator to face. There is a constant tension on the eyes when the individual is looking toward a light, and this is equally true of a reflected light which enters from the rear and is thrown back in the face by a bright wall in front. This makes it very essential that the color of the walls in an operating room should be such as to absorb light and not reflect it. Bright colors are to be avoided in decorating, and this one room of all others should be given over to service rather than to attempt to make it attractive by the use of light shades. Fortunately it may be made comfortable to the eyes without sacrificing artistic beauty if the proper colors are selected. Where paper is used on the walls it should be a solid color without pattern. Green is a suitable shade as also is the deep brown known as chocolate. The latter produces a soft, restful effect in a room, unobtrusive in any way, and unobjectionable from an artistic sense.

The size and location of the window in front of the operating chair are important factors in securing effective light without eye strain. The window should be sufficiently high to carry the light directly down from the sky into the patient's mouth when the head is tipped slightly back, and there should be nothing to interfere with the direct passage of the rays such as trees in front of the window or tall buildings standing too near. A very common error made by practitioners is the admission of too much light in the operating room. The idea seems to prevail that the more light the better, but this is a serious mistake. It is true that a very excellent quality of light is required, and in the immediate vicinity of the patient's mouth the light cannot be too strong short of sunshine. But this is the only vicinity where it is needed and the diffusion of light over a wide area by having a very large window in front of the chair is a severe tax on the eyes which few operators realize. If a window is too large some of the light should be shut off with a shade, and this is particularly true where the window runs down so near the floor as to flood the lower part of the room with light. The operator is looking downward much of the time and this flood of light is reflected in his eyes. In any arrangement of an office whereby an operator must use one window for operating and face another as he stands at his chair he should cut off every

ray of light from the window he faces by a dark shade, and in the same connection he should avoid anything on the wall in front of him which will reflect the light in his face. A bay window while very alluring to some practitioners is extremely bad unless the window looking toward the operator's face is heavily shaded. The only direction from which it is permissible to admit light to the room except that which comes straight to the patient's face is at the operator's back, and as has just been intimated there should be nothing in front of him which would reflect this light back in his eyes.

Many operators go on year after year suffering eye strain and unconscious of the cause of their discomfort through ignorance of the essentials necessary in the arrangement and control of light in the operating room, or through carelessness in carrying them out. When it is considered how important the eyesight of the dentist is it would seem only a reasonable supposition that every operator should give some attention to a matter so vital to his future comfort and usefulness. The essentials are simple and are capable of being carried out in a reasonable degree at least by every practitioner.

CHAPTER IV.

ASEPSIS IN THE OPERATING ROOM.

BY A. E. WEBSTER, M. D., L. D. S., D. D. S.

Under this heading must be considered the possibilities of patients carrying contagious diseases to the dental office, and other patients becoming infected from the germs of disease left in the plush dental chair, the carpets, curtains, and hangings about an operating room. There is also the more frequent and possible means of transmitting disease to be considered, the actual contact from instrumentation.

It may not often occur in an ordinary practice that patients suffering from a contagious disease apply for dental treatment, but it does often happen that patients apply while members of their family are suffering from a contagious disease. Such diseases as measles, diphtheria, whooping cough, scarlet fever, chicken pox and small pox are said to be capable of transmission by clothing. Then there are such diseases as tuberculosis, pneumonia, influenza and some pus infections which may be transmitted by an unkept office equipment. Disease may be transmitted through the water supply, the air supply or noxious gases. Even darkness is conducive to the growth of micro-organisms.

To minimize as far as possible the transmission of contagious diseases in a dental office the operating room should have an abundance of direct sunlight, there should be no draperies or hangings about the room. The walls should be of hard finish and capable of being cleaned. The woodwork of plain finish, no crevices for the collection of dust. Cabinets, brackets and shelves should be plain and of hard finish. Drawers should not be lined with baize or fabric of any kind. The chair, and especially the head rest, should be covered with some material which is capable of being cleaned without destroying it. Plush is decidedly objectionable. The floors should be capable of being cleaned, as is the case with hard wood finish or linoleum put down in a whole piece and cemented at the edges so that water may not get under it. If a rug or cork is used to stand upon at the chair it can be cleaned frequently. Carpet in an operating room is the most unhygienic of all floor dressings.

Typhoid fever and other intestinal infections are most frequently transmitted by the water supply. In some cities and towns the water is never fit to drink while in others it may be drunk if boiled and in others the water may be unfit for use only at certain periods. Water which is unfit to drink is unfit to wash a drinking glass or to rinse the mouth.

The air supplied to an operating room is of some importance, especially to the operator, because he so constantly breathes it. Hot air heating often supplies air which is obtained from a dirty, damp basement or from sewer ventilators. Sewer gas often enters an operating room from poorly trapped or ventilated plumbing. The fountain cuspidor is rarely trapped and is often the source of sewer gas. Coal gas leaking from defective pipes is an insidious kind of poisoning that an operator may not notice for months. The proper ventilation of an operating room deserves some consideration.

The keeping of an operating room aseptic is no small undertaking. In fact it is well nigh impossible and yet it may be kept clean enough so as not to be the means of spreading contagious diseases. Dust is the enemy of cleanliness and health. Every crevice, every crack, every shelf and every loose fabric is an element of danger. The walls, shelves, brackets, cabinet, chair, woodwork, light fixtures, windows, in fact every thing should be thoroughly cleaned once a week, with a brush, soap and water. After this the room may be closed up and formalin gas set free in sufficient quantity to fill it and allowed to remain for some hours. Formaldehyde tablets may be evaporated by heat over a Bunsen burner. Three or four tablets may be placed on a piece of flat metal over the gas flame. The heat necessary to evaporate the tablets is not very great. An equally efficient method is to place a couple of ounces of formaldehyde in a dish over the Bunsen flame which will quickly drive off the formalin gas. Once the gas begins to come off no one should remain in the room because the gas is very irritating to the air passages. The floors, chair, cabinet, bracket and all handles should be carefully cleaned and dusted with a damp cloth every day, and if there is any reason for suspecting that a patient has been in the office who was suffering from a contagious disease there should be general disinfection and ventilation.

Such parts of the furniture and equipment as the operator is likely to handle in his ordinary duties should be wiped off with a cloth made damp by a five per cent solution of phenol or bichloride of mercury one to the thousand. There should be no waste cotton or dressings

permitted to fall upon the floor. There should be a convenient receptacle for such things, that can be emptied frequently and sterilized. There is nothing much more unclean than the ordinary waste cotton holder where the plier points are drawn over the edges to remove the cotton, unless the holder is sterilized after each operation. Soiled towels, napkins and rubber dam should be immediately removed from the operating room.

The dental cabinet should be thoroughly cleaned and wiped out with a damp cloth once a week and disinfected by the evaporation in it of formalin gas. Each tray and shelf containing operating instruments should be cleaned daily. Besides this the tray containing operating instruments should be covered with some material which can be easily removed and sterilized or destroyed. No instruments should be permitted in the cabinet until they are first sterilized. A fairly thick paper is quite suitable to cover the operating tray and may be removed after each patient and a new one placed in position. What are known as hygienic trays which are made of glass or granite are suitable and readily cleaned.

The table on the bracket arm is often made of such materials and of such a form that it cannot be kept clean. A simple plain table of glass without any elaborate frame to hold it is all that is necessary. Once any decoration is attempted there are crevices for dust. With the swinging trays from the cabinet it is not necessary that the table should contain places for the operating instruments, medicine bottles, gold, amalgam and cement. The fact is the aseptic cabinet and bracket table and chair covering are not yet manufactured. They have not been demanded. The bracket table may be covered with a thick paper which can be removed after each operation and destroyed.

The operator should be suitably dressed for the work he has to perform. His coat should be of washable material, close fitting around the neck and sleeves, no buttons or flats to catch in his patient's hair or clothing.

Long hair and whiskers are not conducive to aseptic operations. The operator should aim to prevent his expired air from entering the patient's mouth or nostrils. This may be done by breathing through the mouth and by directing the exhalation either upward or downward by the position of the lower lip. If the lower lip be carried forward and upward the exhalation will be driven upwards while if the lip be held backward and under the upper lip the exhalations will be driven directly downwards.

The operators hands are almost impossible of disinfection; because though the surface may be sterile for a while it soon becomes infected from the natural exudations from the deeper parts of the skin. These exudations may be hindered for a time from pouring out by the application of astringents but the more the hands are used the more active the glands become. Those hands which are covered with a smooth, unabraded skin and have regular well kept finger nails can be made more aseptic than the dry, scaly hands with rough, irregular nails. Rough and violent scrubbing and scraping of the hands is likely to put them in such a condition that even this will not clean them. The nails are difficult to keep in condition unless trimmed short and kept smooth by files and brushes. Sharp instruments should not be passed under the nails to clean them because they scratch the tissue, leaving opportunity for lodgment of infections. Orange wood properly trimmed will serve to clean under the nails without wounding. The dentist should look upon his hands as one of his assets and should avoid everything that might in any way disfigure them or roughen the skin. The hands should be carefully washed in warm water and soap, the nails scrubbed thoroughly and cleaned beneath and again washed in running boiled water. This will suffice for ordinary cases, but if the hands have been exposed to pus infections or the saliva of the patient, or an operation is to be performed which demands the breaking of the mucous membrane or entering the circulation of the patient greater care must be exercised in cleaning the hands. They should be washed as above and then immersed in a one in forty phenol solution for three to five minutes or a two per cent solution of permanganate of potash, or one in a thousand bichloride of mercury. Following this, alcohol may be poured over them. But if absolute certain asepsis is demanded rubber gloves should be worn. The general surgeon of today will not depend upon the disinfection of his hands, but wears gloves. There is no doubt that the dentist's greatest percaution should be to prevent the transmission of infection from one patient to another. While the patient may become infected from his own saliva the dangers are not so great as from infection from without. As the dentist operates for a patient his hands are certain to become infected from contact with the patient's lips, face, mouth or clothing, and should be cleaned and disinfected as parts of the operation are reached which demand aseptic conditions. The operator should avoid touching his clothing, his face, hair, or the furniture while treating roots of teeth or doing operations which may bring his instruments in contact with abraded surfaces. Before

cotton is wound on a broach for treating root canals the finger should be immersed in a bichloride solution or a formaldehyde solution.

The field of operation should be as carefully prepared for operation as the hands or instruments. Patients often visit the dentist whose mouths are not even freed from particles of food from the last meal or two. It is well to have such patients rinse their mouths as thoroughly as they can with a two per cent solution of permanganate of potash before even a thorough examination is undertaken. A blast of air from a compressed air tank or a spray of one of the essential oils will clear an area for inspection. Not having these appliances a stream of tepid water forced between the teeth will clear out an interproximal space. Large cavities containing decomposed food and decalcified dentin should be opened and washed out with abundance of water. If the cavity is to be filled at once or the pulp involved the teeth in its vicinity should be dried and wiped with alcohol. And if the rubber be in position all of the exposed teeth should be thoroughly sopped with a strong disinfectant. Root canals should never be opened without thoroughly cleansing the cavity itself and the teeth about.

The sterilization of instruments is perhaps more important than the sterilization of the hands or the field of operation because they more frequently come into contact with the secretions of the body. This is especially true of extracting forceps, lancets, clamps, separators, matrices, files, trimmers, scalers, broaches, explorers and hypodermic needles. Instruments should be selected with a view to their easy sterilization. Cone socket instruments and deeply knurled or wooden handles are not so easily sterilized as all steel and fairly smooth instruments. The dental hand-piece is difficult to sterilize without danger of rust or corrosion.

There are two general methods of sterilization in common use, (1) by heat and, (2) by drugs.

As a rule heat is more certain but even boiling for ten or fifteen minutes will not destroy the spores of some organisms. Sterilizers are most satisfactory which will permit of the water being drained off allowing the instruments to dry from their own heat.

Sterilization by drugs is not always satisfactory because efficient drugs have to be used in such strength that unless the instruments are wiped dry before using there is a possibility of injuring the patient's mucous membranes. The odor and the time required for some drugs to act are serious objections. A 3 to 5 per cent solution of formaldehyde will sterilize instruments in a shorter time than any other drug or combination of drugs which are at all suitable for the purpose.

Formaldehyde solutions will rust instruments rapidly but if borax be added rust does not occur. No dependence should be put in proprietary disinfectants for either the mouth or instruments. Sufficient tests of the efficiency of these nostrums have been made to prove their uselessness.

All the instruments used in an operation should be removed from the bracket table and washed in water and sterilized and then placed in their respective places in the cabinet. Such instruments as burs and serrated surfaces should be cleaned with a brush before being sterilized. The revolving brush wheel on the engine for cleaning burs is objectionable and should go with the cotton holder unless cleaned after each time it is used. After broaches are sterilized they should be kept in a closed drawer which is frequently sterilized with formalin vapor or in alcohol.

The hypodermic needle may be pressed into a cork which tightly fits the bottom of a glass barrel about an inch in diameter and three or four inches in depth. The cork may be saturated with any sterilizing fluid which will not rust the needle. Such a needle is always ready for use. If the barrel be deep enough the whole syringe may be kept within it and covered with another cork. The nozzle of the water syringe should be kept in the formaldehyde solution when not in use. The nozzles of the spray bottles should be similarly sterilized.

The sterilization of materials used by the dentist deserves some attention. Gold, amalgam, cement, and gutta-percha for fillings need little attention except where they are brought into contact with vital tissues. Gutta-percha is frequently brought into such contact but it is sterilized by heating before being used. The phosphoric acid and chloride of zinc prevent the carrying of infection by the ordinary cements. Gutta-percha points used to fill root canals are often inserted directly from an unclean drawer or box. They should be kept in alcohol in a wide mouth bottle well stopped. Cotton used for wipes should be sterilized by heat and kept covered as much of the time as possible.

There are many minor operations performed by the dentist which are cared for in rather a slipshod method. Roots of teeth are extracted about which purulent infections existed and no attempt made to wash out the cavity with any regard for asepsis. The water used and its containing vessel should be boiled, the syringe and the packing should be sterile. Every office should be equiped with sealed glass jars containing strips of boracic and plain gauze of different widths wound on a spool. Cotton wipes may be kept in a similar jar. The

jar and its contents may be sterilized in an oven or boiling water. The ordinary fruit sealer is an excellent jar for this purpose. With such an equipment the dental surgeon is always prepared for the management of the many surgical operations he is called upon to perform.

CHAPTER V.

HYGIENE OF THE MOUTH.

BY GEORGE H. WRIGHT, D. M. D.

ORAL HYGIENE OF THE INFANT.

The highest physical development of the child is largely dependent upon its environment and its food. These two factors may be influenced by the parent and oral hygienist.

In order to have a clear understanding of the conditions necessary for a sound oral hygiene we must recognize what physiological processes are concerned in the development of the oral cavity, the eruption of the teeth, and the possible changes which may follow any interference with its normal process and which may result in a distinct pathological manifestation. Heretofore, in dealing with the problem of oral hygiene, we have considered simply the adult, now we propose to take a view of the child at the beginning.

Why do teeth erupt? In our endeavor to answer this question we shall lay especial emphasis upon certain factors, as pulsation of force, constantly applied, that impels and moves the tooth onward out of its crypt and through the gum tissue. Any interference in this process induced by unnatural external causes, may so modify the direction of the eruption of these teeth as to cause not only reflex disturbances of digestion, with many other manifestations of pathological diseases, but may also modify the superstructure of the superior maxilla and cause decided malformations in all the facial bones, including the floor of the nasal fossa, the nasal septum, the antra, and may induce abnormal growths, thickenings of mucous membrane, such as adenoids and other obstructions that disturb normal functioning.

Frequently the physician called in to attend a child who is disturbed in the process of teething, so called, will indiscriminately lance the gum, a fibrous tissue immediately over the erupting crown, and in that manner seek to give the child relief. He may succeed temporarily, because the arterial tension below the erupting tooth is relieved. The cusps of the tooth emerge through the wound and there is liberated into the oral cavity, a mass of liquefied alveolar bone and degenerate connective tissue which normally is absorbed by the lymphatics. Only the crown of the tooth is formed at this time and is loosely held

within its alveolar crypt. The lancing relieves the tension which later subsides, and often the tooth returns to its former position below the gum; the cicatrix heals rapidly and histologically will exhibit a denser fibrous mass, considerably matted, and very resistant, and very difficult for the erupting tooth to cut through. At birth the crowns of all the temporary teeth are formed and any change in environment of a tooth may have an important influence upon the future lines of growth of the jaws and adjacent structures, for, coincident with the eruption, we have the development of the inferior meatus of the nose; at birth it is relatively unformed. The maxillary sinuses, sphenoidal and frontal, are post-natal developments. At birth the developing crowns of the permanent teeth occupy the position of the maxillary sinuses. The immediate result of this retarded eruption may be reflected in a decided deflection of the lines of growth, not only of the alveolar periosteum, but also of the adjacent bones. In the region of the intermaxillary bones, where the central incisors have been held for an abnormal length of time, the rest of the structure immediately above will suffer a corresponding retarded elongation. This may be observed in a later bending, or buckling, of the nasal septum, thereby closing on one side the nasal fossa, and on the other exhibiting a very wide opening.

These deformities have their origin, during the period of and particularly after the eruption of the first teeth; later the arch of the teeth, or substructure of the superior maxilla, loses some of its units of strength in supporting this structure, because the points of contact of the temporary teeth are unequal. Undue pressure is brought to bear at isolated points in closing the mouth, with the reflex result that there will be distortion in the structure above. The permanent teeth which are developing immediately following the temporary teeth, continue this tendency to deformity, and the process may go on up to twelve years of age. In the meantime some enthusiast for early extraction may further complicate this deformity by the removal of some of these teeth mal-placed, and at this point we find one of our greatest complications as it leads to an abnormal, unhygienic condition of the mouth. Triangular spaces are formed into which are lodged accumulations of detritus difficult to remove, and in consequence there follows in its train most of the destruction of the teeth through caries, impaired digestion and imperfect respiration.

We know that the crown of enamel with its interlining of dentin is formed first, and subsequently the dentin thickens and elongates; then it becomes covered with cementum and ultimately the root or

fang is developed with its covering of peridental membrane. But this completed growth is not a necessity for the eruption of the tooth, because we find upon dissection of the jaws, from six months up to six years, that the teeth erupt frequently without a vestige of a root, and, consequently, the disturbances within the oral cavity, and reflected in impaired digestion of the child—to be described in detail later—are not "due to the elongation of the root and consequent pressure upon the developing jaw," but to some other cause.

This is fundamentally a problem for the specialist in oral hygiene, inasmuch as the mother of the child will frequently inquire of her dentist, how soon she must "begin the care of baby's mouth." Frequently a child from four to six years will either through an accident lose the central temporary incisors, or loosen them by the habit of prying a pencil between the teeth; soon they are removed by the child, parent or dentist. At this period in the development of the permanent central incisors (immediately following the temporary incisors) we find only the broad crown of enamel and no roots, and the crown situated high in the intermaxillary process. The too early loss of these temporary teeth from whatever cause may induce a thickening in the floor of the nasal fossa and malformation of adjacent structures; because the permanent central incisors are held by a new deposition of alveolar bone and a denser fibrous mass of gum tissue. Concurrent with the continued deposition of dentine and cementum at the apex of the tooth, the erupting force is reduced, because the apical region becomes more constricted, thereby reducing what is normally a wide area of vascular pulsating tissue which was the impelling force necessary for the eruption. These malformations become important factors in producing the subsequent pathological conditions within the mouth.

The erupting tooth of a child slowly develops to the surface after absorption of the alveolar periosteal crypt, immediately above and ultimately cuts its way through a fibrous mass of gum tissue. It is hastily assumed that all possible disturbance with that particular tooth has ended, but a few hours later, or the next day, the tooth may disappear below the gum into its crypt, leaving a small orifice capable of lodging decomposing food and myriads of bacteria.

The fluctuating of the teeth in their coming and going shortly after their first appearance, is undoubtedly due to the change in arterial tension which is manifested through the large vascular pulp of each tooth. It is possible to record the pulsations of the heart, and count its beat through the freshly erupted tooth. The writer has made observations during the past few years and watched this phenomenon.

Under normal conditions, the process of eruption is a natural and orderly physiological procedure on the part of nature. It is not our intention, nor within our province at this time, to go into details concerning the periods at which the groups of teeth erupt; that has been dealt with in another chapter. We shall consider, however, those aspects which either directly or indirectly induce disturbances within the oral cavity, and which we are called upon to treat in order to establish a sound hygiene in the mouth.

The mother invariably consults with her dentist upon the first occasion, after giving birth to her child. There have been excessive changes of metabolism, which have occurred during the period of gestation, and this is reflected quite markedly in the secretions, and particularly in the saliva and oral secretions, which becomes more acid, and in consequence exerts a deleterious influence on the teeth and adjoining tissues. If the patient has been carefully instructed during the period of gestation as to the proper hygiene for the mouth, the evil effects upon the teeth, as a result of the changed metabolism, need not be fraught with so many evil results, as when entirely neglected and the debris naturally formed within the mouth is allowed to accumulate.

Immediately preceding or at the time of the eruption of the teeth, there may be pathological complications within adjacent structures, as in the eye, ear, nose and throat. With this enormous structural upbuilding where nature is elaborating the materials for forty-eight teeth, and the jaws, there is much waste tissue to be disposed of. In close proximity to the erupting second lower molar there is a thick plate of alveolar bone. That bone and fibrous gum tissue in contact must be melted and absorbed before the tooth comes through. Sometimes there will be a swelling in the region of the submaxillary gland and lymphoid enlargements; intense pain, excessive salivation, followed by a hot and feverish condition of the oral mucous membrane. The disturbance may continue until we find an acute otitis media with a sinus and profuse suppurative discharge through the external ear. Usually within a few hours or two days at least, the offending molar will make its appearance through the gum, and disturbance will cease. So, too, in the region of the upper first and second temporary molars, we may find lymphatic enlargements involving the parotid, lachrymal gland and tonsil, with sinus and discharge through the lachrymal duct. The faucial tonsil and normal adenoid upon the side nearest to the erupting tooth may become considerably enlarged through the influence of the lymphatically absorbed waste tissue. Nature has undoubtedly developed and placed these lymphoid organs for a

useful purpose during this structural upbuilding. Wanton destruction or removal without adequate cause is to be deplored.

If our observations regarding the arterial tension preceding and after the eruption of the tooth are correct, it is safe to assume that blood pressure has been a potent factor in the primary process of eruption, long before it has reached the surface through absorption of the walls of its bony crypt. If, during this early process before the appearance of the tooth, or the congestion of the fibrous gum, there should be from any cause whatever an undue arterial tension, then some of the disturbances noted in the young child may be accounted for, although there may be no external evidence of the teeth.

There may be a feverish restlessness, periods of excessive salivation, desire of the child to bite its fingers, and rub its eyes and nose. There may be bright red areas in the region of the parotid and sublingual glands externally; possible rise in temperature with fretfulness and nervous irritability, and reflex disturbances of digestion with frequent ejections of its food. The mucous membrane of the mouth, under these circumstances, may exhibit a hot and dry surface that lasts for a few hours to be followed by salivation.

The etiology of these disturbances in the majority of cases may be referred to improper feeding, as indifferent formula for artificial foods, too much food, uncleanliness, or indiscriminate feeding.

The child taking its nourishment at the breast obeys a natural instinct, and the mother's milk during the first months of feeding increases in quantity with the larger demands of the child, and analysis shows a decline in the nutritive proteids toward the end of the period of lactation. The child thrives best at the breast when the conditions are normal. When otherwise, then artificial feeding by formula is resorted to, but instead of a decrease in the quantity and proteid constituents of the food as observed in nature's method, we find the exact reverse, and the child suffers often in consequence of haphazard artificial feeding; where the food values are progressively increased, while the naturally fed child is getting but a simple diet and that sparingly. It is not a question as to how much food the child shall take, but how little it should take in order to preserve the balance of perfect assimilation and growth.

The salivary glands of the child are functionally active from four to six months and it is claimed that even in the youngest infant the chemical constituents of the saliva are capable of rendering soluble starchy foods; and some children have been known to digest and assimilate starch during the earliest months, yet upon general principles it is

considered very unwise to introduce starchy food of any kind, because of the mechanical irritation and frequent inability to digest and assimilate them.

The one great remedy for reflex disturbances of digestion, as a result of undue tension within the highly vascular tooth pulp, will be found in reduced and careful feeding, and the establishment of normal hygienic conditions. It may be necessary to starve the child for twenty-four hours before beginning where nature serves at the breast, in order to build up again.

In describing the pathological aspect of the oral tissues in the child, the writer in the following has drawn largely from the admirable description found in Barrett's Pathology, Holt's Infancy and Childhood, and Forchheimer.

Stomatitis, in relation to disturbances or inflammation of the mucous membrane of the mouth and adjacent tissues, is in this sense restricted in its application; although the term is a broad one and could be applied to many diverse conditions. Stomatitis is common in infants, and is usually the handmaid of bad hygiene or unsanitary surroundings.

This inflammation of the mucous membrane is frequently found where the child is artificially fed, instead of nursing at the breast. Either the proportion or formula for food is wrong, or there is not sufficient cleanliness and care in scalding the bottles and nipples, which will inhibit the growth of fermentative bacteria. The quality of the rubber in the nipple undergoes change, and under the influence of light and heat decomposes and becomes an active source of irritation to the tissues, which become poisoned. And even though these conditions do not exist as to improper feeding or unclean bottles, it is possible to develop a stomatitis on account of the accumulation of debris from remnants of food lodged within the orifices of erupting teeth, broken down epithelial cells, and combined products of inflammation, which should be daily removed irrespective of the age of the child. Sometimes the most careful and conscientious nurse or mother will neglect this duty.

A simple follicular stomatitis is an inflammation of the mouths of the mucous follicles. Small areas of the surface may be involved, and possibly induce degenerative changes as deep as the mucosa. The membrane will be flecked over with red points. As the inflammation spreads, more follicles become involved until the red points and patches merge, and the entire surface becomes turgid and tumid. As we look into the mouth, the tissues are hot, and dry, and red. There is considerable sensitiveness, and the child will shrink when examination

is attempted. In the early stages, there will be excessive flowing of watery saliva due to the congestion of the blood vessels surrounding the glands, some febrile disturbance, bowels irregular, and either constipation or diarrhea predominating. Close examination reveals swelling of the muciparous follicles and possibly tiny cysts due to the accumulation of secretions within them. (Forchheimer.) The adjacent lymphatic glands become slightly enlarged and sensitive. Fortunately the constitutional symptoms with this form of stomatitis are not severe; there may be deranged digestion, vomiting, and a mild attack of diarrhea. The disease runs a brief course, and disturbances are usually easily corrected by care in feeding and cleanliness.

In later stages, the degeneration spreads, the mouth becomes dry and parched, the blood vessels are congested and active nutrition is interrupted; then comes stasis or stoppage of circulation, and sloughing of the tissue commences.

A child that is fed with a food that it cannot properly digest and assimilate will be poorly nourished, and as a result, almost any form of disturbance may ensue. The irritated condition of the digestive tract may produce diarrhea and gastric disturbances, and may result in ulcerative stomatitis. We have then an advanced stage of the first condition. The functions of the mucous follicles quite cease, and cracks and fissures open in the unlubricated tissue. All the preceding symptoms are aggravated. The child cannot take its food without difficulty, and what is ingested affords little nourishment because of the gastric disturbances that are always present.

Aphthous stomatitis, or herpetic stomatitis as Holt calls it, is a form that may attack people of almost any age, and is characterized by some special appearances. Small round or oval ulcers appear upon the reddened mucous membrane of the lips, cheeks, tongue, or gums. They are from one to three lines in diameter, very little depressed, with a yellowish or white floor, and a red, narrow, perhaps slightly indurated, border. Sometimes two or more of them become confluent, thus forming an irregular, large ulcer. When these heal they leave no cicatrix. The aphthæ do not spread like the spots in ulcerative stomatitis, and they are distinctly painful, while the ulcers are not.

Usually there is an increased flow of saliva accompanying them, the mouth is hot and feverish and the tongue heavily coated. Sometimes the saliva excoriates the skin and the lips are thus kept constantly sore. The older ulcers may have the appearance of a diphtheritic membrane, being a dirty grayish color.

It is usually a self-limited disease and may cover a period from 5 days to 2 weeks. There is a considerable doubt as to its etiology, but Holt* and Forchheimer† agree that it is of nervous origin, and not proved to be contagious. It is frequently associated with disturbances of the stomach and an attack may be coincident with the eruption of the teeth.

Thrush is a form of stomatitis occurring in children and dependent upon the growth of a parasitic fungus. This consists of long, jointed threads, the saccharomyces albicans, which seem to belong to the family of the molds. Thrush is undoubtedly contagious. If a little of the exudate from the mouth is treated with a drop of liquor potassæ and examined with the low-power of the microscope, the structure will reveal the fine threads (the mycelium) and the small oval spores. Slight catarrhal stomatitis, inadequate salivary secretions and lack of cleanliness in the mouth will favor its development.

Wherever many young children are congregated, as in asylums, nurseries, and foundling homes, all are liable to contagion of the disease. It is most frequently developed in children suffering from malnutrition or other wasting diseases, or from any deformities within the oral cavity, as hare lip and cleft palate. On looking into the mouth of young infants a layer of thin white patches, almost a membrane, may be seen covering the palatal arch and appearing as white spots upon the tongue, while the mucous membrane about or at the borders of this coating seems to be in a healthy condition. The white flakes cannot be wiped or brushed off; any attempt to forcibly remove them will induce bleeding.

The preceding remarks are more especially applicable to infantile stomatitis. The same or analogous conditions may be induced in adults by like causes. Anemic and poorly nourished persons are especially liable to inflammations of the oral tissues. The lips are dry and parched, and superficial fissures and cracks in the mucous membrane appear. In a less degree this will be observable upon the tongue, the buccal surfaces, and in the vault of the mouth. This may continue for some time, until finally, with the progression of a general febrile state, a more active stomatitis is developed that may result in a local breaking down or ulceration.

Neglect of the teeth and mouth tissues is a fruitful source of stomatitis in adults. Food is left to ferment and putrefy, and the products of this action will be exceedingly irritative to the soft tissues, as well

*Infancy and Childhood: Holt, 247.
†Archives of Pediatrics, ix, 330.

as destructive to the hard. There will always be gingivitis present in the mouths of those who do not give proper attention to the removal of foreign substances from about the teeth, and this, by continuity of tissues, may spread all over the mouth. Usually the action of the saliva upon the portions freely washed by it is sufficient to keep them clean and normal. But between and about the teeth, where food remains for an indefinite time, in the absence of proper care the gums are always irritated and more or less congested, and this may spread to adjoining tissue, with the result of an acute stomatitis in atonic conditions.

In infantile affections the very first measures to be adopted necessarily imply an inquiry into the food and feeding. If the child is artificially fed, the nursing-bottle should be carefully inspected, and the food that is given must be scrutinized. If there is anything unsanitary about either, it must be at once corrected. The rubber nipple must be sterilized, or, what is better, *discarded* and substituted by a new one that has been made thoroughly aseptic. If the child is poorly nourished through improper or insufficient food, that must be remedied, and plenty of nutritious matter that can be readily digested and assimilated should be given. If there are diarrheas or other wasting disorders, which will too often be the case, they must at once be attended to; it will be impossible to build up a patient while any process of waste is going on. All unhygienic surroundings must be remedied, and the patient should be given plenty of light and air, and proper exercise. In short, beneficent Mother Nature, upon whom we must finally rely for a cure, must be afforded every opportunity. Functional activity must be promoted, and all obstacles removed.

After securing perfect sanitation the local treatment will be mainly depurative and stimulative. If a cathartic is indicated, two drams of castor oil may be administered. For the local irritation, a mouth wash consisting of a solution of five to ten grains of chlorate of potash to the ounce of water may be used as a mouth wash. If the child is too young to use this itself, a swab may be made by tying absorbent cotton to a stick of proper dimensions, and this may be used to apply the solution, employing a proper degree of friction. If the mouth is sore, it may be applied with a soft sterilized gauze—never use a soft tooth brush, it carries infection. The mouth may be occasionally washed out with the following preparation especially after eating:

℞—Borax,	30 grains.
Sodium bicarbonate,	1 dram.
Distilled water,	4 ounces.

Or the following may be substituted in its place:

℞—Boric acid.	
Potassium chlorate, of each	15 grains.
Lemon juice,	½ ounce.
Glycerol,	6 drams.

Never give syrups or honey to a child.

If there are deep erosions of the mucous membrane, or ulcerative surfaces, it may be necessary to cauterize them, either with silver nitrate, pure phenol, or chromic acid crystals. The last named are preferable in instances in which they can be conveniently used. The cauterized places should be subsequently dressed with a solution of calendula.

The treatment of follicular, or ulcerative, stomatitis in adults does not materially differ from that in infants, except that more active measures may be used. The remedies may be proportionately increased in strength, and personal care insisted upon. The teeth should be thoroughly cleansed, and all broken or sharp edges removed. A soft tooth brush should be employed after every meal, only when a normal condition has been established, and with it should be prescribed some antiseptic wash. A two per cent solution of zinc chloride may be used as a gargle. At night a spoonful of milk of magnesia should be taken into the mouth and rinsed about all the teeth, to be left upon them until the morning. Enough of good nourishing food should be given, and the patient should have plenty of pure air and sunshine.

In cases of thrush in infants that are badly or insufficiently nourished, there is usually more or less of gastric or intestinal irritation in connection with the markedly atonic condition. This will probably require the administration of such correctives as rhubarb and soda, or lime-water. When the aphthæ occur in older persons they are often spoken of as "canker spots," or "canker sore mouth." The usual treatment is roughly to cauterize the spots and dress them with a solution of calendula. If an active cauterant is not desirable, as in children, the aphthous patches may be repeatedly touched with the following solution:

℞—Sodium salicylate,	1 dram.
Distilled water,	6 drams.

Or in place of the preceding this may be used

℞—Borax,	45 grains.
Sodium salicylate,	75 "
Tinct. myrrh,	1 dram.
Distilled water,	½ ounce.

The chlorate of potassium solution is strongly recommended.

If the aphthæ exist in considerable numbers, they may demand the use of antiseptic mouth washes. If they are the consequence of a general anemic condition, tonics and alteratives are of course indicated. While they are peculiarly uncomfortable, the aphthæ have no serious pathological signification, except as they are indicative of an atonic condition.

DEPOSITS.

Superficial deposits upon the teeth composed largely of inorganic precipitates have their origin from external sources, and most frequently are derived from the fluids of the mouth. In addition there are accumulations of organic detritus, as decomposing food, animal and vegetable; fermenting starches and sugars; advanced products of decomposition; waste and broken down epithelial cells from the mucous membrane, and myriads of benign and malignant micro-organisms. These combine to form a pasty and cheesy deposition, which is found about the cervical margins of the teeth and gums. This mass is not in the nature or form of a calcareous tartar, and is easily removed by the frequent and habitual use of the tooth brush and waxed dental floss. It is not always necessary to use a tooth powder every day, for once the teeth have been properly cleaned by the careful dentist, it becomes comparatively easy for the patient to keep the mouth free from this debris. It must be emphatically stipulated, however, that these products of decomposition should be daily removed by the patient. In addition, if necessary, the dentist should insist upon seeing his patient at frequent intervals until there shall have been established conditions that indicate a normal, healthy mouth.

No amount of filling and restoring of defective teeth will ever suffice to maintain a healthy mouth so much as the unremitting care and removal of these organic deposits. The elimination and prevention of caries is dependent upon the destruction of the micro-organisms of decay, and the removal of their acid products which are so destructive to enamel and dentin. The action of these organic deposits is not always readily appreciated. The destructive effects of the acid products in the interproximal spaces and angles formed by overlapping teeth, or where teeth have been extracted leaves the space to be filled in by the unsupported teeth, which causes a tipping forward thereby forming triangular pockets which lodge food and debris. The enamel may be quite thin at the points of contact in the interproximal space and universally so, yet not show an active break in the continuity of the surface. This accounts for the apparent rapid destruc-

tion of the teeth, when in reality the destructive process has been going on for years.

Green stains are among the simpler deposits found upon the teeth of young children as well as adults, particularly in the region of the cervical margins. These stains are wholly superficial and vary in color from a dark green or bronze to yellow. They are not indicative of any special pathological disturbance, only insofar as they denote an undesirable condition in the oral secretions. Their early removal is advocated, because they are claimed to be from a disease producing fungus which, if neglected and allowed to remain, will penetrate the enamel, and so erode the surface as to form a series of granular pits which ultimately combine to form a distinct cavity.

Erosions of the enamel surfaces frequently have their inception through the agency of the green stain deposits, and wherever there is a congenital weakness in the enamel, as in faulty structure of the enamel prisms, having soft white spots of calcification immediately adjacent to the interglobular spaces of the dentin, then erosion and decalcification and rapid destruction of tooth substance quickly follow.

Other stains found upon teeth are those deposits caused by the excessive use of tobacco and tea, and sometimes from the use of medicines. Except from the unclean appearance produced by these latter stains, there appears to be no immediate injury to the enamel surfaces in consequence. It is important, however, that they should be removed; this may be done readily by touching the stained area with a small amount of tincture of iodine then scouring with English precipitated chalk. If the surface is eroded and roughened, it must be dressed down smoothly with cuttle bone, or fine Arkansas stone and finally polished with chalk.

The salivary calculus, and the calcareous accumulations being deposited about the neck and roots of teeth, cause recession of the gum tissue and inflammation of the peridental membrane; these are among the most important of the deposits, because the neglected accumulations induce diseases of the gums and adjacent tissues, and although local and superficial in deposition may be the precursor of more serious disturbances.

The salivary calculus is a deposit from the saliva. The calcium salts are held in solution through the agency of the carbon dioxide (CO_2) present in the newly elaborated saliva. This fluid is poured into the oral cavity where it encounters acids derived from a variety of sources, and is subjected to the action of the ferments from decomposing foods. The quantities of saliva are more or less variable;

this is also true of the calcic salts contained in it. The carbon dioxide (CO_2) is held in a very unstable solution, and upon exposure to the oxygen of the air and contact with the acids in the mouth, derived from various sources, the carbon dioxide (CO_2) is liberated, the calcic constituents lose their solubility, form precipitates upon the teeth, and give rise to what is commonly called salivary calculus or tartar. Combined with these calcium salts are products of organic decomposition, which cause the tartar to become a powerful irritant to the gum tissue, and induces inflammation in the contiguous tissues.

The deposition of salivary calculus is mainly in the region of the mouths of the salivary ducts, as Wharton's duct and the duct of Steno. The greater amount is liable to accumulate upon the lingual surfaces of the lower incisors, and opposite Steno's duct, upon the buccal surfaces of the upper molars.

One of the predisposing factors in the accumulation of large precipitates of tartar is found in the fungoid growths and deposits upon the teeth, made up largely of partially decomposed food and threads of the higher bacteria as the leptothrix or streptothrix actinomyces. The protoplasm of the filaments of these organisms breaks up into bacillus-like elements, and all combine to form an agglutinating mass, which holds the precipitates of calcium and becomes a nidus for a concretion. And although the mouth has been kept free from these organic bodies, it is possible to find a foundation for holding tartar deposits in the saliva itself, which is a mixed fluid derived from the secretions from the oral mucous, parotid, sublingual and submaxillary glands. These secretions are subject to considerable variation, both in physical as well as in chemical character. Ordinarily, saliva is a clear, viscid fluid, at times thin and watery and at other times thick and ropy. According to Michaels, it contains all the salts of the blood which are dialyzable through the salivary glands; this offers a fair index of the metabolic processes being carried on in the entire system. There are times when the viscid and tenacious quality of the saliva with its mucin constituents becomes dried upon the teeth, forming masses of sordes (Marshall); this, together with the debris of epithelial cells, mucous corpuscles and salivary corpuscles offers a favorable nidus for tartar deposits.

CHEMICAL COMPOSITION OF SALIVA.

The chief constituents of a normal mixed saliva are ptyalin—a diastatic ferment—mucin, and the chlorides of sodium and potassium. In variable quantities traces of albumin, fat, potassium

sulphocyanide, sulphates and phosphates of the alkalies and alkaline salts, as the calcic phosphates, calcic carbonates and oxide of iron may be found; occasionally also traces may be found in normal saliva of urea and ammonium nitrate. "The source of origin of the saliva that contains these chemical constituents is from the blood, or more correctly from the plasma, which is filtered off from the circulating blood into the interstices of the glands, as of all living textures."

In reaction the saliva when first secreted is slightly alkaline. During fasting, although secreted alkaline, it soon becomes neutral. Tests of saliva with litmus paper frequently give an acid reaction, and this may be due to the elaboration of acids from foods, ferments and bacteria.

Tomes gives the daily average of the amount of saliva excreted from 800 to 1500 grams, approximately from three pints to a little less than a quart.

Lehmann has estimated the specific gravity of saliva in health as ranging from 1004 to 1006, and states also that there may be a rise as high as 1009 and a fall as low as 1002, without the evidence of any existing disease.

Frerichs* gives the following chemical composition of mixed saliva:

Water,		994.10
Solids:—		
Ptyalin,	1.41	
Fat,	0.07	
Epithelium and proteids (including serum-albumen, globulin, mucin, etc.),	2.13	
Salts:—		
Potassium sulphocyanate, Sodium phosphate, Calcium phosphate, Magnesium phosphate, Sodium chloride, Potassium chloride	2.29	
		5.9
		1,000.00

The excretion of the parotid gland contains slightly more water than the secretion from the submaxillary and sublingual glands, and in consequence is less viscid. It is rich in ptyalin, but contains no mucin; its calcic constituents are the carbonate and phosphate, the latter existing in minute quantities. According to Hoppe-Seyler the inorganic elements yield about 0.34 per cent.†

* Kirkes' Handbook of Physiology, 1893, p. 295.
† Marshall Op. Dentistry, 523.

The secretions of the sublingual and submaxillary glands are poor in ptyalin but rich in mucin; the sublingual contains the highest per cent. Carbonate and phosphate of calcium yield about equal proportions. These elements amount to about 0.43 per cent in the submaxillary secretion, but the precentage is not so high in the sublingual.

Mucin is derived largely from the mucous glands, and the organic and inorganic constituents average about 20 parts to 1,000.

Berzeleus estimates the composition of salivary calculus as follows:

Phosphates of calcium and magnesium,	79.0
Salivary mucus,	12.5
Ptyalin,	1.0
Animal matter soluble in HCl.	7.5

Calcic deposits from whatever source should be removed, and inflammations of the gums and mucous membrane of the mouth irrespective of their origin must be relieved and resolved into healthy tissue. It does not necessarily follow that because we find large deposits of tartar upon the necks of the teeth that we have the disease of pyorrhea alveolaris. We have seen many patients whose teeth have been neglected, and who were innocent of the smallest effort on the part of a dentist in all their lives as to removal of the deposits, which were excessive, and to whom the use of a tooth brush was unknown, yet upon the careful removal of these deposits and orderly and habitual use of the brush the mouth was quickly restored to a healthy condition.

The deposits in some instances have been exceedingly thick, and upon the lingual surfaces of the lower anterior teeth an aggregation of successive layers has formed, that completely bound the teeth together as in a plaster cast. The encroachment, however, does not always extend very far below the gum, nor necessarily involve destruction of the peridental membrane. An early treatment of such conditions, to be described later, results in complete restoration without the accompaniment of the disease designated pyorrhea alveolaris.

SERUMAL DEPOSITS.

It is not the purpose of this part of our work to treat exhaustively the various authoritative opinions as to the etiology of the serumal deposits. We shall consider, however, a few of them in so far as to present a general summary that will guide us in recognizing these deposits which call for special treatment in their removal. The subject has been considered more completely in the chapter on pyorrhea alveolaris.

Dr. John Marshall,* in 1891, said, "That the deposition of the concretions upon the roots of the teeth in those localities not easily reached by the saliva, or in which the presence of the saliva would be an impossibility, is due to the causes which produce the chalky formations found in the joints and fibrous tissues of gouty and rheumatic individuals."

Dr. G. V. Black has done considerable research work and has written an exhaustive paper, published in the American System of Dentistry, Vol. I, p. 953, wherein he speaks of a calcic inflammation and phagedenic pericementitis as an accompaniment of the tartar deposits upon the teeth in the region of the peridental membrane, and though he indicates his belief that the cause is wholly local, he also admits that a sanguinary deposit may be closely involved in its origin. He differentiates it as a destructive inflammation of the pericemental membrane, distinct from other inflammations of this tissue though possessing features in common with them. In summing up his estimate, he concludes that the disease is essentially one of the peridental membrane rather than of the alveolus, and the destruction of these two structures is so nearly synchronous that it becomes difficult to say which has gone first.

Dr. C. N. Pierce† gives the name ptyalogenic calcic pericementitis to the conditions wherein the teeth are involved with calcic deposits, indicating, as he believes, the origin of these deposits and other calculi as traceable to the saliva. We are not concerned particularly in this section of our paper with the cause so much as in adequately recognizing the conditions in the mouth that call for treatment, and the establishment of a sound oral hygiene.

W. C. Barrett‡ has summarized the theory of E. C. Kirk on the formation of serumal calculus as follows:

"The capacity of the blood stream for holding in solution the waste products of nitrogenous metabolism, the results of functional activity in the body, is determined by the alkalinity of the blood plasma. Any decrease in this diminishes its solvent power for these, and causes their precipitation in the tissues nourished by the blood stream. This lessened alkalinity may be general, affecting the whole sanguinary current, or it may be localized in certain tissues; in the latter case there will be a localized precipitation of the products of which uric acid is a type. Excessive work causes an increased blood supply to a part,

*Transactions American Med. Assoc., 1891.
†Am. Text Bk. Op. Dentistry, 2d Ed., p. 510.
‡Oral Pathology and Practice: Barrett, p. 139.

and excessive oxidation and tissue waste, which in turn produce lessened alkalinity, or a tendency toward acidity. The ligamentous tissues are especially liable to conditions of this nature, and the peridental membrane, belonging to this category, is especially subject to affections of the character noted. Excessive work being put upon the investing membrane of any tooth, through malocclusion or by bad habits in mastication, by injuries from wedging, the application of ligatures, or other causes, the resulting hyperemia brings in its train overnutrition, localized diminished alkalinity, with the consequent deposition of urates."

We have thus considered those superficial deposits found upon the teeth having their origin from organic debris and the saliva; it remains to briefly differentiate those which form upon the roots of the teeth primarily, and are commonly designated sanguinary calculus. Its characteristic appearance is somewhat different from the salivary calculi, although these latter may, through a considerable period of successive depositions, become in time a dense, black, smooth supragingival deposit, having incorporated through the agency of pigmentary matter; oxides from amalgam fillings, and the action of medicines, which may cause it to assume the external color and appearance of the sanguinary calculus.

The location of these depositis would indicate their entire independence in formation of the oral fluids, as they are found precipitated upon the periphery of a root that is not denuded when formed, and where there is no destruction of the gingival border. It is distinctly more irritating to the tissues than the smooth amorphous deposits from the salivary calculus, and this may be due to its position within the alveolar socket where it is preëminently a foreign body. The depositions are not in uniform amorphous masses, but as separate minute nodules, which cling tenaciously and are with considerable difficulty removed. Successive aggregations unite to form a mass that is hard and brittle, whose color is olive black or olive green. It is unlike the salivary calculus which may be readily detected, and is therefore easy of diagnosis, as it is hidden away within the socket, sometimes beyond a point of accessibility for its removal.

The removal of deposits, whether of salivary or serumal origin, demands the highest skill and care in the use of specially designed instruments for this operation. No hurried and indifferent service rendered the patient will ever restore the oral tissues to a normal condition; this result is obtained only by deliberate painstaking care, combined with intelligent work.

The selection of proper instruments must be determined not by any arbitrary rule, but according to the requirements of the operation to be performed, and the writer has obtained the best results from a composite set selected from the admirable instruments designed by Doctors Kirk, Darby-Perry, King, Marshall, Abbott, Harlan, Smith, S. S. White Manufacturing Company, and J. W. Ivory.

The instruments should be clean and sterilized, and everything about them suggestive of care. The patient should be comfortably seated, and the chair inclined and head-rest adjusted in order to have the mouth receive the largest amount of light possible. All napkins, large or small, must be fresh and clean. The larger napkin should be sufficient to protect the patient's clothing from flying particles and loose debris. Ordinarily the operator stands firmly on the right side of the patient with his left arm around the head-rest, and by this means is in a position to gently steady the head. Small rectangular pieces of sterilized gauze from 4 x 4 inches to 5 x 5 inches are most useful in receiving the soft deposits as they are spooned off. A small piece of gauze should be rolled and placed between the lower lip and gums to prevent pressing the septic matter into the delicate membrane of the lips. The lips may become infected and considerable swelling be induced by lack of care on the part of the operator. In order to lessen this liability it may be necessary to prescribe a suitable mouth wash and special application of the tooth brush for a few days preceding the operation of removing the debris. Where conditions are abnormal, this precautionary treatment is of value in preventing further inflammation.

The left hand should hold the mouth mirror, which serves the double function as a tongue depressor and light reflector. The eye of the operator should always follow the scaling edges of the instrument as near as possible, and whether the movement is a drawing upward or pushing downward, the scaler should be so held and supported by the fourth and fifth fingers resting upon the adjacent teeth, that there shall be no danger of a slipping and plunging into the tissues of the gums. When a deposit has been definitely located and dislodged, it should be immediately removed and accounted for. It may be necessary to frequently syringe the tooth and membranes with a warm, antiseptic mouth wash in order to facilitate the complete elimination of all foreign irritants.

Whenever there are indicated deposits below the gingival margin, it is well first to remove carefully the superficial deposits upon the surfaces of the teeth above the membranous tissues; beginning at the

central incisors and cautiously working round the arch to the third molars; each half of the mouth being treated successively until all the teeth have been scaled. The time necessary for this operation will depend somewhat upon the conditions presented, and it may be necessary to resume the operation at a future time. During this preliminary scaling, mental note should be made of the pockets formed between the roots where debris and calcic deposits accumulate; minute congestion of the gingiva; triangular spaces and irregularities as a result of inclined crowns, and any other factors predisposing and favorable to the accumulation of deposits, as cavities through caries; furrows between the cervical enamel and cementum; hypertrophied tissues; eroded cement fillings; rough and pitted gold fillings and surfaces; projecting amalgam and other fillings; improperly fitting clasps, artificial dentures and gold crowns. All supragingival surfaces should be most scrupulously scaled, cleaned and polished as a preliminary operation to further removal of the subgingival accumulations. It matters not who may be responsible for the old restorations, it is a necessity that the roughened fillings and surfaces be cleaned and polished.

Incidentally, the patient's attention may be directed to certain localities within the mouth where there is a special tendency for the retention of decomposing foods.

Subgingival deposits invariably induce distinct pathological conditions within adjacent membranes, and each tooth carrying upon its surfaces and roots these foreign bodies should be treated individually, until all trace and evidence of their presence has been removed.

The tenacity with which serumal deposits cling may call for the use of a softening agent, and a twenty per cent aqueous solution up to fifty per cent of trichloracetic acid may be used with beneficial results. The percentage strength of the acid necessary is to be determined by trial. The acid is carried into the region of the deposit, either upon a wedge-shaped piece of orange wood stick or upon a few fibers of cotton soaked in the acid. A gentle pumping motion will suffice to reach the nodular deposits. Lactic acid has been recommended for the same purpose with claims for its therapeutic value.

The chiseling and scaling and applications of the acid may be repeated until all the nodules are removed, and the roots are clean and smooth. Care must be exercised not to lacerate the tissue of the gums and peridental membrane. The force employed should be well under the control of the operator to avoid destruction of the cementum, and unnecessary loosening of the tooth. Too much movement of the tooth

within the alveolar socket is liable to carry granules of calcific deposits and septic matter further into the pocket and tissues. Should the teeth be very loose, a temporary supporting splint, made of softened modeling compound, and applied to the labial surfaces of the teeth en masse, when the lingual surfaces are under treatment, will be an effective and agreeable support; the reverse application when the labial surfaces are treated. Frequent syringing with a warm antiseptic mouth wash, such as phenol sodique or peroxide of hydrogen (H_2O_2) three per cent solution, to remove debris is necessary.

The author counsels against a too early application of massaging of the gum tissues, because of the danger of incorporating within the tissue loose deposits that become a continual source of irritation. This operation may be deferred until later when all trace of inflammation has disappeared, and careful exploring reveals no deposits.

Ultimately, a weak solution of zinc chloride may be worked into the pockets as a stimulating astringent. New vitality may be induced, bringing new granulations to the alveolar edges by scraping with a bur or hoe excavator.

The treatment should end when all is clean, and there is an effusion of coagulable lymph, which should be left and not washed or wiped out, because at this point nature can accomplish much in the restorative process.

The dentist should determine for his patient how soon this operation should be repeated, and that will be governed by keeping a careful record of the status of the case with treatment and results for future reference.

CHAPTER VI.

DENTAL CARIES.

BY C. N. JOHNSON, M. A., L. D. S., D. D. S.

In a work like the present it is deemed unnecessary to go minutely into the pathology of this disease and yet it is well to consider somewhat carefully certain of the etiological factors which affect us vitally in operative dentistry. Every operator who attempts to save the natural teeth should have a reasonably clear conception of the cause or causes of caries, of its modus operandi, and the peculiar methods of its attacks. If he is thoroughly informed on these points he will be in a position to do better work thereby, and recognizing this the foremost men in the profession have always sought to inform themselves in regard to these matters.

Some of the theories of the past have been so wide of the mark that they are interesting only as milestones along the uphill road of scientific progress, while others, though crude and lacking in demonstrated data, are worthy of the greatest respect in the light of the most recent knowledge. Certain writers have held the theory that inflammation played a part in the breaking down of the tooth tissue, that the character of the tooth structure itself was the most significant thing connected with it, and that the disease progressed from within outward. Others thought that while the disease began upon the surface of the tooth and progressed inwardly it was due chiefly to the chemical reaction of the saliva, that in fact it was acid saliva which produced the decay. But it was inconceivable to think that the saliva ever became sufficiently acid to eat into a tooth in the manner in which we find caries progressing, or that the soft tissues could tolerate it if it did. Not only this but if the saliva did the work we would find the teeth attacked uniformly upon all surfaces bathed in saliva while as a clinical fact there are certain surfaces in which decay seldom or never has its initial point of entrance. Some of our close observers noted these things and away back as far as 1828 Robertson indicated that the carious process was due to the action of some agency occurring immediately at certain points where cavities were to begin, his idea being that it was caused by "decomposition." This theory was of course vague as to the real active agent of caries, but it was correct

in the principle that it was localized at certain points and was not general in the fluids of the mouth. There was much conjecture about the whole question of the active agent of caries till Professor W. D. Miller demonstrated in 1884, that it was due to the formation of acid brought about by micro-organic growth in the mouth. The findings of Miller have stood the test of investigation since then, and while there are many factors in the development of this disease which we do not yet quite understand, still they gave us the first real basis of scientific knowledge to work from.

In a somewhat close clinical observation of the behavior of caries, the variation in its manner of attack, and in its general modus operandi in different cases, it is hard to conceive that it is always brought about in the same way or that its progress is invariably governed by the same conditions. That an acid causes the solution of the tooth tissue seems settled, and that this acid is the product of micro-organisms is also an apparently accepted fact. But why is it that we find such a variation in the manifestations of the disease in different mouths, and even in different periods in the same mouth? We may find micro-organisms in all mouths—in fact the very micro-organism which Miller demonstrated would bring about decay, and decay which could not be distinguished from that occurring in teeth in the mouth—and yet there are some mouths in which decay never occurs, and in most mouths where it does occur there is a great variation in its virulency at different times.

It was formerly the prevalent idea that these variations were due to differences in the tooth structure, that one tooth was harder than another and would therefore withstand the attack of the carious agent better, and this impression was so strong in the profession that it finally communicated itself to the laity and is still firmly fixed in their minds. It is common to hear patients say that their teeth are so soft that it is almost impossible to save them, or on the other hand that they are growing harder so that they do not have so much trouble with them as formerly. This has been a most difficult fallacy to dislodge from the minds of the profession, and it has been the means of the loss of a very great number of teeth which otherwise might have been saved. The impression that the teeth are inherently so defective in structure that they are thereby peculiarly susceptible to the attack of caries is very disheartening, and it has led many patients to abandon any effort to save them and to allow them to go by default. This impression has too frequently been fostered by members of the profession, whose function as teachers of the public should have made them guard against such false and harmful doctrine.

It is now more than ten years since the investigations of Dr. G. V. Black demonstrated conclusively that there is really little variation in the chemical constituents of the teeth of different individuals, and that what variation there is has little or nothing to do with the inception of dental caries. This came as almost a revolutionary statement at the time but his findings have never been disproved. Neither do the teeth of individuals grow harder and softer in any such sense as would account for the variations we see in the same mouth in the tendency to decay at different periods. Teeth grow slightly harder as age advances but this change is exceedingly slow and not of a character to affect the manifestations of caries. This is readily understood when we recall the fact that the teeth are the most stable organs of the human body, and are not being constantly torn down and built up by waste and repair as are other tissues.

And yet the impression in the profession that some teeth were very much harder than others was a perfectly natural one, owing to the difference in behavior of teeth under cutting instruments. This difference could not escape the attention of the most careless observer. Some teeth crumble away under chisels, excavators and burs, as if composed mostly of chalk; while others resist the attack of steel instruments almost to the point of striking fire. This led to the impression of varying softness and hardness in the teeth, and quite naturally to the conviction that this had a direct bearing on the tendency to decay. But there is another reason to account for the difference in behavior of teeth under instrumentation, and it is in accordance with close clinical observation that these same so-called "soft" teeth sometimes remain in the mouth for life free from caries while the "hard" teeth as frequently decay. It simply resolves itself down to a question of environment—the conditions which surround the teeth—rather than to the organic structure or constituents of the teeth themselves.

The reason that teeth vary in their resistance to cutting instruments is limited almost wholly to the enamel and is due chiefly to the arrangement of the enamel rods. In some teeth the rods stand nearly parallel and radiate outward in regular order from the dentin in a comparatively straight line. It is noteworthy that in any enamel the cement-substance which holds the rods together is not very strong and the enamel is easily cleaved in line with the rods. It will thus be seen that straight-grained enamel like this will break down readily under instruments. But there is other enamel in which the rods pursue a wavy course, and a section of which looks something like the structure of a gnarled oak. When a chisel is directed against

such enamel as this it meets the stout lateral resistance of the rods themselves and is broken down with exceeding difficulty.

But there is no enamel formed in the mouth of man which the acid of decay is not capable of dissolving if the conditions are favorable to its development, and so all enamel is alike subject to the attack of caries. This one difference may be noted that when decay has once begun it is reasonable to suppose that it will progress more rapidly in enamel where the rods stand straight so that the acid can have ready entrance between them than it will in wavy enamel where the access is less easy, though this has no relation to the question of the liability of the teeth to the original inception of caries.

If, then, it is a matter of the conditions surrounding the teeth which chiefly influences this disease, it is imperative that we study these conditions somewhat carefully, and herein, be it said, lies the future hope of the profession in controlling and ultimately in preventing a disease which is acknowledged as being the most prevalent of all diseases of the human race. Had it been a question of the tooth structure there would have been small hope because we have learned that when once developed we cannot change that, but being a question of condition we may reasonably expect in time to so control the surrounding condition as to limit the disease.

First it is necessary to learn what the conditions are which influence the inception of decay. We have said that the micro-organism of caries may be found in all mouths; then the natural query is, why do we not find decay in all mouths? What is the particular agency which makes it possible for the micro-organism to bring about caries in one case, and impossible in another? Dr. J. Leon Williams, and Dr. G. V. Black have called attention to what they consider an important factor in the institution of caries, viz., the formation of gelatinous plaques on the surfaces of the teeth. We know that there are certain micro-organisms which in the process of their development produce a material closely allied in appearance to gelatin, and these are called gelatin-forming micro-organisms. The micro-organism of caries is one of this class, and it is the opinion of Williams and Black that it is mainly through the agency of these plaques that cavities are formed.

It is of course known that an acid in order to dissolve enamel in the way we see it in the mouth must be a strong acid, and unless the micro-organisms have some protection to work under their acid would be diluted very quickly in the fluids of the mouth, and thus their destructive process be interfered with. It is therefore the idea of these investigators that it is by virtue of the protection given the micro-

organisms through the formation of gelatinous plaques that the beginnings of decay are brought about. A film is formed on the surface of the enamel and under cover of this the micro-organism may produce its acid in concentrated form and attack the enamel undisturbed by external interference. In fact Dr. Williams has been able to make ground sections of teeth thin enough for microscopical examination, showing the film in place with the micro-organisms under it and decay beginning in the enamel. Of course, after a cavity has once been started the micro-organisms have a sheltered place in which to work and do not need this gelatinous protection, but it is in the inception of caries that it plays an important role. This film is not soluble in the fluids of the mouth nor is it easily dislodged when firmly attached. No rinsing of the mouth with liquid will affect it, and it takes appreciable friction with a tooth brush to dislodge it. The saliva may therefore flow freely over its surface without disturbing it, and even the most potent of the mouth washes yet devised will not dissolve it.

In this view of the case it is concluded that the significant thing in dental caries is the formation of this film, and that it is really the controlling factor in the question of immunity and susceptibility. In some mouths the conditions seem favorable for the production of these plaques, in others not, and upon this the issue is turned. In referring to plaques it must be remembered that a distinction should be made between these gelatinous plaques and patches of inspissated mucus and greasy masses of material left adherent to the surface of enamel through neglect in caring for the teeth.

Dr. W. D. Miller in writing on this subject seems to place less significance on the film than Williams and Black, and claims that the case is not yet proven. He says that we may find these films freely in mouths where there is no decay, and that we may also find cavities without the presence of a film. In the latter instance he admits that the absence of a film after a cavity has started is no evidence that it may not have been there in the beginning.

In point of fact we have had just sufficient knowledge on this subject to make it imperative that we have more. As has already been intimated the behavior of some cavities is so entirely different from that of others that it is hard to conceive that they are all influenced by the same factors, and it is hoped that further investigations along these lines will give us a broader view of the whole question, and clear up some of the points which at present seem somewhat clouded.

But what concerns us most at this time are the clinical manifes-

tations of immunity and susceptibility as we meet them in our every day practice. Dr. Michaels of Paris in studying the manifestations of susceptibility and immunity, took the ground that they were largely influenced by the condition of the fluids of the mouth, and claimed that in all cases of high susceptibility to dental caries there was a superabundance of ammonium salts in the saliva and an absence of sulpho-cyanates, while in immune mouths there was a diminution or an absence of ammonium salts with the presence of sulpho-cyanates. More recently Dr. F. W. Low of Buffalo, N. Y. has practically confirmed Michaels' findings, and goes one step further in an effort to control the tendency to caries. In cases of great susceptibility he has been administering the sulpho-cyanates to patients with what seems to promise success in arresting the tendency to decay. It is hoped that these investigations will lead to something definite in the way of controlling this disease. A close observation of the phenomena of caries in the average susceptible mouth will disclose the fact that there are certain times when the disease is much more active than others. The periodicity of dental caries may be studied with much profit by the dentist, with the result that he is better equipped to manage the cases that come to him and more encouraged to persevere in the face of an apparently hopeless condition where the active agent of caries seems to be running rampant over the entire number of teeth in a given mouth.

It is very rare indeed where the progress of this disease goes on uninterruptedly to the destruction of all the teeth in a mouth even when no attempt is made to arrest it, and much rarer in the event of any effort being put forth on the part of the dentist and the patient toward its control. That this is true is sufficiently evident from the large number of cases seen in practice where some of the teeth have been lost many years previously while the rest are being preserved with very little tendency to decay. The lesson of this is that if we can carry a case through a period of great liability to decay we may reasonably expect a period of immunity to come sooner or later and with this to aid us in our efforts we may confidently hope to save the teeth for a lifetime so far at least as decay is concerned.

One very significant fact in this connection is worthy of especial note—a fact embodying the greatest encouragement and carrying with it the highest incentive to persistent and painstaking effort on the part of the dentist. This is the assurance, established by a very close clinical observation in the study of cases extending over many years, that the period of immunity may be advanced very materially

by proper dental service at the time of greatest susceptibility. In other words when a dentist is struggling with a discouraging case of caries, endeavoring to keep the teeth free from deposits and insisting that the patient does his part in this work, when he is filling cavities which develop with disheartening frequency and repairing fillings that have failed, he may be assured that the result of his efforts does not stop with the teeth he is operating on, but that in his attempt to suppress decay he is changing the conditions in this mouth and establishing a state of immunity which will eventually aid him materially in saving the teeth of his patient. With this view of the case no dentist should lightly yield up decaying teeth to the forceps, nor should he become discouraged however prevalent decay may be in the mouth. There are exceptions to all rules in practice, and there are some mouths in which the tendency to caries seems to persist for a disheartening length of time, but in the average case the results are so very gratifying that it is well worth the effort of both operator and patient to follow up a line of treatment tending to its suppression.

The period of greatest susceptibility to dental caries is in youth, and it is here that our best endeavor in controlling decay should be put forth. If we can successfully save the teeth to the twenty-fifth year the worst of the difficulty is over, except that in mouths where there has been great susceptibility we may look for occasional relapses even where a condition of comparative immunity has been established. The circumstances which bring about these relapses are not always apparent and it is sometimes difficult to account for them. Anything which changes the conditions of the mouth may do it, such as a protracted illness, a change of climate which involves an entirely new environment, or any radical difference in the mode of life, or disturbance of the functional equilibrium of the individual. But usually if a relapse comes it is easily controlled and not nearly so severe as the original attack.

This reference to the original attack, the relapses, and the periods of immunity does not imply that there is a sharp line of demarcation between them. An occasional cavity, or cavities, may develop at any time, but there is a very great difference between this and the awful havoc which we see so often occurring during periods of great susceptibility. Neither does it follow, when we get a set of teeth in good condition after susceptibility, that there will be no further need of dental service, even though the mouth should remain immune. Where decay has once manifested itself extensively in a mouth the teeth should have the supervision of a dentist at regular intervals

afterward. There is always the necessity for hygienic treatment in the way of removing deposits and general prophylaxis, besides the repairs so frequently required in the operations performed during susceptibility. In a delicate child during the growing period if the teeth decay rapidly it is not always possible to do permanent work, and we may carry the teeth to the twentieth or even twenty-fifth year and have the formation of new cavities practically stopped, but with the necessity before us of making more permanent operations as the other ones fail from time to time. It is always best, of course, to make permanent operations in the beginning if this is possible, but it is not always possible with some of the temperamental conditions we meet in practice.

To carry one of these young mouths through the susceptible period is often very trying but the result is well worth the effort. The plan of procedure should be about as follows: When a child is brought to the dentist with the teeth decaying rapidly there should be no half-hearted measures or perfunctory attention to the work. It is not merely a matter of filling cavities, though this of course should be done at once, and done as thoroughly as the circumstances will permit. But what is of equal consequence is that a campaign of prophylaxis be instituted with the definite aim of limiting the disease as far as possible in the future. The child should be schooled into a system of caring for the teeth by such an impressive lesson from the dentist that it cannot well go unheeded, and there should be a regular inspection of the teeth by the practitioner to see that proper care is being given them, and that normal function is maintained. The key-note to the whole situation is the alteration of existing conditions in the mouth, and while—as has already been intimated—we do not know all we should about the conditions which influence this disease, yet we are certain of one thing that the establishment of full functional activity is favorable to the limitation of the disease. To this end all teeth should be kept comfortable for mastication, and wherever we find evidences that mastication is not being properly performed we should discover the cause and remedy it. A close observer can always tell whether or not the teeth and gums are subjected to the amount of friction necessary for perfect mastication by noting the unpolished surfaces of the teeth and the hypertrophied and congested condition of the gums, and where it seems impossible to establish the habit of good mastication in any given case, or in any particular region of a mouth, the child should be instructed to make up the deficiency by friction of the brush for a stated period of time each day. The time

should be set by the dentist, and the patient urged to brush by the watch. The friction of the brush moistened in cold water over the teeth and gums for three consecutive minutes twice a day will soon have a very appreciable effect in stimulating the tissues to healthy action, and in polishing the enamel smooth and bright.

Cavities should be filled as fast as they occur, the aim being to keep caries out of the mouth at all hazards. Sometimes the disease is so rampant that it is difficult to maintain the courage of the patient, and yet such a case should be fought with all the energy and enthusiasm of the operator, to the end that he inspires the patient with the confidence of ultimate success. Such patients should be carefully schooled in the theory of an approaching immunity, and the operator who is in earnest in his management of the case may conscientiously promise this on the basis of what has been observed in a close clinical study of such cases. There is a reasonable expectancy that in ninety-nine cases out of one hundred the teeth can be saved if proper attention is given them, and the usual history is that even in a very susceptible mouth about the eighteenth or twentieth year the conditions begin to clear up and the hardest part of the contest is over.

It is true that teeth are sometimes neglected so that when the dentist is finally consulted—usually as the result of pain—the conditions are so bad as to be very discouraging, and yet there is no case so hopeless where sufficient of the tooth is left as a basis for a filling, inlay or crown that the dentist should let it go by default. It is the lack of an enthusiastic application on the part of the dentist, a failure to show forth an evident confidence in the possibility of saving the natural teeth, and the neglect to sufficiently emphasize the importance of retaining them that has led many patients both in youth and middle life to become unappreciative of their real value, and indifferent as to their care.

The dentist may not be able as has already been intimated with our present knowledge to treat the mouth medicinally so as to change a susceptible case to one of immunity, but he assuredly can by instituting the proper line of prophylactic and operative procedures so influence the conditions as to at least control the disease and ultimately save the teeth. Not only this but he can by pursuing the proper course in the management of these cases so advance the period of immunity from generation to generation as eventually to limit the disease and bring it under easy control. It is frequently noted now that even where the deciduous teeth are extensively affected, if proper attention is given to the case the conditions are so changed that there is little

tendency to decay of the permanent teeth, and they may be saved without much demand for filling.

The future hope of the profession is in the study of conditions which exist in the mouth, and while the ability to properly perform operations is exceedingly important it is not more so than a close observation of the phenomena which influence disease and also which affect materially the outcome of our technical procedures. If we understand conditions we shall operate more skillfully, more intelligently, and the result of our work will redound to the greater credit of the profession and a more lasting benefit to those who place themselves under our care.

CHAPTER VII.

EXAMINATION OF TEETH FOR THE FINDING OF CARIOUS CAVITIES.

BY GARRETT NEWKIRK, M. D.

The practice of medicine in all of its departments may be comprehended in two great divisions: *First, diagnosis*—finding out what is the matter; *second*, the choice and application of remedies.

Physical exploration of the teeth for the discovery of caries might be styled *mechanical diagnosis*. It should be as carefully and thoroughly made as an examination by the physician for the diagnosis of disease. While it is not all of dentistry to discover carious conditions, and prepare and fill cavities, these constitute the larger part of its employment.

Every one who comes to the dentist for consultation and advice is entitled at once to a thorough examination of his teeth. He has a right to expect that no carious spot shall remain undiscovered. Every continuing patient should have such an examination at regular periods, and should be notified of the time if he fails to remember it. *Examinations at stated periods* are of the greatest importance with young people. They should be made in all cases at least twice each year; as a general rule once in three months; with some children, under special conditions, oftener.

A systematic record should be made not only of conditions requiring operations soon, but of those which threaten danger at some future time.

REGIONAL DIVISIONS FOR EXAMINATION.

First.—Those pertaining to lines of union (so apt to be imperfect) between the enamel plates, on the occlusal surfaces of bicuspids and molars, the lingual aspect of upper incisors, and in the buccal or lingual grooves of molars.

Second.—Gingival—regions bordering or beneath the gum tissue, particularly those upon the labial and buccal surfaces from the central incisors to the last molars.

Third.—Proximal—those surrounding and including the contact points of the teeth, particularly the surfaces immediately rootward from those points.

Fourth.—Marginal—along the lines of former operations, at the edges of fillings and crowns.

SYSTEM AND METHOD.

There should be a regular system of examination and a particular method of marking diagrams. The writer has adopted the following rules. The lower teeth are examined first, with the patient in a position nearly erect, so that when the mouth is opened the light from the window falls directly upon the field of observation.

Examination begins with the central incisor and proceeds to the last molar, first on the left, then on the right. For the examination of the upper arch the position of the patient is higher with the body and head inclined backward, so that as before the teeth meet the light fairly; and here the order of examination is the same. The diagram blank and a pencil should be on the bracket table, and a record made of each carious or suspected point immediately upon discovery.

CONDITIONS FOR EXAMINATION.

First, Cleanliness.—The first procedure for an examination of the teeth is to clean them. Not only must they be freed from calcareous deposits but as far as possible from stains. In no other way can every surface be brought to view and imperfections noted. The use of the scaler will often reveal points of sensitiveness or the hidden margin of a cavity. One should never pass an opinion as to the number and extent of cavities, or the probable cost of operations, till he has been permitted to put the teeth in a proper condition and make a recorded examination.

Dryness.—Cleanliness of surfaces having been assured, the next precaution necessary is freedom from moisture. No accurate examination can be made of a wet surface. The beginnings of decay are seen imperfectly or not at all through films of mucus and saliva.

For an examination of the upper teeth so far as may be without the use of the dam, a cotton roll, or strip of lintine, or a thick piece of spunk is laid between the alveolar process and the lip or cheek, while the patient is requested to keep the mouth steadily open.

Freedom from moisture for a corresponding examination of the lower teeth is not easily assured. The saliva ejector, valuable in all cases, is here quite indispensable. If the operator has no assistant the patient himself may render service. A long roll of cotton or muslin is held down on each side of the alveolar ridge. For the left side, assuming the operator to be right handed, he will hold with the forefinger of his

left hand the roll between the tongue and the ridge, the assistant (or patient) holding the other firmly between the ridge and the lip. On the right side, per contra, the assistant will hold the roll against the lingual side of the alveolar ridge, the operator that next the cheek.

After drying the teeth with spunk and warm air they are rubbed well with alcohol on cotton and dried again. Where secretions are specially viscid and hard to remove it is well to precede the alcohol with pumice. After this treatment the teeth present a different appearance. Pits and fissures are revealed in the occlusal, lingual and buccal surfaces; also shadows and color spots that often indicate proximal decay.

Having obtained dry surfaces, the operator with a good eye, sharp exploring instrument and a magnifying mirror, will be able to discover carious spots of all classes save one; but that one is perhaps the most insidious and dangerous of all—the decay which has its beginning close to and directly rootward from the contact point of a tooth. These are the decays that sometimes penetrate deeply with an opening so small as to be hardly discoverable by the finest point of an instrument. Unseen and unsuspected, their ravages proceed till a large extent of dentin is disorganized, and the enamel of the occlusal surface is so undermined that it breaks down suddenly under stress. These are the cavities that patients will tell us, "Came all at once," because so long as the enamel stood over the chasm there was nothing to indicate its presence.

A common practice is that of depending on the evidence of thread, passed between the teeth; but this alone is not conclusive. By the roughening or tearing of floss silk it is true that we suspect decay, though the rough edge of a filling, or tartar, may produce the same effect. *But the free passage of floss is not conclusive evidence of a healthy condition.* The surface of the tooth may seem perfectly smooth to the thread over a spot of unbroken, dead enamel and a sepulcher of dentin. In other words the thread will show us plainly very often where decay is, but is unreliable for determining where decay is not.

The only conclusive method is to get separation for vision and instrumental exploration. Where the slightest doubt exists as to the integrity of teeth at these points, the rubber dam should be used in association with the mechanical separator. With the dam in position we are certain of dryness, and there is no call for haste in the examination. From four to six teeth may be included at once, and their proximal surfaces examined in succession.

By the use of the mechanical separator, sufficient space may be

obtained nearly always in a few moments for a decisive exploration. A bit of space with a gleam of light makes a world of difference in the field of observation. Where before no sign of decay was seen, it may be that a speck of discoloration, brown or whitish will appear. A delicate steel point finds an opening, a sharp, thin chisel breaks the enamel roof, and the excavator possibly reveals a deep extension of decay. A condition such as this we have no right to overlook. *We should know positively, either that it does or does not exist.* We have no right to dismiss an examination with the word or thought, "I guess that's all right." It is our business to know. Opinions fathered by wishes have no value.

RECORDS OF EXAMINATION.

The dentist should keep himself supplied with pads of examination blanks such as are kept in stock by the supply houses. Each blank should exhibit a diagram of the teeth, both deciduous and permanent, with lines for name and date.

In some cases it is well to make the first record tentative—presumably incomplete. Pursuing the methods first described, the teeth are surveyed as thoroughly as may be without the employment of dam and separator. The diagram is marked for every cavity and fissure that is positively indicated, and at every proximal line where the least uncertainty exists an interrogation point (?) is placed.

After other operations have been concluded, the doubtful spaces are examined one by one with the aid of dam and separator. If there is found in one place nothing to do, well. If in another but superficial decay, it is polished and medicated with reference to the adage, "A stitch in time saves nine." If a cavity is discovered, separation is increased and a filling, temporary or permanent, introduced.

When all this is done the operator may truly feel that no interest in the case consigned to his care has been neglected.

CONCLUDING NOTES.

Special care should be taken to examine along the subgingival margins of gold crowns, especially those placed over teeth with living pulps, where the right preparation could not have been made and there was necessarily an ill fitting band. Also careful exploration should be made about the margins of Logan and other bandless crowns for caries that may have begun in the root. For a complete, visual examination of cavities beneath the gingival gum, a thin bladed retrac-

tor is convenient, and often it is necessary to control hemorrhage with carbolic or trichloracetic acid or adrenalin chloride.

Failure to examine for decay beneath fillings of unfavorable appearance is a common fault and followed often by serious consequences. The dentist is apt to take too much for granted as to conditions beneath fillings made of all sorts of mixtures that have gone under the general name of amalgam. We should not be prevented by a false conservatism from thorough examination in these cases. We should make doubly sure that our insidious enemy, caries, does not "steal a march" on us in the tattered uniform of a friend.

A small keen hoe or hatchet excavator will oftentimes penetrate a dead enamel wall and reveal a cavity better than a delicate pointed explorer.

No service rendered by the dentist should entitle him to better compensation on the basis of time than that involved in a careful examination of the teeth.

CHAPTER VIII.

SEPARATION OF TEETH PREPARATORY TO OPERATING ON CAVITIES IN THE PROXIMAL SURFACES.

BY GARRETT NEWKIRK, M. D.

Restoration *is the watchword of operative dentistry.* Simply upon the forms of the teeth depend their relations one to another and to their surrounding tissues, and together with color, their appeal to the esthetic sense.

Among the many considerations necessary in the restoration of tooth forms, and one of the most important, is that of the interproximal space. This has a definite relation to the forms and contact points of the teeth involved. For the first adequate study and presentation of this subject the profession is indebted to Dr. G. V. Black, through a paper read by him before the Odontographic Society of Chicago, and published in the *Dental Review*, 1890. Up to this time and for many years previous the best operators had often advocated the restoration of the natural forms of teeth largely as a matter of idealism, but none had grasped the subject in all its relations. Dr. Black set forth the importance of a normal interproximal space for the conservation of healthy gum tissue, to secure the best conditions of cleanliness, to prevent the lodgment and impaction of food, to allow the ready cleansing of the adjacent surfaces, to insure in large measure the permanence of fillings, to promote the comfort of the patient and satisfaction of the operator—all this depending of necessity on the true proximal contour of the teeth, in accordance with nature's plan.

Separation for dental operations, by whatever method, has for its object the assistance of the operator in the restoration of tooth forms, and the preservation therewith of healthy interproximal gum tissue. Without separation preparatory to filling, it is impossible to secure the necessary contours.

Separation may be of two sorts, first, by the slow pressure of some expansive material like wood, cotton, linen tape, rubber or gutta-percha, continued for hours or days, and denominated "previous;" second, by a driven wedge or one of the mechanical appliances, coincident with the operation of filling and styled the "immediate."

Both methods are valuable and necessary, each in its place. As a rule the previous should be followed by the immediate, for whatever space has been obtained beforehand should also be held during the several stages of operative procedure.

PREVIOUS—SLOW WEDGING.

The writer will say at the outset that the longer he continues in practice the less he depends on very slow wedging for the separation of teeth. He is more fearful than formerly of inflicting permanent injury to the tissues involved—viz., the pericemental membranes, the interproximal alveolar wall, and the over-lying gums. All these tissues will endure a certain amount of pressure with temporary displacement, and return to their normal positions unharmed when the pressure is removed; but the pressure should not be greater nor longer continued than is absolutely necessary to the restoration required. It involves primarily the question of blood supply—a diminution here and an increase there within the various parts involved. This may be illustrated by any one in a moment. Place the ends of your thumbs together so that the free margins of the nails overlap. Press these one upon the other alternately and repeatedly, and watch the blood pressure as it changes beneath each nail, the red and the white coming and going, one congested, the other anemic. This is precisely what takes place in the tissues surrounding the root of a tooth when pressure is brought to bear for separation. Ere long if pressure is not relaxed absorption begins. It follows, therefore, that whenever the "immediate" method of separation can be employed judiciously, it is the one to be preferred.

GUTTA-PERCHA.

Slight, non-irritating separation may be made to great advantage in many cases with gutta-percha, this being used at the same time as a temporary stopping.

As we know, it is often advisable, sometimes unavoidable, that such fillings should be inserted for a period of days or weeks. In these cases it is possible to make the material accomplish the double purpose of protection and separation. By the use of considerable force with a broadfaced burnisher as the material slowly hardens in the cavity, it may be so compressed as to make it elastic—like rubber, only in smaller measure. The effect will be increased if the gutta-percha is inserted while the teeth are held slightly apart by the mechanical separator, which should be kept in place till the filling is cold. Then, the gutta-percha answers well if it simply holds the space

obtained by the separator till the next sitting, when by re-application of the instrument the space may be increased, probably to the full extent necessary.

Gutta-percha is further useful as a separating material in that the gum tissue that sometimes overlaps the gingival margin of a cavity may be crowded back from the enamel edge—or from the cemental border of an extruded tooth—making possible a clearer view of the parts, and better preparation for the filling. But this must be done with extreme care, otherwise serious injury may be inflicted by over-pressure. Years ago it was advised by some to leave the fillings much over-full, in order that the material might be forced down and spread by the cusps of the occluding teeth, allowing it to remain for weeks or months. In some instances the effects of this practice were disastrous. The interproximal gum tissue was injured or destroyed, and articulation of the teeth seriously interfered with.

Whenever it is purposed to use a temporary stopping for separation, all over-hanging walls should be vigorously chiseled away and decayed matter removed from the cavity, both for medical treatment and to give a firm base for the pressure to be exerted. And, as a rule, it pays in satisfaction and efficiency to use the rubber dam.

In this connection it seems best to quote a paragraph from Dr. C. N. Johnson's work on the Principles and Practice of Filling Teeth: "To economize time in the management of these cases, it is well for the operator, on examining a mouth where several fillings are needed, to select these proximal cases at the first sitting and pack gutta-percha in each of them. He may then proceed with other work, and by the time that is completed some of the teeth thus wedged will be found ready to operate upon. The more stubborn cases may be left till the last, and, if necessary, the gutta-percha may be renewed in these as the other operations are in progress."

In speaking of this material it should be understood that the writer has in mind not merely that known as "sheet" or "base-plate," but the various kinds of prepared gutta-percha sold by the dealers in convenient form for use. They are easily worked but inferior to the old-fashioned sort in resistance to wear, and not so elastic. The gray gutta-percha is preferable to the pink only for its appearance in conspicuous places.

COTTON.

Among the first of materials used for separating teeth was *cotton*, in the form of compressed pellets, pressure depending on the absorp-

tion of moisture; and it is still used by some almost exclusively. As a separator merely it is more effective than gutta-percha, and may be preferred whenever a considerable space is demanded within a limited time. As a rule it produces no great soreness, and if the teeth are held steady by the mechanical separator during the subsequent operation, ordinary, careful malleting is well borne by the patient.

But the cotton pellet is of course unfit for a temporary stopping and should not be used for more than a day without change. If saturated first with sandarac varnish as it sometimes is, making it quite impervious to moisture, it is no better than gutta-percha for separating, and by no means so good a filling.

Cotton is particularly valuable for making space between the incisors, or between a cuspid and a lateral incisor. As a rule the pellet should be introduced from the lingual direction, and, with a thin-bladed instrument pressed toward the incisal borders of the teeth. It is readily seen that by crowding the material from the base toward the apex of the interproximal triangle we secure the advantage of two inclined planes along the teeth. Now, if first a piece of waxed thread shall have been introduced rootward, it may be drawn down upon the pellet, the ends carried through incisally and tied firmly so as to give additional compact to the material. Also the ligature prevents crowding out of the cotton toward the tongue or the lip, and the whole force of expansion will be directed against the teeth. As a form of cotton for this and many other purposes the writer is partial to "lintine" or "cottonoid," as bought in sheets.

RUBBER.

An easy method of separating—easy for the operator—is that of stretching and drawing between the teeth a piece of rubber, that may be cut from a good sized elastic band, or from strips of different thicknesses and widths supplied by the dealers. But these if kept long on hand deteriorate in quality and become worthless. In a small proportion of cases, with phlegmatic patients, where teeth have short crowns with long roots and are very hard to move, one may be justified in using a piece of rubber, narrow and not too thick—to get a "start" for the space required. Then, if the mechanical separator is insufficient, some other material should be used to induce further separation gradually.

Nearly always, if the elastic quality of rubber is depended on entirely for a considerable movement of the teeth, much annoyance or real suffering will be experienced by the patient, not only through

the period of wedging, but during the operations to follow. While not easy to account for, it is a fact of experience, that the pressure of elastic rubber between the teeth gets "on the nerves" of a great many people as nothing else will. One risk of using the rubber is that of injury to the gum tissue. As the material contracts labio-lingually it bulges into the interproximal space toward the gum, and indeed is likely to slip upon the surfaces of the teeth in that direction.

WOOD.

The wooden wedge for separating teeth has been much employed. Of the many woods recommended at various times all have been quite discarded except the orange wood, which is supplied in neat bundles by the supply houses. Where one suspects the presence of a small proximal cavity in a very close space, in the mouth of a sensitive person, where the insertion of cotton or gutta-percha would be difficult or ineffective and rubber inadmissible, where allowable force with the mechanical separator moves the teeth but slightly and an increase of space must be had by the slower process, then, in the slight space gained by screw force, we may insert a thin wedge of wood, by hand pressure merely or with one or two light taps of the mallet. The wedge may then be separated from the stick with cutting pliers made for the purpose. If, however, before its insertion a sharp notch is cut well around at the base of the wedge, it will afterward break off readily from the body of the stick, and, as a rule, with less jar than that from the pliers.

On removal of the separator the wedge is left snug in place, where by slow swelling under moisture it separates the teeth.

TAPE.

Some practitioners have been partial to waxed linen tape of various widths, for slow separation. The unrolled tape is dropped into hot beeswax, let cool, and is then stripped of adherent wax. With slow, persistent pressure, this thin tape may be crowded between the teeth, and usually without the aid of a mechanical separator. Otherwise, in place of the screw separator one may use a thin, narrow steel wedge, at the end of a strong handle, that the operator may if he chooses make for himself. This can be inserted near the necks of the teeth, and by hand pressure alone will induce sufficient space between the crowns for the insertion of tape or thin wood. The ends of the tape may be cut close with a very sharp knife or fine pointed scissors. The best scissors that I have found for this purpose, and that I keep

on the bracket for general use, is a small "manicure" pair with the extreme sharp point of each blade ground away.

Another method of preparing the tape is to dip it in a thin solution of gutta-percha in chloroform, and then let the chloroform evaporate. This leaves the tape permeated with a film of gutta-percha, which makes it very tough and impervious. It will therefore not deteriorate in the fluids of the mouth as rapidly as waxed tape.

It is well to remember that wherever slow wedging is necessary, the chief difficulty is overcome when the first slight space has been secured for a day.

THE MECHANICAL SEPARATOR.

It is axiomatic in the mechanical world that, wherever a certain thing is to be done in a particular way, a specific machine accurately made, and intelligently directed, will secure results more uniform and definite than are possible by the varying, individual hand method.

Operative dentistry consists largely of a series of mechanical problems, and, wherever conditions admit, the principle above stated holds good. To a celebrated business man has been accredited the statement that he never would do any sort of work himself that he could hire done as well or better by some one else. We may say in like manner of any mechanical operator that as a rule he cannot afford to do by direct effort that which may be better done by an intermediate mechanical contrivance. As a recent example of this principle we have the anatomical articulator, which eliminates much of experiment and guess work in the proper arrangement of artificial teeth.

The separation of teeth as considered within the scope of this chapter is a mechanical process, and we wish to know how far it may be accomplished by the application of screw and wedge forces, in a manner positive and definite. What are the requirements of such an appliance, and have they been successfully met?

First: The points of pressure must be aside and far away from the median line of the proximal surface; otherwise they will intrude upon the field of operation, or, if carried too far rootward will press dangerously on the interproximal gum tissue.

Second: The pressure having to be well aside from the median line, it should be upon both sides equally.

Third: As the separating applies to both teeth, there should be necessarily four distinct points of pressure at regular distances.

Fourth: The points must be far enough over the crown so that

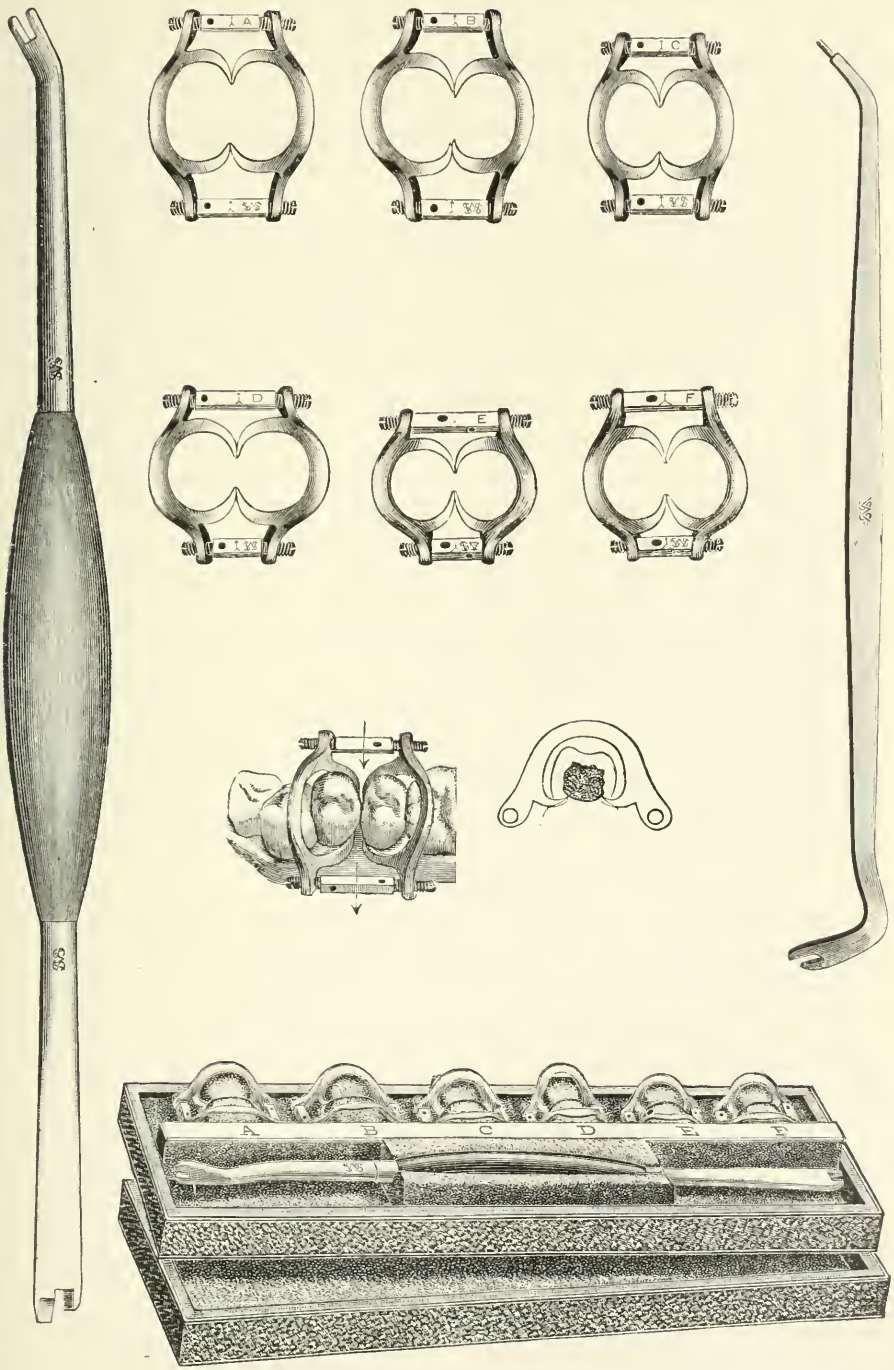

FIG. 106.—Perry Separators.

their tendency under pressure will be to move rootward, otherwise they would be likely to slip off; but they must at the same time be stayed, to prevent their going too far, with impingement on, and danger of injury to, the soft tissues.

Fifth: The four points make necessary two bars, each with a right and left hand screw, through which forces may be exerted alike in both directions.

Sixth: While the principle of the instrument is everywhere the same, proportions of the parts must vary for purposes of adaptation to the different forms and classes of teeth, considered in relation with their interproximal spaces. This fact precludes the construction of any so-called "universal" separator which shall be equal to the different forms, each in its special field. Either the "universal" will fail to meet all these requirements—for example, having points on one side only with an opposing wedge; or, it will be intricate and cumbersome, lacking the simplicity of the special instrument.

Just as possible a universal saw for the carpenter, or a universal pattern for a coat, as of one separator adapted to all parts of the mouth. It is altogether probable the one who owns a "set" of separators will employ one form or another much oftener, and with greater satisfaction in every case, than the possessor of a "universal" only. "The best is none too good," as relates to the instruments of operative dentistry. When one is selecting an appliance that ought to last throughout his professional life, he can ill afford to ignore this truth. It is here that the mistake of a moment is oft the detriment of years.

THE BEST.

The author has no hesitation in saying that the principles of mechanical separation have found their best expression in the "set" invented by Dr. S. G. Perry, originally four in number, now six. These various forms are marvels of ingenuity, adaptation and simplicity. Artistic of construction yet strong, there is slight chance of their being superceded.

The usual objection offered to the Perry set is that it is expensive; but, if we take into consideration both usefulness and durability, in the long run it will prove the best investment. Few dentists would think of going into practice without a good chair or first class engine; and yet, one might perform good operations over a plain arm chair with a head-rest. The writer is positive that he would rather use a cheap chair till he could make enough money to buy a good one, than to practice one month without the Perry separators.

Let us enumerate, briefly, some of the advantages and uses of mechanical separation.

First: In Examination of Teeth for Carious Cavities.

The important office performed by the separator in this connection has been considered in chapter VII.

Second: Preparatory to Slower Wedging and Temporary Stoppings.

Where it is evident that sufficient space cannot be had with the mechanical separator alone, it may be used to obtain room for the insertion of cotton, wood or gutta-percha; and in like manner for the introduction of gutta-percha as a provisional stopping.

Third: In the Preparation of Cavities for Filling.

Time and observation demonstrate to every experienced operator that faulty preparation is probably *the commonest fault of dentistry*. Back of this fault very often lies the fact of insufficient space—teeth that have had no separation; or having been separated have nothing to keep them apart for operations following:—For what sufficeth it to wedge with cotton or wood, and make no provision for holding the space obtained?

The mechanical separator will do this; and it will hold the teeth steady, so that the instrument employed, chisel, excavator or bur, can be used more accurately, and with less pain or shock to the patient. And the separator with four points generally is not in the way of observation, does not obtrude in the interproximal space, and holds the dam aside for the admission of light.

It is well to remember, however, that occasionally where wide lateral extension of a cavity is demanded, either for "prevention" or on account of existing decay, a point of the separator may impinge upon the field of operation. In such a case the instrument may be used for preparation of the main cavity and then removed. Before removal, however, if sufficient space exists for the insertion of a narrow wooden wedge, this may be employed to hold the space, both for the final preparation and the beginning of the filling.

Fourth: For the Insertion of Gold Fillings.

As in cavity preparation, the separator holds the teeth steadily in position for instrumental service in filling. It makes the use of the plugger more accurate and positive, and the application of mallet force less trying to the patient.

As a rule where a tooth is filled after "immediate" separation by one of the Perry instruments, with or without slight wedging before-

hand, the patient will not complain of any malleting necessary for the proper condensation of gold.

Fifth: In Connection with Porcelain Inlays.

The mechanical separator may assist greatly in securing access for cavity cutting and grinding, facilitates the removal of a matrix, or the insertion of an inlay, holds the teeth apart for the final finish of the work, especially in connection with the anterior teeth and cavities of moderate extension. It may also be used to gain space for the removal of inlays that have become loosened, and their re-insertion.

Sixth: Preparatory to Filling with Amalgam or Cement.

The separator gives the advantages before described for preparation and initial space. The teeth are held apart and steady up to the moment of applying the matrix, or with the use of a hand matrix the separator may remain in position.

Seventh: For the Finishing of all Proximal Fillings.

To give access for fine cutting instruments, finishing files, tape or disks, for proper "knuckling," there is nothing to compare with the Perry separators.

In Miscellaneous Conditions Requiring Separation.

Cases are presented where the interproximal space has been left unprotected, where the patient is distressed by food impaction with every attempt at mastication and the gums perhaps are continually congested and sore, in consequence of previous faulty operations. Such teeth are seldom firm in their sockets, and in many cases may be separated by the "immediate" method sufficiently for contour restorations. Not infrequently we find some foreign substance, a piece of wooden tooth-pick or berry seed perhaps, imbedded between the necks of teeth and hard to dislodge, or, as occurred recently in the writer's practice, one may discover a sequestrum of bone as the result of arsenical poisoning. In such cases the Perry instrument with its widely separable points will render valuable aid.

Final Considerations.—To adjust the mechanical separator easily and deftly requires practice, and the operator must not expect smooth sailing in every case at first. With the bicuspid and molar forms, the lip of the patient is likely to be lifted up uncomfortably. To relieve this at once a smooth steel instrument like the handle of an explorer should be inserted at the angle of the mouth and passed gently forward, lifting the lip over.

Whenever the separating points are going higher than they should, so as to crowd upon the gums, the screws should be relaxed and the

instrument held in proper position while gutta-percha is warmed and crowded under the bows. When this is hard (and cooling may be hastened with the chip-blower), the rootward movement of the points is prevented and separation may proceed. The screws should be kept well oiled, both for ease of working and to prevent their wearing out. They should be turned on beforehand till the points are at the distance apart that will just allow them to slip over the teeth. Then with but a little turning the instrument finds its true position, and the wrench has less to do within the mouth.

It is said that some are deterred from using the molar separator by what they consider the extreme difficulty of its application in connection with the rubber dam, for in most cases the clamp must be dispensed with. It is not hard to obviate this difficulty. Apply the dam as usual and the clamp temporarily. Then ligate, if necessary drawing knots of thread from both sides into the furthest interproximal space. After exchanging the clamp for the separator the rubber will rarely become displaced.

The writer has discovered that in certain unusual cases some forms of the separators may be used in a manner not shown by the "*Directions*." For example, one may find molars so small that the bicuspid form would apply—or a first molar so much larger than the second, or a second so much larger than the third, that the bicuspid-molar separator reversed—i. e., with the larger bow forward, will best meet the requirement.

Force should be applied always with immediate reference to the feeling of the patient—at first barely to the point where he admits that the pressure is uncomfortable—if really painful the screw should be turned back a little. One may say to the patient truthfully that in a few moments the feeling of undue pressure will pass off. Afterward as a rule there will be no objection on his part to quarter or half turns of the screws with intervals of rest between. Tact and caution on the part of the operator must never relax. The temptation to hurry and crowd must be resisted.

Here, as in relation with other operative procedures, patients have their idiosyncrasies. One will disclaim any sense of discomfort whatever, one will anticipate trouble that does not come, while another is truly hyper-sensitive and deserving of the most delicate consideration. Now and then, once a year possibly, a patient will present with whom the separator is impracticable by reason of unusual tenderness of the peridental tissues or general nervous timidity.

Much depends on the attitude of the operator in the first intro-

duction of any appliance that might excite the fears of his patient. If we show to the patient, older or younger, the necessity of space and the advantages of separation; if we assure him that we shall be careful not to carry the pressure beyond the point of reasonable endurance on his part; if we are painstaking further to consult with him or her as to the degree of force that may be easily borne, we shall have little trouble in the use of this most valuable assistant.

CHAPTER IX.

EXCLUSION OF MOISTURE FROM THE TEETH DURING OPERATIONS.

BY GEORGE EDWIN HUNT, M. D., D. D. S.

GENERAL CONSIDERATIONS.

The desirability of excluding the saliva from tooth cavities about to be the scene of operative procedures is based on four considerations. First, perfect dryness is essential *to secure cohesion of gold.* Second, the saliva is laden with micro-organisms, many of which in their life processes form by-products detrimental to tooth structure, and, therefore, exclusion of the saliva is necessary *that the tooth structure may be sterilized.* Third, saliva obscures and distorts the view of the walls and angles and dryness is desirable *that a perfect view of the cavity may be obtained.* Fourth, the dentin of teeth with living pulps is much more sensitive when wet and dryness is necessary *to diminish the pain of excavating.*

Before Dr. Sanford C. Barnum, of New York City, invented the rubber dam and gave it to the profession in 1864, dryness of tooth structure was obtained by the use of napkins, cotton and other absorbents. The exclusion of saliva by such means was necessarily of comparatively short duration and extensive operations with cohesive gold were impossible, although the more skillful practitioners in those days acquired a degree of dexterity in handling napkins and absorbents that is seldom seen among our contemporaries. Since 1864 nothing has been found to equal rubber dam for excluding the saliva during lengthy or intricate operations, although absorbents may be used in many short operations with perfect success if they are used intelligently. It is therefore necessary that the operator become skilled in the adjustment of the rubber dam, to the end that it may be used to the best advantage and with a minimum amount of annoyance and discomfort to the patient, to whom, under the most favorable circumstances, it is a trial. Many operators do not use the rubber dam as often as they should. This is usually due to the fact that the operator is unskillful in adjusting it and dreads the time and trouble his unskillfulness requires to place it in position. In this, as in all other manual operations, practice alone will bring ease of manipulation.

THE USE OF RUBBER DAM.

Rubber dam is classified as heavy, medium and light in weight, according to its thickness. Heavy and light dams each have their advantages and disadvantages. Heavy dams are less likely to be torn in adjustment, they will more often remain in place without the use of ligatures or clamps, and they are not easily caught up by revolving burs, stones, discs or other engine instruments. Light-weight dams are more apt to be torn in adjusting, usually require ligatures or clamps to hold them in place, and are readily caught up by engine instruments by which they may be torn or cut. However, owing to the conformation of the teeth, or their relation to each other, it is often difficult to adjust a heavy dam where a light one can be carried to place with comparative ease. Therefore, if but one weight of dam is to be used, a medium weight, which diminishes the disadvantages of the two extremes, is best. A light colored dam is preferable as absorbing less and reflecting more, light. Rubber dam, like all rubber, deteriorates with age and is sometimes ruined by the manufacturer in vulcanizing. A simple test for quality is to stretch it well with a thumb or finger and note whether it returns to its original shape without bagging or tearing.

Size and Shape.—For operations on the anterior six teeth a triangular shaped piece of dam will be found both efficient and economical. This may be obtained by cutting diagonally a piece from six to nine inches square, the long side to be against the upper lip when adjusted. For the posterior teeth a piece from seven to nine inches square will be found most useful. It is poor economy to use smaller pieces as the edges will be found to be in the way and imperfect exclusion of saliva from the exposed surface of the dam may result.

The Holes.—Holes permitting the passage of the tooth crowns may be made in different ways. Various sized single punches may be obtained from hardware or dental supply dealers or a triangular punch, capable of making three different sizes of holes, may be used. With these, the dam is placed on a block of wood and a hammer or mallet used on the punch. Very few operators now employ this method, however. The most efficient method is by the use of one of the improved rubber dam punches on the market, having a revolving steel disk with four or more round holes, varying from $\frac{3}{4}$ of a millimeter to 3 millimeters in diameter, which engage a pivoted cone-shaped steel plunger, punching the desired sized hole in the dam.

If a punch is not available, the rubber may be tightly stretched over the tapering round handle of a gold plugger, when the application of a sharp knife blade to the tense rubber on the side of the handle will

result in a clean cut, round hole. The size of the hole may be varied by nicking the rubber at a greater or less distance from the plugger end and a little experience will enable the operator to thus cut holes of any desired size. As a rule operators are more apt to use holes too small rather than too large.

The distance between the holes will vary in different cases, from 2 to 4 millimeters being the usual distance in medium weight rubber. The lighter the rubber the further apart the holes should be. In abnormal cases, where the teeth are separated or the gum tissue has receded, the holes may have to be much further apart. In normal cases, teeth with long crowns and presenting large interproximal spaces, require that the strait of rubber between the holes be wider than in cases where the crowns are short and the interproximal space small. These matters should be noted, for if the distance between the holes is greater than necessary, the rubber will bag in the interproximal space and be in the way, and if it is less than it should be the strait of rubber will slide down between the interproximal gum tissue and the proximal surface of one of the two teeth, exposing the gum tissue and causing a leak. This latter will also occur if the holes punched are too small, requiring excessive stretching of the rubber to encircle the neck of the tooth.

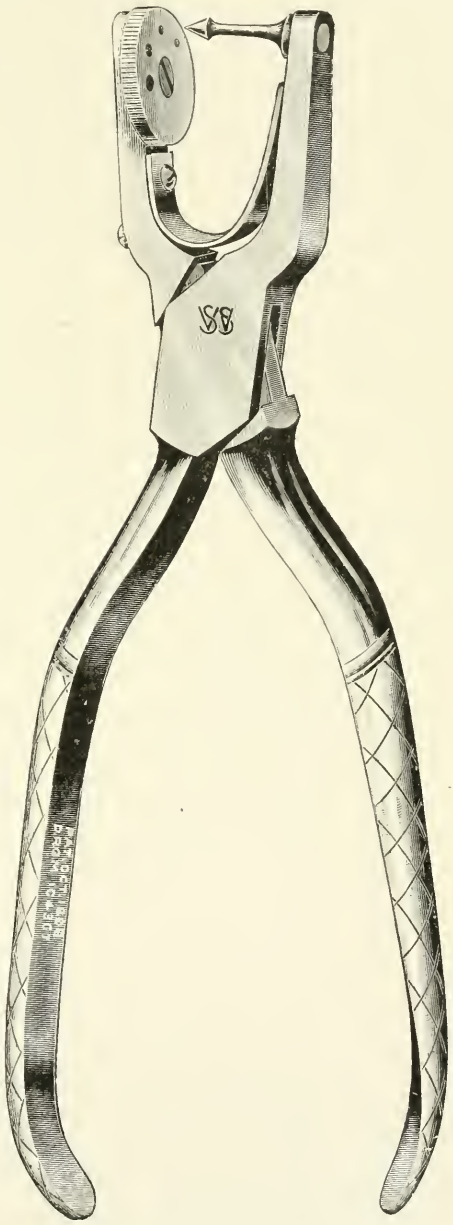

FIG. 107.—Rubber Dam Punch.

The location of the holes will be governed by the location of the tooth to be operated upon. In all cases the holes must be far enough from the upper edge of the dam to permit the rubber to cover the upper lip after adjustment. If the patient has a moustache, the holes must be far enough from the upper edge of the rubber for the latter to cover the moustache. But in no case should the rubber cover the nostrils or interfere with breathing through them. For teeth on the right or left of the median line a corresponding variation to the right or left of the median line of the dam is desirable and, in a general way, the curve of the holes should correspond to the curve of the dental arch. The novice should hold the rubber dam against the teeth to be isolated and note the approximate location of the holes necessary to have the dam cover both lips properly after adjustment.

The number of teeth isolated by the dam is a matter of importance. In those abnormal cases where the rubber is adjusted with great difficulty, owing to the shape of the teeth, wear on the occlusal surfaces, unusual resistive power of the facial muscles or other cause, and in treatment cases where the operation is short and easy of execution, the number of teeth isolated may be much reduced, sometimes even limited to the one tooth to be operated upon, but in nearly all cases several teeth should be included. This is desirable in that it gives better light and better access by getting the rubber out of the way and diminishes the danger of catching up the rubber in revolving engine instruments. The opportunity for error in operative procedures is sufficiently large without adding to it inconveniences within the control of the operator, yet many operators make the mistake of including too few teeth when adjusting the dam. In all distal surface operations the tooth lying distally should be included. In operations on the anterior teeth, for convenience sake, from four to six teeth should be isolated. In operations on the molars and bicuspids the teeth anterior should also be isolated up to and including either the lateral or central incisor. On account of its anatomy the cuspid is an unsafe tooth at which to stop. It has less of a constriction at the neck than any of the other teeth and the dam, whether ligated or not, is more likely to be worked crownwards by the action of the tongue and lips than with other teeth. For this reason, in operations on the lateral incisors the rubber should include the first bicuspid on that side and in operations on the bicuspids and molars should extend forward to one of the incisors.

Adjusting the Dam.—Prior to adjusting the dam, if the cavity reaches the occlusal surface or incisal edge, the operator should carefully note the articulation and the landmarks of mastication as a guide

for the fullness of his filling. If the teeth set very closely together and especially if the occlusal surfaces and incisal edges are badly worn, as in an "end to end" bite with the "ball and socket" tempero-mandibular articulation, a waxed thread should be passed between the teeth about to be isolated and all calculus and rough or sharp edges of fillings or cavities revealed by the fraying of the thread, removed and smoothed so the dam will not be torn. Dr. C. N. Johnson suggests that a thin broad instrument like a gum depressor or thin spatula, forced between the teeth and carried rootwards by a see-sawing motion, will smooth rough or jagged edges of enamel left by caries and permit the safe passage of the dam. A rubber or wooden wedge will also move the teeth in a few moments sufficiently to permit the passage of the rubber at any particularly difficult point. Just before proceeding to adjust the rubber the tooth crowns should be swabbed with a pledget of cotton dipped in absolute alcohol, to remove inspissated mucus, food debris or other infectious matter which might be crowded under the free margin of the gum in adjusting the dam.

On the anterior teeth and also on the posterior teeth when it is not intended that a clamp be used, the dam should be adjusted first over the tooth nearest the operator, taking the others in succession. By this method the best view of the field of work is obtained. The dam should be stretched labially or buccally and lingually by the thumb and fingers of the right and left hands and worked rootwards by a see-saw motion until the rubber is well down to the cervix and the strait between the holes is pressing down on the interproximal gum tissue. In performing this operation on the anterior lower teeth the operator stands at the right and slightly in front of the patient, the fingers of his right hand guiding the rubber on the labial aspect of the teeth, his left hand fingers within the oral cavity guiding the rubber on the lingual aspect. In adjusting the dam on the anterior upper teeth the position of the hands is reversed, the fingers of the left hand caring for the labial and those of the right piloting the lingual portions of the rubber. The position of the hands will be naturally suggested by the convenience of the operator in adjusting the dam on the posterior teeth, the right hand guiding the buccal and the left the lingual portions of the dam while operating on the left side of the mouth and the positions being reversed on the right side of the mouth. As a rule simply hanging the rubber on the teeth as described is all that is necessary at this time to keep it in position but if there is a decided tendency for it to slip off or to be thrown off by the action of the tongue and lips, a piece of waxed floss silk thread should be passed down the distal surfaces of the end

teeth beyond the point of contact. This will hold the rubber in place temporarily.

In difficult cases, where the teeth are closely in contact and have broad contact surfaces, or perhaps facets worn on the proximal surfaces, a little vaseline on the rubber between the holes will facilitate its passage between the teeth. Sometimes the use of a waxed silk thread by an assistant or by the operator is necessary to carry the strait of rubber rootward past the point of contact. In some cases the passage of the rubber can be accomplished by stretching it well and tilting it so the edge of the rubber strait presents at the point of contact instead of the width. If the rubber is securely hung over the first tooth or teeth and an especially difficult point is reached, it may be passed, care being used not to confuse the holes and tooth crowns, and the rubber adjusted over the remainder of the teeth, the operator finally returning to the refractory one. Occasionally difficulty will be experienced on account of involuntary movements of the cheek, lip and tongue muscles. Dr. C. N. Johnson recommends that the patient be given a hand mirror with which to view the operator's efforts. The patient's attention thus being directed to the difficulty, the muscles will usually be voluntarily relaxed. In obstinate cases, if this method does not succeed, the application of the dam should be limited to as few teeth as possible.

Having hung the rubber on the teeth temporarily the lower edge of the dam should be raised and a napkin placed in position over the lower lip so the dam will not come in contact with the lip or with the chin or cheeks, and napkin and dam secured by the rubber dam holder. A saliva-wet dam is a great source of discomfort and annoyance to the patient if in contact with the skin. The patient being fairly comfortable and the lateral edges of the dam held back out of the way, the operator is free to return to the adjustment of the rubber to the teeth.

To insure a saliva-tight joint the edge of the rubber must be turned rootward so it will pass between the tooth and the free margin of the gum. This can often be accomplished by simply stretching the dam labially and lingually and working it well rootwards before releasing it. Sometimes a flat instrument, like a spatula, run around the cervix, will turn the dam margin rootwards. Ligating the tooth will always accomplish this result.

Ligating the Teeth.—Ligatures and clamps should only be used when they are necessary to the success of the operation, but they are often necessary. If the carious cavity is a proximal one, the tooth should be ligated to insure security of the dam. For the same reason it

is well to ligate the tooth facing the cavity. Often the end teeth of those isolated will need ligating in order that the action of the tongue, cheeks, and lips may not force the rubber crown-wise. On molars and bicuspids, the clamp, as will be explained later, takes the place of a ligature on the tooth to which it is applied. In operations on incisal edges or occlusal surfaces, or in treatment cases it is often unnecessary to use ligatures at all.

The ligature should be a well waxed floss silk thread made for the purpose. If the interproximal space is large enough to permit of it, the ligature may be passed from labial or buccal to lingual between the point of contact and the interproximal gum tissue and returned in the same manner. Usually it is better to force it down between the approximating surfaces past the point of contact. Having passed it rootward down the mesial and distal surfaces of the tooth to be ligated, the ends should be gathered up and the portion embracing the proximal and lingual surfaces of the tooth carried rootward by traction, the rubber preceding the ligature. This will curl the rubber edge rootwards, as

FIG. 108.—Surgeon's Knot.

desired. Often this is all that is necessary for the retention of the rubber and the floss silk may be removed, or, in cases where the interproximal space is small and the point of contact well rootwards, the ends of the thread may be cut off close to the labial surface of the tooth and will retain the rubber in position by its wedging action. If complete ligation is desirable, the first part of a surgeon's knot (see Figure 108) should be tied and, just before it is drawn taut, traction again made rootward, supplementing this, if necessary, by carrying the thread rootward with a suitably shaped blunt instrument, as a plugger, used on the lingual surface. Having carried rubber and thread fully to the cervical constriction, the knot should be tightened and the tie completed. The free thread ends may now be cut off close to the knot with curved bladed scissors or, if an end tooth, a dam weight may be fastened to the ends of the thread and the weight passed back and left suspended over the patient's shoulder. This latter method assists in

keeping the rubber out of the way of the operator. The remaining teeth should now be ligated in rotation, as above described.

Dr. E. K. Wedelstaedt suggests an effective method of ligating. The first portion of the surgeon's knot is made on the lingual surface instead of the labial or buccal, and the thread ends again passed through the interproximal spaces to the labial or buccal. Strong traction is now made on the thread ends and the half completed knot on the lingual carried rootwards to the cervical constriction, with a suitably shaped blunt instrument. A full surgeon's knot is now tied on the labial or buccal surface, completing a double wrapped ligature.

Sometimes the action of the muscles or the shape of the crown causes the rubber to slip crown-wise over the ligature. This is most apt to occur with light-weight dams and in the molar region. To obviate it, from two to four glass beads may be strung on the ligature and arranged at effective points about the cervix of the tooth. Their bulk will prevent the rubber slipping over them. Dr. Fernandez suggests the use of short pieces of very small rubber tubing as being preferable to the beads. Dr. Wedelstaedt suggests tying a small roll of cotton in the ligature, to secure bulk. Usually a bulky knot, which may be tied in the thread before adjustment, on the lingual and the retaining knot on the buccal, will be sufficient.

To be effective, ligatures must encircle the tooth at the cervical constriction. Carrying them to position is painful in some cases and painless in others, owing to the extent the gingival gum tissue must be forced rootward to allow the adjustment of the thread. As a rule the pain felt quickly passes away as the tissue recedes before the pressure of the dam and thread, but if it is severe and the ligature absolutely necessary, the rubber should be everted sufficiently to paint the gum-margin with a two per cent solution of cocaine hydrochlorate. The ligature may then be painlessly adjusted and by the time the effect of the anesthetic has worn off, the gum tissue will have retracted sufficiently that pressure is relieved and further pain averted. No permanent injury to the gingival margin need be feared unless the force used in adjusting the ligature is brutal enough to tear and lacerate the tissues, and with ordinary care the margin will return to its original position a few minutes after the removal of the rubber.

In some cases, where there has been considerable recession of gum tissue and, perhaps, of alveolar process, and correspondingly large interproximal spaces present, instead of using ligatures, wads of absorbent cotton may be packed between the teeth, holding the rubber to place. Whatever method is employed, the operator should be care-

ful to remove all retaining material or appliances before attempting to remove the dam.

Clamps.—Clamps are used to hold the rubber on the tooth and to keep it out of the way of the operator. If properly selected and adjusted they are harmless and not particularly uncomfortable but if not so selected and adjusted they may be detrimental to tooth-structure and soft tissues, and very painful to the patient. If the clamp is too small, the beaks may bite into the enamel; if it is too large or does not fit the tooth, it may be forced rootward and impinge seriously on the soft tissues; if carelessly adjusted the gingival tissue may be severely pinched by the beaks. The beginner should try each clamp on the tooth and note that it encircles the cervix properly, before attempting the adjustment of the rubber. A clamp which fits the cervix, even when carefully adjusted, may crowd the gum tissue rootwards to some extent but, as with ligatures, no permanent injury will result and the tissue will resume its original position on removal of the pressure. Cocain may be used to deaden the pain of adjustment, if necessary.

Two forms of teeth are especially difficult to clamp successfully, those excessively bell-crowned, on which the clamp tends to slide rootward and impinge seriously on the gum tissue, and those short crowned teeth seemingly or really larger at the cervix than at any point crownward, from which the clamp tends to slip off occlusally. In both cases, a perfect fitting clamp will go far to remove the difficulty. Clamps have been devised for the bell-crowned teeth, with bows so arranged as to rest on the occlusal surface and prevent the slipping of the beaks rootward; and it has also been recommended that gutta-percha or other plastic material be placed between the clamp-bow and the occlusal surface, but none of these methods are efficient and a better plan is to dispense with the clamp and use a ligature. In many of the short crowned teeth it will be found that a cervical constriction exists if the beaks only reach it but that the gum tissue overlaps the cervix unduly. If this is not the case and the tooth-crown actually narrows occlusally, reliance must be placed on a perfect fitting clamp and caution during the operation that the clamp be not dislodged. In selecting the clamp for these cases preference should be given one with beaks having a decided rootward inclination, as is the case with the Ivory number 14. With such a form the beaks pass between the crown and the overlapping gum tissue until they reach the cervix, with a minimum amount of impingement on the soft parts.

There are many sets of clamps on the market, all with some merit and each with their advocates. Ordinarily the operator will use one

of a few standard clamps but a large assortment of special forms should be available to fit the extraordinary cases which occasionally present.

Usually the only tooth on which a clamp is placed is the posterior one of those isolated and in adjusting the rubber on molars and bicuspids, when a clamp is to be used, the operator should begin with the tooth furthest back and work forward. Having selected the clamp best adapted to the tooth, the rubber should be adjusted on that tooth and the clamp placed in position by means of the clamp forceps. The difficulty experienced in practicing this method is that in proportion as the clamp is needed for the retention of the rubber, it is difficult to keep the rubber on the tooth long enough to adjust the clamp. To obviate this some operators stretch the rubber over the bow of the clamp, adjust the forceps to the bow, gather up the rubber with the left hand and place the clamp in position on the tooth. The rubber is then stretched with the fingers until it slips under the beaks of the clamp and encircles the neck of the tooth. The objections to this method are that the rubber obscures the view of the tooth except in a few favorable instances where it may be held out of the way with the left hand sufficiently to permit of the crown being seen, and that stretching the rubber over the beaks often forces the latter down unduly on the soft tissues. The Ivory clamp was devised to meet these objections.

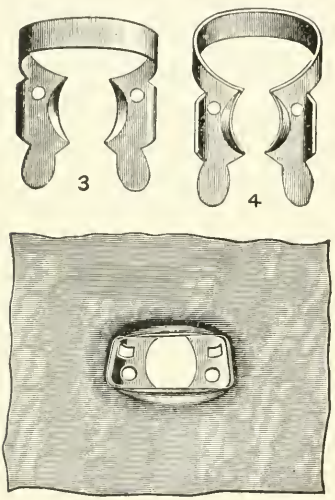

FIG. 109.—Ivory Clamps.

This clamp has buccal and lingual flanges on the beaks, so arranged that the bow of the clamp may be passed through the hole in the rubber and the latter hung on the two flanges. The clamp with the rubber in position is now taken up by forceps designed for this purpose and adjusted on the tooth, the rubber being so stretched over the flanges as to bring the tooth-crown into view as the clamp is carried to place. The rubber is then slipped rootward from the flanges and encircles the cervix. Mesial projections on the beaks keep the rubber from obscuring the view of the mesio-cervical portion of mesial cavities.

Cervical Clamps.—Buccal, labial and lingual cavities, with all

or a portion of the cavity lying rootwards from the cervical line, require the use of cervical clamps if any clamp at all is used. The wide range of location met with in these cavities renders it desirable that the operator have several forms of clamps to meet the differing conditions, although the mechanical improvement in some forms has been so great in recent years that they may be used successfully in widely varying cases by change of adjustment. The Ivory, Keefe and Dunn are all useful and have a considerable range of adjustment.

The use of cervical clamps is often attended by much pain, due to forcing the soft tissues rootward sufficient to allow the beak a bearing on normal cementum. If possible, the gum tissue should be retracted previous to the operation by packing the cavity with gutta-percha. If the cavity is not of a retentive form the gutta-percha may be held in position with a wire or thread ligature. In superficial caries where this is impossible, the soft tissues may be divided by a longitudinal cut and the flaps pressed out of the way. On completion of the operation the incised tissue should be pressed into apposition and gently massaged with the finger tip.

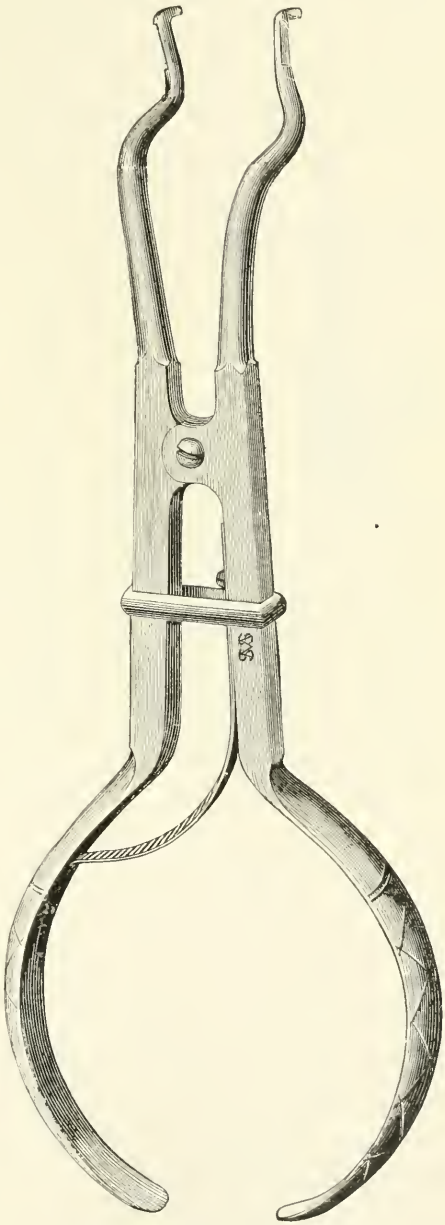

Fig. 110.—Brewer Clamp Forceps.

Rather than adjust a cervical clamp many operators hold the dam to place with a pointed instrument while filling the subgingival por-

tion of the cavity and still others prefer to use absorbents in a manner to be described later, using amalgam for the subgingival portion in molars and bicuspids, and pellets or cylinders of non-cohesive foil in the anterior teeth, afterward adjusting the rubber dam and finishing the operation with the filling material indicated for the case in hand.

In all cases where clamps and ligatures are used, as in all other steps in operations in the oral cavity, the comfort of the patient should be considered, and while the operator would grossly err in allowing his regard for the feelings of his patient to interfere with the perfect performance of the operation, it is often possible to save the patient annoyance and discomfort by the exercise of judgment and care.

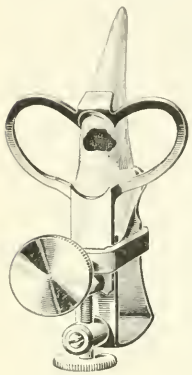

FIG. 111.—Ivory Cervical Clamp.

THE SALIVA EJECTOR, BIBS, ETC.

In some cases the required posture of the patient or the location of the adjusted rubber dam interferes seriously with the swallowing of the saliva. Operations on the upper molars, where the chin of the patient is elevated and the neck muscles tense, are examples of the first class, and the adjustment of the rubber on the lower molars illustrates the second class. In some cases, also, the mental state of the patient or the pain of excavation will result in an abnormal amount of saliva being delivered to the oral cavity. Whether due to larger amounts of saliva or to the inability of the patient to dispose of it by swallowing, the excess will drool from the mouth and should be cared for. Rubber bibs for the protection of the patient's clothing may be used or towels placed over the chest. The saliva ejector is of great help in these cases, by siphoning off the saliva. Occasionally a nervous patient will be found who objects to its use but many others will stand the pain of excavating and the strain of a long operation far better if they are instructed in the use of the ejector and allowed to manipulate it. The diversion of attention from the operation to the manipulation of the ejector is, of course, responsible for this.

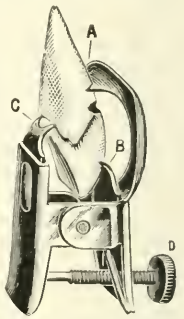

FIG. 112.—Keefe Clamp.

RUBBER CUPS, COTTON ROLLS AND NAPKINS.

As has been previously remarked, before the days of rubber dam, napkins and other absorbents were the only available means for the

exclusion of saliva. In later years some efforts have been made to increase the efficiency of the methods employed in using absorbents but, in the opinion of the writer, they have been futile. By the old methods, absorbents skillfully manipulated will exclude saliva in normal mouths for from twenty to thirty minutes, or longer, without distressing the patient. For short operations, such as redressing a pulp canal or inserting a temporary filling, this is more than ample time. The writer has seen large occlusal cavities in lower molars filled with non-cohesive cylinders and finished with cohesive foil while the saliva was excluded by the use of napkins. The subject of the exclusion of saliva by the use of other materials than the rubber dam may be divided as follows:—First, the use of rubber cups; second, the absorption of the saliva after it flows into the mouth; third, the prevention, partially or totally, of the delivery of saliva to the oral cavity.

Rubber Cups.—Rubber cups known as Denham's coffer dam shields, fashioned like the cups used for carrying pumice for polishing teeth, are used with some success for short operations. The base of the cup is of thin rubber. A hole is made in the base with the rubber dam punch and the cup adjusted on an Ivory or similar clamp. The clamp is then carried to place on the tooth and the rubber slipped over the flanges of the clamp as described in the use of rubber dam. In pulp canal treatment of lower teeth where the adjustment of the dam is particularly difficult, these cups may be used to advantage. The saliva ejector may also be used to assist in reducing the amount of saliva in the mouth.

The Use of Absorbents.—Absorbing the saliva after it flows into the mouth may be accomplished by napkins or by specially prepared rolls of absorbent cotton. The manner in which this is done will readily suggest itself to the operator. The roll or napkin is adjusted in a V shape with the free ends to the anterior, the bottom of the V just posterior to the tooth to be operated on and the roll resting against the buccal and lingual surfaces of the teeth. Special clamps, with large flanges, designed to clasp the roll or napkin and hold it firmly against the gums, may be had. Where this method of excluding saliva is efficient, the clamps are an advantage in that they permit the operator to use both hands. If the quantity of saliva delivered to the mouth is small, this method, in connection with the saliva ejector, may meet with success.

The Exclusion of Saliva from the Mouth.—The older operators depended far more on the exclusion of the saliva from the mouth than

on its subsequent absorption. This may be accomplished by stopping the salivary ducts at the point where they open into the oral cavity. For this purpose, napkins from four to five inches wide and about twelve inches long, are desirable. These may be cut from a piece of clean, bleached linen and thrown away after use. The napkin should be folded longitudinally until it presents a width of an inch to an inch and a half. For operations on the right side below, the patient should be instructed to raise the tip of the tongue to the roof of the mouth and the napkin adjusted across the mouth from left to right, the end resting against the lingual surfaces of the teeth on the left side. The tongue tip is then lowered and the free end of the napkin carried from right to left over the dorsum of the tongue. Rolls or wads of absorbent cotton are then adjusted between the buccal surfaces of the upper molars and the cheeks, closing the openings from the parotid ducts. The forefinger of the left hand resting on that portion of the napkin covering the dorsum of the tongue, is used to hold the tongue firmly against the floor of the mouth and the other fingers are used to hold the right cheek out of the way, the thumb being pressed firmly against the under part of the chin. If there is an excessive flow of saliva from the right parotid duct, the cotton covering it may be removed, when saturated, and a dry piece quickly and easily adjusted. This is, however, not often necessary. For operations on the left side below, the napkin is reversed, starting with the end resting against the lingual surfaces of the right teeth, passing under the tongue from right to left and over the dorsum from left to right. The forefinger of the left hand is now used to hold the left cheek away from the buccal surfaces of the teeth, while the other fingers depress the tongue and the thumb insures immobility by its position under the chin.

Occasionally a patient will be found whose tongue involuntarily resists the effort to depress it but that ceases under firm, steady treatment. The napkin over the dorsum permits the operator to compel obedience from the tongue muscles that would be impossible with the bare fingers against the bare mucous membrane. By this method the secretion from the submaxillary and sublingual ducts is kept out of the mouth completely. Care must be exercised in removing the napkin for the mucous membrane dries so thoroughly it might be injured by roughness or haste.

The difficulty in excluding saliva during operations on the upper teeth is much less. Here we only have the parotid duct to consider and the use of a napkin as described above under the head of the use of absorbents, is usually sufficient. It acts not only as an absorbent

but also lessens the quantity of saliva delivered through the parotid duct. In some cases it may be advisable to also use the ejector.

A form of tongue depressor consisting of a duckbill arm to rest on the dorsum of the tongue, a suitably shaped shield to rest against the under side of the chin, and a ratchet arrangement whereby the depressor may be locked when the relations between the tongue and shield are such that the tongue is fully depressed, may be bought of dealers in surgical instruments and Dr. Henry A. King, of New York, produced a similar device on lighter, more graceful lines, in 1904. If the patient does not object to their use, these instruments permit of the use of the napkin, as described, with both hands free.

CHAPTER X.

PREPARATION OF CAVITIES FOR FILLINGS.

BY A. E. WEBSTER, M. D., L. D. S., D. D. S.

Definition.—Under this heading is included all those operations which have for their purpose the removal of carious tooth tissue, formation of cavities for the reception and the retention of fillings and the extension of cavity walls to prevent further decay.

Nomenclature.—In every nation or class of people living and associating together is developed a system of signs or sounds by which ideas are communicated to each other. This is their language. In every business or trade or occupation there is similarly developed a system of signs, words and names which are used by those engaged in the same trade or occupation as a means of communication. These signs and names are termed the nomenclature of the trade or profession. Without such a code those in the same occupation would not be able to understand each other. So in the subject of the preparation of cavities it is necessary to have a system of names and signs which all must understand before communication is possible. The majority of the names used in the preparation of cavities will be familiar to those who have studied dental anatomy. Others will be defined. The nomenclature followed will be that adopted by the Institute of Dental Pedagogics.

Cavity Nomenclature.—Cavities in teeth take the names of the surfaces of the teeth in which they occur.

Labial cavities occur in labial surfaces.

Buccal cavities occur in buccal surfaces.

Lingual cavities occur in lingual surfaces.

Occlusal cavities occur in occlusal surfaces.

Mesial cavities occur in the surfaces of the teeth looking toward the median line.

Distal cavities occur in the surfaces of the teeth looking away from the median line.

Proximal cavities are those which occur in the proximal surfaces of the teeth.

Cavities which involve more than one surface take the name of the two or more surfaces involved, thus:

Mesio-occlusal cavities involve both the mesial and the occlusal surfaces.

Disto-occlusal cavities involve both the distal and the occlusal surfaces.

Mesio-labial cavities involve both the mesial and the labial surfaces.

Mesio-lingual cavities involve both the mesial and the lingual surfaces.

Disto-lingual cavities involve both the distal and the lingual surfaces.

Mesio-occluso-distal cavities involve the mesial, occlusal and the distal surfaces. Other combinations may be made to describe the location of cavities.

CLASSIFICATION OF CAVITIES.

Teeth usually begin to decay in defects of the enamel surface or on smooth surfaces not kept clean. Thus they may be divided into two general classes; pit and fissure cavities, and smooth surface cavities. Pit and fissure cavities do not require to be extended beyond the limits of decay or the defect in the enamel, while those on smooth surfaces usually require to be extended sufficiently to bring the margin of the filling to a point on the tooth's surface where it is kept clean either by the excursions of food or by the actions of the lips or tongue.

Pit and fissure cavities occur in the lingual surfaces of upper incisors and occasionally in cuspids, and in the occlusal surfaces of bicuspids and molars and the occlusal and middle thirds of the buccal and the lingual surfaces of molars.

The classification of cavities which follows requires a similar method of treatment for each class.

Pit and Fissure Cavities.—Cavities in the occlusal and middle thirds of buccal and lingual surfaces of molars.

Cavities in occlusal surfaces of bicuspids and molars and lingual surfaces of upper incisors and occasionally upper cuspids.

Smooth surface cavities occur in the surfaces not kept clean and may be classified as to location as follows:

1. Cavities in the gingival third of labial, buccal, and lingual surfaces.

2. Cavities in proximal surfaces of incisors and cuspids which do not involve the incisal angle.

3. Cavities in the proximal surfaces of incisors and cuspids which do involve the incisal angle.

4. Cavities in proximal surfaces of bicuspids and molars which do not involve the occlusal surface.

5. Cavities in the proximal surfaces of bicuspids and molars which do involve the occlusal surface.

NOMENCLATURE OF THE INTERNAL PARTS OF CAVITIES.

The surrounding walls of a cavity take the names of those surfaces of the teeth toward which they are placed, thus an occlusal cavity has a mesial wall, a buccal wall, a distal wall, a lingual wall and a fifth wall which is known as the pulpal wall.

The pulpal wall of a cavity is that wall which is occlusal to the pulp and at right angles to the long axes of the tooth. If the pulp be removed the floor of the pulp chamber becomes a wall of the cavity and is known as the sub-pulpal wall. In cavities occurring in the axial surface that wall covering the pulp is called the axial wall and if the pulp be removed the wall takes the name of the wall of the pulp chamber. Cavities in the axial surfaces of teeth have mesial and distal, or buccal and lingual walls, and an occlusal and a gingival wall, and an axial wall.

In complex cavities which involve the axial and occlusal surfaces the gingival wall is termed the seat of the cavity and the pulpal wall is known as the step.

For purposes of convenient description cavities in teeth are supposed to be cuboid in form.

Where two walls join, a line angle is formed taking the name of the two walls entering into its formation, thus: Bucco-pulpal line angle or gingivo-axial line angle.

Where three walls join, a point angle is formed taking the name of the walls entering into its formation, thus: Gingivo-labio-axial point angle or gingivo-linguo-axial point angle.

The enamel wall of a cavity is that portion of the wall between the cavo-surface angle and the dento-enamel junction and includes the thickness of the enamel.

The dentin wall is that portion of a cavity which is lined with dentin.

The enamel margin includes the whole outline of the cavity and is equivalent to the marginal line of the cavity.

The cavo-surface angle of a cavity is the angle formed by the junction of the wall of the cavity with the surface of the tooth.

THE PLANES OF THE TEETH.

The horizontal plane is at right angles to the long axis of the tooth.

Mesio-distal plane is parallel with the long axis and passes through the tooth from mesial to distal.

Bucco-lingual plane is parallel with the long axis and passes through the tooth from buccal to lingual.

The bevel of the cavo-surface angle is reckoned from the plane of the enamel wall.

DIVISIONS OF TEETH AND CAVITIES.

For convenience of locating a cavity on the axial wall of a tooth the tooth may be divided into thirds, and known as the occlusal third, middle third and the gingival third. Cavities in teeth may be divided in the same way either in the horizontal plane or in the mesio-distal plane, thus: A buccal cavity is located in the gingival third, in the horizontal plane and in the middle third in the mesio-distal plane.

STEPS IN CAVITY FORMATION.

The beginner in any mechanical work does not at once arrive at the best and most expeditious methods of procedure. But after a time if he be an observing person he will fall into an order of procedure which he will follow more or less rigidly. Hence it is important that he should at first at least follow those who have had opportunities of developing the best methods. The Institute of Dental Pedagogics has given the following steps in cavity formation as those fulfilling the greatest number of requirements.

1. Establish the outline of the cavity (outline form).
2. Remove the softened decay.
3. Give the cavity proper form. Which includes convenience form, resistance form and retentive form.
4. Bevel and polish the enamel wall.
5. The final touches or the toilet of the cavity should include a careful observation of the condition of the tooth tissue over the pulp and a thorough cleansing of the cavity surfaces.

General Consideration of Outline Form.—Before a dentist is justified in undertaking the treatment of a patient's teeth for the purpose of eradicating present caries and the prevention of future decay he should consider well all the factors which enter into the causation of decay and its prevention. The family history and the personal history of caries are of value in deciding the character of the operations to be performed. In some families even though

there be many cavities while young, they yield to treatment and fillings have a degree of permanency not found in others of more favorable appearance. Then again caries in some families rarely appears before the fifteenth year while in others it begins at the appearance of the deciduous teeth. Caries will cease at the twentieth year in some families and not recur until perhaps the fiftieth year or perhaps not at all. Patients giving a family history of immunity after a certain age and a personal history of immunity at the same age need not have what are sometimes called heroic operations done for them. The greatest attention in such cases should be given to the prevention of present decay rather than that which may occur in the future.

Such conditions might influence to a large extent the location of the cavity margins. The physical, mental, and personal habits have a great influence on the character of operations that should be performed. Many patients apply for dental treatment who are not in a fit physical condition to have ideal dental operations performed. A dentist would be lacking in judgment who would ask a frail girl maturing into womanhood to submit to having the outline of many proximal cavities carried through sensitive tissue to bring them to a clearing margin. Then again there are those who are so weak mentally that it takes careful management to preserve their teeth at all. They think they cannot bear anything in the way of inconvenience. Such patients need the strong controlling force of a man who knows just how to handle them before he may venture to do ideal operations.

Some patient's teeth are kept perfectly clean apparently without an effort. They eat proper foods and masticate them well, which is a factor in preventing caries. Almost all surfaces of the teeth are kept clean and are consequently immune to caries. If caries does occur the cavity margins do not require to be extended appreciably to meet areas which are immune. Others have teeth which always seem to have what might be called a scum over them, with cavities occurring in every defect of enamel and on surfaces which would be immune in other mouths. Where decay seems so progressive, cavity margins must be extended until they reach the immune areas of the tooth's surface even though much of the surface must be covered by filling.

The very appearance of the mouth often helps the operator to choose the character of operation. A certain viscid tenacious saliva, abundant in quantity, usually indicates rapid decay and demands that the outlines of the cavity should be extended far beyond the areas of contact with the other teeth. Many points of white or yellowish-white decay on smooth surfaces especially in labial, buccal, and lingual

surfaces is indicative of a marked susceptibility and demands free extension of cavity outlines, while if the cavities be dark brown or black in color and are found only in fissures the outlines need not be extended so freely. Because of the difficulty of keeping irregular teeth clean cavities in such cases should be extended fully. It resolves itself into this, in all cases where decay occurs, that part of the tooth's surface which is not kept clean about the cavity should be included within its outline.

1. *The outline form* is the form of the area of the tooth's surface to be included within the outline of enamel margins of the finished cavity. The first step in the preparation of any cavity is to decide as far as possible the extent of the caries which in a measure helps to locate the outline of the cavity. The extent of the caries helps to locate the outline only in simple pit cavities, and those occurring in exposed surfaces and those which are so large as to have involved all the defects of enamel and susceptible areas of the tooth's surface under consideration. To find out the extent of the caries it is necessary to break down the enamel not supported by dentin except perhaps where it may be left for esthetic reasons as in labial and buccal cavities in incisors, cuspids and bicuspids. The loosened and soft decay may be removed and the cavity washed out with a stream of tepid water. This will so clear the field of operation that a better judgment can be made as to the amount of sound tissue remaining, the condition of the pulp and the proper location of the outline. In the further preparation of the cavity it is well to have the rubber dam in position or use some other means of keeping the cavity dry.

(a) **In fissure cavities** the outline must include all the fissures and angular grooves radiating from the caries even though the cavity be but small. Such a cavity usually begins because of a defect in the continuity of the enamel surface and if only the carious portion be removed and a filling inserted the defective fissures remaining are just as likely to decay as originally. It is found that unless filling materials are polished flush with the enamel surface the thin edge left over the margins will likely be a point of leakage and later decay. If angular grooves are left radiating from a cavity it is impossible to so polish the filling that none will be left over these margins, hence it is better to cut them out and include them in the cavity.

(b) **Superficial defects** of the enamel about cavities should be cut out until sound enamel is reached and in some cases until full length rods are reached. In many cavities occurring about the gum margins there is an area of whitened or defective enamel passing around

the tooth which if not cut out and included in the cavity will decay in a short time and cause the loss of the filling, and perhaps the confidence of the patient in filling operations. In some of these cases the outer ends of the rods are worn away or lost by the effects of superficial decay and are likely to cause the failure of the filling if the margin pass across it.

(c) **Extension for Prevention.**—The general rule laid down for locating the margins of cavities which occur in proximal surfaces is to extend them to such a point on the tooth's surface that the joint between the filling and the enamel may be in immune areas. There may be some exceptions to this rule in rare cases but if cavity margins are allowed to come against adjoining teeth the fillings cannot be considered more than temporary.

Any one who has practised dentistry for more than a few years cannot help having observed the wisdom of extending all proximal cavities buccally, lingually, and gingivally far enough to bring the margins to such a point on the tooth's surface as will ensure their being kept clean or protected by healthy gum tissue. It makes but little difference whether the cavity be small or large in a proximal surface the outline should be well beyond any contact with the adjoining tooth. This extension of cavity walls through sound tissue to bring the margins to immune areas is known as extension for prevention.

(d) **A developmental groove or another cavity** should not be allowed to come too close to enamel margins. It is better in such cases to cut out the groove and include it in the cavity. The rods of the enamel in such cases usually stand at right angles to the surface which is faced away from the cavity, so when the cavity is prepared they are left without support. If only a small portion of enamel be left between a cavity and another filling it is almost certain to become a source of weakness to both fillings. Such enamel is usually more or less undercut and unsupported by dentin and the seat of fracture during the insertion of the gold.

(e) **The buccal and lingual margins** of proximal cavities in bicuspids and molars should be as nearly parallel as possible and at right angles to the seat of the cavity. Such a preparation makes the gingival wall more accessible to start and condense the first portion of the filling. Besides it brings the outline into full view during the building of the filling. If these margins and the walls of the cavity adjoining them are parallel the filling material as it is condensed will not draw away from the margins as in divergent walls, or tend to fracture the tooth as in convergent walls.

(f) The outline in all cavities should be *straight lines* or *regular curves* because it is much easier to adapt a filling material to a regular margin than to an irregular or ragged one. Besides they are said to be more esthetic, which is doubtful, but at all events they look more like the work of a good mechanic.

Technique.—To obtain the proper outline of a cavity it is necessary to break down and remove all enamel not supported by dentin. The straight chisel in the hand well guarded against slipping will cut away enamel readily if the edge of the blade is made to insinuate itself between the rods. The force should be applied in the direction of the long axis of the rods. In some cases the sharp edge of the blade may be placed against the wall of enamel and the edge snapped off piece by piece (Fig. 113). In others the edge of the chisel may be placed against the enamel and given a quick decisive blow with a mallet which will readily fracture the enamel (Fig. 114). It is well to be careful not to attempt to cut off more at once than will easily be cleaved away on account of the shock from the mallet which may be painful to the patient and come with such suddenness as to cause doubt of the operator's skill. A chisel in the automatic mallet will often break enamel, but like hand pressure it is difficult to control. A chisel in an engine mallet will break enamel rapidly and is under control but violent on the patient if a blow is given against the enamel which does not chip off. The final planing of the enamel wall to bring it to evenness must be done with a chisel. Cavities in proximal surfaces which require extension through sound tissue are best enlarged by cutting the dentin out under the enamel with a comparatively small bur and then breaking down the enamel with the chisel.

Fig. 113.

Fig. 114.

Fissure cavities can be extended in undecayed enamel by cutting a narrow slot through the groove with a small dentate fissure bur ground at the point on two sides to make it into a drill. A wornout, inverted cone bur ground to the same form will cut equally well. If the hand-piece be given a swaying motion and the point kept sharp even perfect enamel can be cut rapidly. If it be found that the dentin is not very sensitive the drill point may be directed rather under the enamel which seems to undermine it and allow it to cut easier. It is important that the drill be small, a large drill imparts too much jar to the tooth. Even the smallest size of an inverted cone bur so ground will serve every purpose because once the enamel is broken the edges may be chipped

in with a chisel or a hatchet excavator. In certain large distal cavities in molars the buccal and lingual walls cannot be reached with a straight chisel and a curved chisel with a narrow blade cannot be controlled if force enough be applied to fracture the enamel. The blade is almost certain to drop into the cavity and touch sensitive dentin or perhaps wound a living pulp. An instrument made on the form of a broad axe, with the blade short and wide and parallel with the long axis of the shaft will successfully break such enamel walls without danger to the pulp or the gum tissue.

In smooth surface cavities in exposed positions the outline may be extended with dentate inverted cone burs by placing the base of the cone against the axial wall and carrying the corner of the bur under the enamel. In this way the foundation of the enamel is cut first leaving it easily cleaved away.

The final trimming or planing of the enamel wall is done with broad bladed chisels holding the width of the blade parallel with the long axis of the rods. Black's side instruments will shave the buccal and lingual enamel walls of molars, while the gingival is best reached with a Darby-Perry chisel. The enamel walls of pit and fissure cavities are best trimmed with fissure burs run rapidly and held at right angles to the pulpal wall.

2. *Softened and decalcified dentin should next be removed from the cavity.* In certain rare cases a portion of hard, discolored dentin may be left when its removal would expose a living pulp. In such cases a non-irritating disinfectant should be used for sufficient length of time to insure disinfection before the filling is inserted.

Technique.—The manner of removing the remaining decayed tissue depends upon the character of the tissue, the size and location of the cavity and the sensibility of the dentin. In shallow cavities in exposed surfaces where the dentin is usually sensitive a deep decisive cut with a hatchet excavator in one corner of the cavity, followed by prying up or scooping out of the tissue in one layer is less painful than to attempt to remove the tissue in small pieces. In large cavities when the decay reaches close to the pulp it is better to go around the edges with spoon excavators flaking up the decay and peeling the layers off without making much pressure. After the decayed tissue is well removed down to the solid dentin at all points except where the pulp comes nearest to the cavity, then take a large spoon excavator and carefully scrape away the decalcified dentin until hard tissue is reached. This can be done without pain to the patient if little or no pressure is applied. Usually in these cavities it is the dentin at the

dento-enamel junction which is most sensitive. In certain cavities of dark brown or black decay where the tissue is hard, as occasionally occurs in occlusal cavities in molars in old patients, the decay may be most rapidly removed with burs. In no case should burs be used close to the pulp. In fact burs are of little or no value in removing decayed tissue except where it is hard. Spoon excavators are of most general use, though hatchets and burs may be used in special cases.

3. A cavity may be considered of proper form when it is so shaped that it can be conveniently filled, when it will retain the filling and when its walls will resist any stress which may come upon them.

(a) **For convenience** a cavity should be so formed that all its walls may be seen directly or brought into view with the mouth mirror. Grooves and undercuts should be avoided in a completed cavity form. They are always difficult to fill and add very little to the retention of the filling, and are a source of weakness to the walls. Line angles and point angles should not be so small and acute that instruments cannot reach their depths. Proximo-occlusal cavities in molars and bicuspids are in their most convenient form for filling when they are so shaped that they will retain the filling and resist the stress of mastication. If such cavities have a flat seat and step, parallel buccal and lingual walls and a dovetail in the occlusal surface, they are then convenient to fill with whatever material is desired. Cavities in incisors and cuspids require perhaps some slight modification of a gingivo-labio-axial point angle and gingivo-linguo-axial point angle to make it possible to more conveniently start a gold filling. These angles are made more acute and the corner is cut more deeply than is necessary for retention. They may be truly called convenience angles. In some cavities difficult of access it is often more convenient to cut away a wall or to extend an outline so as to bring the walls into full view. The labial surfaces of incisors and cuspids should not be cut away for convenience of access to a small proximal cavity. In the majority of these cases it is better to separate the teeth until access can be had to properly prepare the cavity and insert the filling, while in other cases the lingual surface may be cut into for convenience of access.

Technique.—The general technique of obtaining the outline form having been described it is not necessary to discuss more than what is specially done for convenience. A cavity with a good outline is easily filled. In many cavities having penetrating decay it will often be more convenient to fill any irregularities or pits not used for retention with cement, leveling up the walls. Often a buccal plate of enamel in a

mesio-occlusal cavity in an upper bicuspid is left for appearance sake though the dentin is gone from beneath it. The loss of the dentin leaves such a deep groove at the junction of the axial and buccal walls that it is very inconvenient and difficult to fill it with gold. In such cases it is much better to fill the grooves with cement and square up the buccal and lingual walls so that they may be parallel. For convenience of starting a cohesive gold filling in proximal cavities in incisors and cuspids a No. ½ or No. 1 inverted cone bur, which is held parallel with the long axis of the tooth as it is carried from labial to lingual to form a flat seat for a filling, may be swayed toward the labial as it is carried to the labio-gingivo-axial angle, and as the bur approaches the depth required it should be swayed to the lingual and carried slightly toward the incisal. By this movement a deep acute angle is cut which has the general direction of the greatest amount of tooth tissue avoiding the pulp. This acute angle is in a like manner cut in the gingivo-linguo-axial angle. With acute angles cut in opposite walls in the seat of any cavity there should be no difficulty in starting a cohesive gold filling. These may be truly called convenience angles though they are large enough to assist in the retention of the filling. These angles are easily filled and securely hold the gold in position while more may be built upon it. The small pits drilled at random in the seat of the cavity as has been too often the practice are difficult to fill and not always secure when filled. There seems to be a growing tendency among operators who do not wish to expose gold on labial surfaces to cut the lingual surface freely away, making a dovetail in the enamel for retention. This is really a convenience form.

(b) **Resistance form** is that shape given a cavity intended to afford such a seat for the filling as will best enable it to withstand the stress brought upon it in mastication. Its importance depends upon the area of the surface of the filling exposed to occlusion, and the strength of the closure of the jaws. The general rule in foundation construction is to keep as nearly a flat base as possible. Foundations made to resist heavy weights and tipping stress are flat. A cone-shaped base in a pulpless bicuspid or molar decayed mesio-occluso-distally has often been the cause of a fracture of the root. In such cases the filling acts as a wedge, cleaving the weaker wall. The seat of occlusal cavities should be flat and at right angles to the stress coming upon it, likewise cavities in proximo-occlusal surfaces of molars and bicuspids should have a flat seat and step to resist the heavy stress of occlusion and the tipping stress which comes upon

these fillings. It is not often realized by operators how much stress some fillings may be called upon to resist. In strong men a single molar may occasionally have a force of from two hundred to two hundred and fifty pounds applied to it. The closure of incisors of course is much less, but the anchorage for a filling in these teeth is less. The biting off of a crust of bread and its mastication will involve a pressure of from 100 to 150 lbs., while an ordinary beefsteak requires seventy-five pounds of pressure on an area the size of the human teeth to cut through it. In accidents of a piece of lead in canned goods, or shells or bones in flesh, a filling may receive the whole weight of the closure. Pulpless teeth, crowns and dentures have much less force applied to them than normal teeth. It would seem that when the pulp of a tooth is lost the pericemental membrane loses some of its power to resist pressure without injury. Hence fillings antagonizing with pulpless teeth crowns and dentures need not be so securely seated as those opposing sound teeth. In deciding what amount of seating a filling should require the force of the closure of the jaws must be well studied. Also the teeth antagonizing the filling and the area of the filling exposed to occlusion. It is obvious that labial, buccal, lingual, and small proximal cavities in incisors and cuspids do not require to be securely seated because the surfaces of these fillings are not exposed to the forces of mastication. No one thing has done more for the stability of fillings than the study of the forces of the closure of the jaws and the introduction of proper methods of seating fillings to resist that force.

Technique.—The inverted cone bur, the fissure bur, the chisel, the hatchet and the hoe excavators are the only instruments which can be used to form a flat seat in cavities to resist the force coming upon the filling. Round burs and spoon excavators have no place in forming the seat of a cavity. The seat, the step, and the lateral walls must be definite, joining each other with right angles or acute angles. The seat in molar and bicuspid cavities may be cut flat from buccal to lingual and from the enamel margin to the axial wall with an inverted cone bur about one millimeter in diameter. As this bur is carried back and forth from buccal to lingual there is often some difficulty in keeping it from jumping out of the cavity, and perhaps winding up the septum of rubber dam between the teeth, or wounding the gum, or perhaps cutting dangerously near the pulp. The difficulty of holding a bur in such a position is increased with the increase of the size of the bur and also by placing it in the right-angled handpiece. If, after all the overhanging enamel is broken down and the

softened decay removed, the Ivory or Hinicker matrix be adjusted, a bur can then be held in the base of the cavity without fear of accident in one direction at least. It is generally well to use a small bur, cutting the dentin only, and then cut away the enamel with Black's side instruments or Darby-Perry chisels. This will leave a wide flat seat. The step is usually partly formed with cement and as the last part of its formation an inverted cone bur in the right angle may be carried over the whole step. The seat of incisor cavities is formed in the same way only using much smaller burs; about a half millimeter inverted cone is more suitable for laterals and some centrals.

(c) **Retention form** is that shape given a cavity which will prevent the filling from being dislodged. This is largely provided for in the resistance form and to some extent in the convenience form, but in certain cavities the filling might resist the direct stress upon it and yet be easily displaced with slight lateral force. Retention form is provided for in proximo-occlusal cavities in molars and bicuspids by a dovetail in the occlusal surface and by providing parallel walls or perhaps walls slightly undercut. Proximal cavities in incisors and cuspids which do not involve the incisal angle do not need more than a flat seat deepened at the gingivo-labio-axial and gingivo-linguo-axial angles, with a slight undercut at the junction of the labial and lingual walls at the incisal. Cavities which involve the incisal angle should be provided with a step if much stress is to come upon the fillings. For many years operators have been chiefly concerned in the retention of fillings, only having regard to what might tip them from the cavity, not thinking that the greatest force in dislodging fillings is the direct stress of the closure of the jaws. The more fillings failed the more and the deeper were made the pits, grooves and undercuts. The pits did not contain enough filling material to have strength to resist the stress, and the grooves and undercuts often cut clear through the dentin, leaving only the enamel for retention which frequently fractured. The thoughtless operator has an idea that if he uses a large round bur in the center of the tooth making the cavity larger inside than at the margins the filling cannot get out. This might succeed if the enamel were not so friable when unsupported by sound dentin. The surest way to make a cavity which will retain a filling is to study carefully the forces which may come upon it to dislodge it. Estimate the strength of the cavity walls and then so shape the cavity that its seat or foundation will be opposite the stress applied and its retention cut in the direction of the greatest amount of dentin, and if undercuts are used place them in opposite walls of the

cavity. In general the retention should be as near the point of stress as possible, and the area of the seat and step equal to the area of the filling exposed to the occlusion.

Technique.—A cavity is usually shaped to resist tipping stress with the same instruments as are used to make the resistance form. Occlusal cavities in molars and bicuspids require parallel walls, and at opposite points a slight undercut which can be made with the inverted cone bur as its shaft is held at right angles to the pulpal wall. The only force which might remove this filling would be a lifting force from the adhesion of some sticky substance such as taffy. Proximo-occlusal cavities in molars and bicuspids cannot be retained to any extent by grooves or undercuts. The dovetail in the occlusal surface which is easily cut with a cross cut fissure bur or inverted cone bur is all that is necessary. In some bicuspids retentive form may be obtained in the occlusal surface by deepening the step at the point farthest from the proximal cavity with an inverted cone bur slightly undercutting the buccal and lingual walls. Proximal cavities in incisors and cuspids may have grooves extending out from the point angles for retention. As the inverted cone bur is sunk into the angles it may be carried up the labial and lingual walls a short distance making a groove. In many of these cases an obtuse angle hatchet or hoe may be used to cut a definite angular groove in these walls. The retention towards the occlusal is best cut with a small contra-angled hatchet excavator. No. 27, S. S. W., is a very suitable size.

4. *The proper bevel and polish of the enamel wall* of a cavity is of prime importance because the permanency of the filling depends so much upon the joint between the filling and the tooth. A good working knowledge of the histology of the enamel is essential to obtain the correct bevel of the enamel wall at all points.

The enamel is composed of rods cemented together by a less dense substance than that composing the rods. In consequence of the cementing substance being less strong than the rods the structure is likely to cleave between the fibers. The rods are difficult to cut across or hard to wear down from their ends but easily split, if the cleaving force is in the direction of the long axis. This is of importance in breaking down enamel to open into a cavity. If a chisel be directed against the enamel so that the rods are split apart little force is required. The rods are more or less parallel in their outer half while in their inner half they are interlaced and tangled together. In some teeth the rods radiate from the dentin almost parallel, while in others they are wavy and are interlaced a great deal. It is this

variation in the interlacing of the fibers that accounts for the difference in the degree of resistance enamel has for cutting instruments. It was formerly believed that enamel which was very resistant to cutting instruments was harder because it contained more lime salts than that which cut more easily. This was shown to be a fallacy by Dr. Black, who demonstrated that the so-called soft teeth had not less lime salts but seemed to be soft because the enamel rods were straight and consequently easily split apart, while the so-called hard teeth were merely hard because the fibers of enamel were interlaced and tangled together much like the fibers of wood in a pine knot, and any attempt to cleave them is difficult because no matter in what direction the attempt is made the rods must be cut across.

The direction of the enamel rods may be said to be from the center of the tooth to the surface. The rods are generally perpendicular to the surface but there are many locations where they approach the surface at a decided inclination. At a line about the center of a molar or bicuspid the rods are perpendicular to the surface, but as the occlusal surface is reached the rods become more and more inclined toward the cusps where they become parallel with the long axis of the tooth and perpendicular to the tip of the cusp. Likewise as the gingival is reached the rods become more and more inclined toward the root. It is clear from these facts that a cavity in an axial surface coming close to the cusp or marginal ridge cannot have its occlusal wall perpendicular to the axial surface without leaving many enamel rods not supported by dentin. A decided bevel should be given enamel walls at these points which may make the filling material so thin that it may flare up from the margin. Any attempt to make an occlusal wall of a cavity close to the occlusal surface is fraught with many chances of failure. It is usually advisable to cut through to, and include some of the occlusal surface.

The enamel rods incline toward pits and fissures and as they pass from a fissure in the occlusal surface of a bicuspid or molar toward the cusps, the rods incline more and more until they are perpendicular to the tip of the cusp. Thus a groove or fissure which is not cut out very widely requires only parallel walls to protect its margins, while a cavity in the occlusal surface of a bicuspid which is cut widely enough to approach the cusps needs a good deal of bevel.

In incisors and cuspids a line around the crown at the junction of the gingival with the middle third will find the rods pretty generally perpendicular to the tooth's surface. But as the incisal is reached

the inclination of the rods becomes greater and greater until they reach the cutting edge where they are parallel with the long axis of the tooth. The inclination in the incisal third is often as much as 30 to 40 degrees. In proximal surfaces the degree of inclination of the rods depends upon the abruptness with which these surfaces join the incisal edge. The more rounded the corner the more the rods are inclined toward the incisal. Thus on the distal surfaces of laterals the inclination is greater than on the mesial surface. Proximal cavities coming close to the incisal edge in these teeth require so much bevel to remove the short rods that the margin of the filling is endangered by being too thin.

Passing around the incisors and cuspids the rods are generally perpendicular except at the junction of the proximal and lingual surfaces, where the rods are inclined towards the marginal ridge and become rapidly inclined the opposite way on the lingual, and consequently when this ridge is approached it should be cut well back because the rods are not supported.

Cavity walls cut in the incisal surface of incisors and cuspids are well protected even though not brought down on the labial or lingual surfaces because of the inclination of the rods.

Since the enamel rods are not always parallel with each other nor always at right angles to the plane of the tooth's surface, and since all filling materials are not always of equal strength with the enamel, it is not advisable to make the cavo-surface angle a right angle. But instead the outer half of the enamel wall should be cut back until the angle formed by the junction of the enamel wall and the tooth's surface should be greater than a right angle. The number of degrees greater depends upon the inclination of the enamel rods, the friability of the enamel, the force to come against it and the kind of filling material to be used. Gold fillings have the greatest protecting power for enamel walls and are the most likely to cause fracture or crumbling of the edge during insertion, consequently cavities prepared for the insertion of gold require more bevel than those prepared for amalgam or porcelain. Cavities prepared for gold, where much force may come upon the edges and the enamel is friable, require more bevel than cavities which occur in surfaces where less force may fall. Teachers and writers of operative dentistry have always said much on beveling enamel walls but rarely given the student any adequate idea of how much bevel a wall should receive. This idea is hard to impart in words unless accompanied with diagrams and a statement of the number of degrees. Every student has an idea of what a right

angle is, and he knows when a cavo-surface angle is a right angle. Now if he will divide a right angle into sixteenths, eighths, sixths, and fourths he will have an idea what is meant when the bevel is to be 5 to 25 degrees. This means that the cavo-surface angle is 90 degrees plus the number of degrees of bevel, (which is for example 25) or 115 degrees. As a rule when a lecture is given to a class of students on beveling enamel walls there will be many of them go to the extreme in bevels. This must be guarded against lest the filling material be too thin on the edge.

Technique.—Beveling and smoothing enamel walls require so much skill and deft manipulation that it is only after repeated trials in cases where the results can be examined with a large magnifying glass that an operator can be at all sure of results.

A disk is the most suitable instrument to bevel and polish enamel walls but unfortunately its range is limited. There are really but few cavity walls which can be reached at the proper angle with a disk. It will reach the labial, lingual and buccal enamel walls in large proximal cavities but not the gingival, and only occasionally the occlusal. The beginner is certain to round the cavo-surface angle with a disk unless he bears in mind that the disk must not be pressed against the wall, but must be held in position to cut the rods parallel with their long axis, allowing no wabbling of the hand-piece, mandrel or disk. When the rods are thus cut the hand-piece is held at the necessary angle to cut the bevel required. Often too much bevel is cut in large proximal cavities, by allowing the disk to go too close to the gingival wall. At the junction of the gingival wall with the proximal walls the rods are in such a direction that the disk cannot possibly reach them to give them the proper bevel. The gingival enamel wall must be trimmed and beveled with a bur or chisel. A disk in the right angle will reach enamel walls in molars and bicuspids to better advantage in many cases than the straight hand-piece.

The next most suitable instrument and the most universally applicable is the chisel. As the walls are planed down parallel with the long axis of the rods they may then be shaved down to the proper bevel. The instrument must be held firmly and not allowed to turn or catch and jump as it is carried along the enamel wall.

The bur is very universal in its application in trimming and beveling enamel walls but can never leave as smooth and uniform a margin as the disk. In all small cavities in pits and fissures, and in labial and lingual surface cavities it is the only instrument that can be used. In the majority of such cavities the walls are cut back with a bur as

the cavity is being prepared. The bevel may be made with a straight cut fissure bur run rapidly. The gingival enamel wall in proximal cavities may be best trimmed with a round bur, and it is recommended by Johnson for trimming the walls in occlusal cavities in molars and bicuspids.

The strip has a very limited use in smoothing enamel walls. It may be used in proximal cavities in incisors which do not involve the incisal edge but extend well onto the labial and lingual surfaces. In this position a strip held tight and passed back and forth from labial to lingual without allowing it to be lapped around the tooth will smooth the margin as nothing else will.

5. *The toilet* or putting the final touches on the prepared cavity should include a close scrutiny of the condition of the tissue covering the pulp and removing any dust or chips which may have collected in the cavity.

If the cavity wall be at all close to the pulp it is well to go over it with a large, sharp spoon which will remove any remaining decalcified dentin. Some care is needful lest so much pressure be applied as will cause pain. It is usual to cover such a pulpal or axial wall with cement and then form this up as if it were a wall of dentin. The cavity may now be dried thoroughly from a blast of warm air which will remove loose chips, but if moisture has been allowed in the cavity some of the chips will be so attached to the walls and crevices that they will not be removed by a blast of warm air. In such cases a piece of dry cotton rubbed around the walls will loosen the debris and then it can be blown away. Alcohol is often used to assist in drying a cavity but in sensitive teeth the patient receives a shock from the rapid evaporation of the alcohol.

INSTRUMENTS.

While it is of importance to know how to prepare a cavity it is of almost equal importance to know what instruments to use and how to use them. The study of instruments and how to use them is no small part of the preparation to practise dentistry. We are known by our tools. A fifteen minutes' examination of a dentist's operating equipment should satisfy any one as to his standing as an operator. Our instruments are of such importance to us that they deserve much of our attention in selection, arrangement and keeping in order.

An instrument is divided into handle, shank, blade and cutting edge. (Fig. 115.)

The **handle** is that part which is grasped while the instrument is being used.

The **shank** is that part connecting the handle with the working point or cutting edge.

The **working point or cutting edge** is that part of the instrument which comes in contact with the material worked upon.

If the working point be flat and sharp the portion widened to bring out this form is called the blade.

For convenience of communication instruments are classified as excavators, pluggers, scalers, trimmers, separators, polishers, clamps, burs, drills, burnishers, etc. These names denote the purpose or the use of the instrument. If we wish to further describe an instrument we say "hatchet" or "spoon" excavator, "right angle," "contra angle," or "cow horn" plugger. These refer to the form of blade or shank.

Chisels which are used for cutting or chipping away enamel have their cutting edges at right angles to the shaft and are sharpened by cutting or grinding only one plane of the blade.

Hoes have the cutting edge at right angles to the shaft but the shank is so bent that the edge is looking towards the opposite end of the shaft, and the bevel to form the cutting edge is at the expense of that part of the blade away from the handle. They are used only with a drawing motion.

Hatchets have the cutting edge parallel with the long axis of the shaft and the cutting edge is formed by cutting or grinding both planes of the blade. The shanks are made at various angles to bring the edge within reach of the cavity walls.

Spoons are really not spoons in the true sense of the word. At one time they were made that they would dip up fluid but they are not now so made. There is no concavity in the blade. They have shanks of various curves to make the blades reach into the various depths of cavities. Spoons are, with the chisel, the most useful instruments in our equipment. They will remove softened decay to best advantage and will also cut decalcified dentin.

FIG. 115.

There are gingival margin trimmers and side instruments which are modifications of the chisel with shanks formed so as to bring the working edge into positions where the ordinary chisel will not reach.

While it is desirable to have every form and variety of instrument

that will assist in any way in operating, it is at the same time desirable to have as few instruments as will fulfil the requirements. It will be found that the most useful instruments for all cavities in molars and bicuspids will be chisels, spoons and burs, while incisors will demand the small hatchets in addition.

Below is an equipment of cutting instruments sufficient to begin with and will fill most requirements. (Figs. 116 to 140.)

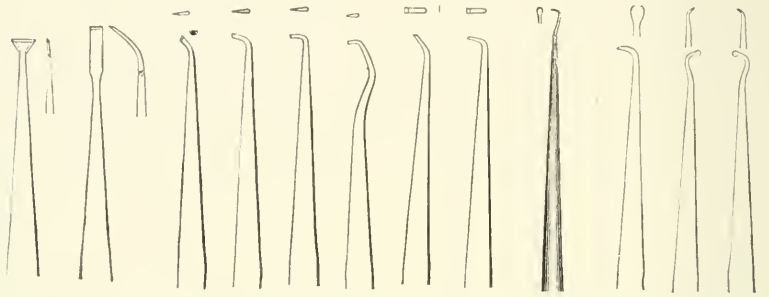

FIGS. 116. 117. 118. 119. 120. 121. 122. 123. 124. 125. 126. 127.

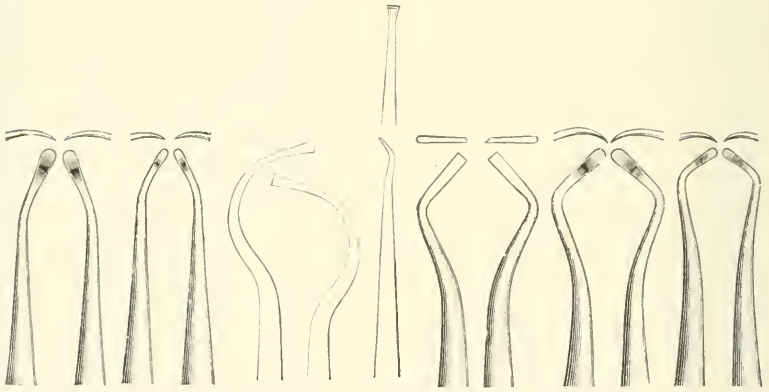

FIGS. 128. 129. 130. 131. 132. 133. 134. 135. 136. 137. 138. 139. 140.

THE DENTAL ENGINE.

The dental engine is classified as an instrument used in the preparation of cavities. While it may not be used to any extent in the preparation of a given cavity yet it is indispensable to the up-to-date operator. Other things being equal the operator who uses the dental engine the least will please his patients the most. The dental engine should only be used for that part of the preparation of a cavity which cannot be conveniently done by hand. If such a rule were followed in practice patients would not dread dental operations. There are

two general forms of engines which affect operations to a marked extent, the all cord engine and the flexible cable. The all cord engine carries the bur forward without any jar or shock, while the flexible cable usually winds up or springs back as pressure is brought upon the instrument, thus the bur is rotated with a series of stops and rapid turnings which jar the tooth and unnerve the patient. The all cord engine is not so convenient to reach difficult locations hence its want of popularity.

BURS.

Only small burs should be used in the cable engine; those more than one and a half millimeters in diameter should not be used in teeth with living pulps or those with a sensitive peridental membrane. There are many forms of burs and drills used in cavity formation but the most useful is the inverted cone. (Fig. 141.) The round bur which

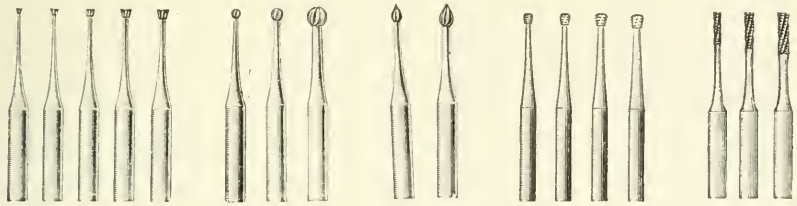

FIGS. 141. 142. 143. 144. 145.

has been used so extensively has no place in cutting that part of the cavity where a bur is indispensable. A bur should never be used to remove softened decay because spoon excavators will do it better. The round bur and the cone bur are useful to open into a pulp chamber when the pulp has been desensitized or devitalized. (See Figs. 142 and 143.) The form of the blades of a bur has something to do with the rapidity of its cutting. The dentate bur cuts enamel more rapidly than the plain blade. There is a dentate pear-shaped bur that cuts enamel better than any other form. (Fig. 144.)

The inverted cone bur has the great advantage of being capable of being made into other forms which are as useful as the original. Burs cannot be sharpened to make it pay at present prices but the operator can in a moment convert a dull bur into a most useful instrument for cutting out fissures or drilling out old fillings. A bur which has once cut enamel should never again be used to cut sensitive dentin. It has lost its keen edge. Burs should be arranged in the bur rack as new ones, those used on dentin a few times, those used on enamel and those only useful to grind into drills, etc. Dull fissure burs can be

flattened on opposite sides and the end sharpened into a drill point. (Fig. 146.) Dull inverted cone burs may be ground square across the end, thus cutting the blades off the end and bringing them far enough up the shaft to be sharp. This instrument will often cut out fissures as well as the original bur. It can be ground in this way until the blades are all ground off. (Fig. 147.) The old inverted cone may be ground into wedge or hatchet shape at the end (Fig. 148) and used to open up fissures, but such an instrument unless small gives the tooth quite a shock. It cuts better if the hand-piece is given a swaying motion.

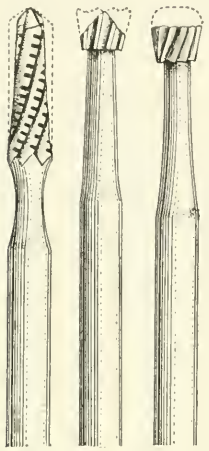

FIGS. 146. 147. 148.

SHARPENING OF INSTRUMENTS.

No instrument which is intended to cut sensitive dentin should be used until it is first sharpened. Because a hatchet is new, it is no guarantee that it is sharp though it is likely to be. An Arkansas stone, on account of being fine and hard, is the most suitable for sharpening dental cutting instruments. If the stone is soft the fine instrument will sink into it, cutting it into gutters, or will catch and spoil the cutting edge. The stone should be wiped off with an oiled rag and thus kept free from particles of steel. After spoon excavators have been sharpened for some time on the Arkansas stone they develop what is called a thick edge and should be ground thin on a carborundum wheel, care being taken not to heat so fine a point while grinding it.

The first attempts at sharpening chisels and hatchets may result in improper bevels, but some attention to this point will avoid the difficulty. A free back and forth movement of the hand will ensure best results. Spoons are the most difficult to sharpen. The motion should be back and forth on the stone, keeping the cutting edge parallel with the motion, and during each stroke the instrument is rotated so that every part of the edge will come against the stone during the motion.

PREPARATION OF PIT AND FISSURE CAVITIES.

General Conditions.—Pit and fissure cavities are the result of defects in the enamel covering of the tooth, and are to be found in the occlusal surfaces of bicuspids and molars, lingual surfaces of incisors and occasionally in the occlusal third of the buccal surfaces of molars.

The enamel begins to calcify at several points, the central incisor at three points, the bicuspids and molars at the tips of the cusps. As the calcific matter is deposited the different lobes of enamel should join between the cusps, but this does not always happen, and as a consequence there is left a fissure which is a defect in the continuity of the surface and must be distinguished from a groove which is only a depression and not a defect. In teeth with very high cusps the fissures are often quite wide open. In fact they are sometimes so open in lower first molars that a fine exploror can be forced between the plates at almost any position along the depression between the cusps. It is a peculiar thing that often even such a wide fissure will not be the seat of caries while others of less width will decay. But the great majority of all fissures are the seat of caries sooner or later. The conditions are the most favorable for development of micro-organisms. Suitable material to develop upon is squeezed into these crevices during a meal and remains there only to be supplemented at intervals. If it were not for the pits and fissures in teeth caries would rarely occur in occlusal surfaces, because they would be kept clean by the mastication of food. There is no better cleaner of the surfaces of the teeth than the chewing of hard tough foods.

Decay in pits and fissures is so often of a penetrating character that great care in examination is necessary. Even though a fine explorer will not enter between the plates of enamel there may be a large cavity beneath. In fact pulps are often reached by decay and pain be the first evidence that anything is wrong without any perceptible break in the enamel. In such cases a close observation will reveal a whitened area beneath the enamel along the fissure. Any change in the color of the enamel usually indicates some defect in the dentin beneath. If decay has once begun in a fissure there is only one treatment open to the operator. Cut it out in its entirety and include it in the cavity. Occasionally fissures may be found in recently erupted molars which have not begun to decay and may be prevented from doing so by drying them perfectly and squeezing them full of soft cement carried to place on the index finger and held there until the cement hardens. This treatment will often prevent such fissures from decaying in young patients where no other measures are available.

If every opperator had the opportunity of seeing the micro-organisms of decay under a microscope and then seeing the width of the finest fissure under the same power there would be no doubt in his mind as to what should be done. Fissures are defects and are always a source of weakness and especially so when radiating from a cavity. Decay

having once occurred in a fissure is an indication that it is susceptible, and even if the decay be all removed recurrence is almost certain if the fissures are not cut out to the end and included in the cavity. Besides cutting out the fissures it is necessary to cut out angular grooves because it is impossible to properly finish a filling flush with the margin in these deep V-shaped spaces. If they are left they only form places for the lodgment of fruit seeds, etc.

Technique.—The first step in the preparation of pit cavities such as are found on the buccal surfaces of the first molars and the lingual surfaces of the upper incisors is to get access to the cavity. Since these cavities do not need their outlines increased to prevent further decay their preparation is quite simple. If the decay has not progressed to any extent they may be opened with a drill or a cone bur. Once a small bur will enter it is well to cut outwards rather than from without inwards. A larger and larger bur is used until free access is gained to the cavity. Usually there is not much soft decay in the cavity now under consideration so the inverted cone bur may be used to complete the preparation of the cavity. But if the pit has been the starting point of quite a large cavity the enamel can best be cut away with a chisel, the softened decay removed with spoon excavators and the cavity washed out with a stream of tepid water. If the rubber dam be now applied a full view of the cavity is possible and a decision as to the location of the outline arrived at. The enamel walls may be cut back with a good sized fissure bur, and the remainder of the decay removed with spoon excavators and a cement base inserted which will become the axial wall of the cavity. As the enamel rods around such cavities tend to lean towards the pit no bevel is required if the walls of the cavity are cut at right angles to the general plane of the enamel surrounding the cavity.

Occasionally a cavity in the lingual surface of the upper central or lateral may have a fissure extending from it quite through the singulum which complicates its preparation. The fissure usually runs clear to the limits of the enamel which in a young patient will be far under the gum. Such fissures must be cut out and included in the cavity. It may be necessary to pack the gum out of the way with gutta-percha. An inverted cone bur will cut out such a fissure more rapidly than any other instrument. Size $\frac{1}{2}$ to $\frac{3}{4}$ mm.

A groove often extends occlusally from a pit cavity in the buccal surface of a molar but rarely needs to be extended over the ridge. If an occlusal cavity also exists it should be prepared before the buccal cavity is filled because when the two cavities are open at the same time

a better judgment can be formed as to whether they should be joined or not.

The order of procedure in preparing fissure and pit cavities in the occlusal surfaces of bicuspids and molars is dependent upon the extent of the decay. If a shallow cavity has occurred in the central fossa of a molar which has fissures radiating from it the edges of unsupported enamel may be broken down with a chisel and the outline form proceeded with at once. The fissures can be cut out with small inverted cone burs or those made into drills as described in a previous section. Once a small channel has been cut through a fissure the edges may be then broken down with a sharp chisel until the general outline has been obtained. An inverted cone bur or a sharp flat-ended fissure bur will cut out a flat seat and give the walls the proper form. If the cavity walls do not come close to the cusps the enamel wall needs no bevel. All that is necessary is to cut the walls at right angles to the pulpal wall. If there is now any decay left it may be removed with spoon excavators. If the pulpal wall has been cut with an inverted cone bur it will not be necessary to cut convenience angles nor will it be necessary to provide for any further retention than that cut with the inverted cone bur in forming the seat and walls. Clear the cavity of cuttings and it is ready to fill.

If a deep cavity has occurred, however, the operator is concerned with the possibility of the involvement of the pulp and the sensitiveness of the tissues from both decay and exposure to changes of temperature. It is necessary to determine the condition of the pulp as soon as possible because if it must be devitalized it should be done before there is any cutting of sensitive dentin in gaining the outline form. Cut away the unsupported enamel with a chisel, putting the guard finger on the tooth to be cut. Then remove the softened tissue with large spoon excavators, having a care for pressure. The spoon may be worked under the leathery decay at the edges and flake after flake removed without pain. Then wash out with tepid water. As soon as it is determined that the pulp is not to be devitalized there are two methods open, one is to now flood the remaining decay in the cavity with an anodyne which will prevent any pain from exposure and proceed with the outline form. Then remove the remaining decay and cover the pulpal wall with cement. In this method the deep sensitive tissues are not exposed for any length of time. The other method is to immediately deal with the deep parts of the cavity covering with cement and as soon as this hardens proceed with the outline form. By the latter method the sensitive tissues are dealt with early in the operation and are pro-

tected from thermal changes and the seat for the filling may be cut in the cement while the fissures are being drilled out. There is always a chance of finding some decay under the edge of the cement when the fissures are cut out. The final step in either method is to bevel the enamel walls which may be done with a round bur run rapidly or a fissure bur in the right angle held perpendicular to the pulpal wall and then in such locations as come close to the cusps the instrument should be held so as to give the wall a slight bevel.

A cavity in either of the occlusal pits of the upper bicuspids should when completed include both pits and the connecting fissure or groove. It is very rare indeed that the tissue between these pits should be left if either have failed. It is not necessary to cut this fissure or groove more than one to one and a half mm. in width (Fig. 149). Cavities in the occlusal surface of the lower bicuspids need not be treated in the same way. In the majority of cases there is neither a fissure nor a groove joining the pits but a ridge of sound enamel, which should be

FIG. 149.

FIG. 150.

FIG. 151.

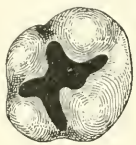

FIG. 152.

FIG. 153.

rarely cut across because defects have occurred in either or both pits, unless, of course, the enamel has been undermined by caries. (Fig. 150.) There is a crescentic form of the lower second bicuspid which if defective at all should be cut out in its entirety. (Fig. 151).

Occlusal cavities in the pits and fissures of the upper molars depend in their outline form entirely upon the extent and direction of the fissures and angular grooves. A cavity in the central fossa of the upper first or second molar is usually simple in preparation. There is often a question, however, as to how far to cut out grooves extending to the mesial or to the buccal. The general rule applies, cut all fissures and grooves until a good finishing margin can be obtained. Often it is advisable to cut the buccal groove out until the break is reached to form the buccal surface. In such cases the extremity of the groove should be sloped into the center of the cavity giving a decided bevel to the wall. Thus a good finishing margin is reached without cutting a slot clear through to the buccal surface which would tend to weaken the cusps. Where there is a defect in both the central fossa and the disto-lingual groove it is always advisable to prepare both cavities at the same time when a

decision can be made as to the advisability of cutting across the transverse ridge. If cut across it should appear as Fig. 152. If there is any thickness of dentin under the ridge it should not be cut across. (Fig. 153.) There is often a supplemental cusp in the upper first molar which has grooves and fissures about it which must be cut out. These are often so penetrating that cusps are undermined and must be cut away thus facing almost the whole occlusal surface with the filling. (Fig. 154.)

Third molars are irregular in their markings but usually have three cusps, two buccal and one lingual, with a pit between and fissures run-

Fig. 154.

Fig. 155.

Fig. 156.

Fig. 157.

ning buccally, mesio-lingually and disto-lingually. Neither fissures nor grooves pass over the marginal ridges. (Fig. 155.)

Lower first molars have a central depression which is often defective and fissures and grooves extending buccally, lingually, mesially, and distally. These cavities are the most uniform of any under this heading. (Fig. 156.)

The lower third molars often have the same outline as the lower first, while the second will have the appearance of Fig. 157.

SMOOTH SURFACE CAVITIES.

1. *Cavities in the gingival third of labial, buccal and lingual surfaces.*

General Considerations.—The number of cavities and the extent of caries in these locations is a true index to the care of the teeth. Cavities should not occur in these locations if our present views of the cause of caries be correct, that is if the patient takes reasonable care of his teeth. There is not a buccal or lingual surface except in cases of marked irregularity that cannot be reached with a tooth brush. It is safe to say to the patient who has such cavities that he does not brush his teeth properly and a lesson should be given to him at once. In the majority of these cases the first indication of beginning caries is a sensitive spot that the patient accidently finds with his finger nail or a tooth pick. The area of the sensitiveness gradually increases until the tooth brush is not used even on that side of the mouth for

fear of touching the sensitive spot. A break in the enamel occurs and extends both mesially and distally. This line is just at the junction of the free margin of the gum with the enamel where there is a slight protection from the action of the lips. These white lines of superficial decay rarely enter the proximal surfaces in young patients but usually do so in those of advanced years where the gums have receded to some extent. This decay never begins under the free margin of the gums but often extends there by undermining the enamel. In such cases the sharp edge of the cavity irritates the gum tissue, causing a hypertrophy which makes it appear as if caries had begun under the gum.

The proper treatment of labial, buccal, and lingual caries calls for careful consideration, not that fillings are often dislodged but that they so often fail at the margins. There is usually an area of defective enamel extending from the cavity and unless this is all cut out failure is certain and even then the operation has not changed the environment. The future of fillings in these locations depends more upon the patient than upon the perfection of the operation. If after these locations on the teeth have been made comfortable the patient cannot be induced to regularly and carefully clean them no kind of operation other than the removal of the gingival third of the affected surface and covering the gingival margin with healthy gum tissue will last even a reasonable time. It is often a serious question how much of the enamel about such defects should be cut out and included in the cavity. The indication of the beginning of caries is a sensitive area. In such cases a thorough polishing with powdered pumice followed by chalk, with instructions to the patient to follow a simular treatment will often prevent the formation of a cavity. Since the general introduction of porcelain as a filling material labial cavities may be more freely cut for the prevention of future caries.

Though many labial, buccal and lingual cavities are difficult to manage there are a few where decay is slow and the tissue so non-sensitive that they are among the simplest operations that come under the dentist's care.

Technique.—The form to be given these cavities is simple but the management of the operation is exceptionally difficult, because of the hypersensitiveness of the dentin and even the enamel, and because of the difficulty of getting free access to the cavity. The gum tissue has usually grown into the cavity and is exceptionally sensitive as all pathological gum tissue is. And perhaps the greatest handicap of all is, the patient dreads the operation more than all others

and the operator dreads it himself. Operations in these locations have a peculiar tendency to increase the flow of saliva which adds materially to the difficulty of the operation and to the discomfort of the patient. There are few operations in dentistry where the pain and discomfort to the patient are so out of control of the operator as a shallow sensitive cavity in the buccal surface of a lower molar in a nervous woman. The saliva flows freely, the ordinary therapeutic remedies cannot be used unless the rubber is applied and this cannot be done without a clamp which will certainly touch the sensitive area. Difficulties such as these can only be overcome by an experienced master hand. The hypodermic injection of novocain and adrenalin chloride into the gum opposite the end of the root promises results, while the injection of cocaine into the tooth with the high pressure syring is more to be depended upon.

In the majority of small cavities even if the gum tissue has grown into them it is less painful and more expeditious not to make any attempt to remove the gum from the cavity until the operation can be made, while in large and deep cavities where cotton and gutta-percha can be packed and retained without the removal of much of the decay it is wise to do so at a previous sitting. When the gum is removed from these deep cavities one of the difficulties has been overcome. In labial cavities the first step after using a solution of cocaine on the gum around the neck of the tooth is to apply the rubber dam. Dry the cavity. Break down the enamel around the cavity avoiding the decalcified dentin. Carefully plan the next step which will be the most important in the preparation of all such cavities. It is just as painful to remove one layer of the decalcified tissue as it is to remove the whole mass. If the cavity be small and no danger of pressing upon the pulp, select a location at the mesial or distal wall and sink a sharp hatchet or Darby-Perry spoon No. 9 or 10 down to the bottom of the decay and scoop the whole mass out at once. Just as this cut is undertaken the operator should warn his patient and at the same time divert his attention by remarks on some interesting topic. An application of hot phenol or phenol and alcohol will relieve the pain incident to the exposure of the dentin to the air. The further preparation of the cavity will not be more sensitive than any other unless it should reach the junction of the proximal surface with the labial about one mm. from the gum. An inverted cone bur in the direct hand-piece will cut a flat axial wall, and extend the other walls in any direction leaving sufficient undercut to start and retain the filling. Since the introduction of porcelain it is not necessary to discuss the peculiar forms of these cavities

which make gold fillings the least conspicuous. The outline should extend under the free margin of the gum and when finished be covered with it. There should be such extension mesially and distally as will ensure sound, hard enamel. If any special convenience is required to start a gold filling it should be cut in that part of the cavity furthest from the operator and in the greatest thickness of dentin. Any undercuts in the dentin for retentive purposes should be in opposite walls of the cavity. The cavo-surface angle may be trimmed with a chisel or a round bur or a cone bur. The remaining decay over the axial wall, if any, should be removed and the cavity is prepared for filling. (Figs. 158 and 159.)

Buccal cavities in bicuspids are treated in like manners but those in molars are modified by the difficulty of acces and the impossibility of applying the rubber dam when the gingival wall is far below the gum. The decay may be removed in the same way and the final forming of the cavity done with a bur in the right angle. There is one frequently occuring buccal cavity which nearly always fails when filled. It occurs in the distal third of the buccal surfaces of third molars. These surfaces are rarely cleaned by either food or the tooth brush. Sooner or later they involve the whole disto-buccal surface and the occlusal. While they are small cavities in the buccal surface they are so sensitive and difficult of access that proper extension cannot be made, hence recurrence of caries is inevitable. As soon as the occlusal surface is involved a good dovetail can be cut and the filling when inserted sloped off in such a manner as to prevent heavy occlusion upon it.

Fig. 158.

Fig. 159.

Lingual cavities in the gingival third are rare. They only occur because of a marked recession of the gums, or from wearing an artificial denture. The preparation of the cavity is similar to that in the labial and buccal surfaces. Any variation will depend upon the extent and location of the caries.

2. *The preparation of cavities in proximal surfaces of incisors and cuspids which do not involve the incisal angle.*

General Considerations.—Patients who have neglected their teeth for years take an anxious interest in them as soon as cavities appear in their incisors and cuspids. They recognize at once that if these teeth become unsightly they have lost one mark of beauty. They often allow molars and bicuspids to decay beyond any hope of being restored to usefulness under the foolish notion that they can re-

tain the anterior teeth even if the others are lost. There is no more fallacious notion than this met with in the practice of dentistry, except perhaps mistaking the first permanent molar for a deciduous tooth. It is difficult to decide what is best to do for a patient of say twenty-eight years of age who has lost the power of mastication on his molars and bicuspids and has several proximal cavities in the incisors. The incisors are used for a purpose for which they were never intended, and as a consequence wear down rapidly, cutting off the incisal retention to proximal fillings. While it is true that a patient is justified in becoming anxious when his anterior teeth begin to decay he should in fact be more anxious when his molars and bicuspids show signs of being lost, because the anterior teeth cannot be preserved permanently if they are used for the mastication of food. Artificial dentures of molars and bicuspids alone are but a poor substitute for the natural teeth of mastication. The incisors will be used in preference, to their destruction. It is the dentist's duty when he sees small proximal cavities in the anterior teeth to look into the future sufficiently to educate his patient along the lines of being exceedingly anxious about the condition of the molars and bicuspids. Fillings in the anterior teeth even if small are doomed if they are called upon to bear the stress of mastication. These teeth are thin and small and give but a poor opportunity for the firm anchorage of fillings and if called upon to do a duty they were not intended for there is certain to be failure. This is the cause of a large class of failures in fillings in the anterior teeth which cannot be classed among failures from recurrence of caries.

It has been found by those of largest experience in filling teeth that there are certain areas of the teeth more susceptible to caries than others. These susceptible areas are found to be those which are not habitually cleaned by excursions of food in mastication, or by the friction of the cheeks, lips, or tongue. Proximal surfaces of the anterior teeth which are close together are not habitually clean, and decay in proportion to their uncleanness. It has also been observed that not all points of proximal surfaces are equally susceptible. All that portion from the incisal edge to the contact point is usually immune and in fact the actual contact point is rarely the seat of beginning caries but a point immediately gingival to the contact is the susceptible area. This is as it were an eddy behind the contact where secretions may rest and plaques form without disturbance. Each case presents its own little variations and should be considered before any operating is proceeded with, because in these days of esthetics the whole susceptible area may sometimes be removed and restored with gold without exposing the filling.

It has been noticed for a long time that proximal gold fillings fail at the gingival margin, which is true, but closer observation has shown that failure rarely occurs in the center of the proximal surface but at the linguo-gingival angle and the labio-gingival angle. That portion of the gingival margin in the center is usually covered with gum tissue and hence does not decay, while both to the lingual and to the labial of this point the free margin of the gum crosses the margin of the filling and at these points recurrence happens. If the margin is placed immediately gingival to the contact it is in a susceptible area and failure is imminent. Teeth which are spaced in the occlusal or incisal third will have their proximal surfaces cleaned by the excursions of food down to the contact and if the margin of the filling is incisal to the contact recurrence is unlikely.

The lingual margin is often a location of failure of proximal gold fillings in the anterior teeth. Operators have too frequently left the lingual enamel plate for the convenience of packing the gold. Cavities are often cut quite over on the labial surface for convenience of access. Such preparations are a mark of the man who is compelled to do too many fillings a day to make a competence. There is often a marked concavity both inciso-gingivally and mesio-distally on the lingual surface of an incisor which leaves the lingual wall little more than enamel if a proximal cavity occurs. If such a lingual plate of enamel is left it is not strong enough to bear the stress of packing gold against it without fracture. Even if this enamel plate does not actually break out during the insertion of the gold it becomes checked sufficiently to allow leakage. There is only one safe rule to follow. Cut the enamel away on the lingual, until what remains is supported by dentin.

The preparation of small proximal cavities in the anterior teeth naturally divides itself into two general classes. Those which are prepared with a view to the permanency of the filling and those which are prepared knowing that the filling will be more or less temporary. If all the work of the dentist could be made mechanically correct and its permanency was not dependent upon conditions outside of his control, dentistry would be practised as a trade and would not have the power to retain so many bright minds within its ranks. The varying circumstances that influence the permanency of dental operations make dentistry interesting. The only man who can say that his operations will be permanent is the one who does not know or the one who intentionally wishes to deceive. The claim of absolute permanency of dental operations has done much to discredit the profession because the patient who has lost several so-called permanent fillings must think that the

dentist was ignorant or dishonest, either of which is not creditable to the profession. Therefore when we speak of preparations for so-called permanent fillings we mean only relatively permanent.

Porcelain fillings have within the past few years taken such a hold on the profession that few gold fillings are now inserted in exposed surfaces of the anterior teeth for patients who value their personal appearance. Though this may be true there is still a large field left for gold and other fillings.

The preparation of cavities for those fillings which may be looked upon as more or less permanent demands a study of the general condition of the patient, the oral secretions, the mucous membranes and the teeth. There must be a careful study of the susceptible and immune areas of the teeth. These considerations will usually demand the extending of the gingival wall of proximal cavities under the free margin of the gum and the labial and lingual walls to those areas which are immune to caries, while the incisal margin will be carried far enough to the incisal to prevent it from coming in contact with the adjoining tooth. If a cavity is so extended there will be no portion of its margin in susceptible areas. The gingival margin will be covered by healthy gum tissue, the labial margin will always be kept clean by foods, the lips, and the brush, the lingual margin by food and the tongue, and the incisal margin by food. The only other requisites for a fairly permanent filling will be perfect mechanical adaptation to the cavity walls and not so much stress of occlusion as will wear, stretch, or dislodge the filling.

The preparation of cavities in proximal surfaces of incisors which must of necessity be looked upon as temporary demand less general consideration but more consideration of the particular reasons for such temporary operations. There must be a perfect understanding between patient and operator when operations are to be made which are not ideal. The ideal operation may be pointed out to the patient and the reasons given for deviations from it. In this way the patient understands what is to be expected from such operations and is not deceived. And besides if the operator shows himself to be a good prognosticator his standing is enhanced in the patient's mind and not diminished if the operation lasts no longer than he said.

While we must admit that all cavities cannot be prepared according to an ideal formula there is no intention in this chapter to countenance slip-shod operating. Every reason that may be given here for not preparing cavities according to the outline in a previous paragraph can be made an excuse for careless operating. One operator may be so

much more skillful and deft about his work, that what would be too painful for another operator's patient to bear would be easily borne by his. The rough, unskillful operator will rarely find patients who can bear to have proper preparations made in teeth with living pulps, while the skillful operator will rarely find cases where perfect preparations cannot be made.

If the proper preparation of a cavity would prove too painful for a young patient a temporary operation is indicated, and in such a case where cement is to be used, it is not desirable to break down any more of the enamel than will ensure sufficient access to remove the decay. Then again if small proximal cavities develop slowly and the exposure of gold would be objectionable it would be manifestly better to gain sufficient space to insert small gold fillings than make the ideal extensions. Such small fillings are not likely to prevent further decay for more than three or four years but the patient has not had gold fillings exposed in the teeth for that much of her life. While it is sometimes desirable to make cavities that do not have their margins in immune areas there are certain cases which are so markedly susceptible to caries that they must have their margins carried full well on to immune areas.

Technique.—Separation is a necessity for the proper preparation and filling of proximal cavities in the incisors and cuspids. Space should be gained in such a way as to prevent the teeth from being sore when worked upon. There is no necessity for having the peridental membrane so sensitive that the patient experiences pain from every touch of the tooth. If slight soreness should occur it is well to support the teeth while operating.

Usually the first step in the preparation of proximal cavities in incisors is to chip away the thin enamel with a chisel or a hatchet or hoe excavator. These latter instruments are narrow in the blade and unless carefully used the points may drop into the sensitive portions of the cavity. The thin edges of the cavity may be shaved down from the incisal to the gingival on the labial and the lingual with the corner of a triangular chisel, holding the second finger on the tooth as a guard. The blade of the chisel should be carried toward the center of the tooth as the edge is carried toward the gingival. A sharp spoon will remove the major portion of the decay. At this time a decision can be made as to the extent of the carious tissue and the probable outline form.

The outline form having been decided upon, the chisel with a keen edge will do more than any other instrument. The enamel may

be cut away chip by chip until the incisal margin reaches a point which will be kept clean by excursions of food. Both the labial and the lingual walls may be cut back with the chisel, using the pen grasp, but occasionally the thumb and palm grasp will reach the lingual walls to best advantage. In opening up the cavity the loose decay was removed, also the thin enamel edges, so now the chief concern is with the proper formation of the cavity for the reception of the filling and the prevention of future decay without regard to existing caries. Cavities of less than 1.5 mm. in diameter without much undermining of the enamel can be extended to advantage with a round bur. The largest round bur which will enter the cavity is not so likely to cut into the dentin and cause pain. The blades may be carried against the enamel cutting from the dentin outwards. It will be found necessary to extend the gingival wall considerably rootwards in many cases to insure the margin of the cavity being covered with healthy gum tissue. In the case of the small cavity just mentioned a round bur directed against this wall in the manner described will work quite efficiently. But in the majority of cases an inverted cone bur ½ mm. in diameter for laterals and small cavities, and 1 mm. in diameter for centrals directed against the gingival wall and swept across from labial to lingual and from lingual to labial holding the hand-piece at such an angle as will give the corner of the bur a grip of the tissue will usually cut the dentin gingivally and at the same time make a flat seat for the filling with convenience angles for starting the gold both at the linguo-gingivo-axial angle and the labio-gingivo-axial angle. As the bur cuts into the angles the hand-piece should be swayed in an opposite direction and the bur carried upward along the labio-axial line angle and linguo-axial line angle, thus making a slight groove which should under no circumstances extend more than one-third or one-quarter of the distance to the incisal retention. In this connection it must not be understood that grooves are recommended in either the labial or lingual walls. A slight extension incisally from the convenience angles for holding the filling more securely during its insertion is all that is desirable. As the gingival wall is thus formed the enamel edge will not be cut away which can be done with a narrow chisel introduced from the labial. Such a chisel should have a fine neck so it may be held at any angle. A round bur may be used to trim the enamel at the gingival but must be held firmly, allowing it to rotate in the proper direction, or it may catch on the edge and pull the rubber off or cut a deep notch in the margin. The outline at the junction of the lingual wall with the gingival and the labial with the gingival must be cut with great care

otherwise too much bevel will occur, or these points will not be extended far enough to ensure a clearing margin. It must be kept in mind that these are vulnerable points in these fillings.

Any decay or decalcified tissue that might be remaining in the cavity should be removed. Spoon excavators with thin cutting blades and of a size to readily enter the cavity will rapidly remove the remaining defective tissue. Darby-Perry No. 9, 10, 2 and 4 are thin bladed spoons suitable for small cavities.

Give the cavity proper form to resist any stress that may come upon the filling, also make it of such a form that it will be convenient to fill. In cases where the gingival wall does not need extension for prevention, and the outline form has been obtained and the decay removed, the resistance form, the retentive form and the convenience form may be all made at the same time. An inverted cone bur $\frac{1}{2}$ mm. in diameter for small cavities and $\frac{3}{4}$ or 1 mm. in diameter for larger cavities in centrals and cuspids will cut a flat seat at the gingival by holding the instrument parallel with the long axis of the tooth and carrying it well into the linguo-gingivo-axial angle and into the labio-gingivo-axial angle as before mentioned. In these cavities it is impossible to cut the gingival wall at right angles to the long axis of the tooth with an inverted cone bur because the shaft cannot be held exactly parallel with the long axis, but if the dentin be cut slightly deeper at the gingivo-axial line angle the outer border or enamel wall may then be trimmed sloping inward except at the cavo-surface angle which should be beveled. The main feature of the gingival wall is to be flat from labial to lingual and form a right angle or an acute angle with the axial wall. There should be no deep grooving of the gingival wall nor cutting of deep pits. A flat seat with walls forming right angles from it is the best form to resist stress. The necessary retentive form in these cavities is provided for in the cut into the linguo-gingivo-axial angle and the labio-gingivo-axial angle and a slight cut into the dentin at the junction of the lingual wall with the labial at the incisal extremity of the cavity. At these points the dentin is the thickest and the cuts are directed away from the pulp. The incisal retention can be completed with an acute angled hatchet, S. S. W., No. 27. This instrument may start to cut at the labio-axial line angle about a millimeter from the incisal retention and be carried toward the incisal and then started again in a similar position on the lingual carrying each cut around the incisal retention started with the bur. This action of the instrument will deepen the cavity rapidly. It is not necessary to make a deep undercut at this point, it is more important to have a good bulk of gold even at right angles to the

axial wall than a fine hole bored deeply. The lingual wall should not under any circumstances be grooved in its length nor should the labial. There are cases where a short groove may be extended from the convenience angles but even these are not necessary in small cavities.

A source of weakness in fillings at the incisal margin is the thinness of the gold. The enamel rods on distal surfaces have a decided incline towards the incisal, and if beveled at all makes the gold thin. This difficulty may be overcome if the incisal retention is some distance gingival to the cavo-surface angle by making a slight concavity from the incisal retention to the cavo-surface angle with a round bur. This deepening between the labial and lingual cavo-surface angles will

Fig. 160.

Fig. 161.

Fig. 162.

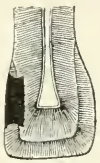

Fig. 163.

thicken the gold to the very edge. Such a concavity cannot be cut deep or the retention might be destroyed and the enamel plates undermined. (Figs. 160, 161, 162, 163.)

The enamel wall may be trimmed and beveled with the chisel, round bur or strip, and where there is abundance of space the disk. The disk and strip are very treacherous instruments but in the hands of those who are willing to study their peculairities are the most tractable at our command. A strip narrower than the inciso-gingival diameter of the cavity held tight and carried back and forth without pressure against the walls will finish an enamel wall in these cavities as no other instrument can. A disk in large cavities may be satisfactory but it should not be permitted to reach the junction of the gingival wall with the labial or lingual or too much bevel will be the result. A round bur is better adapted for these positions.

If the cuttings are now removed from the cavity and the tissue over the pulp carefully inspected the filling may be inserted.

Lower incisors and cuspid cavities demand special treatment insofar as these teeth differ in form from the uppers. They have smaller and longer crowns than the uppers. They are much narrower mesio-distally and the contact points are always at the incisal edges. The latter fact together with concave proximal surfaces at the gum line make operations prone to failure. The teeth are so thin that the

labial and lingual plates of enamel have but little dentin between them, and if retention be cut deeply between these plates for the incisal retention the corner is almost certain to fracture. In some of these teeth the pulp extends far into the crown and is a source of difficulty. Cavities which do not extend close to the incisal edge are simple in preparation and the fillings of fair permanency. There is little or no stress on small fillings in the lower anterior teeth. Retentive form is made as in the upper. In fact the preparation is the same except that there is not as much space between the teeth, and all the instruments should be smaller. Retentive form and convenience angles may be cut with a ½ mm. inverted cone bur holding the shaft at right angles to the long axis of the tooth. The base of the bur may be carried down the lingual wall and sunk into the gingival at the linguo-gingivo-axial angle. The labio-gingivo-axial angle may be cut in like manner using a bur in the right angle hand-piece. The incisal retention may be cut as in the uppers.

3. *Preparation of proximal cavities in incisors and cuspids which involve the incisal angle.*

General Considerations.—Proximal cavities in incisors and cuspids which have become so extensive as to involve the incisal angle have usually been filled before. The conditions which caused the failure of the former filling will be of value in determining what form of preparation is desirable for the new cavity. In such cases as have not been filled before there is often difficulty in deciding whether the incisal angle should be cut away or not. Corners of enamel often stand the force brought upon them before the filling is inserted and break off shortly afterwards. There may be two reasons for this, a tooth with a cavity in it is usually saved a little in mastication but as soon as made comfortable by a filling it receives full force upon it. Or the corner of enamel may be checked during the insertion of the gold and come away later. It is a safe practice to remove a corner of enamel when it has not a support of dentin if the cavity is to be filled with gold. As patients become older the enamel is more and more worn away and seems to check and split more readily than thicker tissue. This is especially true where proximal fillings have failed from wearing away of the tooth tissue leaving the filling to carry too much stress. The margins of cavities in such teeth demand free cutting away of tissue and careful operating to prevent checking of the edges.

The character of the articulation, the peculiar motion of the teeth on each other in mastication and the force of the occlusion all influence

the operator in deciding the form of preparation. In most of these extensive operations failure does not occur from primary decay about the margins, but is secondary to the shifting of the filling or checks in the enamel. If a patient should have no molars and bicuspids suitable for mastication large fillings in the incisors need to be much more firmly seated than if there were good posterior teeth for mastication. Teeth which come together with a kind of anterio-posterior motion, sliding the lowers from the labio-incisal angle of the uppers to the gingival will drive almost any filling from the upper teeth. And if the lower teeth happen to require fillings, they will be as likely to fail as the uppers.

Outline Form.—The determination of the outline form in proximal cavities which involve the incisal angle is not one of extension for prevention in the ordinary acceptation of the practice. It is extension to more securely anchor the filling rather than to prevent decay. The proximal surfaces are usually so far extended before such an operation is contemplated that no further extension is necessary to prevent recurrence of caries on these surfaces. The outline form depends on the age of the patient, the extent of the caries, the thickness of the tooth, the amount of wear on the incisal edge, the friability of the enamel and the character of the occlusion. Depending upon these conditions there are five methods of preparation open to the operator. The first to consider is a modification of the method used in preparing proximal cavities which do not involve the incisal angle. The indications for this form of preparation are thin teeth, young patients, not very heavy occlusion, not much of the incisal edge involved and not much undermining of the corner.

Resistance Form.—The seat and labial and lingual walls are prepared as already described, except that the seat is made broader and longer and the grooves are made deeper. The filling will be called upon to bear heavier stress than those described in the former section and requires a greater seat. The labial and lingual margins should be a straight line from the incisal to the point where they curve to form the gingival wall.

Retentive Form.—Much care is necessary to avoid cutting out all the dentin between the labial and the lingual enamel plates in cutting the incisal retention. To be of the most value this retention must be as near the point of stress as possible and large enough to contain a sufficient bulk of gold to have strength to resist the forces of dislodgment. The horn of the pulp is not always secure from an accident in cutting this retention. It is generally sufficient to make the

occlusal wall of this retention at right angles to the long axis of the tooth, but to be certain of doing this it is well to aim to make the depth of the retention closer to the incisal than that at the axial wall.

Technique.—With a wide chisel cut away the corner, shaving both the labial and lingual to the gingival. Some patients' only fear is the slipping of the instrument and wounding the gum or touching the sensitive portions of the cavity. In such cases a coarse disk or a thin stone will trim away the enamel corner readily and with less anxiety to the patient. Remove the softened dentin and form the seat with an inverted cone bur 1 mm. in diameter which may be held parallel with the long axis of the tooth and carried into the labio- and linguo-gingivo-axial angles, cutting deeply into the dentin at these points and carrying a groove towards the incisal less than half way. The incisal retention may be cut with an inverted cone bur held at right angles to the axial wall giving the corner of the bur a catch into the dentin some distance gingivally to the final occlusal wall. Slight grooves may now be cut toward the gingival from the incisal retention. A disk is the only instrument to finish the enamel walls. It can be held to cut the enamel parallel with the length of the rods and then to slightly bevel the outer third. The incisal cavo-surface angle will bear considerable bevel. Remove any remaining decay from the axial wall and clean up the cavity walls. (See Figs. 164 and 165.)

Fig. 164.

Fig. 165.

The second method is suitable in thin teeth, young patients, incisal surface not much worn nor not much involved, corner undermined. Chiefly useful in laterals. Pits and grooves in the lingual surface may be included in such a preparation.

The outline form is the same as in the last case except that there is a tongue or dovetail cut in the lingual surface at least one and a half mm. from the incisal edge depending upon the form of this surface. The margins of the dovetail should join with the lingual wall in rounded corners.

The resistance form at the gingival is the same as in the last case.

The retentive form in the incisal region is entirely different. Instead of cutting between the labial and lingual plates as in the former case the incisal retention is cut into the lingual surface in the form of a dovetail. The dovetail is cut about one and a half mm. in depth, depending upon the thickness of the tooth and the nearness of the pulp. The direction depends upon whether there are defects in the enamel of the lingual surface or not. It is generally advisable to

make this retention at right angles to the proximal wall and about one and a half mm. inciso-gingivally and about one and a half to two mm. mesio-distally. To be of the greatest value as retention it must be cut as near as possible to the incisal but must not be so near as to weaken the edge.

Technique.—The technique up to cutting the supplementary retention in the lingual has already been described. It is always difficult to control the hand-piece to cut into the lingual surface of any tooth and it is especially difficult to do so in this case, if it becomes necessary to use the right angle. Where this form of preparation is advisable the lingual surface is usually markedly concave inciso-gingivally thus making it almost impossible to reach it with the straight hand-piece. Unless the operator has confidence in his ability to hold the hand-piece and operate through the mouth mirror it is better to raise the chair, tip the patient's head back and operate by direct view. A No. $\frac{1}{2}$ or $\frac{3}{4}$ mm. inverted cone bur should be held at right angles to the lingual surface of the tooth, starting the corner of the bur on the lingual wall of the cavity at the junction of the enamel with the dentin. This bur will cut a slot the full depth of the enamel and the necessary distance towards the opposite side of the tooth. The enamel edges should be cut back and, if need be, the slot cut larger and made retentive in form, that is, the incisal and gingival walls must be slightly undercut. (Figs. 166, 167 and 168.)

Fig. 166.

Fig. 167.

Fig. 168.

The third method of preparation is indicated in thin teeth, corner undermined, edge much involved, lingual plate of enamel badly decayed, and heavy occlusion and appearance of gold not a serious objection. In such cases there is a step cut in the incisal surface, its width depending upon the extent of the destruction of the cutting edge. As a rule the step should extend mesio-distally farther than the width of the filling to be supported. The depth depends upon the weight of occlusion and the thickness of the tooth.

Technique.—When it has been decided to cut across the incisal exposing the gold on the labial surface a stone is the most suitable instrument to begin with. Cut the incisal edge down the width and

depth required. Prepare the proximal cavity as in case two. With an inverted cone bur cut a groove from the proximal cavity across the step between the labial and lingual enamel plates, deepening and enlaging the groove at its extremity. A good deal of care is necessary in cutting this groove to keep it from coming too close to the labial plate and at the same time have it large enough to contain sufficient gold to have strength.

FIG. 169.

FIG. 170.

FIG. 171.

The fourth method is more frequently applicable than either of the last two described. This method of preparation was first described by Dr. Johnson and takes his name. It is indicated in thick teeth, much worn, corner undermined, edge much involved, heavy occlusion, brittle enamel, old patients, lingual surface not too much involved. The successful preparation of such a cavity and filling it with gold demands much consideration before it is undertaken and careful manipulation afterwards.

Technique.—The seat and proximal surface are prepared as in the last two cases. Dependence for the retention of the filling is in the step cut across the incisal. The step does not involve the labial plate and yet the occlusal surface is completely covered with gold. The step is largely at the expense of the lingual surface. The labial wall must in consequence be cut with a definite angle with the axial wall. The labial wall in the step must also meet the pulpal wall with a definite angle to give the necessary resistance to a heavy occlusion coming against the lingual surface of so large a filling.

The outline from a labial view is shown in Figure 169. There is no exposure of gold except as a proximal filling. If the incisal surface has been sufficiently worn to expose the dentin the outline will show the whole occlusal surface faced with gold. (Fig. 170.) The lingual outline will show almost a third of the surface covered with gold. (Fig. 171.) Those surfaces of the tooth which are exposed to heavy occlusion are covered with gold and those surfaces which are exposed to view from without show but little gold.

An inverted cone bur held against the axial wall at right angles to the long axis of the tooth will, if carried across the incisal, cut the step about 1 mm. in depth. This first cut must be kept well to the lingual

or the labial plate may be so thin as to expose the gold through the enamel. The lingual plate may now be trimmed away with the chisel. Usually it is necessary to carry the inverted cone bur across the incisal again to make the step flat and at right angles to the stress. The extremity should be deepened to give additional strength and to resist tipping. The groove through the dentin forming the step should not be more than ½ mm. deeper than the lingual wall except as it approaches the extremity where it may be slightly deeper, while at the same time the lingual wall is not trimmed away so much at this point. There may in some cases be some difficulty in obtaining sufficient resistance to forces which may happen to be applied to the labial surface. But as a rule fillings are rarely tipped to the lingual.

Fig. 172.

Finishing the enamel walls demands a careful study of the direction of the enamel rods at every point. The labial wall of the step may be beveled with a fissure bur, a disk or a round bur. This wall is sloped from the junction of the labio-incisal angle to the pulpal wall of the step. The extremity of the step is best trimmed with a round bur. The lingual wall of the step must have a slight bevel and join with the proximal lingual wall in a rounded form. A sharp corner at this junction would invite failure either during the insertion of the filling or afterwards by the occlusion. At the junction of the labial wall of the step with the proximal wall is a source of weakness if a sharp angle is left to the enamel. A small disk in the right angle will reach the lingual cavo-surface angle and also the labial.

Fig. 173.

The fifth method is applicable in those cases where there is an edge to edge bite, wearing the teeth down to expose the dentin and perhaps loosening the incisal retention in a small proximal filling. There is not much of the incisal edge lost and yet a proximal filling cannot be retained because of the rapid wearing of the tooth and the difficulty of cutting an incisal retention. The surest method to follow is to cut the step clear across the incisal including all the exposed dentin and beveling both the labial and lingual enamel walls toward the pulpal wall of the step. Of course, enough of these walls must be cut down to face the whole end of the tooth with gold. The preparation of the proximal cavity should be done as before described except that it does not require any provision for retention because the step will provide all the resistance necessary. There is little or no force to drive the filling to the labial or the lingual because there is little

Fig. 174.

loss of these surfaces. The chief point of difficulty in preparation is at the junction of the proximal cavity with the step. There must be bulk enough of gold at this point to ensure against stretching. If a sharp corner is left at this junction it tends to leave a point to start the stretching of the gold. The technique of preparing this cavity is so much like those just described that it is not necessary to repeat it. (Figs. 172, 173 and 174.)

Shoeing.—There is a class of cavities met with in old patients so similar to the one described in the previous paragraph that it might not be out of place to describe their preparation here. They are strictly speaking occlusal cavities but they are not similar in origin to other occlusal cavities already described. As patients advance in years their teeth become worn until the dentin is reached which soon hollows out in a cup shape on the occlusal surface. This exposed dentin often becomes quite sensitive to acids and in fact is dissolved or worn away so rapidly that the pulp is often involved. The teeth become much shortened and unsightly. To foresee and prevent such unhappy results is the duty of the dentist. If a tooth seems to be cupped out even though there is little direct antagonism of the opposing tooth, it is well to prepare a cavity for the reception of a gold filling which will cover the exposed dentin and prevent its further wear. The anterior teeth, both upper and lower, are chiefly subjected to such wearing because so many people have lost their molars and bicuspids.

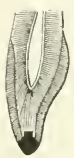

FIG. 175.

Technique.—The technique of preparation is simple. This eburnated dentin is not usually sensitive to cut. An inverted cone bur can be held parallel with the long axis of the tooth and carried across the occlusal surface cutting a groove about a millimeter in depth. As the tooth is worn down a good deal it is quite thick labio-lingually giving ample room for good anchorage. The extremities of the groove should not come too close to the mesial or distal surfaces. The inverted cone will make all the undercuts necessary to keep the filling from being lifted from the cavity which is the only force that can dislodge it. The walls should be sloped into the cavity and the finished filling should come over the entire end of the tooth and be of sufficient thickness to resist stretching or curling up at the edges from constant hammering of the opposing teeth. (Figs. 175 and 176.)

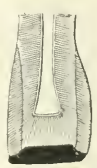

FIG. 176.

PULPLESS INCISORS HAVING LARGE PROXIMAL CAVITIES.

While the majority of incisors which have lost their pulps and have large proximal cavities require to be filled with porcelain or should be cut

off and restored by a crown there are cases which should be filled with gold.

The difficulty in preparing such cavities is to avoid cutting away the dentin; because so much has been already lost by getting access to remove the pulp there is no strength left to retain and support a filling. In thin teeth not much worn on the incisal, a fair amount of dentin, and not much filling exposed to occlusion the chief retention may be obtained in the pulp chamber. The pulp chamber should be filled with cement and then the gingival wall cut wide and flat as if the pulp had receded markedly. Grooves may be cut in the labial and lingual walls part of the distance to the incisal, depending upon the thickness of the tooth. The incisal retention should be cut with an inverted cone bur placing it into the pulp chamber and cutting towards the incisal, thus getting a good undercut without going near the incisal. The aim should be to make up in bulk of gold (the greater portion of which will be in the pulp chamber) for not getting the retention as near the point of stress as in other cases.

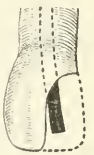

Fig. 177.

If the tooth is thin and the decay together with the cutting to remove the pulp has involved a good deal of dentin any further cutting of dentin is contra-indicated. It is better to depend for retention of the filling upon a post cemented in the root canal and extending far enough into the cavity proper to give a good attachment for the filling. There is no further preparation of the cavity required than to give it proper outline form and resistance form; the post will provide the retention. The technique of inserting a post in an incisor so that a gold filling may be condensed around it is not always easy. Select a piece of iridio-platinum wire No. 16 for a central or cuspid and No. 18 for a lateral. Ream out the canal about five to seven mm. in depth, not the same diameter the full depth, as it is usually better to taper the wire slightly. To do this it is best held in a pin vise for filing. With heavy pliers give it the necessary bend to enter the canal and project in the center of the cavity so that gold may be packed between it and the cavity walls and also cover it at the surface. To accomplish this it will be necessary to fit the pin in the cavity, mark it about the proper length and remove it to cut it off. Then file it down to some extent and perhaps flatten that portion extending into the cavity with a hammer on the anvil so as to conform with the flat shape of the tooth labio-lingually. Before setting in cement it should be tried in and note taken of its length, its size and proper position to allow gold to be packed around it, and its capability of retaining the filling. (Figs. 177 and 178.)

Fig. 178.

4. *Preparation of cavities in bicuspids and molars which do not involve the occlusal surface.*

While the general rule is laid down that all proximal cavities in bicuspids and molars should be extended through to the occlusal surface there are cases in which it is better practice not to do so. In the very old, the very young and in cases of immunity to caries it is not always wise to extend proximal cavities to the occlusal surface, but such operations must be looked upon as temporary in character.

There is more or less recession of the gums around the necks of the teeth as age advances. The gum tissue which once filled the interproximal space does not more than half fill it at fifty or sixty years of age. These open spaces between the teeth serve as pockets for the collection of food which ferments and acts as a starting point of decay. The cementum is exposed and decays rapidly. In such cavities which are usually shallow and girdle the tooth it would be manifestly unwise to extend through to the occlusal surface. There is plenty of access, the contact is far occlusal to the cavity and the tooth is thick enough occluso-gingivally to bear any stress which might come upon it. Besides old patients should be treated with a good deal of consideration. Radical and painful operations should be reserved for those in the vigor of life. Old people dread dental operations even more than the child who has been told of the horrors of the dental chair.

For many reasons, as has already been said, it may not be wise to make a full extension of cavities occurring in the proximal surfaces of the teeth of the very young. These patients are often so nervous and restless in the dental chair that anything like ideal operating cannot be undertaken. It is better in such cases to do temporary work rather than create a dread of dental operations in the minds of young patients. Again the warning must be sounded that oversensitiveness, etc., must not be made an excuse for improper extensions. While we must all admit that such cases are met in practice yet there are not nearly so many of them as some of the old operators would have us believe.

Often a large proximal cavity is found in the mesial surface of a first permanent molar and after it has been opened up and prepared for filling the beginning of a cavity is found in the distal surface of the second bicuspid. Now comes the problem. What should be done with such a defect? If it is left without a filling it is certain to decay. If a small filling is inserted whose margins are in contact with the adjoining filling recurrence is almost certain within a very few years. Should the whole proximal surface together with the neces-

sary step be cut out now, or should an attempt be made to get a clearing margin to a filling confined to the proximal surface? The answer to these questions depends upon the conditions present. If the patient be a young girl and caries progressive and a full extension would seem impossible a small cavity may be prepared. It must be explained to the patient that this is a temporary operation which will need careful examination every few months. Any change of color about the filling will be a signal for its removal. By this method perhaps two or three years have been gained and the patient at this time will be glad to have a more permanent operation made. If the patient be robust and the dentin not too sensitive and a tendency to caries and lack of care of teeth, the cavity should be prepared in the most ideal manner. Then there is the middle course which may be followed if there is a marked immunity to caries. The cavity may be extended as much as possible to clear the margins but yet confining it to the proximal surface. There are many cases of thick necked teeth where this preparation will have fairly good cleansing margins. The management of this type of case in practice will indicate what may be done with similar cavities in other locations.

Many times small cavities are found in the proximal surfaces of teeth in patients of middle life which have not increased in size for years, or perhaps at one time decay was rapid but for some cause or another has ceased. The walls of these cavities will be dark or even black in color, the enamel about them does not seem to have its normal histological structure when cut, the dentin in the bottom of the cavity does not seem to be sensitive. In some of these cases there may be a slowly progressing caries at only one location in the cavity. Radical extensions of cavity margins are not indicated in such cases. It is not necessary to cut such cavities through to the occlusal surface if there is abundance of access and there is sufficient thickness of tissue left to bear the forces of occlusion.

Technique.—The technique of preparing proximal cavities in bicuspids and molars which do not involve the occlusal surface is quite simple. They are simple cavities and are prepared as buccal, labial, or lingual cavities. There is no force to dislodge the filling.

5. *Preparation of cavities in the proximal surfaces of bicuspids and molars which involve the occlusal surface.*

The preparation of cavities in the proximal surfaces of molars and bicuspids opens up the "question of extension for prevention" again. While there may be excuses for not extending proximal cavities in the anterior teeth there cannot be the same excuses for not doing so in

the bicuspids and molars. These teeth are wider bucco-lingually than the anterior teeth, the proximal surfaces are often flat which in a measure accounts for more frequent failures in these teeth than in the anterior teeth. The bicuspids and molars are usually closer together and rarely as well cared for as the incisors.

The outline form depends upon the age, and sex of the patient, the character of the carious process, the strength of the closure of the jaws and the friability of the enamel. The extent of the caries is a factor in deciding the location of the outline only when it has gone beyond the susceptible areas. All small cavities of decay are extended until immune areas are reached. The gingival wall is cut away until the margin of the filling will be covered by healthy gum tissue. The buccal and lingual walls are extended until the margins are quite clear of the adjoining teeth and may be kept clean by the action of the lips, the tongue, the tooth brush and food in passing over them. The outline of such cavities on the occlusal surface depends to some extent upon the depth and direction of the fissures. While cutting proximal cavities through to the occlusal gives more perfect access to the proximal cavity it also gives an opportunity for cutting out defective grooves or fissures in the occlusal surface and forming a step for the filling which is the chief source of retention. The outline in the occlusal should be formed so as to give the greatest amount of retention for the filling with the least cutting away of tissue. The buccal and lingual walls should be parallel and at right angles to the seat of the cavity. There should be no acute angles or irregularities in the outline.

Technique.—In the ordinary proximal cavities where the occluso-proximal marginal ridge has not been broken away and but slight defects in the occlusal fossa the simplest method of procedure is to cut into the fissure in the occlusal with an enamel drill or fissure bur about ½ mm. in diameter. This instrument should be carried right through the marginal ridge leaving a slot, the edges of which can be broken down with a chisel. If the cavity be a distal one, Black's side instruments work admirably. At this juncture the decay in the proximal cavity may be removed with spoon excavators and the cavity washed out with a stream of tepid water. If the rubber is now applied and the cavity dried the full degree of extension may be decided upon. In the great majority of cases where the proximal decay has been at all extensive the buccal and lingual walls may be cut back with the chisel. If the enamel is supported by dentin it will be impossible to cut it back with the chisel until the dentin is first removed. This may be done with an inverted cone bur which is placed in the seat of the

cavity and carried from the center to the buccal and then carried towards the occlusal undermining the enamel. This may be repeated on the lingual wall and if the gingival needs extension it may be cut with the same instrument. The chisel will now shave back the enamel slightly beyond the point of the removal of the dentin. A narrow necked chisel may be passed between the teeth to shave the gingival enamel away. In many of these cases it is difficult to control an inverted cone bur along the seat and keep it from jumping out of the cavity or dropping dangerously near the pulp. If an Ivory matrix is adjusted the bur may be held tightly against it while it is cutting and thus prevented from doing what was not intended. The outline of the step should be completed by carrying an inverted cone bur 1 mm. in diameter as far to the opposite side of the tooth as the fissures extend and at this point carried to the buccal and lingual enough to make the cavity at the extremity a little more than $\frac{1}{2}$ mm. wider bucco-lingually than any other point in the step. Instead of widening the extremity of the step as just described it may be deepened about half a millimeter and slightly undercutting buccally and lingually. This method is applicable where there are no fissures or angular grooves requiring removal. There is always some difficulty in properly trimming the enamel at the junction of the occlusal outline with the proximal. A careful study of the behavior of the enamel as it is cut away is the only guide to the proper beveling.

The resistance form of cavities in bicuspids and molars is of first importance because these teeth and their fillings are called upon to bear heavy pressure and sudden impacts from hard substances in the closure of the jaws. The chief dependence to resist this heavy stress must be in a flat seat and step which are at right angles to the force applied. There should be no dependence put in grooves or undercuts in the walls of the cavity to resist the stress of occlusion.

As the outline form is being gained the resistance form is being provided for. The inverted cone bur which was swept across the gingival wall made the seat flat from buccal to lingual and from the cavo-surface angle to the axial wall. And as the step was being cut out with the same form of instrument it was made flat. The junction of the axial wall with the step should be slightly rounded just so as not to leave a sharp corner which might be the starting point of stretching the gold under the heavy biting in some mouths. If decay has removed a good deal of the axial wall thus lessening the area of the step it may be restored with cement and formed as if it were dentin.

The retentive form is largely provided for in the resistance form

and the outline form. However, there are forces which may dislodge fillings in bicuspids and molars though they would resist the heaviest of stress. Such fillings must be so placed as to prevent their being tipped from the cavity or lifted directly out. The tipping stress is overcome by the dovetail in the occlusal surface and by providing sufficient bulk of gold in the step so that portion of the filling in the proximal surface may not be broken away from the step. As the buccal and lingual walls are being cut back the inverted cone bur is allowed to cut deeply into the bucco-gingivo-axial angle and carried occlusally about two-thirds the distance to the step, thus making the slightest grooves, which widens the cavity bucco-lingually at the seat and not at the step. It must not be understood that the outline is wider bucco-lingually at the seat than at the step. It is only in the depth of the cavity that it is wider. A slight undercut in the step will provide against the lifting of the filling if the walls cannot be widened as just mentioned or if the proximal cavity is to be filled with non-cohesive gold or tin-and-gold, and finished with cohesive gold.

The convenience form has already been provided for in the

FIG. 179.

FIG. 180.

FIG. 181. FIG. 182.

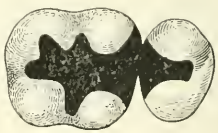

FIG. 183. FIG. 184.

angles cut at the seat and in opening up the cavity to the occlusal to gain free access. There is no more fatal mistake in the formation of this cavity than allowing the proximal walls to diverge as they approach the gingival. Even if such cavities are successfully filled the least condensation of the filling after it is inserted will result in the gold drawing away from the margins.

The enamel walls should be first cut in the length of the rods and then the cavo-surface angle beveled the required amount at every point. If the operator notices the manner of cleavage of the enamel while trimming the walls he will be guided in their final polishing and beveling. Any mistake in the proper bevel of the enamel is sure to be followed by fractures of the enamel around the filling.

Technique.—A disk will trim, bevel and polish part of the buccal and lingual walls on the proximal and part on the occlusal. A disk will not reach the margins near the gingival without cutting too much bevel nor will it reach the walls at the extremity of the step. These

locations must be trimmed with a bur. A chisel will trim the gingival wall. Darby-Perry gingival enamel chisels will sometimes do good service at these points. (Figs. 179, 180, 181, 182, 183 and 184.)

If any decalcified tissue remains over the axial or pulpal wall it may now be carefully cut away and the cavity cleared of any chips.

The procedure of preparing these cavities is slightly modified if the proximal decay is extensive enough to undermine the enamel both buccally and lingually. In such cases the walls are readily cut away with the chisel and the seat is easily formed. What is of considerable moment in these cases is the support of the buccal and lingual cusps and at the same time to get enough resistance form for the filling. Caries has reduced the area of the step and the area of the seat cannot be increased by cutting into the tooth until the axial wall is at right angles with the seat and step, without involving the pulp. The next best thing to having a step of dentin is to have one of cement. The cement serves the purpose of a non-conducting lining and a support for the metal filling.

Lower bicuspid cavities deserve special mention inasmuch as they are of different form from the uppers. Proximal decay in lower first bicuspids which have low lingual cusps must be prepared as the anterior teeth. The groove between the cusps is rarely defective in the low cusped variety. In the high cusped variety there are usually two pits on the occlusal separated by a ridge of perfect enamel which need not be cut through to form the step if the occlusion is not heavy. These teeth are often wide enough bucco-lingually to permit of the whole cavity being dovetailed. The lower second bicuspids demand more resistance form, and even though there is a good transverse ridge it should be cut across to get enough resistance and retentive form to retain a large proximal filling.

In special large mesio-occlusal cavities in upper molars there is often some difficulty in managing the mesio-buccal cusp which has become undermined. The cusp is usually high and not well supported by dentin. If a fissure should run over the buccal from the central fossa then there is no doubt about what should be done. Cut the whole cusp down with a stone as far distally as the central groove. It should be cut low enough to leave room to be covered with sufficient bulk of filling material to bear the stress of mastication. And if it be cut further rootwards as it approaches the central groove giving it a general slant to that portion of the cavity it will help to resist the tipping stress on the filling. The same method of managing the disto-lingual cusp will often add to the retention of the filling and re-

move a weak cusp which is likely to be fractured. Mesial cavities in lower molars occasionally involve one of the cusps and need the same treatment. (Fig. 185.)

There is a class of cavities in molars which is often puzzling to the beginner. They occur as the result of defective enamel over the whole occlusal surface. Caries often ceases after the whole enamel surface is stripped off. There are spots of penetration but for which they might not need operative interference. The pulps are alive and apparently normal and the patient under fifteen years of age. It is mostly considered wise not to devitalize such pulps if they can be retained alive. Grind off any projecting spiculæ of enamel. Remove the decayed tissue with spoons and if hard remove with large round burs. The only force which is liable to dislodge a filling from such a tooth will be a lifting one. To overcome this and to keep the filling from being forced off the end of the tooth cut a continuous groove with an inverted cone bur all the way around the tooth about midway between the enamel and the probable location of the pulp. A groove made with such a bur will have undercut enough to resist the lifting stress. If a groove cannot be cut all the way round, good sized pits may be cut at the four corners. These will give sufficient hold for a filling if it is not built too high. (Fig. 186.)

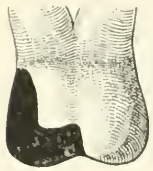

Fig. 185.

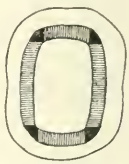

Fig. 186.

THE MANAGEMENT OF LARGE PROXIMO-OCCLUSAL CAVITIES IN PULPLESS BICUSPIDS.

Bicuspids are so narrow mesio-distally and the pulp cavity is so situated in the crown that when the necessary cutting is done to remove the pulp from a proximo-occlusal cavity there is little dentin left to support the cusps. It usually happens that if a bicuspid has decayed deeply enough in one surface to involve the pulp the opposite surface is also defective. This increases the weakness of the cusps. With the present knowledge of inlays it is hardly ever advisable to fill such bicuspids with gold foil. The malleting of so large a filling is sufficient to endanger the walls by wedging the gold between them. Very occasionally a post might be inserted in the root canal of a bicuspid to act as a support to a gold filling. Such a post is more serviceable in lower bicuspids where the transverse ridge is not often defective and the post serves for retention without cutting a step across the occlusal.

THE MANAGEMENT OF LARGE CAVITIES IN PULPLESS MOLARS.

The secret of success in filling large cavities in molars is to cut away the enamel freely. Leave as little enamel exposed to occlusion as possible. Grind it low enough to be well covered with filling material. Enamel exposed to occlusion in a pulpless molar must be supported by a large bulk of dentin or failure is certain. Posts screwed into the root canals often assist in supporting a large proximo-occlusal filling which would otherwise have to be supported by cutting deeply into the dentin of the tooth, thus unnecessarily weakening the whole structure. Large cavities in the lower molars rarely need a post for the retention of the filling. The pulp chamber may be used for this purpose by cutting a groove around its walls at the base. The bulk of filling in the chamber will be strong enough to resist any tipping stress and the undercut will resist the lifting force.

THE TECHNIQUE OF INSERTING A SCREW POST.

The technique of inserting a screw post into a root canal for the purpose of supporting a filling or a tube for a jacket crown is simple and yet has to be done a few times to gain speed and get the best results. The screw posts which are the most suitable have square heads with a tapering thread as a screw nail. The thread is sharp and will cut into the dentin as it is forced into the canal. Select the proper size of post, ream the canal slightly smaller than the post. Screw the post in and out a couple of times. Mark the point on the post when screwed into place at which it should be cut off to be properly covered with filling material. Remove the post, nick it deep enough with a file so as it will twist off when fully twisted down to place after being dipped into soft cement or chlora percha. A post to be of service should not extend through the filling nor yet be so short that the filling cannot be thoroughly packed around it. If the post is intended to resist a lifting force that portion of it which is in the filling should be riveted to form a head on it. There is always some danger of splitting a root by screwing a post in too tightly.

CHAPTER XI.

THE TREATMENT OF SENSITIVE DENTIN.

BY J. P. BUCKLEY, PH. G., D. D. S.

GENERAL CONSIDERATIONS.

It is claimed by the best authorities that "*in the normal condition dentin should be without sensation;* and that the source of sensitive dentin, or of impressionable pulps, lies in their continued subjection to irritation by which responsiveness is developed" (Barrett). This view is, I believe, generally conceded to be correct by all who have given this subject their attention. It is true that in the preparation of cavities for fillings we find few teeth the dentin of which is without sensation. This fact is not surprising, nor can it be construed as being contrary to the statement that normal dentin is not sensitive, when we remember that there are few teeth in the mouths of patients demanding the services of the dentist, the dentinal fibrillæ and pulps of which have not been subjected to continued irritation.

In the discussion of means and methods by which the sensitiveness of the dentin can be allayed I shall not attempt to enter into the details of many histologic and pathologic phenomena which are certain to arise in the consideration of the *therapeutics* of this subject; but shall confine myself largely to the drug aspect.

It is desirable at the outset that the reader should understand and appreciate the fact that there is no other one source of failure in operative dentistry so great as the improper preparation of the cavity. This result does not always follow because of ignorance on the part of the operator of the principles involved in cavity preparation, but oftentimes because the patient will not permit, or the operator does not feel justified in inflicting, the pain necessary in carrying out those principles.

The sensitiveness of the dentin can be obtunded in no small degree by the use of various therapeutic agents; and I might state that there are few operations which we are called upon to perform wherein the patient will appreciate our efforts more than in this by applying drugs and remedies for the mitigation of pain. But in order to apply intelligently and successfully any remedy, whether it be a drug or an agent, to the dentin and thereby obtund the sensitivity of the dentinal

fibrillæ without endangering the vitality of the pulp itself, we must be familiar with several factors or conditions, which I cannot with propriety here discuss, in detail at least. For instance, a thorough knowledge of the anatomic and histologic structure of the tooth is of the highest importance, as is also a knowledge of the pathology, not only of the fibrillæ, but of the pulp tissue as well—the changes which these structures are capable of undergoing if unduly irritated by the application of the remedy employed. Still another factor of equal importance, and one which more directly relates to the phase of the subject under consideration, is a knowledge of the pharmacologic action and the therapeutic application of the drugs and remedies used for this purpose.

The tendency in dentistry as well as in medicine today is towards rational therapeutics. Empirical methods of treatment are being rapidly relegated to the past. Before using a drug or an agent for allaying the sensitiveness of dentin, or for any other purpose, we should know what *action* to anticipate from its employment. This is not too much to expect from the trained dental practitioner of today.

THERAPEUTICS.

The remedies suggested for obtunding sensitive dentin have been many and varied. I shall discuss only those which, from clinical experience, have proved of sufficient value to merit consideration; and for convenience of study, will divide them into four general classes.

I. *Physical Agents.*—Any agent, whether heat, cold, light, electricity, or any influence whatever, if employed in the treatment of a diseased condition, is a *remedy*. There are some physical agents by the proper use of which the sensitiveness of dentin can, in a measure, be obtunded.

(1) *Heat.*—The application of dry heat to a sensitive cavity, especially in conjunction with a dehydrating agent such as absolute alcohol, is always an aid; and this is accomplished by means of heating dry air, and gently directing a current of air thus heated into the cavity which has been isolated by the rubber dam and moistened with the dehydrating agent used. Care must be taken not to primarily cause pain, otherwise the object of using the agent would be defeated.

Several apparatuses have been devised for heating the air. Dr. Rudolph Beck, of Chicago, has recently perfected a convenient electrical device by means of which compressed air can be heated as it passes through. Other such devices are on the market. In the absence of any of these the chip-blower can be employed; however, with less

satisfaction. Inasmuch as heat is used in conjunction with another and more important class of remedies, I shall refer to this agent later.

(2) *Cold.*—A lesser degree of heat, commonly designated *cold*, is another physical agent sometimes employed for the purpose of desensitizing the dentin. Heat may be abstracted from the tooth structure by spraying the cavity with a highly volatile liquid, like ether, rhigolene, or ethyl chlorid. In the use of these agents, advantage is taken of the physical law that *a solid in changing its form to a liquid, or a liquid in changing its form to a vapor or gas, must abstract from the thing to which it is applied, a certain amount of heat in order to effect the change.* Ether, or combinations containing ether, and ethyl chlorid, both used as sprays, have proved valuable in some instances, especially shallow cavities near the gum the dentin of which is difficult to obtund by the usual methods employed, and to which reference will be made later on in this chapter.

A precaution to be taken to prevent primary pain in applying this remedy, is to fill the cavity temporarily with stopping, and direct the spray first on this and surrounding parts, after which the stopping can be removed and the spray directed into cavity without any appreciable pain. The degree of refrigeration must not be carried to the point of having a possible deleterious effect subsequently upon the pulp or gum tissue.

(3) *Light.*—A form of energy called *light* has recently been brought forth as having a peculiarly favorable effect upon hypersensitive patients. In one method the rays of light are colored by passing through a blue glass. This is accomplished by darkening the room and employing a blue bulb (16 or 32 c.p.) on an ordinary electric socket. Whether the light acts locally, or affects the vision and thus the general nervous system, has yet to be demonstrated. The result of the author's experience with this agent thus far has not been encouraging. It is true that light differs in effect from heat, though both come from the same heated body. This phenomenon is observed in the action of light on certain chemicals; for example, the silver salts, some of which are used as obtundents, undergo a chemical change when exposed to sunlight or luminously hot bodies.

(4) *Electric Current.*—This agent has been employed as a means of carrying certain drugs into the dentin and pulp tissue for obtundent purposes. The method is called *cataphoresis;* but because of the expensive and complicated apparatus, the length of time required to obtund as well as oftentimes unsatisfactory, and, in not a few instances, disastrous results, the method has generally been discarded.

II. *Escharotics or Caustics.*—Escharotics, or caustics, are agents that destroy or disorganize the tissue upon which they act. Any drug or agent, then, which will cauterize the dentinal fibrillæ, will obtund sensitive dentin. There are many drugs, however, belonging to this class that cannot be used for this purpose because of their deleterious effect upon both the tooth structure and the pulp tissue. For instance, the strong mineral acids will disorganize the protoplasmic dentinal fibrillæ; but they will also disintegrate the inorganic structure of the tooth. Arsenic trioxid has a specific poisonous action upon the fibrillæ, but there is no known means of preventing the same deleterious effect upon the cells of the pulp tissue.

The most valuable escharotics for desensitizing the dentin are: .

Phenol,	Trichloracetic acid,
Zinc chlorid,	Silver nitrate.

It must be noted that, while these agents will obtund, the ultimate result is too often produced, with the possible exception of phenol, at the expense of quite as much suffering as they save.

Phenol has local analgesic properties besides that of cauterant, and will, therefore, be discussed under another and more important class of agents.

Zinc chlorid in various strength solutions can be used to advantage in a class of cavities where the decay or softened dentin does not extend too close to the pulp. Zinc chlorid coagulates albumin and in the process hydrochloric acid is liberated. For this reason the application of strong solutions is painful and should not be employed in deep cavities unless the irritating action of the agent is modified. This can be done to a marked degree by selecting alcohol and chloroform as the vehicle in which to make the solution.

A useful formula is here given:

℞—Zinci chloridi, gr. xx
Alcoholis, f.℥ iv
Chloroformi, q. s. ad, f.℥ j —M.
Sig.—Apply to the cavity on a small pledget of cotton and gently evaporate to dryness.
Note: If the zinc salt does not make a clear solution in the alcohol it indicates that some of the salt has been oxidized; the solution can be cleared by adding one drop of hydrochloric acid.

Trichloracetic acid in concentrated solution causes considerable pain when first applied to a sensitive cavity, therefore defeating the

object of its use; but in a 10 or 15 per cent solution it produces but little pain or inflammatory reaction. In this strength it can be employed; but not always with satisfactory results.

Silver nitrate is perhaps the only known prophylactic for decay. In the posterior part of the mouth where the cementum is exposed to external influences and thus sensitive, or in shallow cavities, especially in children's teeth, the use of this drug, in the solid pencil form or in various strength solutions, will be found valuable, both as a means of reducing the sensitiveness and preventing further ingress of caries. As an agent for obtunding the sensitivity of the dentin in an ordinary cavity, it should not be considered for various reasons. When the agent is employed for the purposes above mentioned, the cavity, after the application, should be kept free from saliva for a few minutes, and, if possible, exposed to sunlight, thus decomposing the silver salt as referred to in this chapter under the subject of *light*. A solution of sodium chlorid should always be at hand when using silver nitrate, and in case any of the latter agent should accidentally get on the mucous membrane of the patient's mouth its action can be checked at once by rinsing the mouth with this antidotal solution.

III. *Local Anodynes or Local Anesthetics.*—A *local anodyne* is an agent which, when applied to a part, relieves *pain*. A *local anesthetic* is an agent which, when applied, produces insensibility to *pain* in that particular locality. According to Long, it rather produces a condition of *analgesia*, which means the absence of sensibility to pain, as distinguished from *true anesthesia*, the absence of all sensibility.

In the judicious use of agents belonging to this class the author firmly believes will ultimately be found the surest and safest road to success. The following agents, or a combination of two or more, will be found to be of the utmost importance:

Cocain,	Phenol,
Menthol,	Ethyl chlorid,
Oil of cloves,	Ether,
Eugenol,	Chloroform.

Cocain is one of several alkaloids, this being by far the most important, obtained from the leaves of Erythroxylon Coca, a plant indigenous to Peru and other South American states. Both the alkaloid, cocain, and the alkaloidal salt, cocain hydrochlorid, are used in various ways for obtunding sensitive dentin. The alkaloidal salt was formerly recognized by the United States Pharmacopeia as cocain hydrochlorate; but in the last edition (1900) it is called cocain hydrochlorid. An important physiologic property of cocain to be

remembered here, is its power, when applied directly to the mucous membrane or when injected or forced into the pulp tissue, of inducing a condition of analgesia in the part by paralyzing the sensory nerve filaments. In addition to this it causes a blanching of the part which is subsequently followed by congestion. It should also be remembered that pharmacologists have proved, beyond a doubt, that cocain is a *general protoplasmic poison;* that muscles as well as nerves and nerve-ends cease to contract or to conduct stimuli when they are exposed to even dilute solutions of the drug. The only reason that the deleterious effect is more noticeable upon nerve than upon other kinds of tissue is that here we are dealing with the medium of sensation and expression.

The author deems it wise to call attention to these well-established physiologic, pharmacologic and pathologic facts, for many instruments have recently been devised for forcing various strength solutions of cocain hydrochlorid, not only into the dentinal tubuli, thereby paralyzing the fibrillæ, but into the pulp proper, anesthetizing this organ as well. In view of these facts it would appear that we are *never justified in completely anesthetizing the pulp of a tooth for the purpose of painlessly preparing a cavity therein.* Therefore under the subject of *cataphoresis* in this chapter, little was written; and for the same reasons, the method of anesthetizing the pulp by *high pressure anesthesia*, for obtundent purposes only, will not be considered. Both of these methods will be discussed in a subsequent chapter on pulp removal.

Cocain and the alkaloidal salt, cocain hydrochlorid, are safe and valuable agents for obtunding sensitive dentin, if confined to the dentinal structure of the tooth. Frequently in deep-seated cavities, especially in children's teeth, the sensitiveness can be completely overcome by sealing in the cavity for a day or two a creamy paste made by mixing the alkaloid cocain with liquid petroleum. The revised edition of the United States Pharmacopeia now recognizes an *oleate of cocain* (5 per cent), which can be used for this purpose. The paste or oleate should cover the entire surface of dentin which we subsequently expect to excavate. Good results can also be immediately obtained by the use of the following remedy:

℞—Cocainæ, gr. xx
Chloroformi, f.℥ ij
Etheris, q. s. ad, f.℥ j—M.
Sig.—After the rubber dam has been adjusted apply to the cavity on a small pledget of cotton and evaporate to dryness.

In the use of this remedy, advantage is taken of the physical law previously referred to in this chapter under *cold*. As the volatile liquids, ether and chloroform, evaporate, a certain amount of heat is abstracted from the tooth structure, and a coating of the alkaloid, driven to an extent into the dentin, is left in the cavity. This remedy will not completely obtund all sensitive dentin, but its use will be a material aid.

There can be no objection in favorable cases, provided the dentin has been previously sterilized, to using aqueous solutions of cocain hydrochlorid with uniform pressure over the entire area of the cavity, thus forcing the anesthetizing solution an equal distance into the dentin. This is an extremely difficult thing to do without forcing the solution at some more favorable point in the cavity through the tubuli and into the pulp. However, there are cavities where good results can be accomplished by the careful use of this method. In some cases of cervical cavities good results can be obtained by hypodermically injecting a 1 or 1.5 per cent solution of cocain hydrochlorid into the pericemental membrane somewhere near the apex of the root. This practice should not be generally recommended.

Menthol, a stearopten obtained from the essential oil of peppermint, can be substituted for the cocain in the above prescription with ether and chloroform, and used in exactly the same manner. An oily liquid (mentho-chloral) can be formed by heating together over a water-bath or rubbing in a mortar, an equal amount of menthol and chloral. This remedy will be found efficacious by sealing in the cavity for a few days.

Oil of Cloves.—A profound analgesic effect can be produced upon sensitive dentin, especially in deep-seated cavities, by using oil of cloves and heat in the following manner: After carefully desiccating the dentin by means of warm alcohol and gentle heat, a pledget of cotton saturated with oil of cloves should be placed in the cavity and a current of heated dry air directed thereon until the cotton is nearly dry. This should be repeated as often as the case demands.

Eugenol, an oily product, is the chief constituent of oil of cloves and can be used in the same manner as above described.

Phenol.—It is gratifying to the author to know that in the last revision of United States Pharmacopeia (1900), the publication of which appeared Sept. 1, 1905, the product heretofore erroneously called carbolic acid has been recognized by its correct name, *phenol*. This agent can be substituted, with equally good results, for the oil of cloves or eugenol as described in the foregoing method. Care

should be taken here, however, in directing the heated air so as not to cause the fumes of phenol to escape on the patient's face. Oil of cloves, eugenol and phenol are three true *local anodynes*, and any one of which, if hermetically sealed in a cavity for a few weeks, will check the continued irritation of the fibrillæ and pulp, thus aiding nature to restore these structures to their normal condition when they should not be responsive. By this means, then, the sensitiveness of the dentin can also be allayed.

Ethyl chlorid, ether and chloroform, by their rapid volatility, produce a condition of analgesia, thereby obtunding sensitive dentin, as previously explained in this chapter under *cold*.

IV. *General Anodynes or Analgesics.—General anodynes or analgesics* are remedies which relieve pain without necessarily inducing unconsciousness or general anesthesia. They may accomplish their object by acting upon the perceptive centers of the brain, the afferent paths in the spinal cord, or the peripheral nerve through which the painful impression is transmitted (Stevens).

In order to do permanent work for certain highly nervous patients, it is sometimes necessary to resort to the administration of this class of drugs. The agents largely used for this purpose are:

Opium,	Nitrous oxid,
The bromids,	Chloroform.

Opium is a most powerful analgesic, and while there are some dental conditions where this drug, or its chief alkaloid, morphin, is truly indicated, it ought not, in the author's judgment, to be given for the treatment of sensitive dentin.

The bromids of potassium, sodium and ammonium are valuable drugs in certain cases. Perhaps there is no drug which will quiet a nervous patient more readily, when the nervousness comes purely from fear or dread, than potassium bromid, which is the representative of this class. In such cases, where it is deemed necessary, the following prescription will prove helpful:

℞—Potassii bromidi, ℥ jss
Syrupi sarsaparillæ comp., f.℥ iij—M.
Sig.—Take a tablespoonful in water after meals the day before coming to the office.

Nitrous Oxid.—There are several apparatuses on the market by which nitrous oxid gas can be administered through the nose. It is possible with such an apparatus to carry the patient just to the analgesic stage, and hold him there until a sensitive cavity has been

painlessly prepared. In cases where the operator feels that it is necessary to resort to this method, good results can be accomplished.

Chloroform.—With the patient in the upright position, chloroform can be carried to the analgesic stage and sensitive cavities prepared. Most authorities agree, however, that chloroform should not be administered unless the patient is in the recumbent position, and that the analgesic stage is the most dangerous. Death has been known to occur suddenly, after a few inhalations, in cases of marked idiosyncrasy against the drug.

The author would not suggest the use of chloroform for this purpose.

In closing this chapter, may I say that most patients who repose confidence in the operator, are sensible and are willing to stand some pain in the preparation of cavities in their teeth. With a true running engine, a steady hand, a *sharp bur*, and with the aid of some of the many remedies herein suggested, the operator ought not to expect nor to ask the patient to stand more than a small amount of pain in the preparation of the most sensitive cavity.

CHAPTER XII.

FILLING MATERIALS: THEIR CHARACTERISTICS, INDICATIONS FOR THEIR USE AND THE METHODS OF MANIPULATION.

BY ALFRED OWRE, M. D., C. M., D. M. D.

The dentist of today is, perhaps, more occupied with the treatment of caries, both in theory and in practice, than with any other branch of his profession. Although we recognize, in the prevalent custom of treatment by filling, only a provisional substitute for some more nearly perfect one at which, in our present stage of development, we have not yet arrived, it behooves us, until we shall have outgrown it, to study closely its methods and materials.

In the discussion of materials we are confronted by the fact that in the very nature of things there can be no one substance suited to all cases. There is, however, for every case a suitable material, or one which can be continued in use as such until, in our pursuit of the ideal, we progress to something more effective.

To acquire the art of filling teeth seems at the outset an Alpine task. A thorough understanding of the properties of various necessary materials will reduce difficulties immensely, just as in setting out for a long climb in the mountains the providing of guides and the study of maps will reduce distances and minimize dangers.

It will be the aim of this chapter to point out as clearly as possible the teleological value and characteristic properties of gold, amalgam, tin, cement, and gutta-percha. We shall try to suggest when and where to apply these materials in filling cavities of teeth to insure the highest degree of success; and also to describe the methods of preparation, insertion, and finish.

GOLD.

From the earliest days of dental surgery, gold seems to have been considered the filling material *par excellence*. It occupies a unique prominence in operative dentistry. The ancient uses to which it was put for royal and religious ornament rendered its more common properties familiar to the metal-workers of even prehistoric times. The greedy, but persistent, alchemists of mediæval laboratories have contributed to modern science the results of their research for "the philos-

opher's stone." Gold has had, therefore, one great advantage—that of familiarity—over the later filling materials whose properties were little known and in whose actions scientists were slow to become interested.

The appeal of gold, to primitive man, inhered in its peculiar combination of luster and yellow color. This color is deepened or raised in tone by the introduction of foreign substances, copper for the former purpose, and silver for the latter. In allotropic form it is susceptible of alteration to other than the original color. When reduced to a finely divided state by precipitation, violet, dark red, purple, brown, and even black may be produced. However, when burnished or fused, it again assumes its characteristic yellow color.

Another peculiar property of gold is its extreme malleability. In this respect it exceeds all other metals. It can be reduced by beating to $\frac{1}{370000}$ of an inch in thickness. It also heads the list in ductility. A single grain may be drawn out into a wire over five hundred feet in length. Both of these properties are modified or rendered *nil* by alloying.

As to the property of hardness, gold, when pure, lies between silver and aluminum. It is about one-third as hard as diamond. This property is generally increased by the presence of alloys, extremely small quantities of some elements (bismuth, lead, etc.) having a very marked effect, even to rendering the metal capable of pulverization in a mortar.

As regards tenacity, pure gold will hold a weight of seven tons per square inch. This property, also, is reduced by the presence of impurities.

The specific gravity of cast gold is 19.3, which can be increased by condensation. In some of its precipitated forms it may be as high as 20.3. The difference is accounted for by the annealing in the former case.

In general, gold is weldable in the cold state in proportion to its purity; a very minute trace, 1 in 1000, of foreign metal such as silver, copper, or platinum, is said not noticeably to interfere with its cohesiveness. This property is usually increased by heating.

The presence of other metals alloyed with gold renders it more susceptible to the occlusion of obnoxious gases. The cohesive power is decidedly lessened by surface gases such as ammonia, hydrogen, hydrogen phosphide, and sulphurous acid gas, all of which are attracted to pure gold, but to a greater degree when the metal is finely divided than when it is cast.

In the scale of conductivity, with silver first, at 1000 for both heat and electricity, copper is second, and gold third with a register of 548 for heat, and 730 for electricity.

Its solubility is proved in aqua regia and in mixtures producing nascent chlorine, bromine, and, under certain conditions, iodine.

The consideration of the qualities essential to a good filling material is a very important one. According to Dr. G. V. Black, the chief qualities are:

Indestructibility in the fluids of the mouth. Adaptability to cavity walls. Freedom from shrinkage or expansion after having been made into fillings. Resistance to attrition and the force of mastication. Of secondary importance are color, non-conductivity of thermal impressions, and convenience of manipulation. It should also be capable of receiving a polish.

Bearing its constant properties in mind, let us see how gold fulfills these requirements.

There can be no question as to its indestructibility in the fluids of the mouth; although iodine discolors it somewhat, it does not cause solution. It is highly capable of adaptation to cavity walls. There is neither shrinkage nor expansion; but the intermittent forces of mastication may work, together with the peculiar molecular structures, to produce some change in form. The yellow color and high burnish, so beautiful in themselves, are, as fillings, more or less of an objection from the esthetic viewpoint. The contrast in color between the gold and the enamel may be rendered less noticeable by attention to the outline form of the cavity. An outline may be varied for the sake of grace, without hindering the achievement of artistic results, bearing in mind, of course, that the application of gold is not, primarily, assumed to be inartistic. Conductivity is a decidedly unfavorable property. In regard to the manipulation of gold, we may say that, in general, it is difficult, and demands sustained effort. It is generally acknowledged that success with this material exacts close application and prolonged study. As to finish, a perfect surface depends only upon the gold being reasonably well condensed.

As to the use of gold, it is not easy to lay down set laws. When and where to apply it depend upon a close study of general conditions and upon the extent to which the operator's instinct for the eternal fitness of things has been cultivated. No aspect of dentistry demands keener judgment and finer appreciation of practical and esthetic values. Moreover, the physical condition and idiosyncrasies of the patient constitute a large factor in the problem. The age and state

of health, both general and local, must be taken into consideration. Mental traits, as well, will be weighed by the tactful dentist, since the immature mind, and that which is under imperfect nervous contro must be met with special resources.

It must be borne in mind that in man as in other animals the period of plasticity is the age of education. Organization and education, physical and mental, have sometimes reached a stage of balance early in life. When this happens, rather extensive gold fillings may be made for patients between the ages of ten and sixteen years.

Between twelve and eighteen, the age of adolescence, the powers of the body develop at a lower rate than those of the mind; and it would be unwise to attempt the insertion of large gold fillings unless the entire system of the patient be adequate to the strain.

As the patient advances in years, the physical and nervous resistance must not cease to be a matter of careful consideration. If this resistance be below par, or if all extra energy be needed to nurse some disorder, it is best to postpone large gold operations.

Locally we have many things to consider, such as conditions of the peridental membrane, the extent and acuteness of decay, the structure and strength of cavity walls, occlusion, wear and tear, the position of the tooth, accessibility, and possibly also the past hygiene and care of the mouth.

It is quite needless to say that no gold filling should ever be attempted in any tooth when there is manifest pericemental inflammation. The slight loosening of the tooth as a result of deposits, or of wear and tear, need not prohibit the insertion of gold; but if any great degree of loosening has taken place, gold is generally contra-indicated. Whether the membrane is abnormal or not, its resistance should be a guide. If caries is rampant, it is often advisable not to consider gold until more favorable conditions, or a period of immunity, ensue.

The firmness of the cavity walls may be insufficient to withstand the force necessary for the proper introduction of gold, especially if the strength of the bite is in the neighborhood of 175 pounds. Many malleted gold fillings fail in strong occlusions. They may also fail where the area of masticating surface has been lessened by extractions of molar teeth. In this latter case, it often occurs that proximo-incisal fillings have been literally pounded out, owing to the excess of work performed by the anterior teeth.

In regard to position, the tooth may be inclined to such a degree as to render gold difficult to insert, and, in consequence, preferably omitted.

The use of gold need not be restricted to any particular teeth, for instance, as has been often suggested, to the ten anterior teeth. It would be more scientific, and decidedly more practical to say that, other things being equal, we can use it wherever there is sufficient accessibility. So far, then, it becomes the ideal.

Much has been said about this material. In fact, it would seem that nothing more remains to be said either for or against it. When we consider that the future preservation of the teeth depends upon the extent to which recurrence of caries can be prevented, and normal conditions and functions otherwise restored, we naturally seek a filling material which will as much as possible further these aims. Statistics have been published showing that the average life of a gold filling is three years. Just so long as gold is used indiscriminately, and by all kinds of operators, will we have such figures.

But these are not the statistics by which we wish to be influenced. It debases our own standards, and works injustice to the best men in the profession of dentistry—those who are most influential, and who make up a very large proportion of the total number—to obscure their results by fusing with them the results of the incapable, and then striking an average. Such statistics are misleading. It would be much more to the purpose to take account only of those men who are preeminently fitted to practice dentistry. Such men are honest enough to acknowledge failures wherever they occur, and if data were gathered exclusively from them, some reliable figures would exist upon which changes could be based when it is found that the percentage of failures is becoming too high.

Not to go any further with this discussion, we may, for the moment, rest upon the statement that success hinges upon careful judgment in the selection of cases, as well as upon manipulation or technique of insertion and finish.

In all discussions of the subject, so much is said as to the importance of purity in gold, that it has been thought best to quote in full the Roberts-Austen refining process as given in Rose's *The Metallurgy of Gold:*

> Gold assay cornets, from the purest gold which can be obtained, are dissolved in nitrohydrochloric acid, the excess of acid expelled, and alcohol and chloride of potassium added to precipitate traces of platinum. The chloride of gold is then dissolved in distilled water in the proportion of about half an ounce of the metal to one gallon, and the solution allowed to stand for three weeks. At the end of this time the whole of the precipitated silver chloride will have subsided to the bottom, and the super-

natant liquid is removed by a glass siphon. Crystals of oxalic acid are then added from time to time, and the liquid gently warmed until it becomes colorless, when precipitation is complete, a point reached in three or four days if ten-gallon vessels are used. The spongy and scaly gold so obtained is washed repeatedly with hydrochloric acid, distilled water, ammonia, and distilled water again, until no reaction for silver or chlorine can be obtained, after which it is melted into a clay crucible with bisulphate of potash and borax, and poured into a stone mold. Lack of care in any one of the operations will result in gold containing one or two parts of impurity in ten thousand.

If further purity is desired, the gold may be redissolved and reprecipitated until satisfaction is attained.

Gold comes to us from the manufacturer in two varieties, foils and crystals. A complete description of the manufacture of foil occurs in an article entitled "Gold Beating" in the *Encyclopedia Brittanica*.

The sheets are usually four inches square, and the number by which each one is identified corresponds to the number of grains in the sheet; *e. g.*, in No. 4 foil each sheet weighs 4 grs., and so on up to No. 100, or higher. Above No. 20, the sheets are rolled out instead of beaten. They may be had smooth or corrugated.

Foils may be classified according as they lack or possess the property of cohesion. They are non-cohesive, semicohesive, or cohesive. Non-cohesive gold is made so by surface treatment, and although the process is not made public, we know that we can render pure gold non-cohesive by exposing it to ammoniacal gas.* The semicohesive golds, and some of the non-cohesive, can be made cohesive by annealing, which demonstrates that surface treatment had consisted, in this instance, of subjection to a volatile gas.

Some non-cohesive foils are permanently so, and the gases covering the surface are probably of the sulphur or phosphor groups, which cannot be volatilized by heat, but condense upon the surface.

Foil has been used for about a century, chiefly in a non-cohesive state. The discovery of its cohesive property, about fifty years ago, marks an era in the history of operative dentistry. It has made contour possible in its broadest sense, and the resulting advances are of tremendous importance. That the possibilities are not yet exhausted is another point which should encourage the profession towards progress.

The crystals of gold are obtained by precipitation. The manufac-

*Dr. G. V. Black, *Dental Cosmos*, Vol. 17.

turers guard their trade secrets so well that we do not know what precipitating agent is used. Oxalic acid, purified sulphurous acid gas, and other chemical reagents can be used, but at present these are largely replaced by electrolytic methods. There are on the market several variations of these forms, of which the fiber-like crystals are generally to be preferred. It is very probable that the crystals have a higher specific gravity, since they have never been subjected to fusion. They are usually sold in the cohesive state. Among qualities decidedly in their favor is a plasticity which renders them easy to manipulate.

There has been, and still is, some prejudice against gold in this form, owing to a variable quality which can be accounted for, in a measure, by the fact that crystals are more easily contaminated.

Although methods of preparation have been more or less faulty in the past, modern methods have given us a fairly reliable product, with the result that crystals have increased in use.

The dentist should procure a gold which is experimentally known for its good qualities; but he must always be on the lookout lest unscrupulous manufacturers permit deterioration.

There is a variety of ways in which the dentist can shape foil as wanted, and to suit the various cavities: the ribbon, mat, cylinder, pellet, or rope. In some of these shapes it can be bought ready prepared.

The ribbon is formed by taking as much as is required of a sheet of gold and, by repeated folding, reducing it to the desired width. The mat is made by simply folding the width of the ribbon upon itself according to size wanted; cylinders, by rolling the ribbon upon a flat broach. The pellet may represent from $\frac{1}{8}$ of a sheet upwards, rolled to a loose ball between the ends of the fingers. The ropes or rolls are made by rolling a part of the sheet between the thumb and forefinger, or between two napkins. The heavier foils need only to be cut into strips of suitable size.

Dr. Black recommends keeping the gold in a compartment where ammonia is present, thus rendering it non-cohesive, and protecting it from other gases. If desired, cohesiveness may, of course, be restored by annealing. For this purpose, gas, alcohol, or electricity may be used as a means of heat. Gas, alcohol, or any open flames are objectionable on account of contaminations, grain alcohol being the least so. A sheet of mica or a porcelain tray may be used between the flame and the gold, thus reducing the objection to a minimum. The electric annealer is by far the best.* It distributes the heat evenly

* The Custer electric annealer is generally recognized as the superior make.

and at varying degrees. It also does away with handling the gold during the annealing process.

In discussing the insertion of gold, it is assumed that the cavity is prepared according to the principles laid down in chapter on the preparation of cavities for fillings.

Non-cohesive gold is not used very frequently for the entire cavity, since surrounding walls are necessary to its insertion, and in this day of specialization few men are enabled to acquire skill in its application. There seem to be scarcely enough points in its favor to compensate for the time consumed in acquiring this skill. Its use is limited to simple cavities. As no union of the gold laminæ takes place, the wedge principle of insertion must be depended upon.

The cylinder is the best shape to use for this work. It should be somewhat longer than the depth of the walls against which it is to be forced. Several cylinders are placed endwise in the cavity, and forced against each surrounding wall with a wedge-shaped instrument, thus leaving a space in the center within which are placed other cylinders

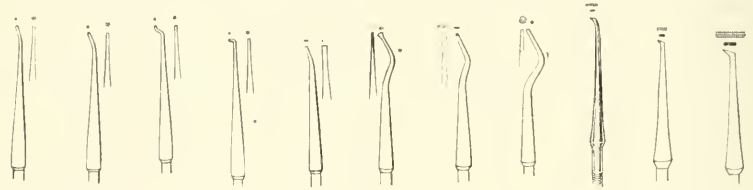

Figs. 187. 188. 189. 190. 191. 192. 193. 194. 195. 196. 197.

until it is impossible to make room for any more. The whole mass is then condensed by a suitable plugger point, the outer ends thus being forced as far as possible into the cavity. The cylinders should always be of sufficient length, so that, when tightly wedged and finally condensed, the cavity will be over full.

It is claimed for the non-cohesive filling that when it is used watertight margins are more perfectly made, and fillings are inserted with greater dispatch, provided the peculiar skill demanded for its manipulation has been acquired.

Filling cavities with cohesive gold, an art which requires years to master, demands less theorizing than demonstration, more actual experience than ponderous texts, so decidedly practical are all its details. Success is based upon many considerations, to some of which reference has already been made. The importance of modern cavity preparation cannot be too strongly emphasized, for upon it much depends. Separation of the teeth for the purpose of accessibility, and fixation to render the attachment tense, are also of moment.

A large variety of plugger points is needed to fill special wants, but for ordinary purposes the dentist confines himself to a few forms with which he has become thoroughly familiar. The illustrations, Figs. 187 to 197, will be referred to as occasion demands.

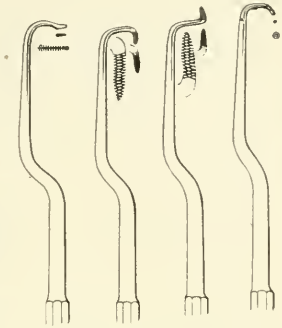

Figs. 198. 199. 200. 201.

The shank of each plugger should bend a few degrees so that it will not interfere with the operator's view of the working point. The modern law of accessibility in cavity preparation has limited the modifications in the shank to only three besides the above; namely, the bayonet, the right angle, and, for special work, the complete reverse. (Figs. 198, 199, 200, 201, 202.)

All should be finely serrated. It is also well to remember that .5 mm. is about as large condensing area of a point as should ever be used. The force necessary to condense gold with larger areas is generally unbearable, and is also liable to cause bridging over or imperfections in solidity. Small points which pierce the gold should not be used.

Another factor to consider is the manner of obtaining condensing force. Hand pressure is the simplest. The hand mallet, the automatic and other mechanical inventions, are all applied more or less. Dr. Black recommends the mallet in the hands of an assistant as the best means. It should be a rule always to place the gold where wanted in the cavity, and closely pack its laminæ with a light hand pressure, then mallet until the required solidity is obtained. The force should be so directed as to distribute itself evenly over the tooth-attachment; that is, toward the long axis. This causes the least inconvenience to the patient.

Fig. 202.

Perfect adaptation to cavity walls and margins, and adequate condensation, are the chief objects of attainment in these fillings. Both are interfered with by over-annealing. In fact, the very first pieces introduced in the cavity may be unannealed cohesive gold, which secures more easily, and with more certainty, the above-mentioned adaptation. Masses of gold, if too large, cannot be properly placed and condensed. For starting the filling, $\frac{1}{32}$ of a sheet No. 4 foil is quite sufficient, or

an amount that may be readily anchored into one angle of the cavity. It is generally not advisable to use a mass of gold the bulk of which is more than one-third the size of the cavity.

A solid plug is obtained only by carefully welding each newly added mass to that already in the cavity. In doing this, the force exerted in manipulation must not in any way distort the filling or interfere

FIG. 203. FIG. 204. FIG. 205. FIG. 206. FIG. 207.

FIG. 203.—Axio-mesio-distal plane. Showing gold started.
FIG. 204.—Axio-mesio-distal plane. Showing floor covered and advance of axial walls.
FIG. 205.—Axio-mesio-distal plane. Overfull and ready for finishing.
FIG. 206.—Longitudinal section, Bucco-lingual plane, mesial fourth, through retention form of cavity. Showing gold started. Dotted lines represent the outline form of the cavity.
FIG. 207.—Same as Fig. 206. Showing the union complete, and surface brought up.

with adaptation, but rather be so directed as further to insure adaptation and stability. The plugger should, therefore, generally proceed from the center to the periphery. It is never judicious to exert force on thin layers of gold covering flat surfaces. Moreover, in covering margins, especial care should be taken to have a good cushion of gold

FIG. 208. FIG. 209. FIG. 210. FIG. 211.

FIG. 208.—Longitudinal section, Mesio-distal plane, Buccal fourth. Showing gold started (as in Fig. 206).
FIG. 209.—Showing the progression of the gold building after gingival wall has been covered.
FIG. 210.—Same section and plane, but cut through middle of tooth. Showing locking of step, and proximal part of filling.
FIG. 211.—Same as preceding. Gold building complete.

over the margins, thus avoiding danger of the plugger point coming in contact with the tooth tissue.

In filling a simple cavity, the process of building the gold is illustrated in Figs. 203, 204, 205. Plugger points 187, 188, 191 and 196, are used in this class of cavities in the anterior teeth, and as we go back into the mouth the bayonet, 194, will also be needed.

The filling of a complex cavity is best illustrated in the mesio-occlusal of a first upper molar. (Figs. 206 to 211.) The axio-bucco- and axio-linguo-gingival point angles are first filled, and then the axio-gingival line angle is covered, starting from each point angle respectively, so that the surface represents an angle of 45 degrees with the axial or gingival wall, and the latter is built out upon until its margin is fully covered. The filling should then proceed swiftly to the contact point, and, in doing so, one should as nearly as possible preserve a flat surface; but the inclination from buccal to lingual may vary according to accessibility. For this part of the work pluggers 187, 188, 192 and 193 are used for starting the filling, and 194, 195, 196 and 197 for further condensing. The step portion of the cavity is started in the same manner as the simple cavity, but instead of building up over the missing wall, the operator laps the gold over the proximal portion, and builds the whole out until it is overfull.

The practice of making mesio-occlusal-distal fillings in one opera-

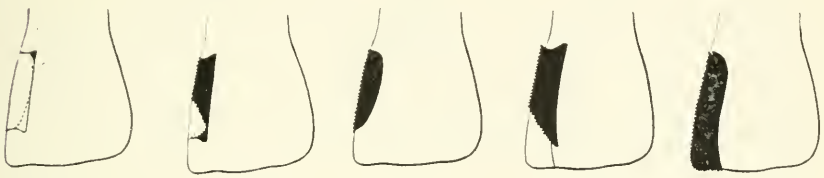

FIG. 212. FIG. 213. FIG. 214. FIG. 215. FIG. 216.

FIG. 212.—Mesio-distal plane. Showing the starting of gold.
FIG. 213.—Same as Fig. 212. Showing progress of gold building and union of incisal part with the rest of the filling.
FIG. 214.—Same section. Gold building finished.
FIG. 215.—Axio-mesio-distal plane. Showing process of gold building in cavities involving angle.
FIG. 216.—Same section as 215. Gold building finished.

tion should be discouraged. It is economy in every respect to make two proximo-occlusal fillings instead; however, they may be so interlocked as to represent the same outline form as the mesio-occluso-distal filling.

The proximal cavities of the anterior teeth present some difficulties owing to the fact that we have less surrounding wall. (Figs. 212 to 214.) For illustrative purposes take the mesial of a central incisor. The gingival point angles are filled first, and the axio-gingival line angle is covered as described in the preceding case. The surface of gold should then be built toward the incisal, preserving an angle of about 45 degrees, and it should be borne in mind constantly that the lingual portion is to be kept in advance. The incisal retention form is filled

as soon as the gold can be attached from it to the main portion, and the body of gold thus tied and strengthened.

Great care should be taken in covering the margin both lingually and labially at the proper time, and also in sufficiently contouring the lingual. In cavities involving the angle without a step, the building of the gold is continued to proper contour. (See Figs. 215 and 216.) Pluggers used for the gingival retention form are 187, 188, and 189; for the body of the filling, 195, 196, and 197; for the incisal retention at times necessary to add, 190.

When the incisal edge is involved, and the step preparation has been made, the filling of the proximal portion is proceeded with precisely as described until the step is reached. The retention form in the

FIG. 217.

FIG. 218.

FIG. 219.

FIG. 220.

FIG. 221.

FIG. 217.—Mesio-distal plane. Showing disto-pulpal angle filled.
FIG. 218.—Same as preceding, further progress.
FIG. 219.—Same as Fig. 218. Gold building completed.
FIG. 220.—Upper second bicuspid. Axio-bucco-lingual plane. Showing the three non-cohesive cylinders of gold in place.
FIG. 221.—The same tooth as that in Fig. 220. Axio-mesio-distal plane, showing partially condensed mass of non-cohesive gold projecting over gingival cavo-surface angle

incisal part is then filled from the disto-pulpal angle, and the gold built down so that its surface will present an angle of 45 degrees with the pulpal wall, and on towards the proximal portion, covering the incisal edge. Lastly, the union of the two portions is completed, and carried out to contour. The force exerted here should always be so as to drive the whole filling more tightly into its retention and resistance forms. (Figs. 217 to 219.)

In the filling of a mesio-inciso-distal cavity in the six anterior teeth, the proximal portions are filled as before; in filling the incisal portion, however, the center should proceed faster than the angles, and it is also best to build one angle out to contour first, remove the separator, and proceed with the remaining one exactly as before.

A great deal has been said about the percentage of failures of adaptation to the gingival wall in bicuspids and molars when using cohesive gold for the entire cavity, although on this point statistical figures may vary quite as widely as do opinions of what legitimately

may constitute such figures. Some of the best operators prefer to use a certain amount of non-cohesive gold in the gingival part of the cavity. The advantage is, besides better adaptation, a saving of time which is, of course, a vastly important factor in the economics of the question.

The non-cohesive gold should not fill the whole of the retention

FIG. 222.—Labial view of six anterior teeth. Showing contour and contact.

form. The usual method of procedure is to place one cylinder in the axio-linguo-gingival point angle, another in the axio-bucco-gingival, with a third between, and partially force them together with the pluggers 192 and 193. The cylinders used should be about twice as long as the gingival wall is wide mesio-distally to allow for after-condensation. (See Figs. 220 and 221.) The cohesive gold is now forced into the non-cohesive, using an assistant plugger, while locking the gold from the lingual to the buccal wall. Thus the cohesive gold

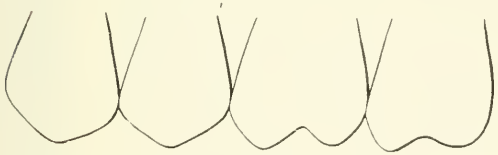

FIG. 223.

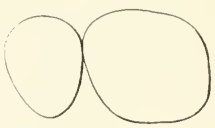

FIG. 224.

FIG. 223.—Buccal view of bicuspids and molars. Showing contour and contact.
FIG. 224.—Occlusal view of upper bicuspid and molar. Showing contour and contact.

really forms the fourth surrounding wall for the non-cohesive. Thence the filling is proceeded with as in the operation already described where cohesive gold was used for the entire cavity.

The final condensation of the non-cohesive gold takes place from the surface, by means of large parallelogram pluggers (see Figs. 197, 198, 199, and 200, the last three for distal surfaces).

In finishing, it is assumed that the cavity has been overfilled to allow for trimming away of enough gold to leave a perfectly smooth surface, and still have proper contour. The instruments and appli-

ances for this purpose are many. Of them, the following are indispensible: A plentiful supply of corundum stones in various sizes and grits, sandpaper discs and strips, the Wilson saw frame (Fig. 226) and saws cut down to a thread-like thinness, Dr. G. V. Black's trimming knives (Figs. 227, 228, 229) and Dr. E. K. Wedelstaedt's gold files. (See illustration, Fig. 230.)



Fig. 225.—Occlusal view of lower bicuspid and molar. Showing contour and contact.

Generally the first cutting is done with the aid of corundum stones or sandpaper discs and strips, depending upon locality, and, in proximal positions, the saw is an adjunct of great importance. Thereafter, the steel instruments, chisels and excavator for inaccessible places in occlusal fillings, trimming knives and files, and, for the final smoothing, cuttle-fish discs, pumice stone, whiting, or rouge, used with suitable appliances.

The chief watchword in this part of the work should be: Lacerate the tissues as little as possible; reproduce natural form plus the *needed* contour and contact point (Figs. 222 to 225); obtain as smooth a surface as possible so that an explorer will pass from filling to tooth tissue without catching. Always cut from the gold to the tooth tissue as far as possible. As to the use of the knives, only thin shavings should be cut, and the force should be directed so as not to disturb the filling.



Fig. 226.

Occlusal fillings are first ground down with corundum stones and water, starting with reasonably coarse grits, and finishing with finer ones. A variety of shapes is necessary in order to reach well into grooves and variations in surfaces. A good polish can be obtained by using fine, wet pumice stone powder applied with wooden wheels or points, rubber discs, or moosehide wheels. This may be followed with whiting and even rouge for a very high degree of polish.

In buccal, labial, and lingual fillings, the use of discs should be substituted for part of the corundum work; but both these materials are very liable to cut too much into the filling. The pointed fissure burs can be used over the gingival margin. The Black trimming knives and Wedelstaedt files are all of use here. The polishing is done as above indicated.

In the proximo-occlusal fillings the saw is passed under the gingival overhang, and should be first drawn carefully toward the contact point, and with it as much as possible of the remaining overhang

should be removed, or as much as the limitation of movement will allow. The trimming knives can now be used, and should be followed by the files, with some care to guard against too much cutting; the needed contour and symmetry of shape must always be remembered.

Figs. 228 227 229

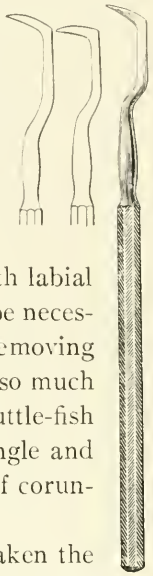

Further smoothing is done with sandpaper discs and strips, followed by the usual polishing process. It is often necessary to carry the polishing powders on linen tape over the proximal portion, in order to finish thoroughly.

In proximal fillings in the six anterior teeth, the first cutting is usually done with sandpaper discs and strips, although the corundum stones are material aids on both labial and lingual surfaces, especially the latter. It may also be necessary to use the saw, knives and files for the purpose of removing the gingival overhang; but they are perhaps not needed so much here as in the posterior teeth. Polishing is done with cuttle-fish discs and strips, and with the powders. The incisal angle and edge, when involved in a filling, demand a greater use of corundum stones and sandpaper discs.

Considered as a stopping, nothing as yet has quite taken the place of gold, although it cannot be said to apply perfectly to all cases. A full knowledge of its properties, behavior, and working qualities, is the first essential. With skillful instrumentation and bulldog persistance, one ought to be able to conquer the art of making nearly perfect gold fillings in a comparatively short time, say in from five to ten years.

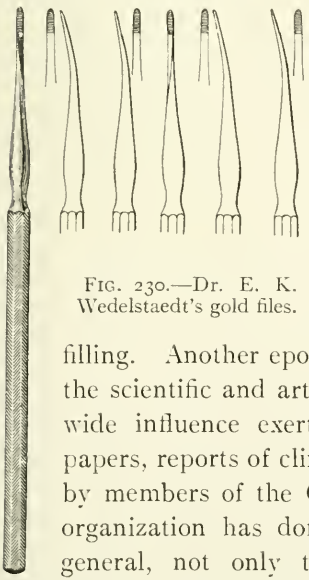

Fig. 230.—Dr. E. K. Wedelstaedt's gold files.

Reference has been made to the discovery of the cohesive property of gold as marking an epoch in the history of tooth-filling. Another epoch may be said to have been ushered in by the scientific and artistic work of Dr. G. V. Black. The world-wide influence exerted by this great worker may be noted in papers, reports of clinics, etc., published in the various journals by members of the G. V. Black Club (Inc.) of St. Paul. This organization has done much to simplify gold filling, and, in general, not only through its home meetings, but in state, national, and international gatherings, has done much to further the progress of operative dentistry.

AMALGAM.

Owing to the plasticity conferred upon an alloy of one or more metals with mercury, amalgam is usually spoken of among the plastic filling materials. What takes place in the union is the lowering of the fusing point of the alloyed metals by introducing mercury, a plastic stage thus ensuing before crystallization is complete. This plasticity and subsequent crystalization—both interesting phenomena—led to its introduction as a filling material.

The study of amalgam is somewhat complex because we have to deal with an alloy of certain metals not always constant in physical properties out of the mouth, and liable to still greater modification after introduced into the cavity as an amalgam. For various applications in the arts, metals are alloyed to gain specific ends not obtainable by any one of them alone: to increase hardness, strength, toughness, elasticity, and resistance to corrosion; to lower the fusing point; to modify color, etc.

Alloy making and application were known to the ancients, although they did not always produce what they intended to, nor did they know very much about the separate elements. Alloy for amalgam fillings was introduced in the first quarter of the last century. Things were done on a more or less empirical basis until the impetus of scientific method altered matters. Although formulas may not have changed markedly, there has been undoubted improvement as to certainty of procedures and results. It was the general lack of applied science which made it so difficult for amalgam to take its present place of usefulness, and we owe a debt of gratitude to all the zealous workers who have combined to give it that place. The early prejudice against it was due to its non-scientific composition and use. It is, perhaps, needless to say that amalgam has been criminally abused in the past, and that the better conditions which might naturally be expected from scientific workers have not been commensurate with their efforts. Its plasticity readily betrays operators into unwarranted speed—a fact which is only too soon recognized by the charlatan class.

Some properties of amalgam should be noted. Its color is grayish white. It is generally spoken of as brittle, although under certain conditions it manifests a degree of malleability known as "flow." It is harder than silver, but not very tenacious. Gases are condensed upon its surface to a larger degree than with gold. As to conductivity, all alloys have less of this property than do the simple metals. These properties are modified, first, according to the number and quantity

of the various metals added; and, second, according to the mode of making.

As to the manner in which amalgam fulfills the requirements of a filling material: It may be said to be practically indestructible in the mouth. Chemical action of any kind is always more energetic in alloys, hence amalgam unites easily with oxygen and sulphur. In adaptation to cavity walls, it is nearly as good as gold. The change in form in amalgam, due to contraction and expansion, so noted in the past, has been reduced by modern science to the minimum. It withstands attrition well, and, in general, the forces of mastication are not so manifest upon well-made fillings of this material as upon those of gold. Its color is one serious drawback. Its conductivity is low, far lower than that of gold. As to ease of manipulation, this property increases in proportion to the amount of mercury introduced in the alloy; but the operator must choose between this advantage and the superior one of firmness, for, if the latter be the desideratum, it must be had at the expense of the former. In susceptibility to polish, it fulfills the demand.

The properties of amalgam decide its application, to a large extent; for instance: its color limits its use to the posterior teeth, or where it is little noticed; the possibility of easy manipulation often determines its use in cavities inaccessible to gold. So then, generally speaking, it can be used in the bicuspids and molars, especially in cases where more nearly perfect results can be obtained than by the use of gold. However, if exposed to view to any extent, it is contra-indicated. We may say that so far as it is peculiarly adapted to such selected cases, it becomes the ideal material.

If success is to be obtained in amalgam work, the following points must be carefully considered: The individual metals used; the purity and the proportion of the metals; the manner of production; and the manipulative procedure. The study of the chemical and physical constants of the metals is imperative. As to the behavior of metals toward one another in alloys, it may be said that mixtures are not merely mechanical. They are in the nature either of a solution of one metal in another, or of a chemical combination. A chemical combination may be a pure one, or it may provide an excess of one of the metals in which latter case the excess is mingled mechanically with the mechanically combined constituents. Proportion, temperature, etc., of course determine the final manner or manners of the combination.

There is no hard and fast rule regarding the reciprocal action of metals in alloys. Some metals alloy easily in any proportions; some

less easily and in only set proportions; and again others alloy with extreme difficulty under any conditions. As a rule, metals of similar chemical nature have greater affinity as alloys than those which differ.

Mention should be made of the fact that only chemically pure metals ought to be employed. Otherwise, unaccountable variation will manifest itself.

The proportion of metals is of considerable moment. Experiments have shown that like quantities of metals alloyed alike produce certain results. Furthermore, the addition of a very minute quantity of some metals is capable of causing great modification in the properties of the resultant alloy. The manner of production is of tremendous importance, for instance:

If metals be heated to a temperature beyond the fusing-point, a different atomic grouping may occasionally result. The length of time they are kept in the fluid state, the mixing process, the various methods of cooling and casting, may noticeably modify an alloy. In some cases when cooled slowly, they will separate into several alloys of differing compositions; that is, the alloys with a higher fusing-point solidify first. This is spoken of as liquation. At the same time specific gravity may manifest itself so that the lightest alloys, if solidified last, may be uppermost. If liquation take place, there will be not only variation in composition, but also, to a marked degree, in the properties. Liquation should, therefore, be prevented as far as possible wherever constancy of properties ought to prevail. This can in the main be accomplished by rapid cooling.

It is clear then, that much depends upon the manner of production. The foregoing remarks may be made more clear by a description of the process of making dental amalgam alloy:

Take the formula 60 per cent silver, 35 per cent tin, 4 per cent copper, 1 per cent zinc. To make 10 oz. we shall need 6 oz. silver, $3\frac{1}{2}$ oz. tin, 8 dwts. copper, 2 dwts. zinc. Zinc is added in the combination of brass, because free it is easily volatilized and oxidized. The brass, however, should be of known proportions, say 75 per cent copper and 25 per cent zinc (a constant alloy). The weight will then be 2 dwts. copper and 8 dwts. brass. The brass, copper, and silver are fused in a plumbago crucible first. The tin is fused in a separate ladle, and added as soon as the first three are in fluid condition. Fusing all the metals at once has been tried, and analysis and experiment show greater variation. Some stirring is necessary until the pouring out begins. A quarter inch steel mold about four inches wide cools the alloys fast enough. One out of every thousand melts, as above, were

subjected to analysis by Prof. C. J. Bell in the chemical laboratory of the University of Minnesota. Five sections of the bar were made, and the percentage of each metal was very nearly the same in all, and according to formula.

If thicker castings be made, liquation is very liable to take place. The bar can be reduced by means of a twelve-inch bastard file, and strained through a brass wire mesh. Iron filings from file and bench vise may be removed by passing the magnet through for several minutes, and it is then aged by subjecting it to the temperature of boiling water for about twenty minutes; the mass is placed in a beaker, and introduced into a pot of boiling water.

The silver is added for its hardening and settling qualities; it also causes expansion. Tin is added chiefly to counteract the expansion caused by the silver, and to retard the setting. Copper increases hardness and strength, and has some effect upon color. Zinc heightens the color, and somewhat hastens the setting.

The percentages of dental amalgam alloys have been determined by experiment. For a detailed study of them the reader is referred to

FIG. 231.

the scientific investigations of Dr. G. V. Black (*Dental Cosmos*, Vol. 28, and elsewhere).

Dental amalgam alloys are classified as binary, ternary, etc., according to the number of metals added.

With amalgam the most vital point for consideration is the manipulative procedure. Not only is the percentage of mercury to be reckoned with, but also its incorporation, the compression of the mass, trimming and finish, are all elements that figure prominently in the results. One reason that this material has not reached a higher plane generally is a lack of sufficient study and attention to minutiæ and detail in the technique of insertion. This deficiency should be more widely acknowledged and repaired.

It has been the writer's privilege to observe several hundred amalgam operations made by Dr. F. H. Orton, of St. Paul, during the past twelve years. The results have been uniform, and as nearly perfect as are ever seen. His method of procedure is incorporated in the following description of filling a cavity with amalgam:

The cavity is prepared as for gold, with this difference, that the

enamel bevel should be somewhat longer. All cavities must be simple; if not so in the first place, they must be made so by adjusting a matrix to replace the missing wall. The matrix should be unyielding and fit closely to the tooth-surface. The amalgam is prepared by placing the mercury in the palm of the hand, and gradually adding the alloy until affinities are practically satisfied. The hand should be perfectly clean and dry. The incorporation of the ingredients is accomplished by rubbing with a glass pestle. (See Fig. 231.) Both judgment and skill are necessary to obtain the proper mix; a certain crepitus is noticed when the mass is about ready, and some experience will enable one to know when this point is reached. It should be an object to have as little surplus mercury as possible when the mixing is finished; therefore it is forced out in chamois skin or muslin with heavy pliers so much so that the mass should resemble a hard, flat cake which fractures sharply. In packing the amalgam the object is density and complete union of all the particles. As it is somewhat plastic, the plugging points should be as large as the cavity will permit, and with serrated surfaces (see Figs. 232, 233, and 234). Hand pressure as ordinarily understood is not sufficient; hence the aid of the mallet comes in, using bayonet shanks as illustrated. It will be found that it requires a rather heavy blow from the mallet to compress the amalgam, and that the blows must be repeated until the mercury appears under the plugger point. This surplus mercury is then removed by the aid of gold foil, the two metals having a marked affinity for each other. A cylinder of gold foil is placed upon the surface, covered with spunk, pressed down and removed. More amalgam is then added, and the process is repeated until the cavity is overfull. Importance should be attached to the removal of the surplus mercury whenever it appears; if allowed to remain, it weakens the mass. If care is taken, the amalgam will be sufficiently crystallized to admit of trimming immediately. For occlusal surfaces large spoon excavators should be used, and for proximal, trimming knives and coarse cuttle-fish strips and discs. Fillings in

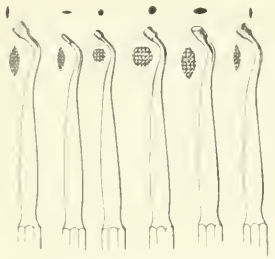

FIG. 232.—Black's hand pressure amalgam instruments.

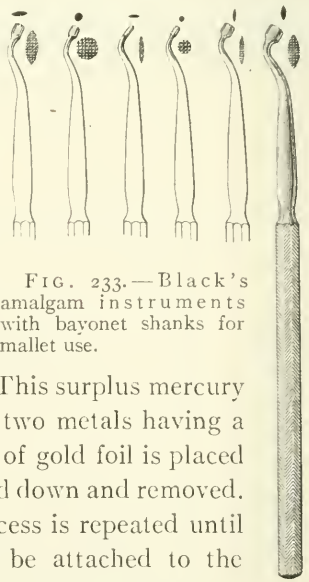

FIG. 233.—Black's amalgam instruments with bayonet shanks for mallet use.

other positions present few difficulties in trimming. The same instruments with some additional chisels or excavators for special inequalities will be found all-sufficient.

It is best to postpone for a day the final polishing. First corundum stones, and then powders, are used, as in the polishing of gold fillings. Since in time these fillings undergo a slight change in form, it may be necessary to refinish afterwards, as occasion demands.

The time required to make a good amalgam filling is nearly that required for gold; therefore were it not for the fact that in certain cases it excels all other materials, there would be no economy in its use. Many large cavities may be filled with amalgam when the malleted gold filling would be entirely out of the question. Restorations of considerable magnitude are often made, whereby teeth are rendered useful for a number of years.

Although amalgam is not proclaimed as the acme of desirability, it occupies a very high place as a tooth saver, and it is well worth effort and energy to increase our knowledge concerning it. There is yet a wide field open to the investigator in alloy making and application. With what has already been achieved, however, the student can and should thoroughly acquaint himself, and thus conserve time by eliminating the errors and profiting by the valuable discoveries of the past.

FIG. 234.—Owre's right and left amalgam instruments for use against matrices at junction of same with cavo-surface angle.

TIN.

For various reasons tin is still used by some dentists, and the ability to insert a tin filling is a test in some official examinations. Hence this material should be studied.

In color it is white with a tinge of yellowish-blue. When pure it has a bright, metallic luster, and although in normal air it does not easily tarnish, it readily occludes gases. It is fifth in the order of malleability, foil $\frac{1}{1000}$ of an inch thin being obtainable by beating. It is classified with the soft metals, and is also of a low grade of tenacity, being tenth in the scale at 2.1 tons per square inch. Its specific gravity is 7.3. It is weldable in the cold state if perfectly pure, and purity generally implies fresh-cut surfaces. When weldability has been interfered with by exposure to air, it cannot be restored by annealing. As to conductivity, tin ranks low: for heat, 154; for electricity, 114.

Tin has been used as a filling material for a century or more; but

it only partially fills the requirements of this purpose. It oxidizes readily in the mouth, is easily adapted to cavity walls, and undergoes no change in form unless subjected to wear, and, when so, the malleability and softness markedly manifest themselves. Its color is objectionable. So far as conductivity is concerned, it is low enough to be of value. The manipulation is very like much that of gold. It receives a fairly good polish. Occasional reference has been made to its therapeutic value, when used as a filling, as a preventative of caries, etc. This seems highly improbable, excepting insofar as it replaces the carious area, as does any other filling material.

Tin has been recommended for cavities which are not exposed to wear and tear, and is practically limited to simple smooth-surface cavities not exposed to view or wear. It may have some application to cases of young children, owing to its rather easy manipulation.

It is prepared for the dentist in several forms, but the foil is chiefly used, between Nos. 3 and 10. But, as this soon loses the property of cohesiveness, the dentist had better prepare the shavings of tin himself, when wanted, by casting an ingot upon a polishing mandrel, attaching to lathe, and, with a sharp tool, cutting as fine shavings as desired for the case in hand.

Its insertion is exactly according to the method pursued with gold, the only difference being that the plugger points may be more deeply serrated. The finishing, also, is the same as in the case of gold.

Since science has aided us in establishing the status of things, it would seem as if the future of the tin filling were somewhat dubious. Personal opinion need not obtrude itself here, for speculation belongs only to the field of theory.

CEMENT.

Among the applied arts, cement, in its various forms, has been in use for centuries. Its introduction to dentistry did not occur until about fifty years ago. Largely owing to lack of science, it has had a degree of difficulty in establishing itself as a filling material, as also had amalgam. For that matter, its *status quo*, all told, is still somewhat doubtful. Nevertheless, it serves many important and useful purposes—so much so that we have come to regard it as indispensable.

Of the three kinds of cement to be considered, *i. e.*, the oxychloride of zinc, the oxyphosphate of zinc, and the oxyphosphate of copper, the first is at present little used. The use of zinc oxychloride as "a stopping of hollow teeth" was first suggested because of its plasticity when freshly mixed, its subsequent hardening, and its apparent in

dissolubility. Its shortcomings were soon discovered, and various modifications of the powder and liquid were tried for the purpose of enhancing its qualities, but to no avail.

The oxyphosphate of zinc, introduced some years later than the oxychloride, gave promise of greater things. It has largely taken the place of the oxychloride, except for some special purposes to be noted. Upon it our main reliance was placed until quite recently —in 1891—when Dr. W. V-B. Ames, of Chicago, brought out the oxyphosphate of copper.

Some general properties of all cements should be noted: Plasticity, facility of setting, granular structure, low strength, porosity, marked solubility, and low conductivity. As to color, the oxychloride is nearest white, the zinc oxyphosphate has various hues, while the copper oxyphosphate is the blackest of black. The properties vary a great deal, according to composition and modes of mixing, especially those of density, setting, porosity, permeability, disintegration, etc.

To a certain extent all cements possess the essential qualifications for a filling. But they are not indestructible in the fluids of the mouth, especially under the free margins of the gum. The oxychloride is the worse in this respect. Their adhesiveness to cavity walls is of great value. Some cements undergo change in form, particularly through contraction. None resist attrition well, although oxyphosphate of zinc and copper wear much better than the zinc oxychloride. As to colors, highly artistic results may be obtained with some of them, but the black of copper oxyphosphate limits the application of it to unexposed places. Cements are practically non-conductors of heat, and are often indicated for this reason. As to ease of manipulation, they are undoubtedly first of all materials. They are incapable of receiving or maintaining a very high polish; although when first finished the surface may be fairly smooth, with wear it soon becomes granular. Some of them are, in general, less irritating to tooth tissue than metallic fillings, and this is one of the most important considerations. Oxyphosphate of copper has been found to be extremely bland when used near the pulp, or even in contact with gum tissue. In regard to the porous structure, this is capable of some reduction through modification of constituents.

Turning to indications for the use of cement: At present the oxychloride is not used to any extent as a filling for the entire cavity, because of its speedy disintegration, and the irritating character of the chloride. Many authorities agree in indorsing it as a cavity lining because of its white color, its density, and therapeutic value. It should

not be used too close to the pulp, because of the irritation likely to result, but it may be used to advantage in pulpless teeth for the larger portions of the canals and to fill the pulp chamber.

We are considering then, practically, only oxyphosphates of zinc and copper. Fillings prepared from these materials are spoken of as temporary, it being implied that they will be replaced sooner or later by more nearly permanent ones. While this is correct, we must not lose sight of the fact that some teeth will never be filled with anything more permanent, *i. e.*, cement seems peculiarly and preëminently to lend itself to the preservation of certain teeth. It is, *par excellence*, the material for use in all cases where for any reason no adequate cavity preparation can be made for the so-called permanent fillings.

It is also indicated in some other cases: those of very old people, and those of younger people in whose teeth caries is acute. In the latter case it is introduced as a temporary filling in the true sense of the term, in extending the usefulness of frail or deciduous teeth.

In discussing the preparation of cements, we are confronted with the large and insurmountable trade-secret proposition. The mere names indicate some of the chief ingredients; but of the various methods of production, the modifying agents used, etc., we have very little data. As it comes to the operator's hand, a cement is made up of a powder and a liquid. The powder of the oxychloride of zinc is composed chiefly of oxide of zinc, calcium oxide being often added to hasten setting, and other ingredients to obtain certain other properties, as silicate of aluminum, magnesium oxide, sodium borate, silex, powdered glass, etc.

The oxyphosphate of zinc is principally composed of glacial phosphoric acid and zinc oxide, to which are added, for the purpose of increasing hardness and lessening solubility, several foreign ingredients, *e. g.*, sodium phosphate gives the liquid a glassy consistence in handling. A chemical analysis of cements shows the following impurities:* arsenic, antimony, lithium phosphate, cadmium sulphide, carbon, fluorhydric acid, nitric acid, sodium carbonate, powdered glass, silex and water glass, sodium borate, magnesium oxide, magnesium nitrate, sodium phosphate, silicate of alumina, phosphate of alumina. The fineness of the powder varies not only with different makes, but occasionally with different lots put out by the same maker. The finer it is, the quicker it sets.

The oxyphosphate of copper is composed of the same liquid as

* Dr. J. E. Hinkins, *Dental Cosmos*, Vol. xliii, p. 591

the foregoing, and cupric oxide, with or without addition of other metallic oxides.

The preparation of cements for filling cavities is not very difficult, but some care is necessary. The phosphoric acid has a tendency to crystallize. To lessen this, Dr. Ames recommends keeping it in a telescoping glass cap bottle, instead of one with the cork fitting within the neck. The prime requisite in mixing is thorough spatulation. Powder should be added to the liquid in only a small mass at a time, and before use the mixture should attain a putty-like consistency.

In the case of oxyphosphate of copper, a creamy mix seems to give best results. It should be needless to say that the glass slab, spatula, and other instruments used in handling cements must be scrupulously clean and well polished.

Cements vary somewhat in their working qualities. Hence, good results can be made sure of only by more or less experience.

The cavity preparation for cement fillings is simplicity itself, since the adhesiveness of the material may be very largely depended upon for securing the filling to the cavity walls. The complete removal of caries should in every case be insisted upon, however. In inserting the material, one must remember to overfill the cavity, and to use as nearly as possible even pressure from all points. For this work broad, flat burnishers are usually employed. These should first be rubbed upon an oil-pad to prevent the cement from adhering to them. The filling should then be left thoroughly to crystallize before trimming, which process is accomplished with chisels, trimming knives, and occasionally burs. A fairly smooth surface may be had by the aid of fine sandpaper discs or strips.

The cement operation, with proper care, may be made a very successful one. That it has fallen in estimation somewhat, is due largely to the fact that the apparent ease of cavity preparation and of manipulation lend themselves to charlatanism. Used by skillful hands in the proper places, cement has, in spite of its lack of durability, a valid claim to a position among filling materials.

GUTTA-PERCHA.

The name *gutta percha* is applied to the inspissated juice of various plants belonging to the natural order Sapotacea. The term is of Malayan origin, *gutta* signifying *gum*, and *percha*, the species of tree from which the gum is derived. It is native in the Malay Peninsula, and although its use has long been known in the Orient, even back into antiquity, it was not introduced into the western world until early

in the last century, when its great possibilities in the realm of manufacture were recognized. It was taken up by dentists about 1850, and, according to Dr. J. Foster Flagg, it was then suggested as a temporary stopping for frail teeth, and was recommended for its ease of manipulation, its non-irritating and non-conducting character, its insolubility in the fluids of the mouth, and its reasonable resistance to attrition. He further asserts that with it he could make better fillings in certain places than with gold. Various modifications of it were introduced better to meet the dentist's requirements. But the difficulties attending its manipulation, its non-resistance to attrition, and the gradual gain of cement, have lessened its use. Lastly, the introduction of copper oxyphosphate has almost crowded it out as a filling for the entire cavity.

The properties of gutta-percha are its decidedly low conductivity, its blandness, or non-irritating character, its agreeable color, and its insolubility. It lacks hardness, even when foreign substances are introduced to increase this property. Its contraction on cooling is also an objection, as is also its more or less porous structure. It is insoluble in the fluids of the mouth; it can be reasonably well adapted to cavity walls; it changes in form, notably by contraction; it does not resist attrition; its color is not objectionable and is easily modified; it is the best material we have for non-conductivity; it is not so easy of manipulation as cement; it takes no polish at all.

Gutta-percha is indicated wherever a perfect non-conductor is needed; but as it cannot be used in any place where it will be subjected to attrition, it is decidedly limited in its application. It is especially applicable to the filling of small pulp canals in pulpless teeth.

Commercial gutta-percha is prepared by boiling and purifying in a number of ways. When nearly pure, it is of a grayish-white color which can be modified as desired. For dental uses the pink base plate gutta-percha seems to be best. It is colored by means of sulphide of mercury.

Its successful use involves considerable skill. It must be heated until soft enough to permit of its being adapted to the cavity walls. In this process it must never come in contact with the open flame. Various devices are employed for heating, such as porcelain trays to be held over the flame, or sand-bath. If overheated it is ruined. Ordinarily the instruments used are flat burnishers which should be warmed and oiled. The cavity should have some retention form, and it is also well to coat the cavity walls with oil of cajeput or eucalyp-

tus. Dr. Black remarks that these oils take strongly to cavity walls, and also slightly dissolve the surface of the gutta-percha, hence their value.

The material is packed piecemeal into the cavity, or *en masse*, care being taken to insure thorough adaptation. One should guard against obtaining too much surplus, for gutta-percha does not lend itself so well to trimming and finishing as do other materials, although surplus can always be removed by the aid of a warmed burnisher. Or, when it has sufficiently hardened, it can be trimmed with thin, sharp trimming knives, always cutting from center to periphery.

That gutta-percha has possibilities is undoubtedly true. It will in all probability be continued in use for some time to come. But, if personal opinion were not out of place, we might close this discussion by observing that the attitude of the dental world seems to the present writer to be that gutta-percha as a filling material for the entire cavity, all things considered, is distinctly altered since the virtues of copper oxyphosphate have been fully made known.

COMBINATION FILLINGS.

The term "combination fillings" has been made acceptable by usage, although it is not in all cases strictly accurate.

The fact that no one material possesses all the virtues desired, together with other reasons, as, for instance, the greater ease with which particular parts of the same cavity lend themselves to particular materials, have led to frequent indication of more than one material for the filling of the same cavity. A few of these will be taken up for discussion, although it must be remembered that endless combinations may be made, according to the necessities of the case, and the ingenuity of the operator.

Platinum and gold are used together, chiefly for resulting color and density. Platinum is bluish silver-white in color. Its specific gravity is 21.46. The color of the combination varies between light and dark gray, depending upon the quantity of platinum used. This platinum-gold combination withstands attrition better than gold alone. For esthetic reasons it is indicated in cases when patients are of dark complexion. It is also desirable when more density is sought than gold alone can supply.

Platinum-gold for filling is used in the forms of folds of both metals, of platinized gold folds, and of platinum and gold foil. It is best not to use it for the entire cavity, a surface of this composition being quite sufficient. Generally speaking it is manipulated in the same manner

as gold alone; but a little more care is called for in annealing and condensing. That is, it is easily overannealed, and a small condensing-area plugger point should be used and moved only its own width each time, thus insuring thorough condensation. It may be worth noting that this serviceable combination of platinum and gold has of late been replaced largely by the porcelain and gold inlays—the porcelain inlays chiefly in the anterior teeth, and the gold in many cases where great surface is to be restored for the purpose of resisting attrition.

The properties of *gold and tin* have already been considered. Tin has been used to fill part of a cavity, the finishing of which is done with gold. Tin was largely applied in proximal cavities to cover the gingival wall, in the same manner as non-cohesive gold; but this operation is practically discontinued, owing to what seems to have been a dissolution of the tin.

One method of preparing tin in this connection is to take it in sheet form, superimpose it upon a sheet of gold, cut to desired widths, and make into cylinders, as described under "Gold." A few operators use this combination in occlusal cavities in deciduous teeth, and in the gingival third of bicuspids and molars in the adult teeth to a limited extent.

It is handled in every respect like non-cohesive gold. It is undoubtedly true that this gold-tin filling may conserve certain teeth; but recent investigation has led to the improvement of amalgam and its consequent preferment over the gold-tin combination in many cases where the latter might formerly have served. Also, in the gingival portion of cavities there seems to be an increase in the use of non-cohesive gold alone; so that, on the whole, the outlook for this combination is not the most encouraging.

The *gold and amalgam* combination is, at times, of great value, amalgam being used either to fill inaccessible parts of cavities, as below the gingival line, or merely to lessen the bulk of gold in very large cavities. In complex cavities it is often admissible to fill, for instance, a disto-occlusal cavity with amalgam, and the mesio-occlusal with gold, making a step into the amalgam.

Gold and Cement.—Besides using the cement for its inherent virtues, it is also employed to lessen the bulk of gold in large cavities and in pulpless teeth.

The *amalgam and cement* combination is used similarly to the foregoing. Cement is also used in amalgam operations to strengthen weak walls, in which case it practically becomes a cavity lining. Frail teeth can often be thus preserved for a remarkably long period.

Cement and Gutta-percha.—Owing to the fact that gutta-percha is not soluble in the fluids of the mouth, it can be used in the gingival portion of proximo-occlusal cavities, cement being employed, since it is somewhat denser, for finishing the rest of the cavity. In general, it is not advisable to let metallic fillings rest upon gutta-percha, owing to lack of firmness in the latter; but a cement intervening will afford the proper support.

It is difficult, if not impossible, to acquire from a text-book the art of filling teeth, be the text ever so explanatory and complete in detail. Theory must be supplemented by practice. To strike an even balance in this respect is a task of some proportions. In filling teeth, we imitate the work of others. Possibly we perfect a detail here and there, make a new discovery, or improve a method. The imitative aspect of the profession predominates, however. But this should not discourage us. All told, the world we live in is an imitative one, the absolutely new things discovered from decade to decade being very few indeed.

Although his technique may have been revolutionized, the art of the sculptor has not changed since Phidias wrought upon the Parthenon or that unknown and remoter hand carved the Sphinx's features in the Valley of the Nile. The bases of the arts do not shift with the years; that which is of permanent value rests upon solid foundations like those of the Sphinx or the Pyramids amid their waste of unsteady soil. That which is good abides, and our own virtues may be measured according to the degree in which we show ourselves appreciative of the virtues of those who have laid our professional foundations.

We might say that we have now reached a certain stage of perfection in the preparation of cavities in teeth, and also in filling them with gold and other materials. Such advancement as has been made should be rigidly maintained. We should not, however, be content to rest upon achievements. We must keep the mind receptive to possibilities, and the hand pliant and supple to slowly evolved technical inventions.

We have often seen and heard emphatic statements from operators to the effect that gold is the ideal and only filling in all cases, and that they use nothing else. Such statements are misleading to beginners who many times take them too seriously. Experience soon teaches that one cannot successfully adapt gold to all cavities. But the question, "what is the best filling?", implying that one material for all cases is possible, will often be heard from both scientific and unscientific people. Of course, the question cannot be answered as it is put. The whole of the foregoing chapter demonstrates this. An attempt

at least has been made to elucidate the fact that any one of our materials is the best one for the special uses to which experience has taught us its properties have peculiarly adapted it.

But supposing that we were actually limited to a choice of one kind of material. In that case we might, perhaps, choose what, in dental parlance, is known as the *gold inlay*—an alloy of gold, silver, copper, and zinc, cemented into the cavity. A discussion of this appears in Chapters XIV, and XVII. This supposition, although quite imaginary, tempts speculation.

Each material should receive the highest possible attention from the operator as it comes into his experience. The object should always be to perfect oneself in the intelligent application and manipulation of materials; and this can best be done by regarding each, as it is indicated, as the ideal. This, indeed, it is, when once its properties are found to harmonize with the needs of the case under treatment.

In closing, perhaps it is well to reiterate that increase in technical proficiency is stimulated if accompanied by growth in a general understanding of the eternal fitness of things—an appreciation of proportions and harmonies, not only in our own specialized branch of the great world of science and art, but in all that we can, by industrious study, bring from that world within the range of our intellect. The whole world of artistic endeavor—literature, music, design, painting, sculpture—every division of the industrial and liberal arts—teems with lessons for the worker in so exacting and delicate a profession as that of dentistry. "It is all triumphant art, but art in obedience to laws." Dentistry itself, regarded in its true light, must, in the minds of intelligent operators, come to be regarded as not the least among modern industrial arts.

For one who acknowledges allegiance to this broader supremacy, the practice of our profession should, so far from narrowing a man's powers, continually expand them, and afford more and more intellectual satisfaction as he progresses towards the ultimate ideal of perfection.

CHAPTER XIII.

THE USE OF THE MATRIX IN FILLING TEETH.

BY GARRETT NEWKIRK, M. D.

Matrix—Definition of; Standard Dictionary: "That which contains and gives form to anything: as a plaster matrix for a cast." From mater (mother). The term is used in connection with descriptive anatomy, geology, biology; also applied to forms for stamping coins, medals, types, etc. Pronunciation, ma′-trix or mat′-rix. Pl., mat′-ri-ces or matrices. "In dentistry—a strip used as a dam in filling side cavities."

It will be observed that the primary use of the matrix is that of giving form to a new structure; in nature to a growth, in art or mechanics to a building or product. In general the term applies to a product which is entirely new, a coin or medal or die. In dentistry we have a modified application of the term in that the matrix is used for *the restoration of pre-existing forms* that have been to a greater or less extent broken down.

The term "*filling*," as usually employed, does not fully express our meaning. It is commonly said by the dentist that he has "filled" a tooth, as if the tooth were only a hollow form, a capsule, a membranous sac, or a shell like that of a cartridge. The incongruity is obvious. Simple cavities in teeth may be "*filled*, and to this class of cases the term should be limited. What we are really called upon to do in most cases is to build up, to restore, the parts of a structure that have been lost. This we do with a substitute material, joining it as best we may to the remains of the natural organ.

We may liken the teeth, if we will, to a double row of monuments. The relation of these monuments is such that they are inter-dependent. The loss of one is felt by others. Each is dependent on its fellows for its own true position and usefulness. These monuments come to us broken, with every degree of injury, demanding repair or substitution. Some are like trees in Africa that have been honeycomed by the insidious white ant. Some are like houses half torn away by a cyclone or an earthquake. They are in part ruins.

The restoration of these monuments in proper form and of material to endure is no simple problem. No two are quite alike, their forms

are almost infinitely various. There are no plane surfaces. The study is one of curved lines.

The mechanical matrix is a temporary wall, placed for the support of building material that is more or less soft and yielding. A familiar example is that of a board employed in the making of a concrete walk, which holds the material in form till it hardens.

The use of the dental matrix is fourfold:

First, to serve as a wall of resistance, so that under pressure the building material may be thoroughly condensed and joined to the tooth. Second, to give the general shape of restoration, with a sufficient excess of material for finish and form. Third, in cases where plastic materials are used that require time for hardening and the matrix is kept in place till the new body has become fixed in its position. Fourth, to hold back the interproximal gum tissue, also the rubber dam, from the cervical border of a cavity, so that perfect contact of the building material at that place may be assured.

MATERIALS AND FORMS OF THE MATRIX.

The ideal material is that combining the greatest strength with thinness and spring temper. It appears to be the consensus of opinion that no other substance possesses so many excellencies as very thin steel. Ribbons of rolled or sheet steel, cut in suitable lengths, are best adapted for general use.

For the first really practical band matrices made of thin steel, the profession is indebted to Dr. T. W. Brophy, who made up a "set" with an ingenious method of adaptation. These were placed on the market about the year 1886.

Since that time many others have been brought out, generally under patent, though it is a question whether the original Brophy matrix did not cover the essential features of most of them.

Tinned copper or German silver, rolled thin, are practicable materials for band matrices, being easily adapted and soldered to fit special cases; for example, where the greater part of a molar or bicuspid crown is to be built up with amalgam, and where it is necessary to have the whole of the base encircled. In such instances it is not possible to obtain the best supporting matrix without making one especially for the case in hand.

A good, practical, special band matrix may be made of the softer materials mentioned, as follows: A ribbon of proper width is cut half an inch longer than the measured circumference of the tooth. It is passed around and pinched together closely with pliers. A piece of

binding wire is wound several times round the matrix ends at the line of juncture, and twisted tight. The projecting ends of the matrix band are now bent back and down upon the band proper and the appliance is ready for use. To do this last part neatly it is well to pass the band over the anvil point or any suitable form so that a small hammer may be used for the flattening.

Nearly always a band matrix made for the case in hand will have its basal circumference smallest. If the form of restoration has been right the body enclosed holds the matrix fast, and it must needs be disjointed or cut for removal. A continuous band matrix to be used and removed entire must be of necessity too large in its rootwise circumference or too small at the crown. If large enough to provide for the proximal contact points it will project far into the interproximal space, leaving a gap between the cervical edge of the matrix and the tooth.

Theoretically, we are told that this condition is to be overcome by use of a wedge at the cervical margin, but this, particularly with a steel matrix, is easier said than done. The material resists strenuously at both points, and the resistance reaches all around the band. Usually it is neither accomplished nor attempted. The operator fills the matrix as it is, leaving the building material projecting and ragged at the base, often impinging on the soft tissues. It is difficult afterward to remove this projection with chisels, files or corundum strips without laceration of the gums and pain to the patient. Therefore, it is very important that the matrix in its introduction should pass close to the tooth, between the hard and soft tissues, never impinging on the latter. It cannot be forced down midway in the interproximal space and afterward wedged forward to place without injury. It should go to its proper position at the first.

Any sort of band matrix, continuous or jointed, whatever may be its merits has one disadvantage. It comes short of the ideal in that it requires the use of two interproximal spaces. This involves often difficulty of adjustment with loss of time, both in the putting on and taking off; and the extra, second space is taken where all available room is needed on the side to be built up. It is an advantage to have the sound side of the tooth crowded against its next neighbor with nothing between them. This was long recognized as a consummation to be wished, but it seemed necessary that in general the matrix must be continuous around the tooth to insure a rigid support.

It seems to the writer, however, that by the use of the "Ivory" matrices and their accompanying clamps, encroachment on the second space may be avoided in the great majority of cases. Just as the

"Perry" separator gets resistance on the inclined planes of the teeth instead of their disto-median axes, so the "Ivory" matrix clutch utilizes the inclined planes of the sound portion of the tooth to hold the matrix of restoration. The principle of the instrument is simplicity itself, and the mechanism highly ingenious.

Of *continuous band matrices—i. e.*, those that go round the tooth far enough to occupy two interproximal spaces—there have been many

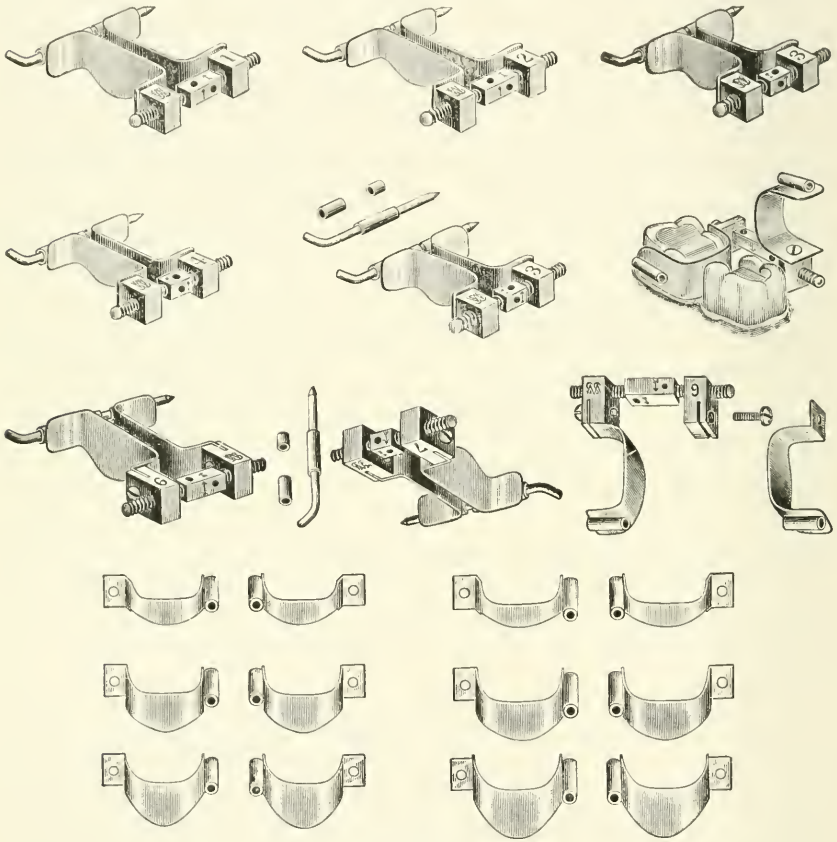

FIG. 235.—Crenshaw's Matrix.

forms invented and placed on the market; some of them patented. Cuts are reproduced here of the "Crenshaw," quite popular in the East, and the "Hiniker," in general use on the Pacific Coast.

There are others, any one of which may be of value, when ruled by skillful hands.

A form of appliance that has been widely advertised and recommended is that which we may style the "*double*" matrix, consisting

practically of two segments backed together and used for building up the disto-occlusal wall of one tooth and the mesio-occlusal of another at the same time. Certainly the principle of such an operation is not just right. Such restorations it seems to the writer should be made separately—one at a time; for the two teeth are not immobile, each moving slightly with any exercise of force upon it. The matrix should be firmly fixed to the tooth that is being operated upon. In the in-

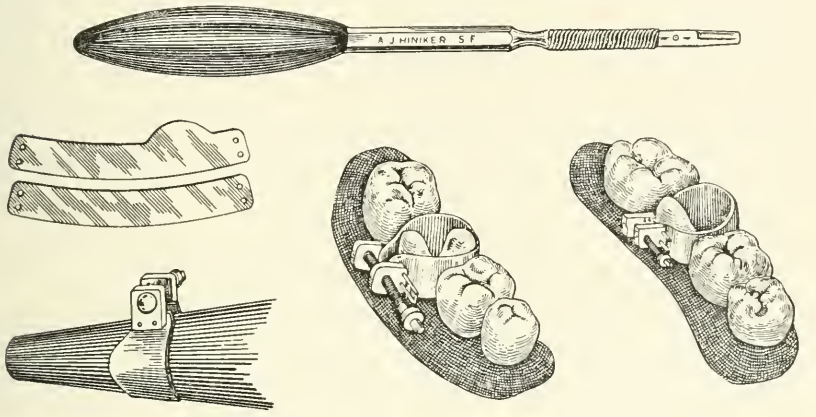

FIG. 236.—Hiniker matrix.

sertion of the single "filling" the tooth and the material move together as one body, and the latter is in no wise disturbed. With two teeth at once, each possessing independent motion, this cannot hold true—the material is likely to be in some degree disturbed.

THE "HAND" MATRIX.

This instrument consists of a short, thin blade, continuous with a shank and handle. It is a valuable instrument in certain places where the band matrix is hardly applicable. It is specially useful for giving form to fillings of cement or gutta-percha, and not infrequently for amalgam restorations. Such a matrix may be readily made by the dentist himself out of any discarded instrument that has a sufficient body of steel for the blade—a spatula or thick chisel for example. The secret of success in getting the desirable tough spring temper consists in persistent hammering with the avoidance of high heat. It may be added also that any other than the finest of files should not be used in dressing down the blade to the required thinness.

For use, with everything in readiness for quick manipulation of the building material, the matrix blade is placed in position and held by

the left hand of the operator. It is seldom that an assistant can manage it as well. The handle is given a strong twist, so that the rootward edge is held firmly up to the cervical margin of the cavity. The opposite edge is held with equal firmness against the crown of the approximating tooth. If either or both of the teeth are at all movable a considerable separation may be obtained by this steady twist of the handle. A sense of firm resistance, too, will be experienced while pressing the "filling" material home. The separation obtained should be equal at least to the thickness of the matrix, so that when it is withdrawn there will be sufficient fullness of material at the "contact" point. For restoring the disto-occlusal walls of a short crowned second molar, where it is sometimes impracticable to apply the rubber dam, and the work should be done quickly; and for incisors in making large restorations with cement, the hand matrix is a very useful instrument.

A FEW DETAILS AS TO MANIPULATION.

Success with the matrix often depends very much on previous preparation. Deep-seated cavities are frequently bordered by swollen, sometimes overhanging gums. It is nearly always better, after a free opening and more or less of preparation, to let these carry a filling of gutta-percha for some days. It is not unusual with the writer to have in one mouth several of these gutta-percha filled cavities waiting for the matrix and restoration.

Before placing the matrix for an operation, if there is any doubt of its fitness it should be tried in tentatively, to ascertain whether it will pass as it should, close to the tooth wall and not upon the gum. Sometimes an ill-fitting matrix may be fairly adapted by pinching in the cervical edge with pliers. The Ivory matrices, however, are so shaped and may be so inclined in their introduction that they go to the right place easily in most cases.

INTRODUCTION AND MANAGEMENT.

It is commonly advised by experts that as a rule the matrix should not be completely tightened at the beginning, but only after the insertion of a third to one-half of the filling. Without doubt we may say that very many operators do not take sufficient pains with that same first one-third. Of amalgam altogether too much is likely to be placed in the cavity at the start. Smaller pieces should be introduced at first and thoroughly condensed with smooth instruments all along the cervical wall and its junction with the matrix. This takes so much time that often a second "mix" of quick-setting amalgam is required

to complete the operation. Sometimes with extra dry alloy one may use a mallet with good effect.

In the second half or last third of the filling, whatever the material employed may be, enough force should be exerted against the matrix to induce separation of the teeth by a space not less but more than the thickness of the band. If the teeth have been prepared by gutta-percha wedging, as above suggested, this necessary crowding apart is an easy matter. As stated before, there ought to be an excess of the new material to allow for final shaping, and there ought to be likewise a separation of the teeth beyond the normal at the completion of the filling. This will permit the final contact point to come slightly below and away from the border of the occlusal surface, otherwise it will be a mere edge continuous with the occlusal surface, and not the rounded, finished knuckle of nature's plan.

There would be an improvement at this point, no doubt, if the operator would take the pains to make in each matrix a sufficient concavity with contour pliers, to bring the filling nearer the ideal form. As it is, with any common form of matrix, the filling as the band leaves it shows only a straight profile from the cervical to the occlusal border. The contoured matrix, however, used for a plastic filling could not be removed at once without disturbing the form. It would need to remain till the material had set.

REMOVAL.

With amalgam there are, as we know, advantages to be gained by leaving the matrix in situ till the material has become hard; indeed, it is very necessary to do so in cases where reconstruction has been extensive and the basal support relatively weak. But, on the other hand, there is something to be gained by immediate removal. This is one of the advantages of an open matrix like the "Ivory." When the clutch is loosened it "lets go." It is readily straightened, being flexible, and touches the tooth or filling only at the point of contact. With the lightly oiled surface a band should always have it is easily removed by gentle manipulation. Then, with a properly shaped blade, half knife, half burnisher, a trimming and close condensation of the material may be made all along the edges. I believe that perfect borders can be made in this manner with greater certainty than is possible otherwise.

EMPLOYMENT OF THE MATRIX FOR GOLD RESTORATIONS.

We know what the bevel of a margin should be for the reception of gold. We know that for the proper condensation of gold over such

a margin the instrument would better have free play; and we know that it is well to have visual as well as mechanical access to the area involved. There is no denying that the matrix does shut off seeing along the very lines where seeing is desirable. If we permit a loose adjustment of the matrix in order to see the margins it is of little use. It is likely also to crowd upon the gum tissue, to draw the edge of the dam from the tooth and induce leakage. If closely adjusted, the matrix forms with the beveled margin a sharp, acute angle, into which the gold must be forced accurately and condensed, else there is left an imperfect line of union. We cannot be as certain with as without the matrix that the gold is being adapted accurately at every point. Undoubtedly there are operators who have learned with much of patience and experience to obviate the risk; who can apply the matrix over a deep-seated cavity and make a good restoration from start to finish. But such operators the writer believes to be exceptional. It is a fact of experience that we are often called on to renew or repair fillings that have been so inserted which have failed at the cervical or cervico-lingual or cervico-labial borders; and we find others that are spongy or pitted or grooved in those places. Let it be understood, however, that after a substantial body of gold has been placed along the wall and angles of the cavity, then the matrix may be of service as a guide to the general form of building, especially for the full extension and thorough condensation of the "knuckle" at the contact point; and possibly the work may be done more rapidly.

If one is determined to take the risk, whatever it may be, of using the matrix "from start to finish" for contour restorations, he *must* familiarize himself with the properties and manipulation of non-cohesive gold. It is the chief dependence of successful operators for the basal third or half of the restoration.

GUTTA-PERCHA FILLINGS.

For the insertion of these the matrix has a well-defined use. Aside from those cases wherein it is necessary to crowd away the gum for a subsequent operation, the margin of a gutta-percha filling should be carefully made like any other. Patients often suffer discomfort and sometimes real injury from carelessly made gutta-percha fillings. It is better to make a filling of good form to begin with than to crowd in an ill-defined mass to be trimmed up afterward, and for this purpose the "hand" matrix is usually well adapted.

CHAPTER XIV.

INLAYS.

BY C. N. JOHNSON, M. A., L. D. S., D. D. S.

The Principle.—To repair a carious or abraded cavity in a tooth by the inlay method the operator adapts a piece of heavy foil, either platinum or gold, to the cavity so that it fits perfectly, thus reproducing the form and outline of the cavity in metal; and in the matrix so formed, removed from the mouth, he builds a filling of porcelain or gold and cements this in the cavity. In the more recent developments in gold inlay work a wax model is made in the cavity, and this is reproduced in gold. The principle is different from that of the ordinary filling, the latter being adjusted piece by piece into the cavity in the tooth, the entire operation being performed in the mouth; while with the inlay much of the work is done outside the mouth and without the necessity of the patient's presence. This is a very great advantage of inlay work and has led in a large degree to its popularity. The relief from the tedium of long and sometimes painful sittings has been a source of great satisfaction not only to the patient but to the operator as well. There is less nervous tension and altogether a greater measure of comfort in doing inlay work than in such operations as large gold fillings, and this phase of the subject has appealed very strongly to patients.

INDICATIONS FOR THE USE OF INLAYS.

That inlays have become an important factor in reparative processes in operative dentistry there can be no question. There is still some difference of opinion as to the precise range of their applicability, but for certain well-defined cases their utility is no longer in doubt. It must, therefore, be apparent that no dentist can practice to the best advantage for himself and his patient without an understanding of this work. There are many cases of affected teeth that can be better preserved by this than by any other method. In cases of extensive decay it may frequently be made to save a tooth which otherwise would be condemned to crowning, and on general principles the longer a tooth can be saved without a crown the better it is for the patient.

From the nature of their method of manufacture inlays are restricted in their use to cavities which will admit of the matrix or wax being inserted and removed without distortion, or cavities which may be made of such a form without an unwise sacrifice of sound tooth tissue.

Porcelain inlays are indicated chiefly in cavities exposed to view in talking, laughing, or singing. It should be the highest aim of art in dentistry to conceal the evidence of our operations from public view, and the conspicuous display of gold so frequently seen in the anterior teeth of patients speaks of a lack of taste which is something of a reflection on the profession. Fortunately this display is less prominent than formerly, and this in large measure is due to the introduction of porcelain inlay work. With porcelain an operation may be made which is not conspicuous at conversational distance from the patient, and in some instances the porcelain may be shaded to match the enamel so perfectly as to defy detection even on reasonably close observation. This is a great step in advance so far as the art side of our calling is concerned, and every dentist should equip himself to take advantage of it.

But this work has its limitations which should be recognized by every conscientious operator. The physical characteristics of porcelain are in some respects very much against its extended use, particularly in positions where the stress of mastication comes forcibly upon it. Porcelain is brittle and will fracture easily. It is therefore contraindicated in cases where the filling must be made with thin margins or in small bulk. It is true that in the anterior part of the mouth where esthetic considerations are very important it is frequently justifiable to take some chances of its fracture and place it in positions of prominent exposure even with some risk of failure. Patients are often willing to take this risk for the sake of the improved appearance over any kind of a metal filling, and where there is a perfect understanding between operator and patient as to the possibilities of failure porcelain may be given a rather wide range of application in the anterior teeth. Porcelain inlay work has not been sufficiently long in general use to afford the necessary data upon which to base reliable judgment as to its probable permanence, and many of these cases where great risk was apparently taken the service of the inlays has been surprisingly satisfactory. It may also be stated that in many other cases where the same care has been exercised in their manufacture, and where conditions would seem to favor their utility they have proved a grievous disappointment. It is this element of uncertainty with inlays which has made many of our conservative practi-

tioners look with disfavor upon the work, and yet their demonstrated utility in so many cases is sufficient to argue strongly in their behalf.

It is probably true that much of the failure has been due to imperfect methods of manipulation and to a lack of knowledge of the underlying principles of the work, as well as to faulty technique in carrying it out. Another uncertain factor has been the cement. This material has proved itself peculiar in its behavior under various conditions and some of its peculiarities have not been well understood. In addition to this, much of the cement used for inlay work in the past has been made for fillings and for cementing crowns without regard to the peculiar requisites for inlay work. Neither have the correct principles of cavity preparation for inlays been generally recognized or put in practice.

In short the work has had to pass through the experimental stage of a new line of effort and has suffered accordingly, but these factors of failure are rapidly being eliminated and we may confidently look forward to more assured success since the principles are being better understood and the technique systematized; though with porcelain inlay work it must not be forgotten that it will always have the one serious limitation of friability of the material itself.

Gold inlay work has a much wider range of usefulness so far as serviceability is concerned than porcelain on account of its great strength, and it should be used quite generally wherever inlay work is indicated in places not exposed to view. Gold may be made to protect frail walls of enamel if necessary and the material itself may be extended into thin margins without danger of fracture.

To specify the particular classes of cavities where inlay work is indicated and draw a distinct line of demarcation between the indications for fillings and inlays is difficult, owing to the varying conditions which are presented in different cases. The preference of the patient must sometimes be considered, though it is not well to allow a whimsical prejudice to influence the operator to do a certain class of work under conditions where it is manifestly contra-indicated. It may be said in general that porcelain inlays are indicated in all cavities exposed conspicuously to view in cases where esthetic considerations are very important, such as cavities in the labial or buccal surfaces of incisors, cuspids and bicuspids, cavities in the proximal surfaces of those teeth where there is much exposure, and in contour operations involving two surfaces where a display of gold would be objectionable.

Gold inlays are indicated in large restorations in bicuspids and molars, in cavities far back in the mouth where the problem of insert-

ing an ordinary filling is difficult, and cavities in the buccal surfaces of molars where the decay has extended under the free margin of the gum. Employed in these cases gold inlays are very useful and may be given a wide range of service, but this will still leave a large class of cavities where the ordinary filling has its legitimate field and where no inlay can do equal service.

CHAPTER XV.

PREPARATION OF CAVITIES FOR INLAYS.

BY C. N. JOHNSON, M. A., L. D. S., D. D. S.

When inlays were first introduced the general impression given the profession that the adhesive properties of cement could be relied upon to hold the inlay in place irrespective of much depth to the cavity led to the formation of cavities too shallow and with insufficient attention to the principle of mechanical anchorage. Inlays should be anchored upon the same general mechanical plan as fillings, the only difference being in the details. It will of course be recognized in the beginning that cavities for inlays must be so formed that the matrix or wax may be lifted from the cavity without distortion, and this idea being prominent in the mind of operators caused them in many instances to make the walls of their cavities too flaring, with the orifice much wider than the interior. This resulted in attenuated edges to the inlay and frequently to a lack of definiteness of form, leaving the cavity more or less saucer-shaped. This is wrong in principle and has quite generally proved a failure in practice. Cavities should be made with some depth and with walls so formed that the inlay will remain seated without tilting or rocking under pressure even before it has been cemented.

In opening up cavities it is true that there are many cases where the orifice must be quite widely extended to admit of entering a matrix or wax into the cavity and removing it. This often involves cutting much sound tooth tissue, particularly in proximo-occlusal cavities in bicuspids and molars, where the decay in the proximal surface may have extended much wider bucco-lingually in the gingival region than it has nearer the occlusal surface. It will be seen at once that to fit a wax model to such a cavity it must be extended bucco-lingually very freely at the point where the proximal surface joins the occlusal to bring it on a line with the cavity further rootwise. The practitioner who purposes using inlays in these cases must have the will to cut quite extensively, and there are many instances where the loss of sound tooth tissue is so very great that the discriminating operator will decide upon inserting a filling instead of an inlay. This is one factor

in the choice between inlays and fillings which has not received sufficient consideration. While it is true that in the preparation of cavities, whether for inlays or fillings, we are frequently called upon to remove sound tissue for better access to the cavity and to establish marginal outlines at points where recurrence of decay will not take place, yet it is unjustifiable to sacrifice large portions of sound tissue in locations of practical immunity from decay in order to bring the cavity within the requirements for inlay work. In many of these cases a filling may be inserted to better advantage and with less injury to the tooth.

One cardinal principle in the formation of cavities for porcelain inlays is that they should be so shaped if possible as to leave no thin margins to the porcelain. A thin margin usually means a fractured margin in a short time. With cavities for gold inlays the exact opposite is true. One of the chief virtues of gold inlays is that the enamel margins may be freely beveled and the gold allowed to lap over them—a relatively thin layer of melted gold being sufficiently strong for ample protection to the enamel. It is with this idea in mind that the following detail of cavity formation for the different classes is suggested.

Cavities in the labial surfaces of incisors and cuspids, and the buccal surfaces of bicuspids and molars. The first essential in the preparation of these cavities is to open the cavity freely by breaking down all enamel undermined by decay. The axial or pulpal wall should be made perfectly flat so that the inlay will have a definite seat to rest upon. This is conveniently done with an inverted cone bur stood with its end looking toward this wall, and carried laterally across the floor of the cavity. There should be an angle formed between the axial wall and the surrounding walls, not a perfectly right angle so as to leave the surrounding walls parallel, but very nearly so. If these walls were perfectly parallel it would manifestly be impossible to fit a matrix and remove it, but the nearer they approach to this the more securely will the inlay be anchored, and the less necessity for relying on the cement as an adhesive agent. Cement should be used in the capacity of a sealing material between two joints and not as a glue to hold the inlay to the cavity. In short the cavity should be so formed that there shall be some frictional retention against the surrounding walls, the inlay in many instances going to place with a snap. When cavities are formed along these lines there will be less trouble from inlays dropping out.

It might be imagined that the fitting of a matrix to such a cavity would be very difficult but this is found in practice not to be so, and

even if it did slightly complicate this part of the operation it would be justifiable on account of the greater security of the inlay.

There should be no beveling of the enamel margins for porcelain except as the slight divergence of the surrounding walls at the orifice of the cavity forms a bevel. In the use of the inverted cone bur for forming the axial wall if the sharp angle of the bur should undercut the surrounding walls they may be trued up with a chisel or with a fissure bur stood with its end looking toward the axial wall and cutting with the side of the bur. The outline of a cavity formed as just indicated is shown in the two sections of an incisor, Fig. 237, longitudinal, and Fig. 238, cross-section.

In bicuspids the form of the axial wall is sometimes different from this on account of the difference in the form of the tooth. If the axial wall were cut perfectly flat in some cases of extensive decay it might result in exposure of the pulp and so it should be given a convex

FIG. 237.

FIG. 238.

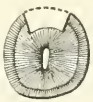

FIG. 239.

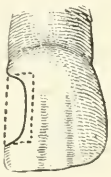

FIG. 240.

form as indicated in the cross-section of a bicuspid, Fig. 239. This form facilitates the firm seating of the inlay fully as well as the flat form, and in some instances furnishes a more secure anchorage.

In extensive penetration of caries where the cavity runs under a strong wall of overhanging tooth tissue and it is deemed undesirable to cut this wall entirely away, it may be permissible to excavate the cavity perfectly and fill the undercut with cement. After this has become hard the cavity may be prepared as usual. This practice is not often feasible on account of the fact that ordinarily when decay undermines a wall it does so in such a way as to weaken it beyond the possibility of retaining it with safety.

Upon broad surfaces such as the buccal surfaces of molars we frequently find decay running along over a considerable area with little penetration into the tooth, and in these cases if the cavity is formed on correct mechanical lines with flat seat and proper angles it need not be made very deep. But an inlay for such a cavity should be of strong material and it is usually best in all buccal cavities of molars to insert gold inlays in preference to porcelain.

Simple cavities in the proximal surfaces of incisors and cuspids. These cavities must be opened sufficiently to the labial or lingual to admit of fitting the matrix, and it is therefore necessary to cut away one of these walls quite freely; though the ample separation of the teeth in advance of the operation will in some measure dispense with this necessity. The same provision for seating the inlay firmly in place should be made in these cavities as in others and the axial wall should be made as flat as possible. If the labial wall has been cut away and the lingual wall remains standing with sufficient integrity to admit of it being left, there should be an angle formed between it and the axial wall, and even where the lingual wall must be removed it will be found possible to make a point angle in the gingivo-linguo-axial region. The gingival wall should be made at nearly right angles with the axial wall and almost parallel with the incisal wall, which should also join the axial wall at an angle, so that the inlay will lock between the incisal and gingival walls as if in a box. Fig. 240 illustrates the labial surface of an incisor with the marginal outline of the cavity indicated, and the dotted lines showing the interior form of the walls.

In cases where there has been much breaking down of the lingual wall with a strong labial wall standing, the cavity should be opened mostly to the lingual and the inlay inserted from this direction. In these cavities an angle should be made in the gingivo-labio-axial region so as to form a flat seat of resistance at this point, which will receive most of the stress brought to bear upon such an inlay.

Cavities in the proximal surfaces of the anterior teeth involving the incisal angle. These cavities present a more difficult problem for porcelain to meet than any of those where porcelain inlays are indicated, and yet their exposed positions often call for this kind of restoration. It is therefore necessary to study very carefully the forms that shall be given these cavities for the most secure anchorage and the greatest strength to the porcelain. The operator must individualize his cavities and take advantage of every possible opportunity presented by the peculiarities of the case to gain depth to the cavity and bulk to the inlay.

It will usually be found that to gain security of anchorage some form of step must be made in the incisal region, and yet there are certain cases which do not lend themselves readily to this method of treatment. Ordinarily the step is made by cutting across the incisal edge at right angles to the proximal portion of the cavity making approximately an L shape to the inlay, but sometimes it is not ex-

pedient to cut away the angle of the enamel in this manner. This is particularly true of those cases where the decay has involved the lingual surface far in advance of the labial in upper incisors leaving little tissue in which to form a step. It is also true in some instances where there has been a simple proximal cavity of shallow depth in either an upper or lower tooth and the incisal angle has fractured off following a check in the enamel leaving a clean sound surface of tissue along the axial wall with the enamel in perfect condition in the incisal region. These are cases which do not call for much incisal exposure to stress and it would seem too radical a procedure to cut away the incisal enamel, besides increasing the exposure. If the teeth in these cases are well separated a cavity may be prepared by cutting a shoulder in the axial wall looking toward the incisal and about one and one-half millimeters from the incisal edge, as indicated in Fig. 241. This should be supplemented by a rather deep and strong

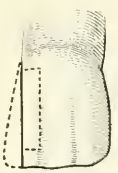

FIG. 241.

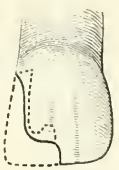

FIG. 242.

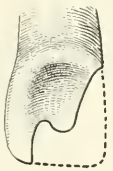

FIG. 243.

anchorage in the gingival region, and if the teeth are sufficiently separated the inlay may be slipped into place laterally. This form of anchorage is of course not the strongest from a mechanical point of view where great stress is exerted on the inlay, but in a somewhat close observation of many cases in practice it has proved sufficiently satisfactory to recommend its use in the class of cavities indicated.

Where the step anchorage is employed it is usually best to shorten both labial and lingual plates of enamel at least half way across the incisal edge (Fig. 242, labial view), though this is not invariable. Sometimes the labial enamel may be left standing in upper incisors provided sufficient bulk can be given the porcelain in the step. In either case the lingual plate should be cut away more than the labial, and this is particularly true near the termination of the step. At this point the lingual aspect of the step should be made to dip rootwise quite perceptibly to provide an interlock to the inlay (Fig. 243, lingual view). Care should be taken that there are no thin edges left to the inlay in any of its outline and this is accomplished by cutting the enamel with little or no bevel. It is also possible in some instances to add

to the bulk of the porcelain in upper teeth, and thus increase its strength in the region of the step, by building it fuller lingually than the tooth originally was. The relation of the lower incisors will often admit of this and in some instances it is advisable to slightly shorten the lower tooth to give the needed space.

In the gingival region provision should be made for a broad seating of the inlay. The gingival wall should be flat and as wide mesio-distally and long labio-lingually as the available tooth tissue will permit. No undercutting is of course permissible but the labial and lingual walls may be made to extend from the gingival wall in a very nearly parallel direction. This will give a box-like form to the cavity in this region and result in security to the inlay when cemented.

Cavities for the restoration of incisal tips. It is sometimes found practical where the incisal portion of an anterior tooth has been marred by faulty development, so as to be dwarfed and unsightly, to restore the end with porcelain. It is also possible in some instances

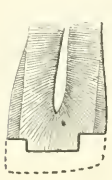

Fig. 244.

Fig. 245.

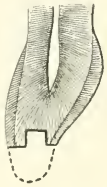

Fig. 246.

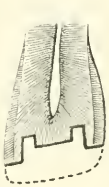

Fig. 247.

Fig. 248.

to do this where the incisal portion of an incisor has been broken off by a blow, though the cavity preparation for the two is entirely different. In the first instance there is usually a thin projection of tooth tissue standing on the end of the tooth as if the enamel had been stripped from it, and this may be utilized as a tenon over which the inlay may be mortised (Fig. 244, longitudinal section of an incisor mesio-distally, Fig. 245, longitudinal section labio-lingually). The shoulder where the perfect enamel begins and against which the inlay is fitted should be cut at right angles to the tenon, and the latter so trimmed that the matrix may be fitted over it and removed without dragging.

In the case of a fractured tooth leaving the end flat the problem of anchorage is greatly complicated. Retention must be gained by drilling into the fractured surface and the danger of approaching the pulp is always a factor in the case. If the fracture has not occurred far rootwise a groove may be made running mesio-distally across the tooth (Fig. 246), shallow in the center to avoid the pulp and deeper at each extremity where it passes mesially and distally of the pulp

(Fig. 247). If the fracture has extended so near the pulp as to reach a thick part of the tooth so that the labio-lingual width of the fractured surface will permit it, two grooves may be made, one to the labial and one to the lingual of the pulp, and these should join the labio-lingual grooves at either side (Fig. 248). All grooves for this purpose should be made flat at the base and as broad and deep as the tissue will permit.

Cavities involving the proximal and occlusal surfaces of bicuspids and molars. These complex cavities are usually better managed by the use of gold inlays than porcelain and the detail of cavity formation herein suggested is in accordance with this idea. The most serviceable of all inlay work is in connection with the large restorations frequently necessary in these cases, and the operator should study carefully the possibilities of inlays in those positions in the mouth where the difficulty of inserting large fillings of foil has frequently proved a serious physical and nervous tax on patient and operator.

As has already been intimated the preparation of these cavities involves a wide extension bucco-lingually of the proximal portion of the cavity as it reaches the occlusal, and wherever a step can be made in the occlusal surface at right angles to the proximal the chief reliance for anchorage should be in this step. This is particularly true of bicuspids where the bulk of tissue for anchorage in the proximal region is not so great as in molars. The step should be given a dovetailed or interlocking form so as to avoid any possible tipping of the inlay and this may usually be accomplished in one of two ways, dependent upon the form of the tooth. Where the cusps are prominent and the depressions between them deep it will usually be found that there is an appreciable concavity at the termination of the step most remote from the proximal cavity, and in this instance the step at this point may conveniently be made much wider bucco-lingually than it is midway between the cusps. The effect is to dovetail the step portion of the inlay against any possibility of tipping. (Fig. 249.) Where the occlusal surface is more nearly flat with little prominence of the cusps and almost no depression between them, the interlock may be secured by deepening the termination of the step rootwise as shown in Fig. 250. a mesio-distal, longitudinal section of an upper bicuspid.

The same provision for a flat gingival wall in the proximal portion should be made as in incisors, and the buccal and lingual walls should extend from the gingival in nearly a box-like form. If the cavity is prepared in this way and the inlay properly fitted it will snap into place with a frictional retention against the walls which adds greatly

to the sense of security. Such an inlay will not rock or tip on pressure even before it has been cemented.

In case the enamel on the occlusal surface leading from the cavity is perfect and it is deemed not advisable to cut into it to form a step, retention against tipping may be secured by making the cavity slightly wider bucco-lingually at the axial wall than it is at the dento-enamel junction (Fig. 251, cross-section of a lower molar). This forms a dovetail and in cases where there is sufficient bulk of tooth tissue to work on it may be done without weakening the walls. It is of course apparent that the only direction in which a model or inlay can be removed from such a cavity is toward the occlusal surface.

In other cases where the dentin is so involved in the occlusal region as to leave the axial wall greatly concave and no foundation for a step, an interlock may be gained by shortening one of the cusps and building the inlay over it (Fig. 252, lingual surface of a bicuspid). It will be found in these cases that the dentin is quite extensively dissolved

Fig. 249.

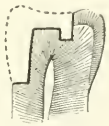

Fig. 250.

Fig. 251.

Fig. 252.

from under the enamel as it arches over the cusp and the wall is made more secure by cutting down the cusp and protecting it with gold. This may be done with both cusps if necessary where there has been much undermining of the enamel, and even this extensive restoration may frequently be necessary without the pulp being involved. These are the cases which heretofore have been quite generally consigned to crowning, but an inlay restoration such as just indicated where even the entire occlusal surface is reproduced in gold is in every respect preferable to a crown. And this is not only true of these cases but of others still more extensive where the mesial, occlusal, and distal surfaces are involved in the same tooth, requiring a restoration of all three with the gold overlapping the buccal and lingual walls. (Fig. 253, lower molar, buccal surface.)

The general form of the cavity in such cases must of course be governed by the conditions presented. Weak or overhanging enamel should be ground away quite freely for the double purpose of securing a firm foundation and for thoroughly opening up the cavity. The

principle of the flat seat for the inlay to rest upon should be maintained as largely as possible, because of the necessity for security against dislodgment under the severe stress of mastication to which such restorations are subjected. The enamel margins should be beveled away quite freely with the utmost confidence that the gold will form an adequate protection to them.

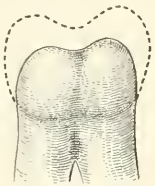

Fig. 253.

In case the pulp is dead advantage may be taken of the pulp chamber for anchorage after the canals have been filled, but in the event of this additional anchorage not being required the chamber may be filled with cement and this leveled to form a flat seat for the inlay.

Cavities in the occlusal surfaces of bicuspids and molars. It is a very rare condition which calls for an inlay in the occlusal surface of a bicuspid unless it involves some other surface. A simple occlusal cavity can be more judiciously managed with a filling than an inlay, and it is only in molars with cavities of appreciable extent where it is judicious to make occlusal inlays. The preparation of these cavities is not complicated. The floor or pulpal wall should be made flat so as to be at right angles to the stress of mastication, and the surrounding walls should be nearly parallel to make a mortised effect to the inlay (Fig. 254, section of a lower molar).

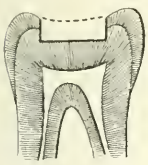

Fig. 254.

In cases where there has been an extensive involvement of the tissue undermining the occlusal enamel leaving it frail, it may be ground down slightly past the marginal ridge and the entire occlusal surface reproduced in gold (Fig. 255).

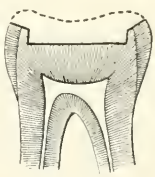

Fig. 255.

The technique of cavity preparation for inlays is quite simple and the operation altogether more acceptable to the patient than for fillings. There is no necessity for applying the rubber dam and this to many is a great relief. The cutting is mostly done with chisels, excavators, and such rotary appliances as stones, wheels and disks. The only necessity for the use of burs in large cavities is in sharpening up some of the line angles, and to flatten the walls left rounding by the stones. The fact that the grinding may be done under moisture reduces the pain to the minimum, and this is a great recommendation for this class of work.

CHAPTER XVI.

THE PORCELAIN INLAY.

BY W. A. CAPON, D. D. S.

The eventual success of porcelain as a filling for teeth depends upon thorough consideration of two primary principles, viz., foundation and adaptation. The first term applies to cavity preparation, the second to matrix formation, and they are closely allied in importance. The consideration of the former by a preceding chapter allows the matrix to become my first topic. The metals used for matrices in porcelain inlay work are made of either platinum or gold foil and their respective value for this purpose is usually an argumentative point whenever the subject of high or low fusing porcelain is discussed. Adherents of high fusing porcelain have no choice except platinum while the advocates of lower heat material can use either gold or platinum. Platinum has for its recommendation adaptability and stability of form, together with its great resistance to high heat, thus dispensing with the necessity for an investing material to keep its form. The virtue of gold is its ductility and easy adaptability to floor and walls of cavity, but this very softness in the majority of cases renders an investment necessary, thus precluding any trial fitting or reburnishing which is of so much assistance especially to the beginner. It being my intention to describe the use of high fusing porcelain particularly, I have no alternative of a choice of metals for a matrix even if so desired, and will consider the subject from this point of view.

The difficulties connected with making a matrix are somewhat regulated by the position of the cavity and the amount of working space in its immediate vicinity, therefore it may simplify the subjects to divide them into three grades as follows:

1. Labial and buccal cavities.

2. Proximal cavities in anterior teeth with lingual surface not involved. Gingival cavities curving well to the proximal.

3. Proximal cavities in incisors involving lingual surface, proximo-incisal restorations, distal surface of cuspids, mesial surface of first and second bicuspid and first molar.

Sufficient space between teeth is imperative with this class of operations because porcelain is unyielding and cannot be forced to

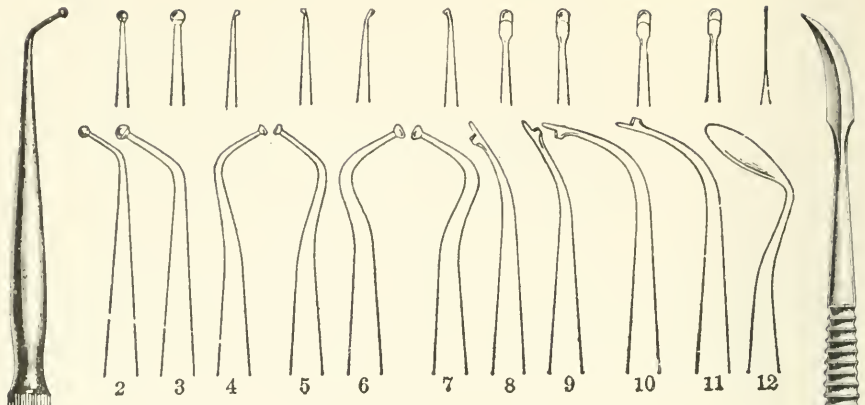

FIG. 256.

position without risk of chipping edges. The matrix must come from the cavity without change of form and frequently there is plenty of space for the inlay when finished, but owing to necessary excess of matrix material it locks itself when there is apparently sufficient space. The impression of the cavity or matrix is made with gold foil No. 40 or pure platinum gauge 1/1000 in. or .001 in. thickness—thoroughly annealed. In these days of inlay requisites this material is kept ready for use by all dental dealers, but it should not be handled much before using and it should be *pure*. If greater softness is required give it a high heat in the furnace muffle. I emphasize the word pure because iridium and platinum are naturally alloyed and as iridium is the most difficult metal of the platinum group to eliminate, this fact may account for the variance in softness in different purchases. The proper thickness of the metal has been a point of considerable discussion, but it is now generally conceded that 1/1000 is the correct thickness for most operations. It may sometimes be slightly heavier, but never thinner. Many argue that if 1/1000 is good 1/2000 must be better because of the minimum amount of metal at the edges, forgetting or not knowing that burnishing reduces thickness to a lighter gauge.

Labial cavities in central incisors are in the first grade, therefore a detailed description will be more easily understood.

The foil is cut sufficiently large to allow holding against adjoining teeth, and somewhat diamond shaped, the extreme ends being held

firmly by the first and second fingers of the left hand, leaving the right hand free to use the instruments for burnishing.

My preference is for few and simple instruments such as two or three sizes of rubber tips and some amalgam burnishers.

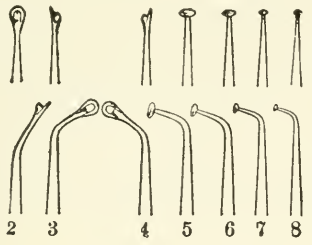

FIG. 257.

Special instruments such as those designed by Dr. W. T. Reeves, and Dr. C. N. Thompson have extensive use and fulfill the requirements desired. (Figs. 256 and 257.)

Whenever possible it is well to give the outline of the cavity by the rubber points or spunk held by ball tipped pliers pressed firmly over the cavity, stretching the metal with safety, then rotating a ball pointed instrument with gentle pressure, commencing with a large size, following with smaller ones until the metal is fairly well adjusted; then use small pieces of spunk, chamois skin or camphor, packing tightly. It is now safe to use the other hand and with it hold the matrix in place with a blunt instrument pressing the packing, then burnish edges thoroughly, but not roughly for fear of tearing. A break on the cavity edge means a new mold while one at the bottom of the matrix is of no moment. Remove spunk or whatever has been used as an assistant and carefully release the matrix which is now ready for the porcelain. If inadvertently there is an undercut in the cavity sufficient to lock the matrix, gently force it out, then replace and reburnish the edges, not touching the interior, thereby making a change of the cavity unnecessary.

The making of a matrix for a proximal cavity requires more skill and practice. The foil should be carried well above the gingival margin of the cavity and if the gum is even with it the edge of the metal should be turned to look toward the proximating tooth and lie over the gum, giving a sure working surplus. Rubber points are not much used in these places, therefore take the flat end of a burnisher and press across the cavity edges, gently forcing the foil to position assisted by small squares of spunk. The burnishing and general procedure is the same as for a simpler cavity except that usually surplus foil is in the way if both labial and lingual surfaces are burnished flat to the tooth, therefore if drawing from the labial side, have the lingual

surface approximately burnished, take out and cut surplus off, then replace and get outline more perfectly and thus save a probable twisting of the matrix caused by an excess of material. If the cavity has greater presentation toward lingual surface the same rule is applied. Many practitioners suggest that much assistance can be gained by holding matrix in place with rubber dam, gold beater's skin, or china silk, and burnishing the matrix through these materials. Occasionally they have value.

Some four years ago Dr. Allen, of Kansas City, added gum-camphor to our equipment as an assistant in making a matrix and it is most excellent when used properly, but many operators make the mistake of using it everywhere, forcing it in the cavity when the matrix is unprepared, and the result is an aperture from edge to edge, therefore it is well to have the cavity walls fairly outlined before using it. After the matrix is made it is recommended that it be thoroughly cleansed by placing it in alcohol which will cleanse it of saliva or blood if camphor packed. The action of alcohol will dissolve the mass so it will drop out. Passing it through an alcohol flame will burn it out leaving no residue which is one of the recommendations for using this material for packing; however, if gold is being used it is safer to use alcohol alone. After the matrix is cleansed clasp the surplus portion firmly with a pair of straight fine pointed tweezers and fill the mold with the shade of porcelain chosen, which is mixed with clean water or alcohol or a mixture of both and applied with a fine pointed sable pencil brush and the little lump of stiff porcelain is gently patted or jarred to place. The edges of the cavity form are traced clean with point of brush and the embryo inlay is laid face down on absorbent paper or a clean napkin which abstracts the surplus moisture. I prefer applying the first piece so dry that it is difficult to pick up with the brush. It is at this point that the advantage of a sable brush is noticed because it holds a point without drooping while camel's hair droops and has no stability.

If the matrix should have a pierced or broken bottom which is almost unavoidable in a deep cavity, fill it as if it were intact and unless the aperture is extremely large it is surprising how much tapping or forcing is required to make the porcelain pass through; however under all circumstances it is a safe rule to turn the matrix bottom side up and examine it closely and trace it with a clean brush, otherwise a very small particle of porcelain left unnoticed and becoming fused will make the work to this point useless.

If a break is made on the cavity edge of the matrix, condemn

it and make another, as it is impossible to have a perfect margin unless the matrix is intact on that margin.

When excess of moisture has been removed, place it on a metal or fire clay tray at the mouth of the furnace, gradually pushing it to the interior, using care that too quick evaporation does not loosen porcelain from walls of the matrix. If this occurs a refilling of the mold is the only alternative. Close the door of furnace and the process of fusing has commenced. The shrinkage of porcelain plays a prominent part in all such operations and unfortunately it keeps the most experienced "guessing," therefore those unfamiliar with the work are handicapped at the beginning by a difficulty that must be reckoned with always. In fact a student's first lesson is the showing of an artificial tooth before fusing and after, and it never fails to create surprise and comment and is a simple object lesson that impresses. Shrinkage of porcelain is always a fifth of its bulk, sometimes quite one-fourth. In small matrices it cannot make much change, but in proportion to the size and quantity do the difficulties increase. It may draw from the walls of the matrix and form crevices at those parts, or it may shrink and draw the form with it, and to avoid this my favorite way is to mix small particles of broken porcelain with the paste. Another way is to cut grooves or concaves at its greatest bulk which divides the material and avoids the crevicing to some extent. The main desire is to have a shrinkage that will change the form of the matrix the least, and some porcelains have a value in this respect. An invested matrix is more secure, but it has drawbacks that in my estimation are often detrimental. A matrix for investment must be intact at every point which is possible with gold, but not always so with platinum. Once invested it must be completed in that form thus debarring opportunities for trial or reburnish, added to which are the increased difficulties of getting proper form or contour while invested.

FUSING.

This is the coherence into a solid mass of the various substances which constitute porcelain and it is this cohesiveness which causes shrinkage, and because of this shrinkage repeated firing is imperative to obtain the necessary bulk of solidified material. It may be twice, three times or more according to the extensiveness of the operation, therefore a knowledge of fusing is an important part of making an inlay, and one that necessitates considerable experience. Of course results are obtained without experience or much practice, but these

results are not always properly fused porcelain. To illustrate this point let me state that a certain dealer and manufacturer wishing to impress upon the profession the advantages of a pyrometer attachment molded small pellets of porcelain of equal size and of one color and mailed them to "porcelain workers" in various parts of the country, asking them to fuse and return. I was so favored with this request, but did not know the results for some months afterwards when by chance I saw the "returns" mounted on a card for exhibition purposes and the various shades and qualities produced by that one little pellet was a revelation. They were all supposed to be correctly fired and no doubt each participant in this trial thought his specimen a correct one. This shows in a simple manner why there is so much demand for information regarding shading, which demand can be lessened by greater knowledge of fusing. How can this knowledge be obtained in the most practical manner? By studying the various degrees of heat with the eye which may be aided by a watch or a pyrometer, but with either of these or any other guide the correct fusing or baking of porcelain reduces the problem to one of personal equation.

A pellet of gold is recommended by many to assist in determining the fusing points. The gold is placed in the muffle near the inlay and its melting denotes the fact that a certain temperature is reached, and so much time by the watch is allowed between the melting of the gold until the fusing of the porcelain. The time to allow is learned by repeated firings, but various sizes of porcelain being baked at the same time must be guessed at.

The use of a pyrometer in connection with a furnace is accepted by many as being the most scientific solution of our fusing troubles, and there is no doubt that it is of much assistance to the majority, but it is a machine and therefore it has no judgment and fusing porcelain requires that necessity. Concentration of a thousand heat units for twenty minutes will produce certain results and the same condition will be obtained by increasing the volume and reducing the time, and as we are fusing irregular quantities, either the heat or fusing point must be varied because these fusing points now used as a standard were obtained by baking porcelain pellets of uniform size at a regular heat for a certain time with the rheostat on a positive point. These facts, therefore, must place the pyrometer in the position it should occupy and that it is a guide which will indicate the furnace heat and *not properly tell* when the fusing has taken place. The man who uses his eye as a guide can fuse any material under all circum-

stances and feel that he has control of the situation, providing he uses an article which fuses at 2300° or less. Over that point it is a greater strain on the eyes and the value of a pyrometer is correspondingly increased, but the proportion of operators using such excessive heat for inlays is very small.

The operator after some practice will observe that various degrees of heat have a shade indicative of the point he desires. The first will be a deep orange color which will fuse a low porcelain body ranging from 1500° F. to 1800° F. If an electric furnace is being used, advancing the rheostat to the next point will increase the brightness of the muffle to a yellow, giving a fusing temperature ranging to 2100°, and another step higher a bright yellow appearance, and a heat sufficient to fuse most of the "high fusing" bodies or those ranging in the neighborhood of 2300°. Beyond this point there is a glare that may be injurious to the eyes unless protected by smoked glasses.

Dr. Hart J. Goslee, in a recent article on this subject makes a valuable suggestion that I take the liberty of quoting. "A degree of familiarity with the physical change which takes place during vitrification and which will enable one to thus detect the proper fusion, may be easily required by the continued fusing of small cubes of properly mixed 'body' placed upon the labial surface of a central incisor facing until he can distinguish between the granular surface of the 'body' and the glazed surface of the facing and observe when the surface of the former becomes the same as that of the latter."

The "first fusing" is carrying the inlay through these various stages of heat until it arrives at what is usually termed a "biscuit bake." This is a reduction of the different ingredients to a solid vitrified mass without a gloss. Drawing it from the furnace in this condition and exposing it to the air does it no injury, in fact small work even when finished does not require particular care in this respect, but large sections and crowns should be immediately placed in a cooling muffle until cool enough to handle.

After the first bake the surplus platinum is trimmed and the inlay adjusted in the cavity. The removal of excess matrix material insures easier access to its position and allows a better observance of general contour. The flat blade of a burnisher is pressed along the edges until the matrix sets firmly in position and that part of the matrix which may have been changed by the shrinkage is forced back to the cavity walls. The inlay is again removed and body added, first cleaning off the surface with a brush, being careful to have any crevice thoroughly filled with porcelain, thereby preventing little air holes

which sometimes defy considerable tapping. The inlay is again given the same considerations as at first baking, but watched with greater care when the heat is nearing the fusing point, because insufficiency of heat will not produce the true shade or finished surface, while too much heat will make it lighter in proportion to the excessive heat beyond the exact point, and reduce the quality of the material.

Better results will be obtained by withdrawing the inlay before it is thoroughly fused and note the condition particularly in regard to amount of material, for if another layer of porcelain is required to give it the proper contour or to have the inlay level with the margins of the matrix, it is better to make this addition at this time, and in so doing the whole mass will be more homogeneous with a truer shade if the final heat is correctly gauged.

If the inlay is satisfactory to the operator the next step is to strip the matrix, which is done with fine straight pointed tweezers, catching the outer edge and turning backwards toward the middle which will avoid chipping the edges. Very frequently small pieces of the metal adhere very persistently to sections of the porcelain. These may not be of disadvantage in large inlays, but in small ones the shade might be affected, therefore it is recommended that every portion be removed, and an old bur will do this easily. My usual procedure after stripping the matrix is to place the inlay in the cavity, always wet, which brings out the shade and adds life to it, and it is at this point the new porcelain worker has his first desire for a transparent cement. It is now that the patient is invited to view it for he is usually as interested as the dentist, and it is also good policy to explain the probable change that will take place by the drying of the tooth and the cementation. This change is often temporary though sometimes permanent, much to our disappointment, but experience may help to reduce it to the minimum.

The inlay must now be prepared for retention. There are three important factors toward permanency, first, shape, which is given by due consideration of cavity preparation, second, the undercutting or serration of the porcelain, and third, the quality of cement. Many failures can be attributed to concentration on the latter, ignoring the importance of the first two requisites. Careful attention should be given to the inlay itself, large or small, thereby saving time, discomfort and reputation. My preference is undercutting or grooving when possible, but that is not always practicable, so it may be necessary to etch the cavity side of the inlay with hydrofluoric acid which has a powerful chemical affinity for all vitrified surfaces, destroying the

gloss and allowing a better union with the cement. Almost the same results are obtained by using small carborundum or corundum stones, and many follow this method exclusively, while others use both roughening and grooving.

The disks employed are diamond, hard rubber and corundum or carborundum. The diamond disks are expensive and unless used carefully very soon lose their efficiency. The cheaper disks cut quickly and with moderate care are durable. An objection to carborundum is its brittleness, and the fine black dust that lodges in the porcelain and is not always easy to eradicate. The groove should be made on at least two sides and more if possible. In using acid care must be taken to keep the finished surface intact and this is done by making a block of beeswax about one inch square, soften a surface over a flame and sink the inlay face down using a warm spatula to cover edges. Drop a little acid on the exposed surface and leave it for five to eight minutes, wash off with water and put the inlay in alcohol which will loosen a fine scale which is scraped off with an excavator. If this surface is not removed the cement will not get a true attachment. No matter how the inlay is prepared it should be thoroughly cleaned with alcohol. The mouth is now put in readiness for the final adjustment of the inlay. Thorough dryness is an important essential, and for this purpose probably the rubber dam is the most efficacious, although if one is accustomed to the proper use of napkins, the unpleasantness of the dam can be avoided in the majority of cases. The cement is mixed to a creamy consistency and applied to the cavity with a spatula and the inlay inserted immediately, forcing it to position by gentle pressure, holding it there until crystallization has commenced. If the inlay is of a simple character further directions are unnecessary, but if complex and extending to the incisal or occlusal surface material assistance is obtained by a soft wooden wedge such as a tooth pick, or waxed floss silk wound about the tooth. A tape floss silk is advantageous because the broader surface equalizes the pressure and as it is drawn over the joints it removes excess cement and exposes the union, showing at a glance if the porcelain has its correct position. When it is not convenient to do this use small squares of spunk, which is soft and firm, for the removal of excess cement while it is soft has a distinct advantage.

After the cement has set and before removal of dam or napkin cover the operation with some moisture preventative such as sandarac or rubber varnish, chlora-percha or paraffin wax. The last mentioned is preferable because it is not disfiguring and gives a blending

effect to the porcelain and tooth and will remain a sufficient time for the purpose desired. The inlay may be finished in an hour or at some future sitting for there is always some finishing with the most perfect work. It may be only a slight disking or it may be that edges need a stone. If so use a small narrow edge of fine grit, grinding no more off the glossed surface than positively necessary, although at times the occlusion is such that the surface must be defaced. After grinding, the surface should be polished, smoothness being the main object.

PORCELAIN SECTION ATTACHMENT.

When it is possible to use an all-porcelain anchorage in restoring a section of a tooth, that method is preferable, because the whole mass of material is of one substance, thereby rendering greater resistance to leverage; but occasionally we must resort to other means of retention, and the use of platinum wire pins, loops, or staples is recommended.

Pins from old porcelain teeth can be used without any other preparation, but they are too thick and rarely indicated in preference to the loop or staple, the latter being adapted to almost every purpose and being also easier to manipulate. Directions for their use are few and easily followed. The tooth is prepared as directed on previous pages, and a platinum matrix made of the edges and cavity, the thickness the same as in other inlay work excepting for the cross-section

FIG. 258.

FIG. 259.

FIG. 260.

of a tooth, when it can be slightly heavier. The wire being the anchorage, it is unnecessary to cover the floor of the cavity with platinum, therefore breaking the matrix is expected. This being done, take iridio-platinum wire gauge 24 and bend in staple form to fit.

Figs. 258 and 259 give the idea of wire formation for a majority of cases, while that shown in Fig. 260 is probably more desirable where there is extreme sensitiveness, it being easier to place retention holes for wire ends than to cut across the tooth to accommodate the loop. The staple with points in the porcelain is stronger, however, than that with the points in the tooth. The attachment to the tooth may be equal in strength, but the tip or corner or any section of the porcelain having the least foreign material must be the stronger, hence the

argument in favor of an all-porcelain attachment when that is possible. The weak points of the porcelain shown in Fig. 261 are opposite to the ends of the wire, while the weak point of that shown in Fig. 262 is as far as the loop extends, although this weakness will be less in proportion to thickness of the porcelain.

While the matrix is in position, the wire is inserted and held there with paste porcelain made of water and gum tragacanth or mixing fluid. Absorb moisture with bibulous paper or spunk and then gently

Fig. 261.

Fig. 262.

Fig. 263.

withdraw the combination from the tooth, and after carefully drying at the mouth of the furnace fuse it the same as other work.

These few simple directions will save the time and trouble necessary for soldering the staple and matrix together, and will also insure a purity of porcelain not otherwise possible.

Fig. 263 shows the loops or pins attached in the porcelain and ready for trial, reburnishing the edges and finishing as represented by Figs. 264 to 267.

Fig. 268 is a part section of a bicuspid showing a way of restoring that is most satisfactory. I have made many such cases, and have yet to learn of the first failure. A whole crown is no doubt quite as easy to make, but at times a demand for the least loss of tooth makes such a repair desirable.

Fig. 264.

Fig. 265.

Fig. 266.

Fig. 267

Fig. 268.

The building of tips and corners can be more quickly accomplished by using pieces of broken porcelain tooth in the foundation, thus allowing a high heat without change in the prominent contour.

About five years ago a firm in London introduced small wedges of porcelain called "Mellersh Cores," their name being taken from that of the inventor. They are in various shades and will take a high heat without change of form or color, and can therefore be used to advantage in contour work.

CEMENT.

It is generally conceded by porcelain operators that while a material of this kind is almost an ideal filling, it falls short of the ideal because we are forced to use as an attachment a substance detrimental to the aim which we have in view, namely, the absolutely invisible restoration of tooth form. Though approximating the ideal we can never fully reach it while we have to depend upon an opaque substance as a means of retention. Still the many good qualities of cement will insure its use for many years to come, for even if an ideal cement should be discovered it will take time to establish a confidence equal to what we now have in the material at present in use. The question may arise as to what is an ideal cement. In many cases what we are now using is ideal, that is from a tooth saving viewpoint, but its failure is that it does not save itself. Cement saves the tooth and porcelain protects the cement, thus making a combination which but for esthetic reasons would be almost perfect. Translucency and perfect color matter little in some instances, but in others they are highly important and the profession should hail the advent of a material having all the necessary qualities as the fruition of a long desire.

Porcelain inlays can be made perfect in shade and shape and the texture may approximate tooth substance in a highly satisfactory manner, but immediately upon attaching it permanently the shade is changed through the difference between the three substances, all of different density, coming in close contact, namely, porcelain, cement, and tooth. The cement being the chief point of difficulty, it is important that the objectionable features should be reduced to the minimum.

It is a poor cement that is not at least a preventative. Many resemble each other in manipulative qualities with the difference of slow, medium and quick setting tendencies. Some are coarse and others are fine and a few have a combination of many good qualities, but with that tendency to "pack" under pressure which causes annoyance to porcelain workers. A cement closely ground of clear color and medium to slow setting, having the maximum adhesiveness with the least amount of powder is what is recommended for a successful operation. In addition to this, it should have the greatest amount of resistance to moisture during what is usually called the "setting" period.

Shading a cement to match the tooth, or to lighten or darken either the porcelain or tooth or both is quite troublesome, and, at times, disappointing. It is of considerable assistance to mix pellets of cement of various

shades and mount them on a card. This allows of comparison and saves much time and guesswork. Yellows are the most required, and this is fortunate because pure calcined oxide of zinc is yellow, ranging in degree of shade from a canary color to cream white, and its chemical combination with phosphoric acid is more complete than when otherwise changed. The variations in shade depend upon the product and it is conceded that the best quality of zinc oxide comes from France. This is of the lightest shade, but it is not safe to assume that the light shades are all of this origin, because manufacturers sometimes produce these variations by coloring matter which, has a deteriorating tendency. It may be infinitesimal in blues and grays, but white is made so by oxides of aluminum or zinc which reduce the chemical union of the powder and acid in a marked degree. All phosphate of zinc cements are similar in manufacture and much the same results are obtained, although some are better adapted than others to use in connection with inlays.

Some inlay troubles are caused by injudicious selection of cements, that is using a quick setting cement instead of a slow one, or vice versa. Another factor is improper mixing in the way of insufficient spatulating which gives poor results through non-incorporation of the two ingredients. Cement mixed too thin will not have the body of material required for resistance, with the added danger of displacement during the longer period which it takes for setting. Cement mixed too thick prevents proper seating of the porcelain and a close union, with probability of fractured edges through endeavors to force it to place. Quick setting cements should be avoided in complicated conditions. Slow setting cement has less value on corners and tips, for usually such places have free access and a quicker setting cement will reduce the possibility of displacement, which is increased through prominence.

In the past four years much attention has been given to the new silicate cements which are on the market under various names with many impossible recommendations, therefore a word on this point may be of some interest particularly in connection with porcelain inlays. These cements are nearly all produced in Germany and it has been my fortune to be familiar with this material almost from its origin, and in that time have formed conclusions through actual observations that may be useful. These silicate cements have not that perfection claimed by the manufacturers and agents, but they have reached a stage wherein it is safe to prophesy an ultimate success, how soon, it is not possible to say. That they meet all requirements at present

or that they can take the place of porcelain is not worth argument, but as an attachment they come nearer to the ideal in appearance than anything yet produced. Their strength and adhesiveness to tooth structure cannot be compared with the ordinary phosphate of zinc cement.

In mixing a silicate cement one is impressed with its tenacity to smooth surfaces, leading to the belief that it must be particularly applicable to porcelain restorations, but in many practical tests it is found that after a few months this adhesiveness has decreased and the filling is easily dislodged. This being the case its use as a medium for inlay attachment is somewhat hazardous. It has a value because of shade and its resistance to "washing out," but this is counterbalanced by crevicing and fracturing and changing appearance in many mouths. And yet there are instances where this material wears well and after three years has almost the appearance of porcelain, but these cases are rare.

SHADING.

The color problem in connection with inlay work is one of much inquiry and discussion. It is a phase of the work most perplexing and the rules given by some authorities are both diversified and difficult, requiring close attention even by the most experienced and often proving discouraging to the beginner. The size and position of an inlay will govern shade to such an extent that consideration of this fact is one of the first rules. The application of the shade guide to the tooth may lead to an incorrect conclusion, because quantity of material adds depth to the shade and most of the guides are pointed. Frequently the point is placed against the tooth without allowing the eye to take in the whole size and general effect. Thus when the inlay is finished it is found to have a lighter appearance which is an error not readily rectified. Overfusing is probably the cause of more poorly shaded inlays than wrong choosing of shade, therefore the choice of something slightly darker is recommended particularly if the operator has limited experience. A rule which can be applied more frequently to a simple labial inlay is to choose a shade darker and reverse the order when applied to small proximal cases. Something darker between the teeth will surely cause a shadow which can be avoided by lighter shades. The cement which is the background is an opaque substance and is therefore a strong factor and one that must not be overlooked, but even with this consideration in mind the most beautifully shaded work is sometimes disappointing. In many cases, however, this is corrected to some extent by time.

In larger inlays and sections of porcelain the cement interference is reduced by being overcome with volume of material and stronger basal shade body which is toned to the desired shade by lighter tints.

Various degrees of yellow are used as foundation shades in the majority of cases with the possible exception of pulpless teeth. These teeth having decreased translucency the opacity of a solid mass is not so noticeable and the question devolves to one of matching alone. And yet the shading of such a tooth requires considerable artistic skill because the operator must do the blending to suit the various shade conditions present and which are not to be found on any one shade guide.

Take, for instance, a large incisal contour embracing one-fourth of the tooth with pulp alive, and the shades may vary from a deep yellow near the gum to a light yellowish-blue at the incisal. This would be matched up with three shades, which are all listed and ready for the mixing; but if pulpless the neck portion might be a brown with a greenish-blue center and a lighter hue at the edge, thus showing that considerable mixing must be done which means guesswork in many cases. The artistic porcelain manipulator is handicapped when compared with a painter who has his palette and colors and desires certain difficult combinations to portray what he sees or is in his mind's eye. He mixes and sees immediate results, whereas with porcelain the shades are powders with no color guidance until the mass is reduced to a vitreous substance, and then not correctly so unless the artistic sense is carried to a completion. A great quantity of matter has been written and published in regard to the proper way to shade porcelain and many excellent rules are formulated, which if they could be carried to a successful issue at all times would reduce this problem to perfection, but rules and directions are of little value without artistic skill to carry them out. This cannot be bought although it may be acquired to some extent, and yet it must be inate in the same ratio that mechanics are part and parcel of the successful dentist. Rules may assist but they cannot always be practical. It is claimed that the most successful mode of shading is to build the inlay by layers of different enamel shades which "break up the absorption and refraction of light rays," thereby giving an opalescence to the inlay not to be obtained otherwise. This is excellent practice and cannot be criticised when circumstances favor this procedure, but there are times when the blending of shades will give equal if not better results and the simplicity of blending is much easier grasped by the inexperienced. Outside of this is the fact that with one exception

all inlay materials are made for blending and the thousands of beautifully matched inlays made with these materials must prove the fact that merit is not limited to the layer method alone.

Dr. W. T. Reeves originated this method and to him we owe much valuable literature on this subject, therefore it will be of interest to reprint what is claimed by him can be accomplished by observing these three rules.

"First. A neutral translucent-looking inlay. Put colors on strong enough, that when covered with what might be called an enamel layer will allow the colors to reflect through, the enamel layer modifying and harmonizing the colors. This will give the translucent effect so desirable.

"Second. If built of three or more layers of different bodies it will break up the absorption and refraction of light rays, so that from whatever angle or point of view looked at it, it will appear practically the same. An inlay built all of one body or mixture will absorb light only from one direction, and viewed from one point will look all right, but from the opposite point of view will show as differently as black and white. An inlay in layers will come very near imitating nature's method of building up a tooth and by breaking up the direct absorption and refraction of light rays, will come very nearly looking the same from all points of view.

"Third. You overcome that great bugbear of most inlay workers, the cement showing through after the inlay is set. An inlay built up in layers will almost overcome the reflection of the cement through from underneath. You will often hear operators say they had a splendid color before the inlay was set, but after it was set the cement killed it entirely. That was because the inlay was baked all of one body and the cement could reflect through from underneath as easily as the light was absorbed only in one direction from above. The three points I claim for this method are translucency, avoidance of shadow, and prevention of cement reflection from underneath."

PORCELAIN BODIES.

Until recent years the advancement of porcelain operations was much retarded because of few and unsuitable materials, but now the variety is almost bewildering. In fact it is a question if the market is not overdone in this respect.

There can be no objection to every porcelain operator having a varied stock of porcelain, provided his experience has been sufficient to enable a skillful discernment of the various qualities of each, and

thereby produce gratifying results by eliminating those of lesser merit until he has secured what in his hands will give the best basis for general application, but the beginner is likely to be confused by so many different makes.

The value of a product in the eyes of many is the assortment of shades. This of course is natural if the operator has had little experience, but as he becomes more skillful he finds that at least half the number is sufficient because he has learned that a little manipulation of a certain few will give the same results in the majority of cases. This statement will be better appreciated by those who have had to contend with the earlier condition of affairs, when only a few stronger shades were available, and they will also agree that an ideal shade guide could be limited to a dozen and then readily cover all requirements. The porcelain inlay worker of eighteen or twenty years ago, had much to contend with and many discouragements to overcome, and much of the antipathy to this new branch of dentistry was no doubt caused by the crude appearance of many so-called finished operations, some of which were far from esthetic whilst those having that recommendation were cases fortunate enough to be within the range of two or three varieties of continuous gum bodies such as Allen's, Tee's and Close's. These gave a few shades of yellows which were regulated to a great extent by heat, therefore a tooth with gray or blue tints to be matched up with yellow meant a discrepancy of shade which justified much criticism. Subsequent events have proven that these efforts had merits because they resulted in different manufacturers putting various porcelain bodies on the market, with a larger number of shades and varying degrees of fusing point.

Porcelain work was increasing rapidly in the latter part of the nineties and in 1898 received a gratifying impetus by the introduction of Dr. Jenkins' low fusing enamels with an outfit particularly designed for using this material with a gold matrix, for up to this time platinum was used exclusively for that purpose. The advent of these goods and the process of using them was the origin of the controversy still existing in regard to the superior virtues of low fusing porcelain over the older and longer tried high fusing. This question has been debated in public scores of times and it is still unsettled, although the differences of opinions are not so positive, for adherents of both factions are forced to admit that each have certain advantages, which when properly recognized lead to the ultimate gain of the work. The introduction of Brewsters' material was an advanced step for the cause of high fusing porcelain and he was the first and only one to give us

enamels with basal shades, thereby increasing the possibilities of translucency which was lacking in many products.

During the past five years the S. S. White Dental Co. have done much toward the advancement of porcelain, having introduced a variety of shades at various fusing points. The Consolidated Dental Co. have also a splendid assortment with a fusing point sufficient to satisfy the most enthusiastic advocate of high temperature. Johnson and Lund's goods are of the best quality and the fusing point is also high. It is generally conceded that a fusing point of 2200° or 2300° is sufficiently high and quite suited to inlay purposes and the increased strain on the electric muffle and the extra time required for such heat counterbalanced the small advantage of an extreme heat if such exists. The following goods having been thoroughly tested can be considered of a standard quality and the assortment is varied enough to suit any demand.

Whiteley's 19 shades fusing about	2300°
S. S. White Dental Co., 26 shades fusing about	2300°
Brewsters Dental Co., 9 shades foundation body	2300°
Brewsters Dental Co., 24 shades enamel	2160°
Brewsters Dental Co., 10 shades (gold matrix)	1820°
Brewsters Dental Co.. 18 shades (gold matrix)	1550°
Jenkins Dental Co., 18 shades (gold matrix)	1550°
Consolidated Dental Co., 23 shade	2600°
Johnson and Lund, 25 shades	2550°
Ash and Son, 7 shades	1900°

FURNACES.

Porcelain as applied to dentistry at the present time has assumed such importance that it is difficult to conceive of the fact that only twenty years has elapsed since the invention of the first furnace which reduced the time of fusing small pieces of porcelain to a matter of a few minutes, and to this fact we owe the real birth of that branch of dentistry which is generally conceded to be a distinct advancement. There is no doubt that tooth carvers and continuous gum workers of many years back have had visions of what the present generation enjoys by the adaptation of this esthetic work, and they have given much thought toward the solution of the fusing problem, for that was the obstacle first to be overcome, having recognized the futility of much advancement while harnessed to the cumbersome and slow coke furnace.

The quality of workmanship produced in this manner is beyond our criticism which proves that improvements in that direction were not required, but toward reduction of time and convenience so that small work could be possible and with little preparation.

To Dr. C. H. Land, of Detroit, belongs the honor of being the inventor of the first small furnace distinctly different from any other and especially adapted for this work, in which he takes such an important position in its history. Much praise must be accorded him for his persistent efforts and inventive genius.

This furnace was called a "Compound Gas or Gasoline Furnace"



FIG. 269.

and was first described to the dental public in *Items of Interest*, Oct., 1886, under the heading "Are Hydro-carbon or Gas Furnaces a Success?" (Fig. 269.)

These furnaces were lined with fire clay with a muffle of the same material. The air blast was supplied by a foot bellows and took about thirty minutes' continuous pumping to secure the necessary heat. The results were not always satisfactory, as frequently the gas

was forced through the muffle causing "gassing" which was a difficulty to be contended with in using any gas furnace.

Four years later the same inventor produced a smaller furnace of the same kind which was called "The Midget Blast Furnace" and was a decided advance because the muffle was much smaller and made of platinum, thus allowing quicker heating and reducing the "gassing," tendency, (see Fig. 270). These little furnaces could be heated sufficiently to fuse the highest grade material in seven to ten minutes and have been a decided favorite over all others of the same kind, and there are many still in use at the present time. In fact, the writer did not discard his until eight years ago, because its efficiency was in marked contrast to the troubles of the more modern electric. These troubles have been reduced to some extent, but entire elimination must not be expected.

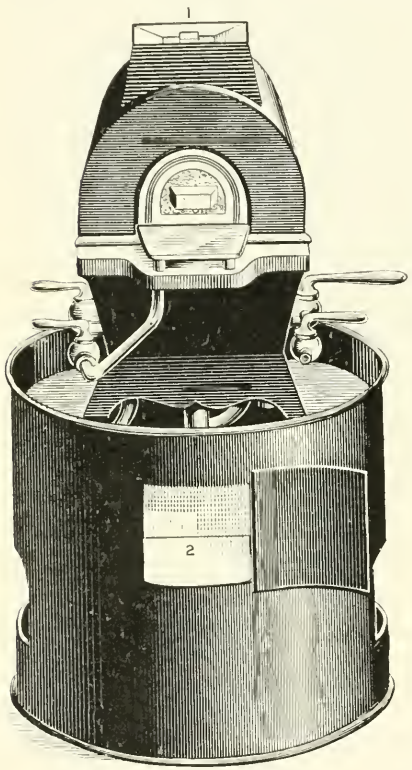

FIG. 270.

In the early nineties several gas furnaces were marketed, the most notable ones being Parker-Stoddart, Fletcher, and Downie.

The application of electricity to dental appliances became general in the early nineties and when Dr. L. E. Custer invented the first practical electric furnace in 1894 the improvement was considered to be a marked advancement, because heretofore the fusing of porcelain by means of gas meant labor to produce the blast which with its attendant noise was most undesirable. Electricity eliminated the possibility of "gassing" the porcelain, a trouble which cannot be understood unless experienced and one which added much to the discouragement of the early porcelain workers. This new furnace being absolutely noiseless and clean was an addition to the operating room and thereby a convenience much appreciated. Its form was adapted more to the use of continuous gum work and is shown in Fig. 271.

It is practically unchanged at the present time, the only improve-

ment being in the heat regulation and easier repair necessitated by wires "burning out." In fact the trend of improvement in all dental furnaces from this date forward has been mainly toward the reduction of this trouble.

Two years after this first electric furnace, or in 1896, the Detroit Dental Mfg. Co. marketed the "Downie" which differed from the former mainly in general form of the furnace and the mode of wiring the muffle.



FIG. 271.

The next furnace brought to our attention was a very small one invented by Dr. Mitchell, of London, and intended for low fusing bodies as it was practically useless for anything higher than Ash and Son low fusing porcelain. In 1899 and 1900 there were three more, viz., Hammond, Peck and Gerhardt, then the Pelton in 1902 and Price's in 1903.

The most recent addition to a numerous list is Roach's Automatic and Caulkins' "Revelation" in 1905. The Hammond had a valuable distinction from all others from the fact that in case of wires burning a new muffle could be substituted immediately. This im-

provement was a decided advantage and other manufacturers soon made the same arrangement. The Price was introduced to the profession with a pyrometer attached, and this improvement has resulted in all the leading furnace manufacturers at the present time having a pyrometer attachment in some form or other. There is very little difference in the merit of these various furnaces, therefore the intending purchaser cannot be far astray in a choice of any one mentioned, although it is important to consider the amount of heat developed on the first step of the rheostat if the dentist is using low fusing material, as several furnaces develop a heat at that point great enough to destroy that material unless watched very intently.

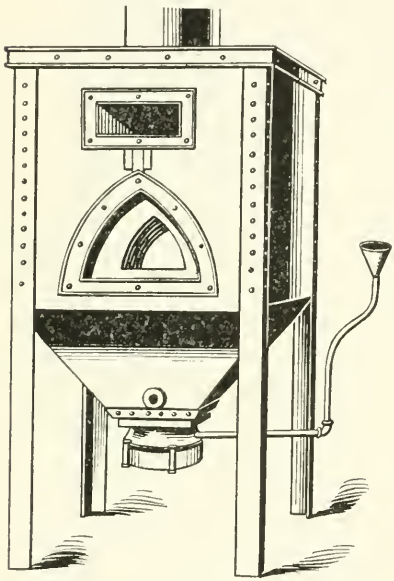

FIG. 272.—Lewellan furnace.

For many years porcelain operations were confined to those fortunate in having electricity or gas conveniences, relegating the practitioner without these advantages to the rear of the vanguard of dental progress. This may not have been a hardship to the majority, because in small places the demand for porcelain work is always limited, but there are many dentists ambitious to do all kinds of work, therefore the introduction of the gasoline dental furnace by the Turner Brass Works, of Chicago, in 1900, was a decided step toward the advancement and equalization of the profession at large. The furnace is simple of construction and capable of producing a heat sufficient to fuse any porcelain and will do it quickly and safely.

This apparatus with the accompanying soldering appliances enables the rural dentist to be an up-to-date practitioner and the numerous sales of this furnace is a testimony that this fact is appreciated.

There is also another gasoline furnace called the Brophy, which is similar in construction and has equal merit with the original. In conclusion it is apropos to state the fact that improvements in appliances for the purpose of fusing small quantities of porcelain quicker was applied on a larger scale to the manufacturing of teeth with the

result that the old fashioned coke ovens are now obsolete, having been replaced with the more modern oil burners, which are quicker, cleaner and save much labor.

They are an improvement and an enlargement of one made for continuous gum by Dr. C. H. Land, in 1892. The simplicity of its form and amount of high heat produced was one of wonderment to the profession at that time.

The fuel is the regular refined petroleum or "coal oil" syphoned to a burner at the base of the furnace, which is so constructed that a natural draught is all sufficient to produce the highest heat required to fuse any porcelain body. They are absolutely without noise or odor and very economical and highly satisfactory in smaller sizes for continuous gum work, but they can only be used where there is a chimney which is necessary for the draught. (Fig. 272.)

To Mr. Lewelan, of Philadelphia, must be credited the improvements of this furnace which has revolutionized the mode of fusing large quantities of porcelain.

CHAPTER XVII.

CONSTRUCTION OF GOLD INLAYS.

JOHN EGBERT NYMAN, D. D. S.

Recently the construction of gold inlays has been entirely revolutionized. A method has been devised by Dr. W. H. Taggart, of Chicago, which supplants all other methods. Applicable alike to simple and to complicated cavities in any situation, obtaining readily any desired proximal contour and occlusion, and with uniform certainty of absolutely accurate results, it may well be styled "the best" method of gold inlay processes.

It embodies all the factors that are requisite of any method that may be termed "ideal," such as accuracy and permanency of results, comfort of patient and operator, ease of manipulation, economy of time.

It is essentially a method of accurate casting of gold inlays, something heretofore impossible, but now easily accomplished by means of a marvelously ingenious device for the application of gas pressure to molten gold. One of the essential problems in this process of casting inlays, which had to be solved was the obtaining of a mold which should have no joints or crevices about it; this necessitated a model of the inlay desired, that could be dissipated completely without residue, by some means which would not in any way injure the mold.

Dr. Taggart finally succeeded in producing a wax of which a model inlay could be made in the cavity of the tooth, carving it to the desired contour, proximal and occlusal. It was essential that the wax become plastic at a temperature that could be tolerated by the tooth, that it would not shrink or warp in cooling, that when cool it would be so hard that it could be removed without distortion, but would not be so brittle as to crumble under the carving instrument, that it could be vaporized by heat. All these essentials were finally obtained.

Then there was the problem of the mold. Of what should it be composed and how constructed? It was essential that the mold material withstand a temperature of at least 2100° F. or 1170° C. (slightly above the melting point of pure gold) without shrinking, cracking or softening; that it should be finer in texture than any invest-

ment material with which we were then familiar; that it must present an absolutely smooth surface in the mold cavity; that it should set sufficiently hard to permit of manipulation without crumbling. This was finally obtained by a combination of silex magnesia and plaster.

These two factors having been obtained, there still remained to be devised some method of forcing the molten gold into the mold so that it would fill the mold to the uttermost corner, a rather difficult problem considering the strong tendency of gold to "spheroid", as it is technically termed, or "ball up" when in a molten or fluid condition.

The genius of Dr. Taggart which had solved two of the problems proved fully equal to the third, and at last after months and months of experimenting with nothing to aid him but his own inventive ability, his masterly knowledge of physics and mechanics, and his faith that he would at last succeed, he did succeed in constructing a machine that would accomplish all that was to be accomplished and so complete was his success, that it was absolutely startling to the profession, creating a sensation such as had never before been known.

It is no exaggeration to state that in the history of the profession nothing to equal this process in value has ever been given it.

The method is as follows: The cavity having been prepared, a mass of the special wax (which is dark green in color in order that the slightest overlap on the surface of the tooth may be readily noticed) sufficiently large to more than fill the cavity is softened by immersion for about five minutes in water of a temperature of from 135°–140° F. or 77° C. This softening must be done carefully and the wax must not be manipulated until it is softened through and through. If insufficient heat is used the wax will crack when it is forced into the cavity. If too much heat is used the surface of it will become pasty and will crumble when an attempt is made to carve it. To soften it in or over a flame must never be attempted as the surface will flow and then become pasty while the interior mass remains too hard to be manipulated. Until one becomes familiar with this softening process, it will be best to use a thermometer to determine when the proper heat (140° F.) has been obtained. While the wax is softening, let the patient hold water as hot as can be tolerated in the mouth in the vicinity of the cavity so that the tooth will not chill the wax too quickly when it is inserted in the cavity.

The mass of wax first softened should be shaped up by the fingers so that it will approximately fit the cavity, then the partially shaped mass is softened again and pressed into the cavity; this will insure its being forced into every corner of the cavity without cracking.

The wax is inserted into the cavity (which must be moist), pressing it in with the finger tips rather than with an instrument.

The patient is at once instructed to bite into it and to chew upon it. It is then hardened by chilling it with a stream of cold water or having the patient fill his mouth with cold water for a few minutes,

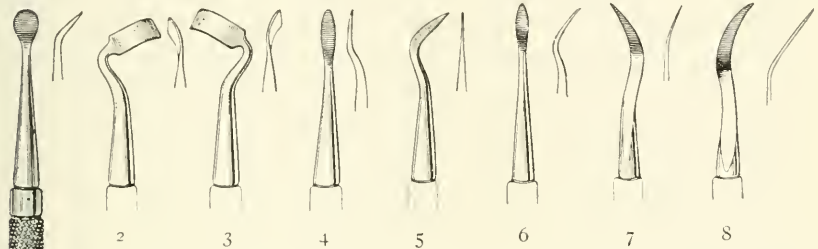

FIG. 273.—Instruments for trimming and carving wax fillings for gold inlays. 1. For occlusal surfaces. 2, 3, 4, 5, 6. For proximal surfaces and trimming along buccal and lingual margins. 7, 8. For proximal surfaces, cutting through at contact point and trimming along gingival margins.

then with suitable instruments first carve the occlusal surface to proper contour, carving flush to the marginal edges, leaving no overlap on the surface, the mass which is wedged into the proximal surface holding the filling in place during this operation.

The occlusal surface having been carved, with suitable instruments proceed to carve the proximal surface, holding the wax in place by light pressure with an instrument on the occlusal surface. Do not attempt to carve thick slices off the wax, but simply shave it off with a movement parallel to the margin until at last it is carved flush to the margin with no overlap remaining. The buccal and lingual sections should be carved before proceeding to carve the gingival section, finally passing a very thin instrument through the contact point and slicing off the portion which may have squeezed into the contour of the adjacent tooth. (Instruments suitable for this carving are shown in the accompanying illustration.) Fig. 273. Should the cavity extend rootwise considerably under the gum margin it may be necessary to adjust a matrix to secure an accurate margin at the gingival section, this should also be done in complex cavities including a large buccal or lingual section of the tooth as well as the proximal. In such cases it is well to note the character of the bite before adjusting the matrix, then carve the occlusal surface from memory, so to speak, afterwards remove the matrix, carve the buccal

and lingual proximal sections, then while thoroughly chilled have the patient close the teeth very carefully, if the occlusion be too high, note the point and carve it away.

In cavities which include mesial, distal and occlusal surfaces it will be advisable to fit a band matrix which will encircle the tooth. This may be constructed of thin platinum or silver, and such a matrix when properly adjusted will not interfere in the least with the bite.

The writer has encountered some cavities, however, to which a band matrix could not be adjusted and without which an accurate wax filling for the cavity could not be constructed. One of this character which he was called upon to fill recently was a lower left second molar, the cavity extending from the mesio-buccal angle around to the disto-lingual angle and the gingival margin of which lay about 2 mm. below the gum. The pericemental attachment was practically at the cavity margin and this would have precluded the adjustment of a band matrix even if the other difficulties to its adjustment could have been surmounted.

The case was operated on as follows:

An impression of the cavity was taken with base-plate gutta-percha, it being possible with this material in a semi-plastic condition to force it slightly over the cavity margin lying beneath the gum. From this impression a cement model was constructed, mounted in the die cup of one of the swaging machines and a 1/1000 platinum matrix was swaged and carefully trimmed to the gingival margin.

This matrix was then adjusted in the cavity and trimmed just flush with the gingival margins, without overlap at any point, then a mass of inlay wax was softened and pressed into the matrix while in the cavity and the patient was allowed to bite on it. This was removed from the matrix and the matrix from the cavity, both matrix and wax were carefully dried, the wax was then placed in position in the matrix and the crevice that was found along the gingival margin between the wax and the matrix was filled by carefully flowing melted wax into it by means of a small spatula; the wax filling now being adherent to the matrix it was replaced in the cavity, it was noted where additional contour was needed and wax was flowed on at that point, when the proper contour was at last obtained. Matrix and wax filling were removed thoroughly chilled, then with a large spoon excavator, a concavity was cut in the wax through the hole in the center of the matrix; this was to provide for additional mechanical retention of the inlay and may be resorted to in any inlay where the retentive shape of the cavity seems to be inadequate, and the securing of ad-

ditional retention would jeopardize the stability of the remainder of the crown of the tooth.

The function of the platinum matrix in the case just referred to, was simply to give a definite edge to which the wax filling could be trimmed to secure an accurate adaptation to this obscure margin so that there would be neither protrusion or recession at the cavity margin, either of which would probably have caused chronic gingivitis. Subsequently, the gold was cast into this platinum matrix which became part of the permanent inlay.

In case of pulpless teeth additional retention may be secured by inserting an iridio-platinum post (about 18-gauge) in the root canal. This should be inserted after the wax filling has been carved. Heat the post (see that it is dry and slightly roughened) and pass it through the wax filling into the root canal; it should be hot enough to melt the wax as it comes in contact with it so that it will pass through the filling without force enough to crowd it from the cavity. When chilled the wax will be adherent to the post and can be removed from the cavity by simply grasping the projecting end of the post and removing it and the filling together.

If matrices or posts are used they should always be of platinum and iridio-platinum respectively, as gold matrices and posts oxidize slightly when the mold is heated up and the cast gold does not adhere perfectly to them.

The wax filling having been completed and removed, it is chilled in ice water, then a little brass rod about 10 mm. long and 2 mm. in diameter, technically known as a sprue-former, is heated by dry heat, and pressed into the wax at either the occlusal or the proximal surface, preferably the latter, then the investment or mold material is mixed to about the consistency of thick cream. In mixing this simply sift the compound into the water, avoid stirring it so that there will be no bubbles.

Dr. Taggart has devised two measuring cups, one for the water and the other for the compound which gives just the proper proportions. The compound sets slowly so that there is ample time for careful, deliberate application of it to the wax model. It should be applied with either a small sable brush or small pointed spatula; a little is laid on at a time and carefully worked into all the corners and angles, especially along the lines of the margins, then after all the surfaces have carefully been covered, more compound is added until the model is covered at all points with an investment about 2 mm. thick.

Then the case appears simply as a brass rod with a mass of investment material on the end of it. This brass rod is now inserted into the hole in the center of the base plate of the molding flask which consists of a metal ring, and a base plate. The ring is about an inch in length, varying in diameter, according to the size of the casting to be made (for by this process a casting as extensive as that of a fourteen tooth bridge may be made), with a small hole in one side near the base to permit the surplus mold material to escape.

The base plate is so constructed, that while it fits into the ring for a couple of millimeters there is also a flange section with a milled edge which extends beyond the side of the flask. In the center of base plate, is a dome and in the center of that there is a hole into which the sprue-former is inserted. Having set the sprue-former in position, put the ring in place on the base plate and fill it with the mold material or investment, slowly rotating the flask as you do so.

Build up an excess above the top of the flask, then press a piece of glass plate down upon it which will force the excess through the little hole in the side of the flask. The glass plate is removed by sliding it across instead of lifting it.

When the investment has set, the flask is heated slightly, then grasping the milled edge of the base plate it is gently turned. This breaks the adhesion of the mold material to it without disturbing the surface and the base plate and sprue-former are withdrawn from the mold. Do not invert the flask in doing this, for if this be done and some of the investment material should flake off it would drop into the sprue hole and result in a flaw in the casting. The base plate should be kept clean and polished at all times, rubbing off the surface after cleaning with a little vaseline.

The base plate and sprue-former having been removed, there will be found a cup-shaped depression in the center, with a hole leading to the mold. The flask is placed over the Bunsen burner in an oven which has been devised by A. C. Clark & Co., and the case heated slowly, carrying the heat to a point where the wax is ignited. The case is kept at this heat until not only has the wax been burned out, but the residual gases therefrom have also been combusted. It is highly important that the mold be kept intact, to obtain a flawless casting. To insure this, heat the flask slowly and do not subject it to any greater heat than is necessary to consume the wax and its gases.

Take precautions to avoid chipping the investment about the concavity and the sprue hole, for if these chips should fall into the mold and it frequently is impossible to remove them if they do, they cause a

faulty casting and if the fault be along any of the margins, your inlay is ruined beyond repair.

The burning out of the wax and its gases being completed, the flask is grasped with tongs and placed in the flask holder of the casting machine.

It may be well to briefly describe the casting machine. It consists of a device which holds a 100 gallon cylinder of nitrous oxide, has a pressure valve which may be set for the pressure desired, two dial pressure indicators, one of which registers the pressure in the cylinder and the other the pressure under which it is released, a blow pipe, a compressing lever, a mold flask holder, and a signal whistle which sounds until the escape valve of the gas cylinder has been closed after the casting has been made, a very valuable little device by the way which prevents the inadvertent loss of a cylinder of gas.

The flask having been placed in the flask holder, a button of gold is placed in the cup-shaped depression of the mold and the flame of the nitrous oxide blow pipe is directed against it. The use of the nitrous oxide blow pipe concentrates a small intense flame directly upon the gold, melting it thoroughly without affecting the surrounding mold as the ordinary gas blow pipe flame would.

The button of gold having been melted until it fairly boils, the compressing lever is brought down, thrusting aside and shutting off the blow pipe, forcing a metal cover, with asbestos rim packing to make it pressure tight, upon the flask ring and releasing upon the molten gold a gas pressure of about twelve pounds from the gas cylinder, forcing it into the mold in the center of the flask, the residual air being driven into the minute pores of the mold investment ahead of the gold.

The various operations are done automatically by the downward sweep of the compressing lever. The whole operation is practically instantaneous, the molten gold has no opportunity to cool and solidify until it is forced into the mold; the gas pressure is confined absolutely to the mass of gold and is sustained while it is cooling, and therein lies the main factor of success of this method.

The flask is cooled, the investment broken out and a gold casting, the duplicate of the wax filling with a metal sprue attached is found.

The metal sprue is cut off with a fine saw or pair of nippers, the gold inlay is immersed in hydrofluoric acid for a short time to remove the particles of investment material that will be found fused to it, then washed, boiled in sulphuric acid and washed again. Frequently the outer surface will need little or no polishing save at the point where the sprue was attached, so perfectly may castings be made

by this process if the wax filling be carefully finished and all the various steps carefully carried out.

After trying in the inlay, if it should be found that the proximal contour is insufficient, this may be added to by simply flowing on a little 22-K solder at that point. It has been found by experience that it is not necessary to reheat the flask before placing it in the machine, should it have cooled off before the wax has been burned out; it must be perfectly dry, however, otherwise there will be a regurgitation of steam that will either blow the gold out of the depression when it is molten or prevent the complete casting, according to the amount of steam developed.

Incidentally it may be pointed out that this method allows one to obtain full value for gold scrap, as gold scrap containing even platinum, solder or clasp gold may be used. The scrap as scrap should be melted into a button before placing it into the flask.

After many experiments the writer uses a gold alloy consisting of equal parts of 24-K gold and 22-K solder. Large inlays may be constructed of this, without danger of flow of material under severe and continued stress of heavy mastication.

The effectiveness of this casting device may be appreciated when you are informed that by it clasps may be perfectly cast of clasp gold.

With this casting machine has been cast gold crowns upon platinum, bases; bridge section even up to those embracing the entire arch; clasps; retaining splints; partial plates; and even full plates may be cast.

There is no question but what Dr. Taggart's invention of appliance and process marks a new epoch in both operative and prosthetic dentistry; its value is such that the profession and the public are under obligation to him.

Since his demonstration of appliance and process other appliances for casting have been devised and presented. One very ingenious machine was originated by Dr. Jamieson, of Indianapolis. It casts by centrifugal force, the flask having a swivel handle is hung from a hook at the end of a horizontal rod about a foot long attached to an upright rod which is revolved by the release of a spring at the rate of about 3000 revolutions a minute.

Another device originated by Dr. Moll, of Chicago, casts by suction, a partial vacuum being created. Still another device, the originator of which the writer cannot ascertain, casts by means of steam pressure. A pad of moistened asbestos is jammed down upon the flask, the heat of the molten gold developing steam of sufficient pressure to force the

gold into the mold. The results by this method are uncertain, the writer experiencing fully 50 per cent of failures by it.

All these methods, however, are based upon that of Dr. Taggart's, in that they employ a wax filling as a model and a flask for the mold identical with his, and it may be remarked that these were the most important factors of his invention, the solution of the casting device being the least difficult of the problems.

The writer has tried all methods and devices for casting and after many experiences states unequivocally that Dr. Taggart's appliance has a wider scope and produces more uniform and more perfect results than does any other. He holds no brief for the gentleman and is under no greater obligation to him than is any and every member of the profession. The statement is made simply because it is a fact.

This process supplants all others because better results can be obtained with less labor for the operator and less loss of time for both operator and patient.

Just a word of serious warning in closing this chapter to those about to employ this method. Do not imagine that it discounts care and skill. One may think it is no trick at all to construct a wax filling for a cavity, but let me assure you, and experience will emphasize it, that it requires all the skill and patience you possess most of the time to properly construct this wax filling and you will probably be discouraged with the process and your endeavors, until you have mastered the manipulative technique; for faulty wax fillings will invariably result in faulty inlays.

Skill, care and cleanliness must be observed in all steps of this process. Once the manipulative technique peculiar to this process has been mastered, one will discover that instead of discounting, it puts a premium on individual skill and carefullness. For by this process more uniform and better results with less labor may be obtained than have heretofore been possible with any process at our command.

CHAPTER XVIII.

THE TREATMENT OF EXPOSED OR NEARLY EXPOSED PULPS.

BY J. P. BUCKLEY, PH.G., D.D.S.

GENERAL CONSIDERATIONS.

In the practice of dentistry there are problems continually arising wherein it is difficult for the conscientious operator to decide upon a method of procedure which will conserve the best interests of the patient. There is no condition confronting us with greater difficulty than in those cases where the decay has extended to such a depth that its thorough removal will expose or nearly expose the pulp. The problem to be solved here in all such cases is to decide whether it will be best to try to save the pulp or to anesthetize or devitalize this organ, remove it and subsequently fill the canals.

There are several important factors to be considered, and upon which will largely depend the success or failure following an attempt to save the pulp after it has actually been exposed. In an accidental exposure in the preparation of a cavity, the chances for saving the pulp, provided the injury has not been too great, are far more favorable than if the pulp had been exposed by the necessary removal of carious dentin. Our success will also depend in no small degree upon the condition of the pulp as well as upon the general condition of the mouth of the patient in which the exposure occurs. If there is congestion or any evidence of degeneration of the structural components of the pulpal organ itself, it would be futile to attempt to cap it, as would be also any attempt to permanently save a pulp in the mouth of a patient who was suffering from some systemic derangement interfering with the general circulation, thus lessening vital resistance; for in such cases the pulp would fail to receive from the blood supply the necessary elements for the restoration of its functional activity. The general condition of the mouth itself and the care it receives daily from the patient, is an essential factor to be taken into consideration before proceeding to cap a pulp. Dr. S. A. Hopkins, of Boston, in a carefully conducted series of experiments to ascertain the difference in virulency of certain pathogenic bacteria in different mouths, and in the same mouth under

different conditions, proved that not only did the germs proliferate more rapidly in neglected and uncared-for mouths, but their pathogenic properties are greatly increased.

There is one class of cases of pulp exposure which frequently presents in a busy practice and in which it is our plain duty to make the attempt to restore the organ to its normal function, even though the conditions for doing so are not altogether favorable. I mean here those cases in the mouths of young patients where the pulp is exposed from decay and the roots of the tooth have not been fully developed. Every effort should be made to cap such a pulp and thereby save it, if for only a year or two, for clinical experience has demonstrated that to remove the pulp and properly close the large openings in the end of the roots is, at best, a difficult procedure; that a tooth in this condition, thus treated, is usually a source of annoyance and its usefulness generally of short duration.

In another class of cases the author also believes that we are justified in capping the pulp. For instance, in those cases of exposure where for certain reasons it is desirable to save the tooth, and on which it would be difficult to adjust the rubber dam, aseptically remove the pulp and thoroughly fill the canals. I wish to state here, however, that I do not mean to infer that a pulp should be capped in an anterior tooth, because of the liability of the tooth structure discoloring after the pulp has been removed. This phase of the subject will be referred to in detail in a subsequent chapter on pulp removal under the preservation of the color of the tooth.

From the foregoing, then, it should readily be understood that no set of rules can be given, the application of which will surely lead to success. Every case must be studied and treated according to the operator's best judgment after having taken into consideration all these various factors.

CAPPING THE PULP.

There are several methods of capping the pulp, each differing in minor details, such as the use of various cements, gutta-percha, concave metallic discs, etc., etc. In the remainder of this chapter attention will be directed to the general precautions to be taken in following the different methods of capping; after which one method will be described in detail which has proved successful in the author's practice. By this I do not mean to convey the idea that all pulps which I have attempted to save have been rehabilitated to their functional activity—many have not; however, a sufficient number of those thus treated have

remained quiet, and proved years later to be vital, to justify making the attempt where the case demands.

Precautions.—The precautions to be observed in following any method are:

(1) By the use of an anodyne, the hyperemic pulp, if in this condition, *must be restored to normal* before the final capping.

(2) The dentin overlying the pulp *must be thoroughly sterilized.* It should be noted here that the usual perfunctory method of sterilizing the dentin by simply applying a germicidal solution to the cavity for a few moments does not sterilize to the degree necessary for successful results. The lack of thorough sterilization has, without doubt, been the chief cause of failure. The accuracy of this statement will be seen when we remember that our greatest success has followed the capping of pulps which have been accidentally exposed with a bur or instrument in preparing a cavity, although, in most cases, greater mechanical injury had been caused than when the exposure was due to caries or the removal of carious dentin.

(3) Pressure in applying the material for capping, or the cement which covers the capping, *must be avoided.*

Technique.—After breaking down all overhanging edges of enamel and removing as much of the debris and softened dentin as can be done without pain or injury to the pulp, the cavity should be flooded with a mild, non-irritating, antiseptic solution, previously heated to the temperature of the body. For this purpose the author suggests the use of peppermint water to which 95 per cent phenol has been added in the following proportion:

℞ Phenolis, f.℥ j
Aquæ menthæ piperitæ, f.℥ vj—M.
Sig.—Use wherever a mild, non-irritating antiseptic solution is indicated.

This solution can be further diluted, if necessary, and used with a water syringe, before applying the rubber dam, thus adding comfort and cleanliness to the operation. The excess can now be absorbed from the cavity with cotton and the dam adjusted. By using some obtunding remedy and a sharp spoon excavator, or oftentimes a large round bur in the engine, the carious dentin can be removed. If, however, the thorough removal of all the softened dentin would make a large exposure, it is best to leave the layer overlying the pulp and depend upon the sterilizing agent, rather than to jeopardize the life of this organ by the injury thus produced. The delicate pulp tissue will not tolerate much abuse and remain quiet, therefore if it is injured to any

great extent it had better be removed at once. The dentin can now be sterilized by sealing in the cavity, for a week or two, the following remedy which is not only germicidal in action, but possesses marked anodyne properties as well:

℞—Menthol, ʒ j
Thymol, ʒ ij
Phenolis, q. s. ad., f. ʒ iij—M.
Heat the phenol and then carefully add the menthol and thymol.
Sig.—Use as directed.

For convenience this remedy will be called *modified phenol*.

It is best to seal with a veneer of quick-setting cement, previously filling most of the cavity with cotton, thereby avoiding pressure and facilitating the subsequent removal of the dressing. By this means the dentin can be thoroughly sterilized, and the pulp, if at all hyperemic, as it is likely to be, will return to its normal condition.

Thymol has a peculiar but favorable action on animal tissue, and for this reason it is incorporated in the prescription. At the next sitting, the case giving a favorable history for the interval, the dam should always be applied, the teeth included sterilized and the previous dressing carefully removed, when the exposure and dentin immediately over the pulp can be gently covered with a thin paste made by mixing pure precipitated calcium phosphate with modified phenol, oil of cloves, or eugenol. The paste should be placed on one side of the cavity and gently coaxed over the exposure in such a manner as to exclude the air. I desire to emphasize the importance of covering the entire dentin immediately over the pulp, as well as the exposure, with this antiseptic and non-irritating paste. By this means we prevent the phosphoric acid of the cement, used to cover the paste and to temporarily fill the cavity, from irritating the pulp. It is best, as intimated here, to fill the entire cavity with cement and wait for a few months or perhaps a year before inserting the permanent filling or inlay. Advantage should be taken of every possible means of preventing subsequent irritation to the pulp. For this reason largely the author uses precipitated calcium phosphate instead of calcined zinc oxid, which latter substance is recommended by many writers. The powder (largely zinc oxid) which comes with a package of cement is supposed to be chemically pure. Those who are familiar with the science of chemistry, however, know that arsenic is found associated in nature with many of the metals, among which is zinc; and, while it can be done, it is difficult to obtain these metals or their oxids free from

arsenic. It is well, especially in those cases where the pulp is not quite exposed, to add a small amount of either *aristol* or *europhen* to the paste. These are iodin compounds and are used as substitutes for iodoform. Both are tasteless, practically without odor, and insoluble in water, but soluble in the *oil* used as the vehicle for the paste, therefore only a small amount should be added.

In closing this chapter, I desire to emphasize the importance of studying carefully the conditions as found in each case; and to say that the opportunity here for exercising good judgment is very great, and that there is a satisfaction in realizing, whether we succeed or fail in our effort to save the pulp, that we did our duty as we saw it.

CHAPTER XIX.

THE ANESTHETIZATION AND DEVITALIZATION OF PULPS, THEIR REMOVAL, AND THE SUBSEQUENT TREATMENT.

BY J. P. BUCKLEY, PH. G., D. D. S.

GENERAL CONSIDERATIONS.

Embryologists claim that when the roots of a tooth are fully developed, the pulp has no further function to perform. If this theory can be accepted as correct, and I think that it is quite well established, it would appear from the large percentage of failures following the most careful methods of pulp capping, that the safest, and, therefore, the best practice would be *to destroy the vitality and remove the pulp* in all cases where this delicate and susceptible tissue had been previously irritated for any great length of time, unless, as explained in the foregoing chapter, there was some special reason for attempting to restore the organ to its functional activity. From sad past experience the author has been led to adopt this general practice. By this I do not wish to convey the idea that it is advisable or necessary to miscellaneously or ruthlessly destroy pulps, for such is not the case. It is the plain duty of every dental practitioner to save the pulps of teeth, if it can be done with any reasonable degree of success. There are many conditions, however, which necessitate the removal of the pulp, such as:

(1) *Dental caries*, or the invasion of pathogenic bacteria and the absorption of ptomains. This is the most prolific source of pulp irritation.

(2) *Mechanical irritation*, due to such causes as abrasion, thermal changes, close proximity of metallic fillings, injudicious regulating, excessive grinding, etc.

(3) *Calcific deposits*, or pulp nodules within the pulp itself. These calcific bodies result from slight but continued irritation of the pulpal organ.

(4) *Crowning teeth and filling large cavities.* It is usually difficult to grind a vital tooth sufficiently to adjust the band for a crown properly, without irritating the pulp and thus endangering its life. Sometimes in filling teeth it is advisable to remove the pulp in order to properly anchor a large filling or inlay.

(5) *Pyorrhea alveolaris.* Frequently in treating this disease the best results can be accomplished by removing the pulp and thereby throwing the entire circulation to the sluggish pericemental membrane.

Factors to be Observed in Removal of Pulp.—Having considered all of the conditions and deciding that the removal of the pulp is indicated, the method by which this can be accomplished with the least inconvenience to the patient and to the operator is the most important consideration. Whatever method is employed in the removal of pulps from teeth and the subsequent treatment, there are at least three factors to be observed, viz.:

(1) Establish and maintain asepsis in performing the operation.

(2) Preserve the color of the tooth.

(3) Thoroughly fill the root.

METHODS.

I. *Anesthetization.*—In the author's opinion a very satisfactory method of removing pulps from teeth, to both patient and operator, all things considered and conditions being favorable, is to anesthetize the tissue by the use of various strength solutions of local anesthetic agents. The solutions are forced or carried through the dentin and into the pulp by means of pressure or the electric current.

(1) *Pressure Anesthesia.*—By pressure anesthesia is meant the process of anesthetizing the pulp by forcing solutions of local anesthetics, usually cocain hydrochlorid, into the tissue by means of pressure. The pressure is applied either by using unvulcanized rubber or gutta-percha, and a blunt instrument, or by specially devised instruments for this purpose. There are many such instruments on the market; and while they are often an aid in accomplishing the ultimate result, they are not an absolute necessity.

The rubber dam should be employed in every case where it is possible to adjust it, and the teeth included sterilized. In cases where the dam cannot be adjusted, it would doubtless be best to remove the pulp by the devitalization method, to which reference will be made later in this chapter, for in using the method under consideration care must be taken to prevent pericementitis following the operation; and one of the precautions to be observed in preventing this result is to *thoroughly sterilize* the cavity before applying the pressure. It should be remembered that the majority of canals which contain live pulps are sterile, generally speaking, and if they become septic at any time before the root is filled, it is the fault of the operator. Thus the importance of

always adjusting the rubber dam, using sterile instruments, and having in a convenient and conspicuous place an antiseptic doily on which to wipe the blood and dry the instruments used.

Attention is again directed to the fact that the usual custom of applying coagulating agents, such as phenol, cresol, etc., to the cavity for a few seconds, does not sterilize the dentin to the degree desired. The best results are accomplished by employing germicidal agents which are soluble in water. In cavities where the decay is not too deep, the dentin can be sterilized by the use of a 10 per cent solution of formaldehyd to which 5 per cent of sodium borate (borax) or sodium carbonate has been added. Where the decay is near the pulp this solution is liable to cause pain, in which case the same result can be accomplished by the use of a 1:500 solution of mercury bichlorid. In using the latter solution the pliers on which the remedy is applied should be wiped immediately on an antiseptic doily to prevent the mercury from acting upon the instrument. One of the best solutions with which to chemically sterilize the dentin, especially in those cases where the cavity has previously been filled and the tubuli are closed and perhaps there is secondary dentin, is a 25 per cent solution of sulphuric acid. Dr. Geo. W. Cook, of Chicago, recommends using pure sulphuric acid for this purpose. The solution can be applied to the floor of the cavity, being careful not to get the agent on the crown of the tooth. After a few minutes the excess can be neutralized with a solution of sodium bicarbonate. After the dentin is sterilized the cavity should be desiccated with warm alcohol and gentle heat, when we are ready to use the anesthetizing solution. Before taking up the technique of this method, however, I desire to emphasize the importance and necessity of cavity sterilization. In our discussion later of the devitalization method, it will be pointed out that the carious and infected dentin can be completely and painlessly removed after the devitalizing agent has been applied, thus *mechanically* sterilizing the cavity; but in the anesthetization method the infected dentin is sensitive and cannot be removed without unnecessarily producing pain. The dentin in this case must, then, be sterilized by *chemical* means, for to force the anesthetizing solution through the dentin without previously sterilizing it, means the forcing of microorganisms, and perhaps poisonous ptomains, into the pulp tissue and many times into the tissue surrounding the apical end of the root, for it is difficult to force the solution to, and only to, the apex; thus too much pressure and the lack of thorough sterilization constitute a prolific source of pericementitis following the removal of pulps by this method.

With the cavity thoroughly sterilized we are now ready to use the anesthetizing solution, which should be made at the time. For this purpose the crystals of cocain hydrochlorid, previously powdered, should be used as the base, and freshly distilled or boiled water as the vehicle. In my own practice I use the flaked cocain hydrochlorid as the base and my regular local anesthetic solution as the vehicle for making the stronger solution. A prescription for the regular local anesthetic solution here follows:

℞—Cocainæ hydrochloridi,	gr. vj
Phenolis,	m. ij
Aquæ menthæ piperitæ,	f. ℥ j —M.

Sig.—Use as a local anesthetic for hypodermic injections.

The flaked cocain hydrochlorid not only insures a pure specimen of the drug, but facilitates making the solution, as the flakes are so readily soluble. There is no advantage in using the above solution over distilled or boiled water or freshly prepared peppermint water, except that the solution is always at hand in a convenient container and is sterile.

The thumb and forefinger with which cotton is to be wrapped around the broach should be sterilized by dipping a large pledget of cotton in the 10 per cent formaldehyd or 1:500 mercury bichlorid solution and rolling this between the thumb and finger. A small amount of the alkaloidal salt is now placed on a clean glass slab and a pledget of cotton, dipped in the vehicle selected, a few drops of which have previously been placed on one end of the glass slab or in a clean glass watch crystal or other container, is gently placed in contact with the flakes, when the latter readily dissolves, making a strong solution. It is never necessary to make a saturated solution, for oftentimes better results will be obtained, especially if the solution is to be forced through the dentin, if the strength of the solution approximates only 4 or 5 per cent.

The cotton thus saturated is placed in the cavity as nearly over the pulp as possible. A piece of unvulcanized rubber which will approximately fill the cavity is selected and passed through the flame. There are two objects in doing this: It sterilizes the rubber, and also makes it more pliable in which form it conforms readily to the cavity of the tooth. The rubber is now placed in the cavity, and by means of gentle but firm pressure with a suitable blunt instrument the solution is forced through the dentin and into the pulp. If there is any evidence of pain as the pressure is applied, it should be stopped for a moment, but never released. The slight pain is only momentary and is an in-

dication that the solution is being confined under the pressure, which is essential for the success of this method. It may be necessary in those cases where there is considerable dentin between the cavity and the pulp to make two or three applications before the pulp is reached without pain, after which one application should complete the thorough anesthetization of the organ. After the first application a small depression can be drilled into the dentin toward the pulp, in which the solution can subsequently be placed, thereby aiding materially in confining the solution under the pressure. When an exposure exists it requires but little pressure to anesthetize the pulp. In these cases the cocain hydrochlorid can be placed in the cavity near or over the exposure and the pulp gently pricked with a sharp explorer, causing it to bleed; this if done carefully will produce very little pain. The blood will dissolve the cocain hydrochlorid, when pressure can be applied and the pulp anesthetized. In doing this, however, there is greater danger of forcing the blood into the tubuli of the dentin of the crown of the tooth, thereby making it more difficult to remove the blood. Care should also be taken not to force the solution any further than is necessary for the painless removal of the pulp, for it should be noted here again that cocain is a general protoplasmic poison, and if even weak and sterile solutions are forced past the apices of the roots pericementitis is almost sure to follow.

When the pulp is anesthetized the pulp chamber should be opened into in such a manner as to expose the canals. This is best accomplished with a large round or inlay bur by means of which the entire roof of the chamber can be obliterated. In opening into the pulp chamber of molar teeth care should be taken not to disturb the floor of the chamber, for by so doing we are liable to add to the difficulty of entering the canals with a broach. While we are never justified in drilling unnecessarily for the purpose of freely exposing the canals, it is, if necessary, far better to weaken the crown of the tooth somewhat by this means rather than leave a portion of the pulp in an inaccessible canal which may decompose and subsequently cause an abscess.

The selection of a proper broach is an important matter. Every broach should be tested before entering the canal. This can be done by bending it in various directions. If the broach is weak in any particular place it can be detected by this means; thus we avoid breaking the broach in the canal, the removal of which is often a difficult procedure. Many good operators claim to be able to remove all pulps by using a smooth, three-cornered broach on which a few threads of cotton are wound. Others use twist or spiral broaches. In all large

canals the author has had the most satisfaction from the use of a barbed broach. The broach should be gently worked along the side of the canal as far as it will go without using too much force, twisted once or twice to entangle the pulp, and then withdrawn. By this means the pulp can be removed from large canals in its entirety.

In the removal of live pulps by the anesthetization method, there necessarily would be more hemorrhage than in those cases where the pulp was devitalized before attempting to remove it. However, the control of hemorrhage is not as difficult a procedure as many writers have led us to believe. In most cases the hemorrhage, if undisturbed. will be checked by nature's method in a few minutes; after which the blood in the cavity and canal should be *thoroughly removed*. I desire here to emphasize the importance of *removing* the blood. One of the factors to be observed in extirpating pulps from teeth and the subsequent treatment, is to *preserve the color of the tooth*. The cause of many teeth darkening after the pulp has been removed, can be traced directly to the failure to remove the blood from the dentin of the crown of the tooth. The far too prevalent practice of wiping out the bloody canal with a solution of hydrogen dioxid, blindly thinking the blood can be removed by this means, cannot be too strongly condemned. The hydrogen dioxid simply decomposes the blood within the tooth structure, oxidizing the iron of the hemoglobin; and the gases evolved in the decomposition force this pigment into the tubuli, which, if left (and it is difficult to remove it), will cause the tooth to darken in almost every instance. In a subsequent chapter the author expects to show that ferric oxid is largely responsible for the discoloration of teeth from pulp decomposition. Therefore we should avoid forming within the tooth structure the pigment which we know will discolor teeth. *The color of a tooth does not depend upon the life and vitality of the pulp, but upon the array of colors in the dentin which are reflected through the nearly colorless and transparent enamel.* If, then, these colors are not changed by our failure to remove the blood or by the use of staining remedial agents in the subsequent treatment following pulp removal, the tooth will not discolor.

To remove the blood from the canal, alcohol can be used, or even better than this agent is nature's greatest solvent, water. The water should, of course, be sterile, and the same specimen can be employed here as was used in making the anesthetizing solution, *i. e.*, freshly distilled or boiled water, or peppermint water to which two minims of phenol has been added to the fluid ounce. If convenient, a little sodium chlorid (common salt) can be added to the water. By

this means the blood can be completely *removed*, not decomposed in the canal and forced into the structure of the tooth.

There are many canals so small and tortuous that even a fine broach will not enter, to any depth at least. In these cases, after the hemorrhage from the larger canals has been checked and the blood removed, the pulp tissue in the small canals can be disorganized by the use of strong solutions of mineral acids or alkalies. The author prefers making a paste of sodium dioxid and absolute alcohol, placing the paste in the pulp chamber over the small canals, and working it down as far as possible with a smooth broach. The alcohol gradually evaporates, when the sodium dioxid can be decomposed into oxygen and caustic soda by placing a pledget of cotton in the cavity moistened with distilled water. After the reaction has taken place, the alkali can be neutralized with a weak solution of sulphuric acid (2 per cent). This process can be repeated until the desired end is attained. There are other means by which the same result can be accomplished, such as the use of pure phenolsulphonic acid, a 50 per cent solution of chemically pure sulphuric acid, strong solutions of sodium or potassium hydroxid, or a mixture of metallic sodium and potassium (Schreier's paste). These same agents, especially the phenolsulphonic acid, can be used to advantage for the purpose of disposing of a remnant of a pulp in larger canals. It is not safe to anesthetize this remnant by means of pressure. The only cases on record to my knowledge, where toxic symptoms have resulted from the removal of a pulp by pressure anesthesia, followed an attempt to anesthetize a remnant of a pulp or in making the second application of the anesthetizing solution.

After the pulp has been removed and the canals dehydrated with alcohol and heat, an *anodyne* treatment is indicated. For this purpose such drugs as phenol, oil of cloves, or eugenol can be employed. The author suggests here the modified phenol solution to which attention was called in the chapter on The Treatment of Exposed or Nearly Exposed Pulps. In using any of these remedies, especially the last named, it is best to insert dry cotton in the canal and then place a pledget dipped in the remedy in the pulp chamber and seal with temporary stopping or cement. The dry cotton in the canal will absorb the moisture from the apical end of the root and the anodyne remedy from the pulp chamber. There is an advantage in using the dry cotton, for it is almost impossible to completely dehydrate the canal at this sitting. If asepsis has been maintained in removing the pulp all that is necessary is to keep the canal in this condition until the root can be filled. The canals should not be filled at the sitting at which the pulp

has been removed by pressure anesthesia unless there be some exceptional reason for doing so. There are many good reasons why the canal should not be filled at this sitting:

(1) While it is our object to force the solution just sufficiently to anesthetize the pulp, our main object is to remove the pulp *absolutely without pain*, and it is very difficult to force the solution to the end of the root without forcing it through the apex and anesthetizing the tissue in the apical area to some extent. With the tissue anesthetized we would have no guide as to when the root was thoroughly filled.

(2) The tearing away of the pulp from its connection at the apex causes more or less irritation, and a few days should elapse to give nature a chance to readjust the condition. The root filling would only serve at this time to further irritate the tissues.

(3) Sometimes with the utmost care in removing the pulp, secondary hemorrhage ensues with the formation of a clot in the apical area, causing soreness, in which case greater comfort can be given the patient by the proper treatment through the root canal than simply by counterirritation or external treatment only.

At the second sitting, the case giving a favorable history, the canals should be filled.

There are cases occasionally where nature does not stop the hemorrhage as readily as we desire. In these exceptional cases the hemorrhage must be stopped by artificial means, even at the possible expense of producing pericementitis. Cauterizing agents are useful here. For this purpose 95 per cent phenol, a 50 per cent solution of phenolsulphonic acid, or a 15 per cent solution of trichloracetic acid, can be worked down into the canal against the injured and bleeding tissue, after which the anodyne treatment is employed as usual. Where the above treatment does not produce the desired result, cotton saturated with a fresh 1:1000 solution of adrenalin chlorid can be placed in the canal and with unvulcanized rubber forced into the tissue beyond the end of the root. This should only be used in extreme cases because of the soreness it is liable to produce.

In this connection I desire to discuss the use of solutions of adrenalin chlorid as the vehicle for making the anesthetizing solution, or the use of adrenalin chlorid and cocain hydrochlorid tablets for anesthetizing the pulp. The adrenalin chlorid has been suggested as a means of *preventing* hemorrhage. Now, it ought to be evident to any one who has studied this subject that to prevent hemorrhage by the use of any hemostatic agent, it is necessary to force the agent into the

tissue from which the hemorrahge comes. Therefore, to get the effect of the adrenalin chlorid in removing pulps by pressure anesthesia, it is absolutely essential that the anesthetizing solution which also contains the hemostatic agent, be forced through the apex and into the apical area—the very thing we have been taught, from sad experience, not to do. When we remember that the majority of pulps we are called upon to remove are those in which there is, or has been, more or less pulpitis, and when we remember also that pathology teaches that this condition is frequently associated with pericementitis, it is questionable whether or not we ought to prevent hemorrhage in removing pulps from teeth. For to permit the escape of blood from the hyperemic tissue at the end of the root, is one of the best means of aiding nature to readjust the abnormal to the normal condition. In case the primary hemorrhage has been prevented by the use of hemostatic agents, such as adrenalin chlorid, secondary hemorrhage is almost certain to follow with the formation of a clot, the absorption of which in the apical area is an extremely slow and tedious process.

In removing pulps by pressure anesthesia without employing instruments devised for this purpose, the best results are obtained in cases where there are four walls to the cavity, for in this condition the solution is easily confined under the pressure. In proximo-occlusal cavities, the missing wall can be built temporarily with gutta-percha or cement. This is seldom necessary, however, if, in packing the rubber in the cavity, care be taken to cover the gingival wall first and thus seal at this point, then working the rubber over the occlusal and gradually creating the pressure. Whatever means is adopted for the purpose of confining the solution, we must avoid having the solution escape at the gingival margin of the cavity and thereby be forced into the gum tissue and pericemental membrane. The cause of many sore teeth following this method of removing pulps can be traced to carelessness or ignorance in this regard. As stated elsewhere in this chapter, there are many ingeniously devised instruments on the market, the use of which is often a material aid in confining the solution under pressure and forcing it through the dentin. The same precautions should be observed in using any of these instruments as have been emphasized in the application of pressure by other means.

(2) *Cataphoresis.*—Cataphoresis is a term applied to the process of carrying medicinal agents in solution into the various tissues and organs of the body by means of the electric current. There is a variety of cataphoric outfits on the market. To anesthetize a pulp by this means the tooth should be insulated by the rubber dam, care being

taken that no moisture escapes from the gum. A small pledget of cotton saturated with the anesthetizing solution is now placed in the cavity, the positive electrode applied to the solution, and the negative electrode, moistened with water, applied to some part of the patient's body, usually the hand, thus completing the circuit. A steady and continuous current is desired and the perfected instruments are so devised that the amount of current can be measured. The time required to anesthetize the pulp by this means depends largely upon the density of the dentin and the perfection of the instruments used. With the pulp anesthetized, the same method of removing and the subsequent treatment is followed as in pressure anesthesia. Cataphoresis, while successful in the hands of those who mastered the technique, never became popular, largely because of the time required to accomplish the result and because of the complicated and expensive apparatus necessary.

If the method of anesthetizing the pulp be followed and the precautions observed as detailed in this chapter, it will be found that there are few pulps which will not yield to the influence of cocain hydrochlorid. It takes time, however, to adjust the rubber dam, sterilize the cavity, remove the pulp and blood from the canal and seal in the anodyne remedy. Many times the operator is not able at this sitting to give the necessary time to complete this operation. There are cases also where the condition or the location of the tooth in the mouth is such as to make the removal of the pulp more favorable by another method which will now be considered.

II. *Devitalization.*—In the chapter on The Treatment of Sensitive Dentin under the subject of escharotics or caustics, reference was made to the fact that there were many drugs belonging to this class of agents that could not be employed in the treatment of sensitive dentin, for the reason that they were penetrating and had the same deleterious effect upon the cells of the pulp tissue as upon the dentinal fibrillæ. Some of the agents which cannot be used for allaying the sensitiveness of dentin are exceedingly valuable and are employed for the purpose of destroying the vitality of the pulp, thus aiding in its painless removal. The most prominent of these agents is *arsenic trioxid*, (As_2O_3), formerly called arsenious acid. The author is again gratified to know that the latest edition of the United States Pharmacopeia recognizes this agent by its correct chemical name, for he was never able to understand why a true *oxid* should be called an *acid* by our legal authority. Arsenic trioxid was introduced to the dental profession in about 1836 by a Dr. Spooner, of Montreal. The agent was first advocated to be used in

the treatment of sensitive dentin; for Dr. Spooner discovered that by sealing the drug in a cavity for a few days the most sensitive dentin yielded to its influence. The fact, however, that nearly all teeth thus treated subsequently gave trouble because of the death of the pulp and the usual sequelæ, led the profession to abandon this agent for the purpose for which it was introduced; but it has ever since been used as a means of destroying the vitality of the pulp. In fact, for years it was the only agent employed with any satisfaction.

There has been much difficulty experienced in the use of arsenic trioxid, largely because of the uncertainty of the preparations employed. Many arsenical preparations are on the market. The white powder can be used by moistening a small pledget of cotton with some liquid, such as phenol, cresol, creosote, or oil of cloves, then by touching the cotton to the powdered arsenic trioxid, a sufficient amount will adhere which should be transferred to the cavity and sealed, preferably with cement. It is well for each operator to select an arsenical preparation with which he can obtain good results, and then this should be used to the exclusion of all others. By this means only can we become thoroughly familiar with the action of the preparation employed. The author prefers a paste, a formula for which is here given:

℞—Arseni trioxidi, ʒ j
Cocainæ, gr. xx
Menthol, gr. v
Lanolini, q. s. ft. stiff paste —M.
Sig.—Apply a small amount to the dentin immediately over the pulp.
Note: A sufficient amount of lampblack should be added to color the paste.

I wish to state here something about the pharmacy of this prescription; for if the preparation does not work satisfactorily, it has not been properly compounded. Arsenic trioxid is the base, cocain is a local anesthetic, and when applied to the pulp produces a condition of analgesia by which the irritating action of the arsenic trioxid is without effect, and thus prevents the tooth from aching while the pulp is being devitalized. With the fatty or oily vehicle, lanolin, it is best to use the alkaloid, cocain, rather than the alkaloidal salt, cocain hydrochlorid; and the less the amount of lanolin used the better will be the action of the base. For this reason largely menthol is added. This agent is a highly deliquescent substance, and there is a sufficient amount of water in the lanolin to liquefy the crystals of menthol, therefore it requires but a small amount of lanolin with the menthol to make a paste out of the arsenic trioxid and cocain.

In those cases where the tooth has ached before the patient presents for treatment, it is always the best practice to allay the pain for at least twenty-four hours before attempting to devitalize the pulp. In any case, whether the tooth has ached or not, before applying the arsenical preparation or before adjusting the rubber dam, it is best to break down all overhanging edges of enamel and carefully remove or wash out with a non-irritating antiseptic solution any food-stuffs or debris which may be in the cavity. Food-stuffs contain albumin, and if such is in the cavity of the tooth when the arsenical preparation is applied, the arsenic trioxid will act upon the albumin, forming the arsenic albuminate, and thereby a certain amount of the agent is neutralized or becomes inert. As much of the carious dentin should also be removed as can be done without producing pain, for the application should be made to a sensitive spot in the cavity. It is never necessary to have an exposure of the pulp; and in case an exposure exists, it is best to apply the preparation to the dentin immediately over the pulp, rather than directly to the organ itself. The preparation should be covered with cotton or small metallic or paper disc to prevent pressure and also to prevent the phosphoric acid of the cement from coming in contact with the ingredients of the paste.

There are at least four factors which govern the length of time an arsenical application should remain sealed within a tooth, viz.:

(1) The age and general condition of the patient.
(2) The general condition of the pulp itself.
(3) The amount and condition of the dentin intervening between the pulp proper and the application of the paste.
(4) The climate or season of the year, strange as it may seem, influences the action of arsenic trioxid.

Taking into consideration these various factors, the arsenical preparation should remain in the cavity from two to six days. At the second sitting the rubber dam should be adjusted, the teeth included sterilized, and the cement and paste removed, after which every surface of the cavity should be freshened with a large round bur. This not only insures the thorough removal of the arsenical paste, which, should a portion remain, is liable to produce pericemental inflammation, but it also *mechanically* sterilizes the cavity by removing the carious and infected dentin. This is important and is an aid in *maintaining asepsis* in the removal of the pulp. In the author's judgment this is much better practice than to depend upon a solution of dialysed iron to neutralize the arsenic trioxid.

The pulp chamber can now be opened into and the pulp removed, observing practically the same details as explained under the anesthetization method. Oftentimes in the initial opening into the pulp chamber, and sometimes on entering the canal, after the application of arsenic trioxid, the patient will experience some pain; but by gently working the broach up the side of the root, very little, if any, pain need be produced in removing the pulp, provided, of course, the tissue is devitalized. However, should pain be experienced, it is best to seal phenol or the modified phenol solution in the cavity in contact with the tissue from three to six days, when it can be removed without pain.

In connection with the *preservation of the color of the tooth*, under the anesthetization method the author stated his objection to the use of hydrogen dioxid for removing the blood from the cavity and canal. It is necessary here also to refer briefly to a well-established practice of treating teeth after the pulps have been devitalized. It is the practice of many dentists, after removing the arsenical dressing, to flood the cavity with a solution of dialysed iron, after which the pulp chamber is opened into, usually producing some hemorrhage; then without any especial effort being made to remove the dialysed iron or blood, tannic acid in some form is sealed in contact with the pulp for a week or ten days, thinking it advantageous by this means to constringe and toughen the tissue before attempting its removal. Let us consider the rationalism of such treatment. The pulp tissue in all large canals is sufficiently tough to be removed in its entirety, and it must be disorganized or removed piecemeal in small canals, whether it has been previously constringed or not. Hence, there is no advantage in using tannic acid and there is a serious objection. If those who follow this practice are observing, they will notice that after removing the tannic acid dressing, the pulp tissue is dark in appearance. They will also observe that many teeth thus treated subsequently discolor. The cause for this is found in the fact that tannic acid and iron, in any form, are chemically incompatible, the resulting compound being *iron tannate*, one of the most insoluble substances known to chemistry. In the presence of moisture a form of ink is produced which is a great staining agent for dentin, and one that is almost impossible to remove by any known process of bleaching.

As has been stated elsewhere in this chapter, there are cases where, for want of time or other reasons, the pulp can be removed to advantage by devitalization; however, when this method is followed tannic acid should *not* be used, and every trace of dialysed iron (if used at all, and it is unnecessary to use it) and blood should be removed with alcohol

or water. In those cases where we are certain that the pulp is all removed and where the canals can be thoroughly dried, the root filling can be inserted at the same sitting, provided there are no symptoms of pericementitis in the apical area. There are many good reasons, however, for not filling the root at this time, some of which have been considered under the anesthetization method.

Complications.—In our discussion thus far of the methods of removing pulps from teeth, we have considered only favorable cases, selecting the method best adapted to the case at hand. There are many instances, however, where it is difficult to remove the pulp by either the anesthetization or devitalization method, at least until the tooth is placed in a more favorable condition. Oftentimes in approximating cavities the decay in one or both teeth has extended far beneath the gum, the rough gingival margin of the cavity acting as a slight irritant by which the gum tissue is stimulated, causing it to proliferate until it fills a portion of, and in some instances the entire, cavity. In such cases the first consideration is to dispose of the hypertrophied tissue. Where the gum fills only a portion of the cavity and the pulp of the tooth is not causing trouble, the cavity should first be enlarged and washed with a warm antiseptic solution, after which it should be dried as well as possible and packed with warm gutta-percha. But in those cases where the gum tissue occupies the entire cavity, and especially where the tooth is aching, it should be removed at once. Hypertrophied gum tissue is quite tough and fibrous, and if it is elevated or pushed back by means of a flat instrument, it will usually be found that the attachment at the gingival margin is small and can easily be severed by employing gum scissors or a lancet, previously dipped in phenol. It is best not to tell the patient what you are going to do, for scarcely any pain will be experienced. The hemorrhage in these cases is usually profuse, but can readily be stopped by cauterization with 95 per cent phenol, a 50 per cent solution of phenolsulphonic acid, or a 15 per cent solution of trichloracetic acid. The blood should now be thoroughly removed, the cavity dried, moistened with eucalyptol and packed with gutta-percha, letting it extend buccally and lingually to fill the interproximal space. The gutta-percha can be removed from the interior of the cavity with a heated flat instrument. Quite often the most practical way of adjusting the rubber dam in these cases is to place the clamp on the tooth posterior to the one thus packed, having a single hole in the dam include both teeth. The packing, if properly placed, will prevent leakage. The pulp can now be removed by the method which the operator deems the most feasible.

There is one instance in the removal of pulps from teeth, where students particularly are liable to make a serious mistake if they are not extremely careful. That is in cases where, in large occlusal cavities, especially in lower first molars of children, the pulp has died and the decay has extended through the bifurcation of the roots, leaving rough edges which continually irritate the tissue, causing it to proliferate and ultimately fill the cavity. To carelessly force the anesthetizing solution into such a cavity, where the pulp in the canals is putrescent, would be the means of causing an acute alveolar abscess. The application of arsenic trioxid would mean the loss of at least one tooth, perhaps one or two on either side of the one to which the application was made, with a portion of the alveolar process.

Before applying either the anesthetizing or devitalizing agent a correct diagnosis should be made; we should ascertain definitely the kind of tissue in the cavity. With a little experience this is usually a simple matter. The history of the case as related by the patient will often serve as a guide. Pulp tissue is generally more sensitive than gum tissue, and when slightly pricked with a sharp instrument bleeds more profusely. If the tissue proves to be hypertrophied gum tissue it can be disposed of in the usual manner, the puncture closed temporarily with cement or gutta-percha and the tooth treated as the condition necessitates. When this cannot be accomplished, it is necessary to extract the tooth. In cases where the tissue is hypertrophied pulp tissue it will generally be found unusually resistant to both cocain hydrochlorid and arsenic trioxid, and it is sometimes necessary to resort to actual cautery by employing strong escharotics, such as pure phenolsulphonic acid, which is not as painful here as would naturally be supposed, or to the administration of such general anesthetics as nitrous oxid in order to painlessly remove the tissue.

Quite frequently we find cases where it seems almost impossible to force the anesthetizing solution through the dentin and into the pulp, and when arsenic trioxid is applied it has little or no effect. In these cases we can suspect that the pulp has receded because of some slight but continued external irritation and the space filled in with secondary dentin, the tubuli of which are irregular and do not run at right angles to the base upon which they rest, as in the normal dentin. This condition is more often found in elderly patients. As a result also of external irritation, pulp nodules, calcific bodies of various shapes, are sometimes found within the pulp itself. Many times in removing the pulp in these cases, the most painless and best results are obtained only by a combination of both the anesthetization and de-

vitalization methods; for the removal of these pulp nodules is often a difficult procedure. After we have used cocain hydrochlorid and pressure or previously applied arsenic trioxid and anesthetized or devitalized a portion of the pulp, we may be able to reach the pulp nodule or nodules without producing pain. But frequently these calcific bodies are agglutinated and close the mouth of the canal; especially is this condition found in molar teeth. The pulp tissue immediately under the nodule is extremely sensitive. In such a case the anesthetizing solution could not be forced into the canal without first removing the obstruction, and arsenic trioxid, if applied, would have no effect. These are cases which require much perseverance and patience on the part of both patient and operator. The nodule can sometimes be loosened by gently working around it with an exploring or other suitable instrument. The author has met with success by taking a small round bur and drilling past the nodule, care being taken not to puncture the root, then with the engine running rapidly the nodule is tapped and dislodged. When the obstruction in the pulp chamber and canals is removed the remaining tissue can be anesthetized or devitalized in the usual manner. If the devitalization method is employed the arsenical preparation can be placed over the mouth of the canal with safety; but it is never advisable to place the preparation down in the canal.

Arsenical Poisoning.—Before closing this chapter it may be well to consider the treatment of local poisoning by arsenic trioxid. However, when such treatment is necessary it is due to carelessness on the part of the dentist or the patient, or both. It is never necessary to tell the patient what drug or remedy has been used in the treatment of teeth, many times it is advisable not to do so; but whenever an agent as destructive as arsenic trioxid is sealed within a tooth, the patient should be thoroughly impressed with the importance of keeping an appointment, and of returning before the appointed time should any untoward symptoms develop. The patient should also be informed that the teeth thus treated might ache for a few hours, as they sometimes do, even when cocain is a constituent of the arsenical preparation; but that the aching will be of short duration. In case, however, the tooth or gum becomes sore, they should be instructed to return at once.

In those cases where the arsenical preparation is not hermetically sealed within the tooth and some of it gets on the gum tissue, remaining only long enough to cause devitalization, all that is necessary is to first wash the part with an antiseptic solution, and then mechanically pick off the dead or sloughed tissue with sterile pliers until bleeding is

produced, if this is possible, after which the part should be *disinfected* and the tissue *stimulated*. To disinfect the part, any good disinfectant can be used. Nothing is better here than the official 3 per cent solution of hydrogen dioxid. As a means of stimulating the cells, iodin compounds are useful. The Pharmacopeia recognizes a compound solution of iodin (5 per cent) which can be applied by first drying the part. After removing the dead tissue and disinfecting, the author prefers applying a paste made of europhen and oil of cloves. A prescription should also be written for an antiseptic mouth wash with which the patient should keep the mouth as clean as possible. The treatment can be repeated as often as the case necessitates; usually one or two treatments will suffice.

In those severe cases where the arsenic trioxid has penetrated to and devitalized the process as well as the gum, the first treatment is surgical. After washing with an antiseptic solution, the affected process should be removed with a suitable bur in the engine. It may be necessary in extensive cases to extract the tooth, after which the treatment is practically the same as has been outlined above. Sometimes there is pain following the surgical removal of the affected process. In this case orthoform can be added to the paste of europhen and oil of cloves. The case should be watched closely and the stimulating treatment kept up until the part has healed. The tissue in the interproximal space will never be fully reproduced, and will always be a source of more or less annoyance.

It will be noted that in discussing the treatment of local arsenical poisoning, no mention has been made of dialysed iron. The practice of applying this agent to the affected part is both useless and wrong.

In closing this chapter the author desires to emphasize what was stated in the beginning, that it is the plain duty of every practitioner to save the pulps of teeth in all cases where it can be done with any reasonable degree of success; yet experience and observation will soon show the folly of attempting to save a pulp that has been irritated for any great length of time, and will prove also that in these cases, the safest practice is to remove the pulp and subsequently fill the canals, notwithstanding the difficulty often attending the performance of this operation.

CHAPTER XX.

THE TREATMENT OF ORDINARY PERICEMENTITIS.

BY J. P. BUCKLEY, PH. G., D. D. S.

General Considerations.—It is not the intention to introduce in these chapters needless pathologic facts, yet in the treatment of pericementitis it is important to remember that the pericemental membrane is very vascular and well supplied with nerves; that it is enclosed within bony walls, and, therefore, when inflammation exists in the tissue the membrane becomes thickened, forcing the tooth from its socket. This elongation of the affected tooth is one of the chief symptoms of true pericementitis.

Before discussing the therapeutics of pericementitis, I desire to indelibly impress upon the mind of the reader the fact that this condition is too frequently produced by carelessness on the part of dentists. It is not always possible to successfully perform dental operations without irritating the susceptible pericemental membrane; however, much of the trouble can be avoided if judgment is exercised and proper precautions are taken in treating teeth.

There are at least two classes of irritants by which ordinary pericementitis is produced, viz.:

(1) Drug irritants.

(2) Mechanical irritants.

The inflammation of the pericemental membrane caused from drug or mechanical irritants, will be called *ordinary pericementitis* in this chapter, in order to differentiate it from *septic pericementitis* —a condition produced by pathogenic bacteria, poisonous ptomains, and irritating gases, which have escaped from a putrescent root canal.

Drug Irritants.—There are many circumstances and conditions which influence the action of drugs upon different individuals and upon the same individual under different conditions. We find cases occasionally where pulps have been removed by pressure anesthesia, and where, seemingly at least, every precaution was taken in sterilizing the dentin, selecting a sterile anesthetizing solution and in applying the pressure; yet severe apical pericementitis follows. This may or may not be due to the drugs used in performing the operation. There are cases, too, where the pericemental membrane becomes

highly inflamed and extremely responsive from the action of arsenic trioxid, even when the drug was properly sealed within the tooth only a short time. These are conditions over which the operator seems to have no control; however, drugs are often used injudiciously. In the preceding chapter it was stated that an anodyne treatment was indicated after the mechanical or surgical removal of the pulp. Therefore, care should be taken to select drugs for this purpose which produce a soothing and not an irritating effect. There are some instances in dental practice where we desire to irritate and thereby stimulate the pericemental membrane; but this should be avoided here. Judgment should also be exercised in sealing in anodyne remedies, such as phenol, oil of cloves, etc., in the canals, especially in bicuspid and molar teeth, for should the temporary filling be left too full and the remedy forced through the apex by the closing of the jaws, even these agents cease to be anodynes and become irritants. Whether phenol, oil of cloves, and similar drugs or remedies are anodynes or irritants, depends largely, then, on where and how they are used.

In filling root canals it is the practice of many dentists—the author among the number—to moisten the canals with *eucalyptol* before introducing chloro-percha and the gutta-percha cone. Care must be taken here to use eucalyptol and not oil of eucalyptus, unless it be the refined product. Commercial oil of eucalyptus has been the cause of many cases of apical pericementitis following the most careful filling of root canals. The eucalyptus tree produces a volatile oil which contains three constituents, each distilling over at different temperatures; the first product thus obtained is eucalyptol, hence the most volatile constituent of oil of eucalyptus and the one which is the solvent for gutta-percha. While eucalyptol is a slight irritant, it is not nearly so irritating as oil of eucalyptus. The irritating property of eucalyptol can be modified and its antiseptic value increased by adding menthol and thymol in the following proportion:

℞—Menthol,	gr. ij	
Thymol,	gr. iij	
Eucalyptol,	f. ʒ j	—M.
Sig.—Use as directed.		

This remedy is equally as good a solvent for gutta-percha as is eucalyptol alone; and will be called *modified eucalyptol* in the following chapters.

Mechanical Irritants.—The pericemental membrane is frequently, I might add too frequently, irritated by mechanical irritants, such as root canal fillings, ill-fitting partial plates, crowns and bridges, mallet-

ing, regulating, faulty occlusion, salivary and serumal calculus, etc. There is perhaps more pericementitis produced by root canal fillings than by any other mechanical irritant. In filling root canals we should be absolutely certain that the canal is *aseptic*. If there be any doubt as to this, the operation should be deferred. In a subsequent chapter the author will discuss in detail the technique of filling root canals; however it is well to mention here that care should be taken in filling all large canals so that the filling material may not be forced through the apex of the root; especially should we be careful in filling the canals of teeth after having treated an alveolar abscess. In these cases we must not expect the patient to flinch in filling the root, for there is no live tissue at the immediate end. The apex has been enlarged and it is very easy to force the filling material through into the space where the tissue has been destroyed. When granulation fills this space and the newly formed tissue comes in contact with the foreign material, the result will be a "lame tooth," which means pericemental trouble.

A frequent cause of pericementitis is the presence of microorganisms, which have been introduced through the failure to establish and maintain sepsis in removing the pulp tissue; or pathogenic bacteria, poisonous ptomains and irritating gases that have escaped into the apical area from a putrescent root canal. This particular kind of pericementitis is known as *septic pericementitis*, and is closely associated with incipient abscess. The nature of the irritants and the treatment of the condition will be fully considered in a subsequent chapter.

Therapeutics.—The first step in the treatment of ordinary pericementitis is to adopt the surgical principle of ascertaining the cause and removing or correcting it, if at all possible. In the earlier stages of pericemental inflammation, it is not always an easy matter to ascertain the *true cause* of the disturbance. For instance, in those cases following the removal of the pulp tissue, it is difficult to know whether the cause is the root filling, the medicine used in the treatment, or whether we failed to establish and maintain asepsis in performing the operation. The author is inclined to believe that it is more frequently the latter than most operators are willing to admit; for certain it is that the more nearly we approach *absolute asepsis* in these operations, the less pericemental trouble we will have. The teeth thus affected are extremely sore, and any remedy can be used in the treatment that will give immediate relief. This is what the patient most desires, and, too often it appears, it is that which the dentist fails to give. Both local and general remedies can be employed. General remedies are more valuable in the treatment of septic pericementitis. If they are

used at all in treating ordinary pericementitis, they should be used only in cases where the patient is nervous and has lost considerable sleep. For immediate relief we must depend largely upon the local application of drugs and remedies. In those cases following the removal of the pulp by either the anesthetization or devitalization method, and where the canals have not been filled, the pain can be relieved almost instantly by the following method: Adjust the rubber dam. If it is necessary to use a clamp, it should be placed on the tooth posterior to the one affected. Sterilize the teeth included in the dam and remove the dressing from the canals. Dehydrate the tooth structure with absolute alcohol. Then wrap cotton loosely around a smooth, sterile broach, dip in oil of cloves or eugenol, and carefully work in each canal. Remove the broach, leaving the cotton. Heat should now be applied to the remedy by means of a hot air instrument or a chip-blower until the cotton becomes dry. Repeat this process several times, after which the same remedy should be carefully sealed within the canal. In doing this, we not only get the benefit of the heat, which is valuable; but the eugenol, the constituent of cloves, is driven into the tooth structure, producing a profound anodyne effect upon the sensitive membrane. The author has succeeded in giving immediate relief by this method of treatment when many others have failed. Grinding the cusps of the tooth where it can be done without injury is advisable; a counterirritant can be applied to the gum and the patient dismissed for several days. It is scarcely necessary to instruct the patient to favor the tooth.

In the treatment of pericementitis following the filling of the root, having every reason for believing that the canals were aseptic, one of the last things the author would suggest doing would be to attempt to remove the root filling. Usually this only serves to further aggravate the condition. These cases can best be treated by counterirritation and general remedies. By counterirritation is meant the application of an irritant to some normal part of the body for the purpose of influencing favorably some other part, usually deep-seated, which is diseased. This irritant is generally applied to the gum over the affected tooth. Capsicum plasters, black mustard papers, cantharidal collodion, all official preparations, are valuable; or the following liniments, which are more generally used, give much relief:

℞—Menthol, gr. xx
Chloroformi, f. ℥ j
Tincturæ aconiti, q. s. ad, f. ℥ j —M.
Sig.—Dry the gum and apply freely over the affected tooth for several minutes.

℞—Tincturæ aconiti, f.℥ ij
Tincturæ iodi,
Chloroformi, āā f.℥ j —M.
Sig.—Make one application to the gum as above.

℞—Liquoris iodi compositæ, f.℥ j
Sig.—Use as above.

Inasmuch as tincture of aconite is an important ingredient in many liniments used in the local treatment of pericementitis and facial neuralgia, it is well to remember that the United States Pharmacopeia of 1900 reduced the strength of this preparation from 35 per cent to 10 per cent. Therefore the new tincture can be employed more freely in these cases without danger of poisoning.

As a remedy to be applied by the patient at home, a split raisin, soaked in hot water, and on which is dusted red pepper, can be held on the gum over the affected tooth. A very efficacious remedy is to direct hot water with some force on the part, beginning with warm water and increasing the heat gradually until it is nearly boiling. This must be kept up until we get the full benefit of the heat and resolution promoted. Another good remedy to have the patient employ, is the hot foot bath. The value of this remedy, like the application of hot water to the gums, depends largely upon the manner in which it is done. A deep foot-bath tub should be used and the temperature of the water gradually increased until it is as hot as can be borne. This should be continued from twenty to thirty minutes.

There are many other drugs and remedies which can be employed in the local treatment of this condition. Those which have been mentioned here the author has found valuable in his practice. It is far better to have a practical knowledge of a few remedies than a superficial knowledge of many. The general remedies to be administered in the treatment of ordinary pericementitis, if found necessary, will be discussed under the treatment of septic pericementitis and incipient abscess in a subsequent chapter.

CHAPTER XXI.

THE CHEMISTRY OF PULP DECOMPOSITION.

BY J. P. BUCKLEY, PH. G., D. D. S.

General Considerations.—The subject of pulp decomposition is one that has commanded the attention of many investigators in our profession, and at the present time the conclusions as to the chemistry of the process are by no means uniform. While this fact is to be regretted, it must be remembered here that there are many difficulties presenting themselves to the student who attempts to study this complicated process from the chemical viewpoint, either for the purpose of outlining a *rational* treatment for the correction of the putrescent condition, or for the purpose of solving the knotty problems of the discoloration of tooth structure from this source. Until we comprehend more fully the nature of the chemical reactions taking place in the splitting up of the complex bodies of dead pulp tissue and have a more definite knowledge of the intermediate and end-products thus produced, the application of drugs and remedies for the correction of the putrescent condition and for the restoration of the color of the tooth structure can never be placed upon a rational basis, but must be empirical, as it has been in the past. This is not in accordance with the tendency of the present time. There is a strenuous effort being made in both medicine and dentistry, to rid the professions of much of the empiricism of the past and to place the treatment of all diseased conditions upon a rational basis. With this end in view the author desires in this chapter to direct the reader's attention to the chemistry of pulp decomposition.

It is essential in studying the chemistry of this process to first ascertain the chemical constituents of the original pulp tissue. So far as chemists have been able to determine, practically all of the elements are present in the pulp tissue and its vascular supply that are found in any other animal tissue. These elements are arranged in different compounds which make up the pulp tissue, the proportion of which varies from other tissues, and this, no doubt, accounts for the histologic difference between this and many of the other tissues of the body. However, from a general chemical examination of the pulp tissue we find it analogous, or nearly so, to all other animal tissue. This suggests

at once the necessity for the student's familiarity with the general composition of animal tissue, which will now be considered.

Chemical Composition of Animal Tissue.—There are at the present time about seventy-six elements known to chemistry; but of this number less than seventeen unite, in varying proportions, to form the chemical basis of the animal body. In fact, six elements are about all with which we are concerned in the study of the decomposition of the pulp tissue. These elements are carbon, C; hydrogen, H; oxygen, O; nitrogen, N; sulphur, S; and iron, Fe.

For convenience in study, the various substances found in animal tissue are divided into two general classes, the classification being based upon the presence or absence of the element *nitrogen*, and are accordingly called nitrogenous and non-nitrogenous substances.

Nitrogenous Substances.—We are taught by physiologists that nitrogenous organic bodies take the chief part in forming the solid tissues, and to an extent are also found in the fluids of the body. *Proteid*, or *albuminous*, substances are the principal nitrogenous compounds, and one or more enter as an essential part into the formation of all living tissue. The elements which constitute the proteid molecule are carbon, hydrogen, oxygen, nitrogen and a small amount of sulphur. Iron and phosphorus are known to exist in the molecule of some proteid bodies. While some chemists have attempted to construct a formula for the molecule, none has been accepted as correct, the opinions of investigators being so varied. To the casual observer it may seem strange that a molecule consisting largely, as it does, of carbon, hydrogen, oxygen and nitrogen, should have these four simple elements so arranged as to baffle chemists in their effort to construct a rational formula. But this difficulty is readily explained by the fact that of all the elements none differ more widely from each other in their physical and chemical properties than these four. Carbon is a solid substance which exists in nature in three forms: Charcoal, graphite, and diamond, and can scarcely be fused or volatilized. Hydrogen, oxygen, and nitrogen are colorless gases which cannot be solidified by any known means and can be converted into liquids only with difficulty. The three gases also differ in their chemical activity. Hydrogen is combustible; oxygen will not burn, but will support combustion; while nitrogen is perfectly indifferent. Fortunately, too, for nature, in her effort to arrange these elements into a complex molecule, the valency of each differs. Hydrogen is univalent, oxygen bivalent, nitrogen trivalent, and carbon quadrivalent, generally considered. Carbon atoms have also, to a higher degree than the atoms of any other

element, the power of combining with each other by means of a portion of the affinity possessed by each atom, thereby increasing the possibilities of the formation of complex compounds. Thus many atoms of the same element occur in each molecule, which, together with the fact that one of the elements is that peculiar, undecided and indifferent element, nitrogen, aids materially in explaining the reason for the instability of the proteid molecule, or the ease with which under certain conditions it is decomposed.

In order that the reader may be able to follow a theory which the author will advance in a subsequent chapter on the discoloration problem, it is well to remember here that the relative amount of nitrogen compared with sulphur found in the proteid molecule is 15 per cent of the former to 0.3 per cent of the latter.

Non-nitrogenous Substances.—The non-nitrogenous substances consist of *carbohydrates* and *fats*. Several classes of carbohydrates are known to exist, all of which are much less complex than the proteid group; and the arrangement of the atoms in the molecule is much better understood. The carbohydrate molecule is composed of three elements—carbon, hydrogen and oxygen. There are always six (or a multiple of six) atoms of carbon in the molecule, while the hydrogen and oxygen exist in the proportion to form water. These compounds readily undergo the process of fermentation.

Human fats are principally mixtures of palmitin, $C_3H_5(C_{16}H_{31}O)_3O_3$; stearin, $C_3H_5(C_{18}H_{35}O)_3O_3$; and a small amount of olein, $C_3H_5(C_{18}H_{33}O)_3O_3$. As shown by the formula of these compounds, the molecules of each also consist of carbon, hydrogen and oxygen. The proportion of these elements varies in the different compounds. That fats are decomposed or saponified by alkalies, or ferment in an alkaline medium, should be remembered, both in the treatment and the bleaching of teeth.

Thus we have every reason for believing that the pulp tissue, like nearly all living organic tissue, is composed of *proteids*, *carbohydrates*, and *fats;* and on this hypothesis the author will endeavor to ascertain the intermediate and end-products resulting from the decomposition of this tissue when death occurs. Before doing so, however, it may be well that the reader fully understand what is meant by the terms *fermentation* and *putrefaction*. These terms are applied to peculiar kinds of decomposition by which the molecules of certain organic substances are broken up into simpler compounds. The difference between the terms is that fermentation is applied to the decomposition of those substances which belong to the group of carbohydrates, while putre-

faction is applied to the decomposition of those substances which properly belong to the proteid group and are classified as nitrogenous substances.

Pulp Decomposition.—The decomposition of the pulp tissue is essentially an analytic process which takes place gradually. Conditions being favorable, the germs present first act upon the complex and unstable substances composing the original tissue, splitting them up into less complex compounds, many of which are capable of further analysis; and the process goes on until simple and well-known compounds are the result. For convenience in studying this subject the compounds resulting from this analytic process will be arbitrarily divided into two classes, *intermediate* and *end-products;* and it will be seen that it is largely the products of putrefaction rather than of fermentation with which we have to contend in the correction of the putrescent condition.

Intermediate Products.—The intermediate products depend to an extent upon the character of the microorganisms in the tissue, but it is safe to say that certain *ptomains* and *amido-acids* are formed.

(1) *Ptomains.*—Ptomains are nitrogenous compounds of organic origin, having the reaction and basic property of alkalies. By some authorities they are called *animal alkaloids*, to distinguish them from a similar group of organic bases known as *vegetable alkaloids.*

Among the ptomains liable to be produced are putrescin, $C_4H_{12}N_2$, cadaverin and neuridin, $C_5H_{14}N_2$, the last two named being isomeric as shown by the formula. One of these ptomains, neuridin, is non-infectious; therefore its presence is of little importance other than to know that it is a nitrogenous base from which ammonia, NH_3, or derivations of ammonia, is evolved by further putrefaction. Still, according to Vaughan and Novy, while pure neuridin is non-poisonous, it possesses a toxic property as long as it is contaminated with other poisonous products of putrefaction. This holds true for all non-poisonous bases. Insofar as the correction of the putrescent condition is concerned, putrescin and cadaverin are perhaps the most important intermediate products known to be formed in the splitting up of the proteid molecule. Like neuridin, they are basic nitrogenous compounds, capable of undergoing further putrefaction, evolving ammonia or derivatives; but unlike this compound, while they were at first regarded as physiologically inactive, both of these bases have been proved by Scheurlen, Grawitz and others to be capable of producing inflammation and suppuration. Therefore if by instrumentation or other-

wise they are forced through the apices of the roots, septic pericementitis or perhaps on acute alveolar abscess will result.

(2) *Amido-acids.*—Amido-acids are acids in which hydrogen has been replaced by the univalent radical, NH_2. Among the amido-acids formed in pulp decomposition, in all probability, are tyrosin, $C_6H_4OHC_2H_3(NH_2)CO_2H$, and leucin, $C_5H_{10}NH_2CO_2H$. These substances, wherever found, have practically the same physiologic properties and pathologic significance. They occur in the intestine during the digestion of proteids, and leucin is found in almost every cell of the animal body.* Pathologically, they are found in atheromatous cysts, in pus, abscesses, etc., as well as in a putrescent root canal. It is well to remember here that these intermediate products are also nitrogenous compounds from which ammonia, or derivatives of ammonia, is evolved by further putrefaction, and that *fats are one of the end-products.*

End-products.—The chief end-products of pulp decomposition, as has been known for a long time, are water, H_2O; carbon dioxid, CO_2; acetic acid, $HC_2H_3O_2$; ammonia, NH_3; hydrogen sulphid, H_2S; and a semi-putrid substance consisting largely of fats, depending upon the extent to which the putrefactive process has progressed.

Simultaneously with the decomposition of the pulp tissue proper, the dentinal fibrillæ are broken up, as is also the hemoglobin and other constituents of the blood; and the tubuli as well as the pulp chamber and root canals are filled with the intermediate and end-products of the decomposition.

The principal gases generated by the putrefaction of the proteid substances, the main constituent of the original pulp tissue, are *ammonia* and *hydrogen sulphid.* Now, it is interesting and important to know which of these two gases is evolved in the greater quantity. This is easily estimated when we recall the relative amount of nitrogen and sulphur found in the proteid molecule. As previously stated, there is approximately 15 per cent of the nitrogen to 0.3 per cent of sulphur. Hence, ammonia is evolved in the greater quantity. It is quite evident, then, that hydrogen sulphid is not generated in a putrescent root canal in such quantities as has been so generally supposed; yet this compound is a constant end-product and is important, because it is an *acid* gas, with a disagreeable odor, having local irritating properties; and also because of the part it plays in the discoloration of the tooth structure. The author desires to state here, however, that while he realizes hydrogen sulphid is an active chemical agent, in his opinion it has been

*Simon's "Manual of Chemistry.

greatly over-estimated in the rôle it assumes in the discoloration of teeth from pulp decomposition as will be shown in a subsequent chapter.

In our study thus far of the chemistry of the complicated process of pulp decomposition, we have learned something of the nature of the intermediate and end-products resulting therefrom, and now it is possible for us to select, with some intelligence, drugs and remedies which will not only destroy bacteria, but will also act chemically upon these noxious products, converting them into non-infectious and non-toxic compounds.

CHAPTER XXII.

THE TREATMENT OF PUTRESCENT PULPS—ACUTE AND CHRONIC ALVEOLAR ABSCESS, WITH COMPLICATIONS; AND THE FILLING OF ROOT CANALS.

BY J. P. BUCKLEY, PH. G., D. D. S.

General Considerations.—The treatment of putrescent pulps and their sequelæ in the past, has, to a great extent, been purely empirical. The reason for this can be found in the apparent lack of interest which generally has been shown in the chemistry of pulp decomposition. A knowledge of the changes wrought in the splitting up of the complex bodies of the dental pulp by microorganisms is of vital interest to every practicing dentist; and every student should therefore familiarize himself with this important subject. The only method by which drugs and remedies can be scientifically applied to the treatment of the conditions under consideration is to have a definite knowledge of the intermediate and end-products resulting from the putrefactive process as outlined in the preceding chapter.

Every practitioner of dentistry knew from sad, past experience that in the process of pulp decomposition, some kind of mephitic gases were evolved which if confined would produce severe pathologic disturbances; but just what the gases were and how the unfavorable conditions were brought about we were left to conjecture. From our study of the chemistry of pulp decomposition we have every reason for believing that the main gases produced are *ammonia* and *hydrogen sulphid*. When these gases are generated and cannot readily escape through a cavity, pressure is produced, thereby forcing the poisonous ptomains through the apices of the roots into the surrounding tissue from which infection, septic pericementitis and in many instances an alveolar abscess result.

There has been much discussion in the dental literature of the past in regard to the penetrating or non-penetrating power of coagulating agents in putrescent root canals. It is true, as claimed by some authorities, that such drugs as phenol, creosote, solutions of zinc chlorid, etc., are contraindicated in the treatment of putrescent pulps, but not

because they possess the coagulating property; for when the dental pulp is undergoing or has undergone the process of decomposition, the proteid constituents or coagulable substances have lost their former identity, and new compounds with entirely different properties have been formed. In selecting drugs to be used in the treatment of this condition, the author will therefore eliminate the question of coagulation and will select drugs, which if properly used, will unite chemically with the intermediate and end-products of decomposition, converting them into odorless and non-infectious compounds, as well as destroy germ life. In this connection it should be remembered that the putrescent condition has been brought about through the agency of microorganisms by a gradual analytic process, and among the products formed which must be considered in the treatment are *hydrogen sulphid*, the *poisonous ptomains* (putrescin and cadaverin), and *ammonia* or derivatives, the latter gas being evolved from the further putrefaction of the last named compounds, or compounds of similar composition. It is well to remember also that *fats* or fatty acids are a class of end-products resulting from the putrefaction of proteid substances.

The main gases formed, then, are ammonia and hydrogen sulphid. Now it will be necessary to dispose of these gases in order to hermetically seal the cavity, an object the accomplishment of which is much desired in the treatment of these cases; for by so doing we prevent the oral fluids from contaminating the medicine within the tooth, the medicine from escaping into the patient's mouth, and the tooth from changing color during the time of treatment.

It has been known for some time that *formaldehyd* (CH_2O), a gas which occurs in commerce in a thirty-seven per cent aqueous solution and which solution is recognized by the United States Pharmacopeia of 1900 under the name of liquor formaldehyd, or formalin, will unite with ammonia, producing urotropin, a solid, as $6CH_2O+4NH_3=(CH_2)_6N_4+6H_2O$.

Formaldehyd unites also with hydrogen sulphid, forming, in the author's opinion, methyl alcohol, a liquid, and sulphur, a solid, as $2CH_2O+2H_2S=2CH_3OH+S_2$.

It is stated on good authority that this same gas, formaldehyd, united with basic ptomains, forms inodorous compounds. By the use of formaldehyd, then the *irritating gases* and *poisonous liquids* (largely ptomains) can be changed chemically into *non-irritating* and *non-poisonous liquids* and *solids*. The official solution of formaldehyd, however, is too irritating for general use; therefore, inasmuch as fats

result from pulp decomposition and are present as such in a putrescent root canal, the author selected *cresol* as an agent with which to dilute the official solution and thereby modify the irritating action of formaldehyd. Cresol is now also recognized by the United States Pharmacopeia of 1900 under this name. Formerly the product was commercially called *tricresol*. This agent has a tendency to darken when exposed to light. It is recommended that a clear solution be obtained and then kept in an amber colored bottle.

Liquor formaldehyd can be diluted with such other agents as phenol, or creosote, if, in the latter instance, a small amount of alcohol is added to clear the solution. Cresol, however, is recommended for four principal reasons:

1. It is miscible with the liquor formaldehyd in all proportions, thus making, without the addition of alcohol, a good pharmacal product from which formaldehyd gas is constantly generated.

2. It is a good disinfectant, much more powerful than phenol.

3. It possesses an anodyne property which modifies the irritating action of formaldehyd.

4. It acts chemically upon the fatty compounds thereby disposing to advantage of these substances.

Treatment.—In the successful treatment of the conditions under consideration there are three important factors which must be accomplished:

1. Establish asepsis.

2. Prevent recurring sepsis.

3. Preserve or restore the color of the tooth.

I. *Putrescent Pulps.*—In calling the attention of the reader to a method of treating this condition, which has proved very successful in the author's practice, I desire to emphasize the necessity for observing the details of the method. Our first duty here, as in all treatment cases, is to make a correct diagnosis, after which the rubber dam should be adjusted in every case where it is possible to do so, and all the teeth included, sterilized. For this purpose either a ten per cent solution of formaldehyd to which a small amount of borax has been added, or a 1–500 solution of mercury bichlorid in cinnamon water can be used. After using one of these solutions the teeth are bathed in alcohol, when, with a suitable round bur, the pulp chamber is freely opened, exposing all of the canals, but making no attempt to remove the contents therein at this sitting. Now, on a small pledget of cotton the following remedy is placed in the pulp chamber and over the mouth of each canal.

Original Formula.

℞—Cresolis,
Liquoris formaldehydi, āā f℥j—M.
Sig.—Use as directed.

For convenience this remedy will be called *formocresol*. It is always best to seal the cavity with a quick-setting cement, for the remedy should be *hermetically sealed and pressure must be avoided*. To prevent the cement from filling the entire cavity and also to facilitate its subsequent removal, metallic or paper discs or even cotton can be placed over the remedy, filling most of the cavity, when only a veneer of cement is necessary to hermetically seal it. This dressing can remain until you wish to have the patient return for a subsequent sitting. The author prefers to leave it about two or three days. However, it can be safely changed the following day, and no harm follow if it remains a week or more. At the second sitting, the rubber dam should be adjusted, the teeth included sterilized, and the dressing removed, after which the canals should be mechanically cleaned with a proper broach, exercising the same judgment here in the selection of the broach as was emphasized in a previous chapter. If there be any odor in the canals characteristic of putrescence, or if effervescence is produced by testing with a solution of hydrogen dioxid, the canals should be dehydrated with alcohol and warm air as thoroughly as possible and the original formula again placed on cotton, this time loosely in each canal, and the cavity hermetically sealed.

In those cases, where, at the second sitting, there is no evidence of putrescence, which will be found to be the condition generally if the first treatment is properly employed, the original formula can be modified and used. It is not necessary or advisable, however, to keep a modified formula prepared. It can readily be made at the time by taking two minims of the original formula on a clean watch crystal, and adding to this one or two minims of cresol as thought best by the operator at the time. This dressing should remain for at least three days, by which time the remedy will have sterilized the entire tubular structure of the dentin, thus *establishing asepsis*. All that is necessary now to *prevent recurring sepsis* is to thoroughly fill the canals. This remedy will not discolor tooth structure and the fact that it not only can but should be *hermetically sealed in the cavity*, will prevent discoloration by the ingress of the fluids of the mouth. In case the color of the tooth crown was lost before undertaking the treatment and being desirous of preserving the tooth by an inlay or filling, the *color can be restored* by one or two applications of sodium dioxid, Na_2O_2.

The use of this agent will be explained in a subsequent chapter on bleaching teeth.

Complications.—1. *Badly Decayed Root.*—This formocresol is very destructive to the soft tissues of the mouth, therefore the importance of always adjusting the rubber dam. If this cannot be done on account of a badly decayed root, it is suggested that care be taken in sealing the remedy in the cavity at the first sitting, and, in placing the cement, the original outline of the root can be approximated. After the cement has set, a band or matrix of gold or German silver can be fitted to and cemented on the root. In treating the case where there is a tooth posterior, it is best to place the clamp on this tooth and gently stretch the rubber over the band and thereby avoid loosening it.

2. *Pulp Partially Alive.*—In those cases where the pulp tissue is putrescent in one or more canals of a multirooted tooth and alive in the other one or two canals, as the case may be, we will find much satisfaction in using the formocresol remedy. These are exceptional cases and it is difficult to know whether this condition exists until the second sitting. If there be much vitality in the live pulp tissue, the formaldehyd in the remedy will doubtless make the tooth ache, but after we know the conditions our method of procedure is simple and the results will be certain. A small pledget of cotton dipped in the remedy can be gently placed over the mouth of the canals which contain putrescent material, and a thin quick-setting cement flowed over the cotton. After the cement has set the live pulp tissue in the remaining canals can be anesthetized or devitalized as the operator deems best at the time. Formerly these were difficult cases to treat, but with a remedy which can be hermetically sealed in a putrescent root canal, the procedure is materially simplified.

The author realizes that the method of treating putrescent pulps, here given, is a radical departure from those generally advocated; and, like myself, at first some of my experienced readers may hesitate to hermetically seal a cavity in a tooth which contains a putrescent pulp. The reason this could not be done in the past by the methods in vogue, is that drugs, in most instances, were selected and used solely because of their ability to inhibit the growth or destroy the vitality of microorganisms. The fact that there were other things, such as irritating gases, and poisonous ptomains, found in the canal and tubular structure of the dentin, and also the further fact that it was as necessary to dispose of these substances as it was to destroy germ life, was not given the significance this phase of the subject merited. The treatment which

is here outlined is along rational lines, for the remedy chemically converts the noxious intermediate and end-products of pulp decomposition into substances which themselves possess antiseptic and disinfectant properties.

II. *Acute Alveolar Abscess.*—The treatment of septic pericementitis and acute alveolar abscess, as was intimated in the chapter on The Treatment of Pericementitis, is so nearly identical that they will be discussed here conjointly. In those cases where the patient did not present for treatment until the confined gases had escaped through the end of the root, carrying the poisonous ptomains into the surrounding tissue, it is our duty to try to aid nature in aborting an abscess. It is in these cases that good judgment must be exercised, and extreme care taken. There is no condition which we are called upon to treat wherein a practical knowledge of pathology and therapeutics will serve us better than in this particular case. Frequently patients delay coming to the dentist until the infection has progressed to a point where all remedies will fail in aborting an abscess; but in many instances this result may be prevented by the proper use of drugs. The local treatment here is exactly the same as above for an ordinary putrescent pulp; for you never have a case of septic pericementitis or incipient abscess unless the pulp is dead and has undergone, partially at least, the process of decomposition. However, if the tooth is extremely sore, as is usually the case, the patient need not be subjected at this sitting to the annoyance of adjusting the rubber dam. Keep the tooth just as dry as possible, open into the pulp chamber, holding the tooth by some means, while drilling, so that the jarring will not further irritate the condition; then carefully seal in the formocresol remedy with cement; after which our attention, if necessary, should be given to the treatment of the infected pericemental membrane. In order to control the infection, and at the same time aid nature in readjusting the abnormal condition, it is not only our privilege, but it is our duty in these severe cases to administer internal drugs. Here alterative drugs are indicated. The great representative of the alterative class is potassium iodid, which can be given in the following prescription:

℞—Potassii iodidi, ʒ jss
Syrupi sarsaparillæ comp., fʒ iij—M.
Sig.—Take a teaspoonful in water after meals.

Ordinarily the directions would be as given, to have the patient take a teaspoonful three times a day after meals; but in these days of septic pericementitis or incipient abscess it is best to direct the patient

to take a teaspoonful every two hours until three or four doses are taken, and then follow the directions written on the label. It is well also to avoid the accumulation of blood in the part. To prevent this, saline cathartics are indicated—one that can be given is the official solution of magnesium citrate, owing to the facility with which it can be taken and its acceptability to the stomach, a prescription for which follows:

℞—Liquoris magnesii citratis, f℥ xij
Sig.—Take one-half at once and the other half in two hours, if necessary.

Magnesium sulphate (Epsom salts) is also an excellent remedy to be used for this latter purpose. The patient can be directed to take a teaspoonful dissolved in a wine-glassful of warm water, having a glass of cold drinking water at hand to drink at once after taking the strong salt solution. The cold water removes at once the bitter and unpleasant taste of the salt. A very good remedy to have the patient employ at home is the hot foot bath as explained in the chapter on The Treatment of Pericementitis. In malarial regions and in the spring of the year in many localities, the salts of quinin can be given, with beneficial results. The salt which the author prefers giving, if indicated in the conditions under consideration, is quinin bisulphate. Nearly all pharmacies have the salts of quinin put up in the form of pills. While these pills may be given it is much better to write a prescription for capsules. The gelatin capsule is soon dissolved in the stomach; thus we obtain the action of the drug more rapidly than when given in the dry, hard, pilular form. The following prescription can be written for the drug in two grain doses:

℞—Quininæ bisulphatis, gr. xxiv
Ft. capsulæ No. 12.
Sig.—Take one capsule every hour until the effect become noticeable.

Quinin acts differently upon different individuals. Most adult patients know the effect of this drug upon their system and therefore will be able to aid the dentist in determining the amount to be taken in a given case.

One of the most prominent symptoms with which we have to contend here is *pain*. In most cases the pain will subside soon after the local treatment; however, it is necessary occasionally, where the patient is nervous and has lost considerable sleep, to administer drugs which act upon the central nervous system, thereby controlling the pain. There are several drugs which if properly given will pro-

duce the desired effect. The United States Pharmacopeia of 1900 recognizes a compound powder of acetanilid which is recommended and can be prescribed as follows:

℞—Pulvis acetanilidi comp., gr. xij
Ft. chartulæ No. 2.
Sig.—Take one powder at once and the other in two hours, if not relieved.

Another very useful prescription for acetanilid is one suggested by Dr. A. W. Harlan, of New York.

℞—Acetanilidi, gr. viij
Syrupi simplex, f℥ ss
Spiritus frumenti, q. s. ad. f℥ iij—M.
Sig.—Take one-half at once and the remainder in two hours, if not relieved.

Dr. J. E. Keefe, of Chicago, suggests the following remedy by which he claims instantaneous and often permanent relief can be obtained:

℞—Alcoholis,
Aquæ, āā f℥ j—M.
Sig.—Use as directed.

This remedy is best administered in the form of a spray, using a watch case atomizer for liquids, forcing the spray well back into the nostril on whichever side the affected tooth is located. The application can be repeated as often as is necessary without any ill effects. In case an atomizer of any kind is not at hand, about fifteen minims of the remedy can be placed far back in the nostril with a suitable syringe.

The author does not wish to be understood as suggesting these various internal remedies in all cases of acute abscess. No therapeutist can tell exactly what internal drugs he would suggest without seeing the case and knowing the history; for there are many circumstances and conditions which modify the effect of drugs. Every remedy here mentioned, however, will be found useful in certain cases.

III. *Chronic Alveolar Abscess.*—There are two varieties of chronic alveolar abscesses—those without an external opening, except perhaps through a cavity in the offending tooth, and those which are discharging through a sinus. In these cases the decomposition of the pulp tissue is complete; the intermediate products (ptomains and amido-acids) have largely been broken up, and pus has been formed from the tissue and fluids surrounding the ends of the roots.

1. *Abscess without Sinus.*—In treating that variety of alveolar abscess which is without an external opening, our method of procedure is somewhat different. The tooth should be located; the rub-

ber dam adjusted, and the teeth sterilized as before; then the pulp chamber is opened with a suitable round bur. Usually the pus flows freely, in which case it is permitted to do so, pressure being made on the tissue immediately over the end of the root. It should be our effort to mechanically evacuate as much pus at each sitting as is possible. This being done, we have no necessity for using formaldehyd in the same strength solution as in those cases where the pulp chambers, root canals, and tubuli are filled with the intermediate and end-products. The modified formocresol remedy will be useful here. The canals should be dried with alcohol as thoroughly as possible and the remedy on cotton hermetically sealed in each canal. It is, however, at this sitting, impossible to get the canals dry, and it is unnecessary to have them so, for the remedy will penetrate where moisture is present. This is an advantage over most remedies suggested for this purpose. In those cases where there is a copious flow of pus at the first sitting, the original formula can be used, and the dressing should be changed every day until it can be removed without the pus flowing from the canals. When pus is forming rapidly at the end of the roots, the dressing soon becomes dissipated, the remedy is neutralized, and it is a loss of time to leave it in the canals more than twenty-four hours. Unless there be some complication, the pus formation should be checked in one or two treatments; at which time the modified formocresol remedy can again be used. It is now possible to change the dressing too often. The formation of pus has been checked, and the tooth should not be disturbed for at least one week or ten days, in order to give nature a chance to effect a cure. If at the end of this time there is no evidence of pus and the case gives a favorable history, the canals can be filled. Should there, however, be a slight odor although the tooth has not caused any trouble, we are not justified in filling the root. In these cases we can further modify our original formula by taking one drop of the mixture and adding two or three drops of cresol. It should be remembered that the value of formaldehyd in any remedy to be used in the treatment of these conditions depends upon the power this agent has of uniting chemically with hydrogen sulphid, ammonia and poisonous ptomains. When these substances are not present, formaldehyd, especially in this strength solution, is contraindicated. This precaution is mentioned here because formaldehyd is an irritating gas and any remedy containing it should be modified according to the conditions as found.

Quite frequently in these alveolar abscess cases, after the formation of pus has been checked we have a weeping of serum from the canals.

An excellent remedy to use in this case is eucalyptol to which thymol has been added in the following proportion:

℞—Thymol, gr. x
Eucalyptol, ℥j—M.
Sig.—Dry the canal as much as possible and hermetically seal in the remedy.

If this remedy fails to check the secretion and the fluid is *serum* not pus, no hesitancy need be felt as to filling the root, although the canals cannot be dried.

Occasionally we find a chronic alveolar abscess of this variety where it is almost impossible to check the formation of pus by applying drugs to the canals of the teeth. In those cases where the pus continues to flow freely when the dressing is removed at the third or fourth sitting, some complication can be expected. It is necessary then to force some stimulating agent through the apices of the roots, after the pus has been mechanically evacuated. The stimulating agent which the author uses almost invariably is a fifty per cent solution of phenolsulphonic acid. This preparation is made by heating phenol in an evaporating dish, adding the sulphuric acid, and then the water, slowly, while hot. If the resulting solution is not clear, it should be filtered by packing cotton in the neck of a funnel and passing the solution through. In resorting to this means of bringing about a more acute condition, I desire to emphasize the necessity of first evacuating the pus as completely as possible before using the remedy, after which the agent should be gently forced through the apices and the modified formocresol remedy sealed in the canal. It will be found that one or two treatments will usually check the formation of pus, after which the case can be treated as an ordinary abscess of this kind. In case this method fails to effect a cure, however, it will be necessary to surgically establish an opening through the overlying process and soft tissue and treat as for an ordinary discharging abscess—which treatment will now be considered.

2. *Abscess with Sinus.*—In those cases where the pus is discharging into the mouth through a sinus, our first duty is to locate the offending tooth. This is generally a simple matter for the reason that the sinus usually opens immediately over the tooth from which it comes. The pus in making its exit, however, follows the line of least resistance, and in some cases the condition of the process is such that the pus burrows forward or backward, and opens through the gum at a point several teeth removed from the one which is causing the trouble. These are the cases that are difficult to diagnose, especially

where the abscess has been discharging for some time, when there is not much tenderness in any special tooth, and where there are several pulpless teeth on this side of the mouth. Sometimes two teeth containing putrescent pulps have a common sinus. In this case it would be impossible to heal the tract by treating only one of the teeth. The use of a silver probe will be valuable in all such cases. By gently working the probe forward or backward the sinus can be explored and the offending tooth or teeth located without drilling into innocent teeth—a discouraging procedure to both patient and dentist. The tooth being located, all that is necessary to effect a cure—there being no complication—is to force some bland solution through the root canal and sinus, thus being certain it is well established; cauterize the tract, hermetically seal in the canal or canals the same agent used for this latter purpose or the modified formocresol remedy, and, at the subsequent sitting, the case giving a favorable history, fill the root.

Establishing Sinus.—If the abscess is not discharging, and it is well in those cases where it is discharging, before adjusting the rubber dam, to enlarge the mouth of the sinus with a lancet or bistoury. By dipping the lancet in phenol, this may be accomplished with very little pain to the patient. After this is done the rubber dam should be adjusted and the canals freely exposed. Now that the infection is past the end of the root, we need not hesitate to mechanically clean the canal at this sitting. The canals being clean we are ready to establish the sinus. To do this we need a bland solution and a good hypodermic syringe with a long straight needle for anterior and a long curved needle, for posterior teeth. There is an advantage in having a long needle, for the nearer the point is to the apex of the root, the less packing and force is required to send the solution through the sinus. Any bland solution can be used for this purpose. The author suggests peppermint water to which two minims of phenol has been added to the fluid ounce. A piece of unvulcanized rubber of the proper size should be selected, softened in the flame, and a hole made in the center through which the needle is placed and inserted into the canal. The rubber should now be tightly packed around the needle and held on either side with flat nose pliers, when pressure can be made on the piston of the syringe and the solution forced through the sinus. This should be repeated several times, care being taken not to break the needle in the canal. If convenient one corner of the dam can be raised, exposing the mouth of the sinus to view. There are two objects in forcing a bland solution through the sinus: one is to be certain that it is open, and the other is to mechanically wash out the

pus. Whenever pus can be mechanically removed, it is always better to dispose of it by this means rather than to do so by the use of some chemical agent. It is common practice after the sinus is established to use a solution of hydrogen dioxid. This is often a dangerous procedure and *always unnecessary* if the first solution has been used in sufficient quantity. For cauterizing the sinus in simple cases ninety-five per cent phenol has been largely employed. An excellent preparation to use for this purpose it the modified phenol solution. With the sinus well established, it is never necessary to place either of these solutions in a hypodermic syringe. The author knows of several instances where this has been tried with disastrous results. The remedy can be applied to the canals on cotton, when, with unvulcanized rubber and a suitable instrument, it can be forced through the sinus. Alcohol is a positive antidote for phenol; the alcohol bottle should therefore be in a convenient place so that the remedy used in the canal can be neutralized at once when it appears at the mouth of the sinus. If this has been well done, it matters little what drug or remedy is sealed in the canal. The modified phenól or the modified formocresol solution will give excellent results if hermetically sealed in the canals for about one week. In cases of long standing when we can reasonably suspect a roughening of the end of the root or process through which the pus has been discharging, it is good practice to use, as the cauterizing agent, a fifty per cent solution of phenolsulphonic acid, and in stubborn cases the pure acid can be employed. This agent rapidly disintegrates cotton, therefore it can be placed in the canal on threads of asbestos, wool fiber, or silk and forced through the sinus in the usual manner, cauterizing it, and also chemically dissolving any sharp edges of the root or process which may be a source of irritation and prevent healing. The author does not believe in delaying the root filling long after the sinus has been cauterized in uncomplicated cases; for by filling the root as soon as we are certain that the sinus is healing, we avoid a weeping condition, which usually exists and which is annoying when this part of the treatment is delayed for one month or six weeks as advocated by some writers. In these cases where the first treatment has been thorough, and the case gives a favorable history, the root should be filled at the second, or, at most, at the third sitting. If the case does not yield to the above treatment, some complication may be expected.

It is sometimes difficult to establish the sinus, especially on molar teeth. In all such cases where there is no complication, the case can be nicely treated with the formocresol solution as outlined under

treatment of abscess without sinus. Before referring to complicated cases the treatment of putrescent pulps and abscesses associated with deciduous teeth will be considered.

Treatment of Putrescent Pulps and Abscesses in Deciduous Teeth.—In treating the conditions under consideration, in the mouths of children, it is necessary in most cases to modify our usual method of treatment. Our first duty here is to gain the confidence of the child. If the abscess is associated with a deciduous molar which we would desire to save for at least a year or two, it can be treated nicely in the following manner: After gaining the confidence of the little patient the mouth can be rinsed with an antiseptic solution—one which has a pleasant taste. Then open into the pulp chamber and place a pledget of cotton in the opening. Now mix on one end of the cement slab precipitated calcium phosphate and the formocresol remedy, making a stiff paste. On the other end of the slab have a quick setting cement ready to mix. Again rinse the patient's mouth and, keeping the cavity as dry as possible, gently pack the paste into the pulp chamber and flow the cement over it, filling the cavity. If deemed advisable, the cavity can be prepared in the cement and filled with amalgam. It is remarkable how rapidly these abscesses will heal and remain quiet when treated in this manner, provided, of course, there be no caries or necrosis of bone.

Complications.—There are several complications of chronic alveolar abscess of both varieties, with and without a sinus, where it is necessary to modify or change the general method of treatment to meet the conditions as they exist. For instance, in the case of an abscess without a sinus where we can reasonably suspect, and where the indications point to a roughening of the end of the root, we ought not to expect to cure the case by simply sealing remedies within the canals of the tooth. If we do, we are expecting too much of drugs. Again, in a case of an abscess with a sinus where the pus has been discharging for several months, with the not unusual result that the end of the root or process through which the pus has discharged has become roughened, we should not expect to effect a cure by forcing phenol or modified phenol through the sinus; because such agents as these have no action whatever on the bony structures.

1. *Denuded End of Root.*—One complication we may expect to find in abscesses of long standing, especially in the variety without a sinus, is where a large area of tissue in the apical space has been absorbed or broken down, denuding the end of the root and the denuded portion projecting into the absorbed area. It is possible, in these

cases, to make pressure over the end of the root and mechanically evacuate all of the pus above the apices; but we cannot expect by this means to evacuate the pus below and surrounding the end of the root projecting into the space. In this case we must do one of two things: Force some stimulating agent through the end of the root into the infected area, to create a more acute condition, or surgically establish a sinus through the overlying process and soft tissue and treat as an ordinary discharging abscess. While the author does not hesitate to adopt the latter method if necessary to effect a cure, it will be found that the use of a stimulating agent will generally suffice in these cases. The agents recommended are a fifty per cent solution of phenolsulphonic acid, or a fifteen per cent solution of trichloracetic acid. In using either of these solutions the pus should first be evacuated as much as is possible; then the solution selected can be placed in the canal and gently forced through the apices and the modified formocresol solution sealed in the canal. One or two treatments will usually be sufficient to check the pus formation, when the case can be treated in the ordinary manner.

2. *Absorbed Root.*—Another complication of both varieties of chronic alveolar abscess is where the pus has stood in contact with the end of the root sufficiently long to cause an absorption, leaving a roughened end which irritates the tissue and prevents healing. Sometimes, also, the process through which the pus has burrowed is left with sharp edges. In all such complications the "acid treatment" is especially indicated. These cases generally yield nicely to the treatment if phenolsulphonic acid is used as the agent with which to cauterize the sinus, as the acid dissolves any sharp edge of root or process.

3. *Encystment of Root.*—A difficult complication to treat is where an abscess occurs on a root, the end of which has become encysted from deposits, excementosis or other causes. In order to effect a cure in these cases, it is necessary to establish a sinus and remove the deposits, excise the root, or extract the tooth. The method of excising the root will be discussed later.

4. *Involving Vault.*—Still another complication often difficult to cure is where the pus has worked its way through the lingual plate of bone and involves the vault of the mouth. The dense fibrous tissue covering the vault is very tough and the pus often separates the periosteum from a considerable area of bone before ultimately discharging into the mouth. Generally a lancet is required to evacuate the pus. In treating these conditions it is essential to explore the affected area, using a sharp steel instrument in order to determine whether there is

caries or necrosis. Unless too much bone is involved the case can be successfully treated by first making a liberal opening with a sharp bistoury and, if necessary, breaking down the sharp edges of bone, through which the pus has burrowed, with a round bur having a long shank, after which the sinus should be established in the usual manner, using a considerable quantity of the bland solution. Now dry the canal and force through the sinus full strength phenolsulphonic acid. Sometimes it is advisable to place a piece of blotting paper soaked in liquid vaselin over the lingual opening when forcing the acid through. This causes the agent to spread and come in contact with the entire area involved. Alcohol and the oils will neutralize any excess of the phenolsulphonic acid that may get on the other tissues of the mouth. This treatment should be repeated as often as the case demands. When there is no evidence of pus and the case has healed sufficiently so that there is only a watery discharge the root can be filled.

5. *Secondary Abscess Pocket.*—Occasionally we find an abscess of the discharging variety which does not yield to our general treatment, yet we are reasonably certain that none of the complications so far mentioned are present. In these cases we can suspect a *secondary abscess pocket.* This is especially true where the sinus opened into the mouth several teeth removed from the affected tooth. This pocket can usually be discovered by the aid of a small silver probe The treatment is simple—all that is necessary is to open the pocket, wash it out first with a bland solution, then inject fifty per cent phenolsulphonic acid. In using phenolsulphonic acid in such cases it cannot be injected through the tooth, therefore it is necessary to use a syringe —a glass syringe with an asbestos-packed plunger and a gold or a platinum needle should be used.

(6.) *Involving Antrum.*—The pus in making its exit follows the line of least resistance, and sometimes it is easier to work its way through the floor of the antrum than through the labial or lingual plate of bone. The treatment of this complication will not be discussed here; but in this connection it is well to remember that so good an authority as Kyle, viewing the question from the nasal side, finds that fully fifty per cent of antral diseases are of dental origin.

Excision of Root.—In all complicated abscesses which will not yield to the treatment outlined above, we can often save the root by excising its end. This should be done only as a last resort and then under the most aseptic measures. The hands of the operator, as well as all instruments used, should be thoroughly sterilized. Before operating, the root should be filled and a thorough exploration made

that the amount of process and root involved may be noted. A local anesthetic injected deeply should be employed and a circular incision made. The opening can now be packed with gauze dipped in a 1.1000 solution of adrenalin chlorid for a few minutes. In all large roots the author prefers following the method of Dr. Thos. L. Gilmer, of Chicago. With a spear-shaped drill a hole can be made through the center of the root after which the root is easily excised with a fissure bur, placing the bur in the hole and drilling mesially and distally. It is often difficult to remove the end after the excision is made. This can be done with a strong hatchet or hoe excavator, an elevator and sometimes with small beaked root-forceps. After removing the excised end, the root remaining should be smoothed with a round bur and the area thoroughly curetted, removing any necrosed process which may be present. The wound should now be washed with an antiseptic solution and packed with sterile gauze. The patient should be instructed to keep the mouth as clean as possible and the packing should be changed every two days until granulation begins to fill the space.

Whenever the operator is in doubt as to the best means of treating complicated alveolar abscesses, he should never hesitate to consult with a practitioner who has had more experience in treating these cases. Such a course cannot be construed as a lack of knowledge, but is evidence of conservatism and progress.

Pericemental Abscess.—All of the alveolar abscesses which we have discussed thus far in this chapter have been the result of an infection in the apical area, the infection being due to pathogenic bacteria, poisonous ptomains and irritating gases, which have escaped from a putrescent root canal. There is, however, an abscess that occurs in the alveolar region about the roots of teeth, not caused from the source mentioned. This particular kind of abscess occurs in connection with live teeth; not necessarily so, however. There is a progressive breaking down of the pericemental membrane and in dental literature it is called a *pericemental abscess*. The cause of this particular kind of abscess is rather vague; but it is generally supposed to be due to some traumatic injury. It frequently occurs on the labial surface of the roots of the anterior teeth involving most of this surface. They have also been known to occur between the roots of molar teeth, especially the upper molars. While a pericemental abscess is often associated with pyorrhea alveolaris, care should be exercised, in making the diagnosis, not to get this condition confused with the latter disease.

Treatment.—For convenience in outlining our treatment for a

pericemental abscess, the condition may be classified as *acute* and *chronic*. As a rule there is very little pain associated with either variety of pericemental abscess. In the acute form, which, as such, is extremely difficult to diagnose, the patient will complain of "something being wrong with a particular tooth." About all that can be done therapeutically with the acute form is to pacify the patient as best we can until the acute abscess develops into the chronic variety, when pus is formed and discharges usually at the gum margin, and thus the diagnosis is more easily made. If the abscess occurs on the anterior teeth where the area involved can be curetted and cauterized it will generally yield to the treatment; but the treatment of a chronic pericemental abscess on molar teeth is at best a discouraging procedure and practically the only permanent cure is to extract the affected tooth. In those cases where the area can be reached, an opening, if necessary, can be made through the gum, the root thoroughly scraped and polished, then after washing out the abscessed area, it should be cauterized with some cauterizing agent. Nothing gives better results than phenolsulphonic acid. With a proper glass syringe and a gold or platinum needle, the remedy can be injected into the abscess pocket. One thorough treatment should effect a cure. In curetting these cases it is far better to go a little beyond the affected territory rather than fail to remove all of the affected tissue and have the abscess recur. Where the abscess can be reached, thorough curettment and cauterization will effect a cure. That portion of the pericemental membrane which has been destroyed will perhaps never be regenerated, but if we succeed in having granulation fill in the area involved, even though the membrane is not regenerated over that particular surface of the root, the tooth can be saved for a considerable length of time.

Filling Root Canals.—There are so many different methods of filling root canals, and there seems to be such a variance of opinion as to the best method of performing this operation, that it is with a degree of hesitancy that the author attempts to discuss this subject. This operation stands as a sort of dividing line between the subjects of *therapeutics* and *operative dentistry* proper. In discussing this subject the author will present the therapeutic aspect and describe a method of procedure which has proved successful in his practice.

It will be remembered that three factors were emphasized in the chapter on pulp removal and the subsequent treatment, viz.:

1. Established and maintained asepsis.
2. Preserve the color of the tooth.
3. Thoroughly fill the canal.

The author suggests filling all canals, which are large enough for a broach to enter, with gutta-percha in the manner which will be subsequently described. In connection with the preservation of the color of the tooth, it should be mentioned that *white base plate gutta-percha* should be used, especially for the purpose of dissolving in chloroform, making chloro-percha. If this white substance is forced into the tubuli of the crown of the tooth, as it is liable to be, it will not change the color of the tooth structure as would the pink gutta-percha. A great many dentists have been moistening the canal, previous to filling with gutta-percha, with *oil of eucalyptus;* and, as a result, much unnecessary pericementitis has followed this operation. If oil of eucalyptus is used at all, the refined oil only should be selected; and, far more satisfactory results will follow the use of *eucalyptol*, the most volatile constituent of oil of eucalyptus. While eucalyptol is irritating, it is not nearly as much so as is oil of eucalyptus. The author suggests modifying the irritating property of eucalyptol and enhancing its antiseptic power by combining menthol and thymol as suggested in the prescription for modified eucalyptol in the chapter on The Treatment of Ordinary Pericementitis.

In this proportion the agents added do not interfere with the solvent power of eucalyptol for gutta-percha; but if the amounts are increased to any appreciable extent this does not hold true.

In filling root canals it is always the safest practice to adjust the rubber dam, for asepsis must be established and maintained. The same agents can be used for sterilizing the teeth after the dam is adjusted as were described in removing pulps by the anesthetization method. The canals should be aseptic before the operation is attempted. If there is any doubt in this regard the operation should be deferred until the canals are in such a condition.

Filling Large Canals.—In filling large canals, especially those in connection with which abscesses have been treated, where the apex is large and where we ought not to expect to get a response from the patient when the gutta-percha cone reaches the apex, on account of the absorption in the apical area, it is best to measure the canal and then use one cone which approximately fits the canal rather than use two or three smaller cones with the possibility of forcing one through the apex and into the apical area. There is almost as much danger of forcing the root filling too far in large canals, as there is in not forcing it far enough in small canals. To measure the canal, cotton can be tightly wrapped around a smooth, sterile broach and inserted. When, by repeated trials the cotton fits the canal, a cone can be made of white

base plate gutta-percha, which is slightly smaller than the tightly wrapped cotton. The canal should now be moistened with modified eucalyptol, flooded with white chloro-percha, working the latter up or down into the canals with a fine smooth broach, exhausting the air. If cotton is wrapped around the broach used for this latter purpose, only a few shreds should be used; for we should avoid making a piston out of the broach and thus defeating the means of exhausting the air. This accomplished, the cone can be slowly and gently pressed to place. In filling large canals from which live pulps have recently been removed, the patient will generally flinch before the cone reaches the apex. When this occurs, we should wait a few moments, when the cone can be gently pressed much farther without causing the patient to flinch a second time. If these precautions are observed, they will be the means of preventing much of the pericementitis following the filling of root canals.

Small Canals.—In filling all canals where we can enter nicely with a smooth broach, it is best to follow the technique outlined above, using a cone which will enter the canal. However much we may regret it, there are canals, especially in the molar teeth, so small and tortuous that even a fine, smooth broach will not enter; at least to any depth. It is useless to try to fill such canals with a gutta-percha cone. The methods of enlarging the canals by the use of acids and caustics, as referred to in connection with the destruction of pulp tissue in such canals, can be employed; but it is not always advisable to enlarge them sufficiently to admit a small cone. After the larger canal or canals in a multirooted tooth are filled in the ordinary manner, the smaller ones can be moistened with modified eucalyptol and chloro-percha worked up or down into the canal. This process should be kept up for some time and until the chloroform has nearly evaporated, leaving the gutta-percha quite plastic. The sides of the pulp chambers can now be moistened with modified eucalyptol and a piece of base plate gutta-percha, selected and softened in the flame, can be packed into the pulp chamber, when pressure can be made towards the small canals and the plastic gutta-percha forced into them. This is much better practice than simply filling the mouth of the canal with a gutta-percha cone. If the canal is so small and tortuous that even a small broach will not enter, and if it cannot be enlarged by the use of acids or caustics, as referred to in a previous chapter, it is good practice to make a paste of formocresol and precipitated calcium phosphate, placing the paste over the mouth of the canal and covering it with cement.

As previously mentioned there are many methods of filling root canals by which good results are attained. The method here outlined has served the author well. In closing this chapter I desire to say that no reasonable amount of time should be considered lost in treating the conditions discussed in this chapter and in properly preparing canals for the insertion of the filling material.

CHAPTER XXIII.

THE CAUSES AND TREATMENT OF DISCOLORATIONS OF TEETH.

BY J. P. BUCKLEY, PH. G., D. D. S.

General Consideration.—In the discussion of the methods of removing pulps from teeth and the subsequent treatment, the treating of putrescent pulps and the various kinds of alveolar abscesses, the author endeavored to emphasize the necessity of *preserving or restoring the color of the tooth.* There is, perhaps, nothing more annoying to a conscientious dentist and to an appreciative patient than a discolored tooth in the patient's mouth. If the precautions, which have been mentioned in the preceding chapters, with reference to this factor are observed in the treatment of teeth, the necessity for bleaching may often be avoided; for after all that has been written on this subject is studied, it must be admitted that the most successful method of bleaching teeth is to so treat them that they will not need to be bleached. There are three principal sources of the discoloration of tooth structure, viz., pulp decomposition, remedial agents and metallic fillings. The greatest source is that of pulp decomposition. Many teeth containing putrescent pulps are discolored before the patient presents for treatment. In those cases where the color is not lost the putrescent condition can be corrected and the color preserved by the method of treatment outlined in a previous chapter.

There are two ways by which the discoloration is produced, *i. e.*, by solutions which stain the cement-like substance uniting the tubuli, and by the ingress into the tubuli of insoluble coloring substances. For instance, many remedial agents in solution such as oil of cassia, silver nitrate, etc., have the property of staining the cementing substance and producing discolorations; while the sulphids formed from certain metals, as for example in amalgam fillings, produce discoloration by virtue of being forced into the tubular structure of the dentin. If more care were taken in selecting remedial agents, used in the treatment of teeth, which would not stain the tooth structure, and if high grade alloys were selected in making amalgam fillings, the cavity

properly prepared, amalgam inserted and polished when set, there would be few teeth discolored from these sources.

Occasionally, however, teeth have been observed to assume a pinkish hue shortly after some traumatic injury, rapid regulation or after the application of some irritating drug had been applied to some small exposure of the pulp as, for instance, arsenic trioxid. It was stated in a previous chapter, that it is always best to apply arsenic trioxid to the dentin immediately over the pulp, even though an exposure exists. Dr. E. C. Kirk, of Philadelphia, has offered a plausible explanation for the cause of this immediate discoloration. He says, "It is now known that the pink staining of the tooth is brought about by a rupture of the stroma of the red blood disks liberating their contained hemoglobin, which dissolves in the plasma, forming a solution of hemoglobin which readily penetrates the dentinal tubuli, the lumen of which is of insufficient diameter to admit the unbroken red corpuscle. This pink discoloration resulting from the infiltration of hemoglobin solution represents the first stage of tooth discoloration. The pink stain readily undergoes alterations, later on assuming a brownish tint, due to the breaking down of the highly complex molecule of hemoglobin into a reduction product known as hematin." But as has been stated, many teeth containing putrescent pulps are discolored before the patient presents for treatment, and inasmuch as this is by far the greatest source it is well to try to ascertain definitely the true cause of the discolorations from this source; for, it is difficult and unsatisfactory to try to bleach a tooth when we have no knowledge of the nature of the pigment we are trying to bleach.

The principle which governs the successful bleaching of teeth is to chemically change the molecule of the pigment in such a manner as to destroy its color, or chemically change the insoluble coloring substance to a soluble form, when it can be washed out of the tooth structure. Attention will now be directed to the cause of discoloration from pulp decomposition as the author understands it. In the chapter on the Chemistry of Pulp Decomposition, the intermediate and end-products resulting from this complicated process were enumerated and it was ascertained that ammonia, NH_3, and hydrogen sulphid, H_2S, were the principal gases formed. It was also pointed out that the relative amount of nitrogen and sulphur found in the proteid molecule was fifteen per cent of the former to 0.3 per cent of the latter; and from this fact it was reasoned that ammonia, a compound of nitrogen and hydrogen, was generated in far greater quantities in a putrescent root canal, than hydrogen sulphid, a compound of hydrogen

and sulphur; and that this latter gas did not assume the important rôle in the discoloration of teeth from this source, as had been so generally supposed.

It is quite generally conceded by those who have given this phase of the decomposition process their attention, that iron, Fe, is the most important element to be considered in the many factors entering into the discoloration problem; and it is a common statement found in our text-books and journals that the discoloration is due to the formation of ferrous sulphid, FeS, which salt is supposed to be formed by the action of hydrogen sulphid upon the iron. This view is held by many writers, among whom is Dr. Kirk, who has perhaps given more thought to this subject than any other writer. The source of iron has been considered entirely from the decomposition of the hemoglobin of the red blood corpuscles; for it is well known that this compound contains iron, which is not characteristic of all proteid bodies. Dr. J. E. Hinkins, of Chicago, in his analysis of the enamel and dentin of human teeth, found that iron existed in both of these structures in combination with aluminum. It is not unlikely that future investigation will find that the iron from this source plays a part in the discoloration of tooth structure. It remains, however, to be demonstrated that ferrous sulphid is the true cause of the discoloration and the author doubts if this theory can ever be proved to be correct. From chemistry we learn that ferrous sulphid is a *black* compound and that no change takes place in the color or otherwise by exposing it to the air. Should the discoloration of tooth structure be due, then, to ferrous sulphid, as claimed by many writers, there would be no necessity, in treating putrescent pulps, so far as preserving the color of the tooth is concerned, for using a remedy which can be hermetically sealed within the tooth. Clinical experience shows that a tooth containing a recently decomposed pulp, in a large percentage of cases, is not discolored, and that such a tooth will not change in color if the formocresol remedy is used in the treatment and always hermetically sealed.

Dr. Kirk admits that, "Ferrous sulphid, as such, cannot be held wholly accountable for the bluish-black color of the tooth which has reached the stage of permanent discoloration." Neither can the *green* nor *yellow* discolorations of teeth be attributed in any way to the presence of black ferrous sulphid; yet, the author is of the opinion that it is possible for this compound to be formed in the ultimate process of pulp decomposition as will be explained later on in this chapter. From the foregoing, it must be evident that it is necessary to search

for other colored substances, besides black ferrous sulphid, which are possible to be formed in the process of pulp decomposition and which are capable of staining the tooth structure.

In articles which the author read before the Odontographic Society of Chicago (*Dental Review*, June, 1901, October, 1902), a theory was advanced which explained the variety of colors exhibited in discolored teeth, and while some criticism has been offered in regard to this theory, he is still of the opinion, that it presents today the most rational solution of this question from both the chemical and clinical viewpoint.

As has been stated, ammonia is not only a constant end-product, but it is generated in far greater quantities than any other gas. It is well known that ammonia has the property of uniting chemically with water, which is always present in a putrescent root canal, forming ammonium hydroxid, $NH_3 + H_2O = NH_4OH$. This reagent will act upon the soluble salts of iron, in both the ferrous and ferric forms, producing respectively, ferrous and ferric hydroxid, $Fe(OH)_2$, $Fe_2(OH)_6$. Therefore, it is not only possible, but quite probable, that the atomic iron which is liberated in the process of decomposition, from the hemoglobin or perhaps intermediate compounds containing it, unite with the ammonium hydroxid present, forming the hydroxid of the metal; and inasmuch as the compounds containing the iron are organic or weak, the ferrous hydroxid, in all probability, would be produced. Ferrous hydroxid is a white compound which readily absorbs oxygen when in the moist state and exposed to air, and gradually changes to ferric hydroxid, a reddish-brown compound. In this change there is an array of four distinct colors—white, green, black and brown—and in the blending of these four colors there is produced every variety of shades exhibited in discolored teeth. This seems to suggest a plausible explanation as to why teeth containing putrescent pulps change color when air is admitted; also why a tooth containing a recently decomposed pulp is not discolored and does not readily change color until air is admitted. I fully recognize the fact that ferrous hydroxid is not the only compound of iron capable of producing color changes when moist and exposed to air. Nearly all of the ferrous compounds change more or less; but with the possible exception of ferrous carbonate, which could be formed, ferrous hydroxid is the only compound of iron possible to be produced, the color changes of which correspond to those seen in teeth which have reached the stage of permanent discoloration.

I have stated in this chapter that, in my opinion, it was also possible

for ferrous sulphid to be formed ultimately by the putrefactive process; but it can only be produced by the hydrogen sulphid acting first upon the ammonia, forming ammonium sulphid, $H_2S + 2NH_3 = (NH_4)_2S$. This *alkaline* reagent will act upon the soluble salts of iron, precipitating the metal as ferrous sulphid. My conclusions, then, with reference to the true cause of the discoloration, are these: that the permanent yellow discoloration is due to the formation of ferric hydroxid; the bluish-black discoloration to a mixture of ferric hydroxid and ferrous sulphid—or to a failure of the ferrous hydroxid to become completely oxidized into the ferric form owing to a lack of moisture or oxygen; the other colors observed are transitory and are due to the gradual transition of the ferrous into the ferric hydroxid. In coming to these conclusions I have accepted the statement that iron plays the most important rôle of all the elements entering into the discoloration problem; for if it were possible to remove the hemoglobin from the blood or the iron from the hemoglobin, I do not believe the dentin could be discolored by any compound possible to be formed by the process of pulp decomposition. If this be true, my reasoning is at least logical.

Having thus far, in this chapter, discussed the *cause* of the discoloration of tooth structure, the methods of restoring the normal color will now be considered.

When a case presents for bleaching there are three important things to be determined:

(1) Ascertain, if possible, the cause of the discoloration.

(2) Decide whether or not the color can be successfully restored.

(3) The selection of the proper bleaching agent with which to restore the color.

The general cause of the discoloration can usually be ascertained from the history of the case as related by the patient. Whether or not the tooth can be successfully bleached depends largely upon the cause of the discoloration, the condition of the tooth structure, and the length of time the tooth has been discolored. Experience will prove that the teeth which will permanently retain their color, after it is restored, are those that have a good bulk of dentin and which dentin can be protected by the remaining enamel and some filling material, preferably porcelain if this material is at all indicated. I desire to emphasize the fact that it is folly to expect a tooth to retain its color any length of time after once being bleached unless *the dentin is properly protected.*

Having ascertained the cause of the discoloration and believing

that the condition of the tooth structure justifies us in attempting to bleach the tooth, we come to the most important consideration, viz., the selection of the bleaching agent, with which the color can be restored with the least inconvenience to the patient and operator.

Methods.—All of the methods employed in bleaching teeth involve more or less chemistry; and from a chemical viewpoint there are two general methods of bleaching teeth—*oxidation* and *reduction*.

I. *Oxidation Method.*—This general method is of two kinds also *direct* and *indirect*.

(1) *Direct.*—By direct oxidation is meant the use of any agent or agents from which oxygen can be directly obtained. The agents used for the purpose are:
Sodium dioxid, Na_2O_2. Twenty-five per cent ethereal solution of hydrogen dioxid. H_2O_2. Alphozone, $(COOH.\ CH_2.\ CH_2CO)_2$-O_2. Aluminum Chlorid, Al_2Cl_6, and a three per cent aqueous solution of hydrogen dioxid. Oxalic acid, $H_2C_2O_4.\ 2H_2O$.

(2) *Indirect.*—By indirect oxidation is meant the use of any agent or agents by which oxygen can be obtained indirectly. The agents employed are such as will liberate nascent chlorin, Cl, a chemically active gas, which, in the presence of moisture seizes upon a molecule of water, H_2O, abstracts the atoms of hydrogen, H, forming hydrochloric acid, HCl, and liberates the oxygen, O, in the nascent state, as $H_2O + 2Cl = 2HCl + O$ (nascent). Some of the agents used for this purpose are:

Aluminum chlorid and a freshly prepared Labarraque's solution (Harlan).
Chlorinated lime and dilute acetic acid (Truman).
Powdered alum, $Al_2K_2(SO_4)_4$, and Labarraque's solution.
Solution of sodium chlorid electrically decomposed.

II. *Reduction.*—By reduction is meant the use of any agent or agents which will abstract oxygen from a compound containing it. The agents which have been recommended are, sodium sulphite, Na_2SO_3, 10 parts, and boric acid, H_3BO_3, 7 parts. These are mixed and placed within the tooth, moistened with water and hermetically sealed. (Kirk.) A reaction occurs between the two substances with the ultimate formation of sulphurous acid which has a great affinity for oxygen and is therefore a good reducing agent. In some cases where the tooth has been discolored by remedial agents and where it is desired to break up the color molecule, good results are obtained by this method. Whenever the method is used the

tooth should subsequently be thoroughly washed with an alkaline solution such as a ten per cent solution of sodium bicarbonate or borax to neutralize the acid.

In most cases of discoloration the direct oxidation method is preferable and in view of the fact that all of the agents used in the direct method of bleaching depend upon the generation of oxygen for their efficacy, it can readily be understood that the direct method is far more satisfactory. The fact, also, that hydrochloric acid is a constant by-product in the indirect method, thereby creating an *acid* medium, adds to the objectionable features of this method; for manufacturers have recognized for years that better results can be obtained in bleaching ivory, wool, hair, feathers, etc., when the bleaching process was carried on in an *alkaline* medium. This is likewise true in bleaching teeth. Believing then, that the direct oxidation method is far superior to the indirect, I shall not burden my readers by describing the latter method; but will direct attention to the detailed use of *sodium dioxid*—a direct oxidizing agent and one which, if its chemical properties are known and its dental application understood, the author believes to be the best agent for bleaching teeth thus far suggested to the profession.

Sodium dioxid was introduced by Dr. Kirk in 1893. It is a rare chemical, not because it is difficult to manufacture, but because of the fact that in the past there has been little demand for it. Its chemical activity precludes its use on soft tissue; hence, it is scarcely known to the medical profession, and is not kept in many pharmacies. It is the oxid formed when sodium is allowed to burn briskly in dry air or oxygen. The product occurs in commerce as a yellow powder and is readily decomposed by water into caustic soda and oxygen. Because of this latter fact, much of the product obtained from wholesale druggists, labeled "sodium dioxid," is nothing but caustic soda. This accounts for the fact that many dentists have tried this method of bleaching and failed to get results. The fault is not with the method, but with the powder used. In order that we might be able to ascertain the efficacy of the chemical, some years ago I devised a simple chemical test for this purpose. In a clean, dry test tube place about one gm. (15 grs.) of the powder and to it add 1 or 2 c. c. (15 or 30 m.) of water. If the specimen is good sodium dioxid, enough oxygen should be generated to kindle a glowing splinter held at the mouth of the tube. Having tested the chemical and proved it to be sodium dioxid, and not caustic soda, the next thing is to properly prepare the tooth, which, of course, should have been previously treated and the root filled with

gutta-percha. The rubber dam should be adjusted, if possible without the use of the steel clamp. The ligature should be wrapped twice around each tooth included in the dam, which should be at least two teeth on either side of the one to be bleached. This will prevent the by-product, caustic soda, from getting on the soft tissue and destroying it. The lower third of the root filling should now be removed with a good sized round bur—it being necessary, for permanent results, to bleach the tooth rootwise as far as possible. We are now ready to apply our bleaching agent. Both the dry sodium dioxid and a solution made by carefully dusting the powder into ice water is recommended to be used. The best results are obtained by using the dry powder, placing it into the cavity and with a platinum broach or pointed glass instrument, work the powder well up into the canal from which the root filling has been removed. Care should be taken not to use steel instruments, as the oxygen will attack the steel forming ferric oxid and therefore we may get into the tooth the pigment we are trying to remove. In some cases it is rather difficult to place the powder in the cavity without getting it on the patient's face or clothing. To overcome this a strip of unannealed 1.1000 platinum foil can be placed between the discolored and adjacent tooth, letting it extend above or below the cutting edge, as the case may be, when white base plate gutta-percha can be warmed and pressed against the lingual surfaces of the teeth included in the dam. This forms a pocket on the labial side into which the powder can be easily placed, using a little gold or platinum spoon or spatula. In more difficult cases a paste can be made of the powder and chloroform, in which it is insoluble, quickly packing the paste into the cavity, evaporating the chloroform, leaving the dry powder where it is desired. Distilled water is now dropped upon the powder, causing a lively effervescence and the following reaction takes place: $Na_2O_2 + H_2O = 2NaOH + O$ (*nascent*). This nascent oxygen is a powerful oxidizing agent. It attacks and rapidly destroys any organic matter which may be present in the tubular structure of the dentin. It also thoroughly bleaches vegetable colors and acts upon any iron compounds which may have produced the discoloration. It converts ferric hydroxid, if present, into ferric oxid—still an insoluble compound. If ferrous sulphid is present in the moist state, it may be converted into ferrous sulphate, a soluble salt; but in the presence of caustic soda it would be reprecipitated as ferrous hydroxid, which, in turn, in the presence of oxygen, is at once reconverted into ferric oxid. Therefore, the pigment to be removed, if our chemical reasoning is correct as to the cause of the discoloration

from pulp decomposition, is ferric oxid, an insoluble compound and must be removed mechanically by washing the tooth. Its removal is facilitated by the by-product, caustic soda, acting upon any fatty substances—fat being an end-product of the putrefaction of the proteid material—which may be present in the tubuli. The result of this action being a soluble soap, the removal of which by washing, aids, as stated, the mechanical removal of the insoluble pigment.

It is my opinion that the ultimate success depends quite as much upon the mechanical removal of the coloring matter as upon the chemical destruction of it; therefore, the necessity for thoroughly washing the tooth after each application of the bleaching agent. Warm distilled water should be used in a strong syringe, letting a moist sponge absorb the water. The cavity is now dried, the color of the tooth observed and the process repeated, if necessary. Usually two or three applications are sufficient. If the color is not readily restored, the dentin can be saturated with a two per cent solution of sulphuric acid which can now enter the tubuli and chemically convert the oxids, that may not have been mechanically or otherwise removed by the saponifying and washing process, into sulphates. The salts produced are freely soluble and can readily be washed out by again using the warm water. When the tooth is satisfactorily bleached, a paste of precipitated calcium phosphate and distilled water can be placed in the cavity, packed into the lower third of the root and burnished, with a warm burnisher, against all exposed dentin. This is thoroughly dried by burnishing, the excess removed, and a light-colored, quick-setting cement used to form a base for the final filling which had better be inserted before the dam is removed.

In conclusion I desire to say that in the bleaching of teeth we find a practical application of the science of chemistry to the practice of dentistry; and that in the discoloration of tooth structure from the various sources can be found a fruitful field for further investigation.

CHAPTER XXIV.

THE TREATMENT OF CHILDREN'S TEETH.

BY C. N. JOHNSON, M. A., L. D. S., D. D. S.

This subject naturally divides itself into two parts—the management of the child, and the management of the teeth. Temperamentally, physically and nervously there is so much difference in children that to ignore this factor and prescribe a set method of practice for all cases would result in confusion, failure and disaster.

The first visit of a child to the dentist is usually a momentous occasion. Sometimes it is undertaken with the direst dread, at others with the most eager anticipations; all dependent on the point of view given the child by the parent. The dentist's duty is to study the temperament of the child most carefully, and he should not content himself with anything short of obtaining a perfect mastery over the child, at least during the time the latter is in his office. The means to be employed in gaining this mastery are as varied as are the manifestations of juvenile human nature—probably the most varied of anything in psychological study.

The chief factor, the fundamental basis of success in controlling children, is the exhibition of extreme kindness and the cultivation of infinite patience. Unless a dentist can bring this kind of an attitude to the management of his young patients he would better not attempt their treatment. And yet there are some children so unruly by nature and so spoiled by false training at home that to obtain command over them in the dental chair the operator must be firm with them almost to sternness. If the parent has no control over the child, as is sometimes unfortunately the case, then the dentist should be the means of giving the child what is probably its first real lesson in discipline. And let it be said that no class of men, not even medical practitioners, are placed in so favorable a relationship to these young patients for the purpose of instilling into them obedience and stability of character as is the dentist, and if the members of our profession would only rise to the possibilities of their opportunities in this regard they would do no small part in developing true manhood and womanhood in the rising generation. To bring up a child with no idea of

individual responsibility, to foster a tendency toward avoiding any duty of a disagreeable nature, to always sprinkle roses for the child to tread upon, is weakening in its effect and results in deterioration of character and the pitiable failure to meet the emergencies of life as they inevitably arise.

A discriminating dentist can do much in his professional relationship with these young minds to develop in them stamina and force of character, and it is sometimes the case that the first real experience of facing and properly meeting an issue is fought out in the dental chair. To be successful in the management of children under these trying circumstances a dentist must be a rare student of human nature, and he should early learn just when to be yielding and tender, and when to be firm as adamant. But let it always be remembered that under no circumstances, however trying the case may be, should he allow himself to lose his own self-control and display temper or impatience; and whenever it has been necessary to be firm and even severe, he should invariably soften his demeanor by the utmost kindliness and an unmistakable interest in the little patient's welfare. To gain complete control of a child who previously has never been controlled by any one is no mean achievement, and the sense of satisfaction in the good attained is well worth all the effort it requires to accomplish it.

One feature of the management of children in the dental office which in this enlightened age of child study would seem unnecessary of mention, but which unfortunately is still a factor in some instances, is the habit of deceiving the child as to what is to be done. There is no more fatal error, no more disastrous or appalling wrong, than to deliberately deceive a child, and the result of one such deception can never be fully estimated. To the dishonor of some parents we are occasionally asked even in the beginning of the twentieth century to become a party to such an iniquitous practice, but no dentist of any self-respect or manhood will ever enter into such a conspiracy. It is always well, of course, to destroy in the mind of the little patient any sense of fear by making as light as possible of the probable severity of the operation, and by the utmost tenderness and gentleness of demeanor; but to deliberately assure the child that a certain operation will not hurt in the least when it is almost certain to hurt, and worse than this to pretend to be applying some medicament to a tooth and then suddenly seize it with the forceps and extract it is a monstrous and cruel wrong.

Ordinarily the first visit of a child to the dental office should

be so managed, if possible, that no work of a disagreeable nature is undertaken. Mothers should be instructed to bring their children early, even before the necessity seems apparent, so that the child forms the habit of having the teeth examined and gets acquainted with the dentist. Thus, when fillings have to be made the ice is already broken and the way made easier. If the case has been deferred till toothache occurs, and the visit is one of necessity for relief, the only operative procedure undertaken at this time should be merely to stop the pain. A sympathetic and personal interest should be manifest for the little sufferer, and the impression formed at this first visit that the dentist is a kind hearted gentleman and not at all to be feared. When once confidence is attained it will usually be found that most children will tolerate any necessary discomfort in having their teeth cared for provided their pride is appealed to in the proper manner and they are upheld as little men and little women.

But the dentist should have a care not to overtax the courage of a delicate child, and should constantly watch with the keenest eye for signs of wavering or undue nervous tension during an operation. It is sometimes better to do temporary work and retain the confidence of the child than to always attempt permanent operations and thereby run the risk of creating distrust and dread. This is particularly true of operations on the deciduous teeth where the object is more to keep them comfortable for a few years than to do artistic and permanent work.

The materials for filling deciduous teeth are limited to those easy of insertion and not too exacting in their requirements. When cavities occur in the proximal surfaces of the incisors they are usually better managed with oxyphosphate of zinc than with anything else. They are ordinarily shallow, and the fact that they are frequently quite sensitive prevents the operator from giving them any appreciable retentive form. Cement can therefore be used when nothing else will remain in place. These teeth do not often call for much operative interference owing to their early loss to make way for the permanent incisors, but with the deciduous molars the case is different. They remain four or five years after the incisors are gone, and the problem of saving them when they decay is sometimes exceedingly difficult. They should be given early and frequent attention when the mouth is susceptible to caries, with the aim always of checking the disease and keeping the teeth comfortable for mastication. The reason for this is not only that the child shall be enabled to properly prepare the food for digestion during these early years, which of itself is very

important, but that proper habits of mastication are established at this impressionable age. If the deciduous molars are allowed to decay and become sensitive the child involuntarily forms the habit of bolting the food without proper mastication, and this habit once formed is likely to persist through life. There are many people today who do not masticate their food to the extent which their present masticating apparatus would warrant simply because they have formed the bad habit of bolting their food during youth.

Simple cavities in the occlusal surfaces of these teeth are not difficult to manage. They may be filled with oxyphosphate of zinc, oxyphosphate of copper, pink base-plate gutta-percha or amalgam, as is indicated in the individual case. Amalgam is more reliable than either of the others provided a proper preparation of the cavity may be made and it does not reach too close to the pulp, but sometimes we are obliged to temporize with cement or gutta-percha.

The most difficult problem we meet in the management of deciduous teeth is to properly treat cavities occurring in the proximal surfaces of the molars. There are several factors in these cases tending to make them troublesome to control. They are usually sensitive, making them difficult of proper preparation for the retention of amalgam, which is the only permanent material we have for preserving them. Unless fillings are reasonably well anchored in these cavities they are likely to be loosened by mastication, and if we attempt too deep anchorage we endanger the pulp. In fact these teeth do not usually present much area of tooth tissue in which to form a cavity and it takes but little penetration of decay to involve the pulp. It is always best to avoid irritating the pulp if possible, and to this end it is frequently advisable to use some other kind of material than metal to fill them.

Much of the discomfort experienced by children in mastication is due to the packing of food in the interproximal spaces wherever decay has occurred in these surfaces. If cement is used it very rapidly wears away so as to present a space between the teeth and thus invite a lodgment of food. Not only this but frequently we find the teeth drifting slightly apart as the jaw expands preparatory to the eruption of the permanent teeth, all of which increases the difficulty. In cases where amalgam cannot be used and cement is unreliable the patient may be made more comfortable with gutta-percha than any other material, though this is, of course, more or less temporary in its service.

The problem is greatly complicated where two cavities face each other, and in some instances the surest method of making the teeth

serviceable for mastication is to bridge across the interproximal space from cavity to cavity with gutta-percha. This is the only material by which two cavities may be joined in this way on account of the individual movement of the teeth. If a rigid material like cement or amalgam is used the filling will very shortly be loosened from one cavity or the other, but gutta-percha being more or less yielding will accommodate itself to the movement of the teeth without injury. If this plan is followed provision must be made to prevent the gutta-percha from being forced down between the teeth in the interproximal space, and this may be accomplished effectively by placing a metal guard of gold, platinum, or German silver across the interproximal space allowing the ends to rest on the gingival walls of the cavities and building the gutta-percha over it. This protects the gum most perfectly and admits of serviceable mastication without discomfort. As the gutta-percha is worn away it may be renewed from time to time, and although this is at best a temporary operation yet it is in some of these troublesome cases the only procedure by which the teeth may be made serviceable.

In pulpless deciduous molars the case should be treated in the usual way, except that some care should be taken not to introduce medicines which have a disagreeable taste or odor. It is always desirable with children to avoid as much as possible anything which tends to create prejudice against having dental operations performed, and usually these deciduous cases may be brought under control by the use of the essential oils which are less objectionable than some of the more powerful antiseptics.

TREATMENT OF THE PERMANENT TEETH DURING CHILDHOOD.

From the time the permanent teeth begin to erupt at about six years of age till the deciduous teeth are all lost and replaced by permanent ones at about twelve the care of the erupting teeth is a very important consideration, and in mouths where there is great susceptibility to decay of the teeth the problem of saving the permanent ones is sometimes perplexing.

When the incisors begin to decay in the proximal surfaces shortly after their eruption it is seldom that we can insert permanent fillings in them at once. It is, of course, better if this can be done, thus making one operation sufficient and creating in the mind of the patient the impression that dental operations are effective when properly performed. But there are many patients who lack the fortitude at such a tender age to go through the necessary tension to have thorough

work performed, and it is better to make several operations on the one tooth at different times and preserve the courage of the child than to attempt a perfect piece of work at the outset and break the spirit of the patient, thus creating a dread of having dental work done.

But let it be borne in mind that just so soon as it is found possible to have the temporary fillings replaced with permanent ones this should be done. In these susceptible cases the teeth can never be made too secure against decay even by the very best work the operator is capable of, and it is therefore well not to trust to temporary work longer than necessary. But in this connection it should be said that the attempt to use gold before the child is sufficiently under control to admit of doing a perfect piece of work will as certainly lead to failure as will the use of other materials more temporary in their nature. We must have a good technique in any operation calculated to be permanent and the requirements of gold in this respect are more exacting than for any other filling. In some instances we may employ inlay work in children's teeth before they will tolerate the exactions of gold foil filling and thus obtain a better result than by the use of any of the plastic materials.

Each case should be studied carefully with the idea of learning the temperament of the child and knowing how to gain such control as shall permit of the best service. The practice of dentistry in its highest attainment is a constant study of conditions, conditions of the mind, conditions of the teeth, conditions of the surrounding parts—all of which materially affect us in the treatment of every case. And in this connection there is no other one thing of equal importance in the ultimate saving of the teeth and the maintenance of a healthy mouth than the establishment during these early years of the correct principles and practice of oral hygiene. It is not the province of the present chapter to go fully into this phase of the question, but it should be said in passing that no dentist is doing his full duty to the rising generation who fails to impress upon his young patients the importance of properly caring for the teeth and gums, or who does not give full instructions as to how this should be done. This should also be followed by a constant surveillance to see that his instructions are carried out.

A very necessary consideration in the treatment of children's teeth is to watch carefully the condition of the first permanent molar. This tooth is one of the most important in the entire arch. It is the chief standard bearer of the jaws during the period when the deciduous teeth are being lost and the other permanent teeth are coming

into place, and if lost early it invariably results in the jaws dropping closer together than normal which detracts materially from the force of character of the face. If it is lost subsequently to the eruption of the second permanent molar and the bicuspids it produces a tipping of the other teeth into the space so as to disarrange the occlusion. No arch is ever perfectly normal with the first permanent molar missing, and even in those cases where the space has entirely closed by the approach of the second molar and bicuspid and where the occlusion seems good from the buccal aspect it will be found defective if models are made and a careful examination is given the lingual aspect.

In view of its early eruption it is peculiarly susceptible to decay, and should therefore be watched most carefully and preserved by filling. Where it has been extensively broken down by caries before it comes to the dentist it may usually be restored to full functional usefulness by the inlay method, and no pains should be spared to place it in a condition of health and service.

As has already been stated, one of the chief functions of the dentist in his treatment of children is to educate them to the importance of properly caring for the teeth, and in respect of the first permanent molar it may be said that this education should begin with the parent before the child is of responsible age so that the frequent error of mistaking this tooth for a deciduous one and allowing it to go by default should not be committed. Parents should be instructed to bring their children to the dentist not later than the third or fourth year, and then the coöperation of the dentist, the parent and the child should result in every individual growing up with a good, serviceable set of teeth.

CHAPTER XXV.

LOCAL ANESTHESIA.

BY HERMANN PRINZ, M. D., D. D. S.

The elimination of pain during surgical operations is inseparably interwoven with the history of the human race. Forever it has been the aim of those interested in the cure of bodily ills to relieve pain in some empirical manner. These efforts, however, were seemingly so very futile that even as late as 1839 Velpau was led to express his pessimism as follows: "To escape pain in surgical operations is a chimera which we are not permitted to look for in our time." Little did he dream that he stood at the very threshold of the discovery of anesthesia, and that less than a decade later the Nirvana of painless operation would be an accomplished fact.

The discovery of anesthesia is essentially to be credited to the dental and medical profession of the United States; the names of Crawford W. Long, Horace Wells, William T. G. Morton and Chas. T. Jackson are inseparably connected therewith. "If America has contributed nothing more to the stock of human happiness than anesthetics, the world would owe her an everlasting debt of gratitude." (S. T. Gross.)

Anesthesia may be defined as an artificial deprivation of all sense of sensation, and, as a consequence, local anesthesia may be explained as the product of the same phenomenon in a circumscribed area of tissue. The mere absence of pain is referred to as analgesia.

Local anesthesia may be produced by physical or chemical means. Physical means, as practiced in olden times, consisted primarily in nerve compression and the application of cold. The results were very problematic. At present, usually two definite ways are employed to bring about local insensibility—first, the application of substances, topically or by hypodermic injection, which produce local anemia; and second, the hypodermic injection of drugs which act as inhibitors to the sensory fibers.

Local anemia or ischemia, viz., a temporary constriction of circulation, prevents, as it has been experimentally shown, the rapid absorption of fluids which are injected into the affected area. The more important means applied for such purposes are:

1. The Esmarch elastic bandage.
2. The application of cold.
3. The extract of the suprarenal capsule.

Some observers have maintained that local anemia as such produces anesthesia. This, however, is not the case. It is merely an important means to confine the injected anesthetic to the anemic region and thus bring about an increased and prolonged action of the drug, and also to enhance its deeper action. Consequently, the concentration of the anesthetic solution may be of a lower percentage, which of course lessens the danger of intoxication.

For plausible reasons the Esmarch elastic bandage cannot be made use of for dental operations.

Physically reducing the temperature of the body by the application of cold (ice pack, ice and salt mixture, cold metals, etc.) was practiced by the older surgeons. Through the efforts of Sir Richardson, in 1866, this method was placed upon a rational basis by the introduction of his ether spray. To obtain good results, a pure ether (boiling point 95° F.) free from water is necessary. Certain other hydrocarbons possess similar properties in varying degrees, depending upon their individual boiling point. Within recent years, ethyl chlorid also known by many trade names, viz., antidolorine, kelene, narcotile, etc., and methyl chlorid and mixtures of the two in various proportions, known as anestol, anestile, coryl, metethyl, etc., are extensively use in minor oral and general surgery. A pure ethyl chlorid (boiling point 55° F.) is best suited for this purpose; it lowers the temperature of the tissues sufficiently to produce a short superficial anesthesia in a few minutes (it reduces the mercury of the thermometer to 50° F. below zero within 20 seconds). Too rapid cooling or prolonged freezing by methyl chlorid (boiling point —10° F.) or the various mixtures thereof produce deeper anesthesia but such procedures are dangerous. They frequently cut off circulation in the affected part so completely as to produce sloughing (gangrene). Liquid nitrous-oxid gas, liquid or solid carbonic acid, and liquid air, all of which have a boiling point far below zero are recommended for similar purposes; they require cumbersome apparatuses and are extremely dangerous.

Ethyl Chlorid.—Monochlorethane; hydrochloric ether, C_2H_5Cl. "A haloid derivative, prepared by the action of hydrochloric acid gas upon absolute alcohol." At normal temperature, ethyl chlorid is a gas, under a pressure of two atmospheres it condenses to a colorless, mobile, very volatile liquid, having a characteristic, rather agree-

able odor and a burning taste. It boils at about 55° F.; it is very inflammable, burning with a smoky green edged flame. It is stored in sealed glass or metal tubes and when liberated at ordinary room temperature (70° F.) it evaporates at once. In commerce it is supplied in plain or graduated glass tubes of from 3 to 60 grams capacity or stored in metal cylinders holding from 60 to 100 grams or more. To remove the ethyl chlorid from the hermetically sealed smaller tubes, the neck has to be broken off, while the larger glass and metal tubes are provided with suitable stopcocks of various designs to allow definite amounts of the liquid to be released.

Mode of application: For the extraction of teeth, immediate removal of the pulp, opening of abscesses and other minor operations about the oral cavity the tube should be warmed to about 75 degrees by placing it in hot water and its capillary end should be held about 6 to 10 inches away from the field of operation. The distance depends upon the size of the orifice of the nozzle; complete vaporization should always be produced. The Gebauer tube is fitted with a spray nozzle, which shortens the distance to one to two inches and is especially well adapted for dental purposes. The stream is directed upon the tissues until the latter are covered with ice crystals and have turned white. "For the extraction of teeth, the liquid should be projected directly upon the surface of the gum, as near to the apex of the root as possible, but care should be taken to protect the crown of the tooth on account of the painful action of cold on this part." Tissues to be anesthetized should be first dried and well surrounded by a film of vaseline or glycerin and protected by cotton rolls and napkins to prevent the liquid from running in the throat. Let the patient breath through the nose; occasionally light forms of general anesthesia are induced by inhaling the vapor. On account of the difficulty of directing the stream of ethyl chlorid upon the tissues in the posterior part of the mouth, it is not successfully applied in those regions. The intense pain produced by the extreme cold prohibits its use in pulpitis and acute pericementitis. To anesthetize the second and third branch of the fifth nerve, it is recommended to direct the stream of ethyl chlorid upon the cheek in front of the tragus of the ear; the author has not seen any good results from such a procedure. Caution should be exercised in using ethyl chlorid near an open flame or in conjunction with the thermo-cautery; severe burns have resulted by setting the inflammable vapor on fire.

Within the last decade the active principle of the suprarenal cap-

sule has demanded extensive comments in therapeutical literature. It has been isolated by a number of investigators under different names, viz., epinephrin by Abel (1897), suprarenin by Fuerth (1898) and adrenalin by Takamine and Aldrich (1901), and many other names are given to these compounds, viz., paranephrin, suprarenalin, hemostasin, etc., but we wish it to be understood that whenever we refer to adrenalin the hydrochlorid of the alkaloid of the suprarenal capsule is meant. Adrenalin is a grayish-white powder, slightly alkaline in reaction and in the dry form perfectly stable. It is sparingly soluble in cold, more soluble in hot water, insoluble in ether or alcohol. The preparation which is employed mostly for therapeutical purposes is a solution of adrenalin in physiological salt solution, 1:1000, to which preservatives, such as small quantities of chloretone, thymol, etc., are added. Adrenalin solutions do not keep well; on exposure to air they are easily oxidized, becoming pink, then red and finally brown. When this stage is reached the physiological property of the adrenalin is destroyed. When the solution is further diluted, it becomes practically worthless after twenty-four hours. When adrenalin is injected into the tissues, even in extremely small doses, it temporarily raises the arterial blood pressure, acting as a powerful vasoconstrictor by stimulating the smooth muscular coat of the blood vessels and thus produces local anemia. Large doses finally reduce the blood pressure and heart failure results. The respiration at first quickly increases, but slows down and finally stops with the expiration. The action is largely confined to the peripheral vessels. Adrenalin is destroyed by the living tissue cells; the body rids itself of the poison in some unknown manner. While adrenalin does not possess local anesthetic action, it increases very materially the effect of certain anesthetics when they are injected into the tissues. This fact was brought out by Braun, of Leipsic, in 1902, who, by his classical researches brought local anesthesia to a rational basis. It is claimed that secondary hemorrhage frequently follows after the anemia produced by the adrenalin has subsided and that the tissues themselves suffer from the poisoning effects of the drug, resulting in gangrene. Such results are only produced by the injection of too large quantities of the drug. The prolonged anemia will give way to a dilation of the blood vessels and if the tissues are too long deprived of circulation we are able to understand why sloughing will result. Small doses of adrenalin have no effect upon the tissues as such or upon the healing of a wound. Palpitation of the heart and muscle tremor which we occasionally notice when we first used this drug, were the direct

result of too large doses. For dental purposes, viz., the injection into the gum tissue, the dose should be limited to 1 to 2 drops of the adrenalin chlorid solution (1:1000), diluted with one or more cubic centimeters of physiological salt solution. For ordinary purposes, one-half drop is quite sufficient. Concentrated solutions are dangerous, the injection of 6–8 drops diluted with 6 c.c. of a 1 per cent cocain solution has produced death in a weakly girl.

According to more recent therapeutical conceptions it is generally recognized that a drug or combination of drugs which simultaneously produce local anemia and inhibition of the sensory nerves in a circumscribed area of tissue is the logical solution of the question of local anesthesia. Certain important factors, however, relative to the physiological and physical action of the solution, employed for hypodermic injection, upon the cell govern the successful application of such methods. It is of prime importance, therefore, to comply with the laws regulating the absorption of injected solutions, viz., osmotic pressure.

If we separate two solutions of salt of different concentration by a permeable membrane, a continuous current of salt and water results, which ceases only after equalization of the density of the two liquids, viz., equal osmotic pressure (according to Boyle–vant Hoff's law), is established. The current passes in both directions, drawing salt from the stronger to the weaker solution and water vice versa until osmotic equilibrium is obtained. The resultant solutions are termed isotonic (De Vries). In organized nature, these osmotic interchanges play an important factor in regulating the tissue fluids. The life of the cell depends upon the continuous passage of these tissue fluids, which furnish the nutrient materials, consisting of water, salt and albumin. These chemicals are normally present in certain definite proportions. A further important factor teaches us that all aqueous solutions which are isotonic possess the same freezing point. This law of physical chemistry has materially simplified the preparation of such solutions. The freezing point of human blood, lymph, serum, etc., has been found to equal approximately 0.55° C., which in turn corresponds to a 0.9 per cent sodium chlorid solution. Such a solution is termed a physiological salt solution. A slight deviation above and below the normal percentage of the solid constituents is permissible. When physiological salt solution is injected into the tissues in moderate quantities neither swelling nor shrinkage of the cell as such occurs; therefore, no irritation results, and in consequence no pain is felt. If, on the other hand, simple distilled water is injected,

a superficial anesthesia only is produced; the injection itself is very painful and acts as a direct protoplasm poison.

With the introduction of cocain into therapeutics, local anesthesia achieved results which were beyond expectation, it opened new pathways and it has robbed dental operations of their horrors.

Cocain Hydrochlorid.—It is the principal alkaloid obtained from cocoa leaves (erythroxylon coca) a large shrub indigenous to tropical South America. It appears in colorless crystals, flaky, lustrous leaflets or white powder; it is odorless, has a saline, slightly bitter taste and produces when placed upon the tongue a tingling sensation followed by numbness. At ordinary temperature it is soluble in about one-half part of water, about three parts of alcohol and glycerin, also soluble in chloroform, ether and olive oil. Its aqueous solution is neutral to litmus paper. Prolonged heating of the salt or its solution produces decomposition of the chemical into methyl alcohol, benzoic acid and ecgonin. Solutions of cocain are unstable, they should preferably always be made fresh when wanted. Cocain hydrochlorid is incompatible with alkali hydrates or carbonates, salicylates, benzoates, bromids and iodids, the mercury salts and silver nitrate. As early as 1860, Niemann noted the fact that cocain when applied to the tongue produced local anesthesia; later investigations, especially those of Von Anrep (1879) were not fully appreciated until Carl Koller, of Vienna, later of New York, brought it before the medical profession in a paper read before the Congress of Ophthalmologists at Heidelberg in 1884. Cocain is a general protoplasmic poison, possessing a selective power for the sensory nerve elements. It paralyzes the nerve cells, fibers and endings and produces vaso-constriction at the place of its application. The respiration is at first accelerated, later it diminishes; respiratory paralysis is the usual cause of death. The pulse is quickened, later it is slow and weak; at first, the blood pressure rises, then falls and collapse results. Local anesthesia, according to Preyer's conception, is produced as follows: Cocain possesses a definite affinity for the living protoplasm of the nerve cell; it enters with it into a labile union, thus producing local anesthesia, which lasts until this temporary union is broken up by releasing the chemical, not as the original cocain, however, but as an inert compound of a simpler structure. In other words, the living tissues rid themselves of the poison in some unknown manner. In dead tissue, the injected cocain will suffer no change whatsoever.

No direct antidotes of cocain are known, consequently the treatment of general intoxication is purely symptomatic. Recumbent

position of the body and inhalation of a few drops of amyl nitrite are the first important steps in dealing with collapse, which should be followed in severe cases with small drops of nitro-glycerin and injection of strychnin sulphate, 1-30 of a grain, together with artificial respiration.

The relative toxicity of a given quantity of cocain solution depends upon the concentration of the solution. Reclus and others have clearly demonstrated that a fixed quantity of cocain in a 5 per cent or 10 per cent solution is almost equally as poisonous as five times of the same quantity in a 1-5 per cent solution. From the extensive literature on the subject, we are safe in fixing the strength of the solution for dental purposes at 1 per cent. This quantity of cocain raises the freezing point of distilled water just a little above 0.1° C. To obtain an isotonic solution corresponding to the freezing point of the blood, 0.8 per cent of sodium chlorid must be added. Having thus prepared a cocain solution which is equal to the blood in its osmotic pressure upon the cell wall, it is now necessary to aid the slightly vaso-constrictor power of the drug by the addition of a moderate quantity of adrenalin, thus increasing the confinement of the solution to the injected area by producing a deeper anemia, for the twofold purpose—first, to act as a means of increasing the anesthetic effect of cocain, and second, to lessen its toxicity upon the general system by slower absorption. As stated above, one drop of adrenalin added to 2 c.c. of the isotonic cocain solution is sufficient to produce the desired effect.

A suitable solution for dental purposes may be prepared as follows:

Cocain hydrochlorid,	5 grains
Sodium chlorid,	4 grains
Sterile water,	1 fluid ounce

To each syringeful (30 minims) add one drop of adrenalin chlorid solution, when used.

Ever since the introduction of cocaine into materia medica for the purpose of producing local anesthesia quite a number of substitutes have peen placed before the profession, for which superiority in one respect or another is claimed over the original cocain. The more prominent members of this group are tropa-cocain, the eucains, acoin, nirvanin, alypin, stovain and novocain. None of these compounds with the exception of novocain has proven satisfactory for the purpose in view. The classical researches of Braun have established certain factors which are imperative relative to the value of a local anesthetic. The principal properties of such a chemical must cor-

respond to the following claims: (1) In comparison to its local anesthetic value, it must be less toxic than cocain. The difference of toxicity must be absolute, viz., the quantity of the drug necessary to produce the same anesthetic effect as a definite quantity of cocain must be less toxic to the amount of body weight. (2) The chemical must be absolutely indifferent to the tissues when injected in more or less concentrated solutions. The progress of wound healing must not be interfered with by the solution. (3) The chemical must be readily soluble in water, the solution must be comparatively stable, and it should be possible to sterilize it by simple means. (4) The remedy must be tolerant to the addition of adrenalin without interfering with the vaso-constrictor power of the latter drug. (5) When applied to mucous surfaces ready penetration of the drug is necessary.

Novocain has been recently (1905) discovered by Prof. Einhorn. It is a synthetical product, representing the hydrochlorid of para-aminobenzoyldiethylaminoethanol; it appears in colorless needle shaped crystals, readily soluble in one part of water and thirty parts of alcohol. Its solution may be boiled without decomposition; it reacts neutral to litmus paper. In general, it is incompatible with caustic alkalies and carbonates and the alkaloid reagents. Novocain possesses the same anesthetic power upon peripheral nerves as cocain. In one-quarter per cent solution it is sufficiently powerful to anesthetize even large nerves, viz.: it is equal in its anesthetic potency to any of the known local anesthetics. Pharmacologists (Biberfeld, Heineke and Laewen) have shown that novocain is about six to seven times less poisonous as compared with cocain.

Novocain fully corresponds to every one of the above claims. Its toxicity is six to seven times less than cocain, it does not irritate in the slightest degree when injected, consequently, no pain is felt from its injection, *per se;* it is soluble in its own weight of water; it will combine with adrenalin in any proportion without interference of the physiological action of the latter and it will be readily absorbed by the mucous membranes. The studies of Biberfeld and Braun brought to light another extremely interesting factor concerning the novocain-adrenalin combination. Both experimentors, working independently of each other, observed that the adrenalin anemia on the one hand and the novocain anesthesia on the other hand were markedly increased in their total effect upon the tissues. Consequently a smaller quantity of this most happy combination is required to produce the same therapeutical effect as a larger dose of each individual drug would produce when injected separately. The injection of a solution of

the combined drugs is precisely confined to the injected area; general effects are therefore rarely produced.

As stated above, the relative toxicity of a given quantity of cocain in solution depends upon its concentration; this same peculiarity is not shared by novocain. The dose of novocain may be safely fixed at one-third of a grain for a single injection. For dental purposes, a 2 per cent solution is preferably employed; as much as 3 grains of a 2 per cent solution in combination with adrenalin has been injected without any ill results. For the purpose of confining the injected novocain to a given area, the addition of adrenalin in small doses on account of its powerful vaso-constrictor action is admirably adapted. It is *the* important factor which prevents the ready absorption of both drugs and consequently nullifies poisonous results. An injection of ten drops of a 2 per cent solution of novocain labially into the gum tissue produces a diffuse anesthesia lasting approximately 20 minutes, the same quantity with the addition of a 1-1500 grain of adrenalin chlorid increases the anesthetic period to about one hour and localizes the effect upon the injected area.

A suitable solution of novocain for dental purposes may be prepared as follows:

Novocain,	10 grains
Sodium chlorid,	5 grains
Distilled water,	1 fluid ounce. Boil.

To each syringeful (30 minims) add one drop of adrenalin chlorid solution when used.

Ready made solutions of cocain and, to some extent, of novocain will not keep when frequently exposed to the air. A perfect sterile solution may be made extemporaneously by dissolving the necessary amount of cocain or novocain in tablet form in a given quantity of boiled distilled water. A suitable tablet may be prepared as follows:

Novocain,	$\frac{1}{3}$ grain
Adrenalin chlorid,	$\frac{1}{1500}$ grain.
Sodium chlorid,	$\frac{1}{5}$ grain.

One tablet dissolved in 15 minims of sterile water makes a two per cent solution of novocain for immediate use. A small glass dish and a dropping bottle constitute the simple outfit.

THE TECHNIQUE OF THE INJECTION.

Various methods of injecting the fluid into the gum tissue are in vogue. For convenience sake, we may be permitted to divide them into:

The injection about the root of a single tooth.

The injection by infiltration near the gum fold.

The injection into the hard tissue of the tooth, known as pressure anesthesia.

Much of the success of the injection depends upon a good working hypodermic syringe, a fine sterile needle, a perfect technique of the injection, and last, but not least, a good sound judgment of the prevailing conditions.

Before starting any surgical interference in the mouth, the field of operation should be cleansed with an antiseptic solution. The syringe is filled by drawing the solution up into it; invert the syringe and push the piston until the first drop appears at the needle point. This precaution prevents the injection of air into the tissues. The injection about the root of an anterior tooth is best started by inserting the needle midway between the gingival margin and the gum fold. Nothing is more dreaded by the patient than this first puncture; a small, very sharp needle causes very little pain. The pain may be entirely obviated by holding a pledget of cotton saturated with the prepared solution upon the gum for a minute or two or by applying a very small drop of phenol upon the point of puncture. The needle opening faces the bone, the syringe is held in the right hand at an acute angle with the long axis of the tooth while the left hand holds the lip and the cheek out of the way. After puncturing the mucosa, a drop of the fluid is deposited in the tissue, and further injection is painless. Slowly force the needle towards the apex of the tooth, depositing the fluid on its upward and return trip. The continuous slow moving of the needle prevents injecting into a vein. After removing the needle place the finger-tip over the puncture and exert slight pressure. A circular elevation outlines the injected area. No wheal should be raised by the fluid, it indicates superficial infiltration and consequently failure. As the liquid requires time to pass through the bone lamella and to reach the nerves of the pericemental membrane and the pulp, from five to ten minutes should be allowed before the extraction is started. The length of time depends upon the position of the tooth. The six anterior teeth usually require a labial injection only, the bicuspids and molars require both, a buccal and a lingual injection. For anatomical reasons, the lower molars present the greatest obstacles to a successful injection. It may be best accomplished by injecting the fluid buccally into the tissue near the gum fold, holding the syringe in a more horizontal position and lingually by using a curved needle. After anesthetizing the tissues buccally, the bone lamella may be

penetrated by a small drill and the injection repeated through this drill hole. Occasionally it is possible to insert the needle between the tooth and the alveolar wall into the pericemental membrane.

The injection into highly inflamed areas as we find in acute diffuse and acute purulent pericementitis is very painful; the engorged tissues will not tolerate a further infiltration, the fluid escapes into the mouth without producing any results. Careful infiltration of the sound tissues about the affected tooth by making a distal and mesial injection usually produces successful anesthesia.

If two or more teeth are to be removed on one side of the jaw, the injection by means of infiltrating the area near the gum fold is to be preferred. It is advisable to use a one-half inch needle for this purpose, so as to reach a larger field with a single puncture. The fluid must be deposited under pressure close to the bone; the further procedures are analogous to the method as outlined above.

By pressure anesthesia, pressure cataphoresis, pericemental anesthesia or contact anesthesia, as the process is variously termed, we understand the introduction of a local anesthetizing agent in solution by mechanical means through the dentin into the pulp for the purpose of rendering this latter organ insensible to pain. Simple hand pressure with a suitable instrument, the hypodermic syringe or the so-called high pressure syringe is recommended for such purposes. Before describing the modus operandi of the various methods, the histological structure of the dentin should be briefly recalled. Dentin is made up of about 72 per cent of inorganic salts, about ten per cent of water and an organic matrix constituting the remaining per cents. The dentin is perforated by a large number of tubules, radiating from the pulp cavity more or less wave-like towards the periphery, where they branch off forming a deltoid network. The dentinal tubules are filled with the processes of the odontoblasts and are known as Tomes' fibers. The odontoblasts form a continuous cover over the pulp. The dentinal fibrils are protoplasmic in their nature; normally, they do not carry sensation in the sense of the word as we understand this term as attributed to a nerve fiber; we can cut, file, or otherwise injure sound dentin without the slightest inconvenience to the patient. When the fibers have become highly irritated, the mere touch may at once produce a paroxysm of pain.

Regarding the principles of pressure anesthesia, it should be remembered that we cannot force a liquid through healthy dentin by a mechanical device without injury to the tooth itself. If a cocain solution is held in close contact with the protoplasmic fibers of the dentin, the

absorption of cocain takes place in accordance with the law of osmosis. The imbibition of the anesthetic is enhanced by employing a physiological salt solution as a vehicle. On the other hand, living protoplasm reacts unfavorably against the ready absorption of substances by osmosis for two reasons: First, its albumin molecule is relatively large and not easily diffusible, and second, as an integral part of its life it possesses "vital" resistance toward foreign bodies. These latter factors are sufficiently demonstrated by the fact that it is almost impossible to stain living tissue. Dehydration of the protoplasm increase the endosmosis of the anesthetic solution markedly.

When we apply the same "pressure" anesthesia upon carious dentin, the above statements do not hold good. We are able to press fluids quite readily through carious dentin. We must bear in mind that such dentin has been largely deprived of its inorganic salts, leaving an elastic spongy matrix in position. By drying out this dentin and then confining the anesthetic solution under a suitable water-tight cover, the pressure applied by the finger is quite sufficient to obtain the desired results. Colored fluids may be readily pressed through such dentin and even stain the pulp.

In teeth not fully calcified and in so-called soft teeth, pressure anesthesia is more readily obtained while, according to Zederbaum, the process fails in "teeth of old persons, teeth of inveterate tobacco chewers, worn, abraded and eroded teeth, teeth with extensive secondary calcific deposits, teeth whose pulp canals are obstructed by pulp nodules, teeth with metallic oxides in tubules, teeth with leaky old fillings, badly calcified teeth—mainly all from one and the same cause, namely, clogged tubuli. In most cases no amount of persistent pressure will prove successful."

From the foregoing it will be observed that the so-called high pressure syringes possess little merit relative to pressure anesthesia. The pressure which can be produced by a good working all-metal syringe, holding it between the index and middle fingers and forcing the piston with the thumb, amounts to 250 to 300 pounds in the average man. The pressure required in pressure anesthesia to produce a perfect contact is usually much less than the above force.

METHOD OF ANESTHETIZING THE PULP.

1. The pulp is wholly or partially exposed: Isolate the tooth with the rubber dam and clean it with water and alcohol. Excavate the cavity as much as possible and if the pulp is not exposed, dehydrate with alcohol and hot air. Saturate a pledget of cotton or a piece of

spunk with a concentrated cocain or novocain solution, place it into the prepared cavity and cover it with a piece of vulcanizable rubber and with a suitable burnisher apply slowly, increasing continuous pressure from one to three minutes. The pulp may now be exposed and tested. If it is still sensitive, repeat the process. Loeffler states that "this pressure may be applied by taking a short piece of orange wood, fit it into the cavity as prepared and direct the patient to bite down upon this with increasing force. In this way we can obtain a well-directed regulated force or pressure and with less discomfort to the patient and operator." Miller described this process as follows: "After excavating the cavity as far as convenient and smoothing the borders of it, take an impression in modeling compound, endeavoring to get the margins of the cavity fairly well brought out; put a few threads of cotton into the cavity and saturate them thoroughly with a five to ten per cent solution of cocain, cover this with a small bit of rubber dam and then press the compound impression down upon it. We obtain thereby a perfect closure of the margin, so that the liquid cannot escape and one can then exert pressure with the thumb sufficient to press the solution into the dentin."

2. The pulp is covered with a thick layer of healthy dentin: With a very small spade drill bore through the enamel or direct into the dentin at a most convenient place, guiding the drill in the direction of the pulp chamber. Blow out the chips, dehydrate with alcohol and hot air and apply the syringe provided with a special needle making as nearly as possible a water-tight joint. Apply slow continuous pressure from two or three minutes. With a round bur the pulp should now be exposed and if still found sensitive the process is to be repeated.

Recently a method has come into vogue which allows successful anesthetization of the pulp by injecting the anesthetic solution around the apex of the tooth. The spongy alveolar process, which contains lymph channels, allows the ready penetration of the fluid. The injection should be made close to the bone pushing the needle slowly toward the apex while the fluid is deposited drop by drop. No wheal should be raised by the injection, otherwise the benefits of the pressure from the dense gum tissue is lost.

According to Hertwig, the protoplasm of the cell primarily transfers irritation and secondly transmits absorbed materials. Therefore, the anesthetic solution has to pass through the entire dentinal fiber before the nerve tissue of the pulp proper is reached. Consequently a certain period of time is required before the physiological effect of the anes-

thetic is manifested. This period of latency is dependent upon the thickness of the intermediate layer of dentin or bone. The successful anesthetization of the pulp depends largely upon this most important factor of allowing sufficient time for the proper migration and action of the drug.

A good hypodermic syringe which answers all dental purposes equally well is an important factor in the successful techinque of the injection. The injection into the dense gum tissue frequently requires from 15 to 30 or even more pounds of pressure while in pressure anesthesia 200 to 300 pounds are often applied. After testing most of the dental hypodermic syringes and pressure instruments as offered in the dental depots within the last five years by means of the pressure gauge and in clinical work, subjecting the syringes to a routine wear and tear, we find that an all-metal syringe gives the best all-around service. It should hold about 30 minims. The Manhattan platinoid syringe can be recommended. If a glass syringe is preferred, the "Sub-Q" will answer the purpose. The hypodermic syringe requires careful attention. It is not necessary to sterilize it by boiling after each use unless contaminated with blood or pus; the simple washing with alcohol and careful drying is sufficient. The piston rod should be covered with a very thin film of carbolated vaseline. If the syringe is boiled, all the washers should be removed. Keep it in a covered glass or metal case; leather or felt lined boxes afford breeding places for bacteria. Dental hypodermic needles must be strong; they should be of re-enforced steel, 27 B. and S. gauge and provided with a razor edge point. The needle itself should measure a quarter of an inch. For infiltration anesthesia, one-half inch needles are necessary. Curved needles are often essential in reaching the posterior teeth. The "Schimmel" needles are excellent, they do not fit every syringe, however. For pressure anesthesia special needles are required. They may be bought at the depots or quickly prepared by grinding off the steel needle at its point of re-enforcement. The sterile needles should be kept in a well corked glass tube. They should be sterilized by boiling after each use in a 2 per cent lysol or cresol solution, dried with the hot air syringe and immediately transferred to a sterile glass tube. Sloughing resulting from an injection is, in the majority of cases, due to septic infection from a dirty needle.

For reference to the administration of general anesthetics see chapter on The Extraction of Teeth.

CHAPTER XXVI.

THE EXTRACTION OF TEETH.

BY FERDINAND J. S. GORGAS, A.M., M.D., D.D.S.

The extraction of teeth, although usually regarded as a minor surgical operation, is, nevertheless, an operation that frequently presents great difficulties, and is, perhaps, more often performed than any other in surgery. To successfully extract teeth requires an accurate knowledge of the histology, anatomy, and physiology of these organs, and the structures in direct relationship with them. The anatomy referred to, denominated "dental anatomy," includes that part of the science of organic structure which relates to the bones of the head, especially the jaws; the origin and distribution of the vessels and nerves supplying the dental tissues with blood and sensation; also a knowledge of the muscles concerned in moving the lower jaw, as well as those which are instrumental in producing the varied facial expressions.

As the teeth are of dermal origin—morphological appendages of the skin, and compared with such tissues as hair and nails—the origin and development of their hard structures, viz., enamel, dentin, and cementum, should be well understood.

The teeth, as before stated, being dermal appendages, are not a part of the osseous system, and the science of embryonic evolution teaches that they are inserted in sockets, as is common with all large teeth, and also that they have a strong attachment. In the human subject all the teeth are imbedded in well-developed alveolar cavities of the superior and inferior maxillary bones, their function being to seize, bite, and masticate the food.

The enamel is derived from the octoderm, differing in this respect from bone, which is a product of the mesoderm. The enamel covering the exposed portion, or crown, of the tooth, being its protective covering, is the hardest structure in the body, and is not, like bone, regenerated. Its structural elements are enamel rods or prisms, and interprismatic or cement substance, which holds the rods or prisms together. When fractured, the tissue separates along the cemental line—this is known as the cleavage of the enamel.

The dentin is derived from the mesoderm, and constitutes the body of the tooth, determines its form, and is similar, in respect to its origin,

to bone. The structural elements of the dentin are minute canals—tubules, and intertubular substance, the canals radiating from a central cavity which contains the pulp of the tooth.

The cementum, which covers the root of the tooth and incloses the dentin, at the gingival border or neck of the tooth, slightly overlapping the enamel, is a variety of bone tissue, destitute, however, of the Haversian canals common to bone, but contains lacunæ and canaliculi like bone. The cementum is composed of parallel lamellæ of bone tissue, small vessels penetrating these thin plates, while other vessels, derived from the pulp, pass through the cementum in the opposite direction. Fibers from the investing membrane of the root of the tooth—pericemental membrane, and which resemble the fibers of Sharpey in bone—are firmly attached to the cementum, and furnish a medium of connection by which the tooth is securely held in its alveolar cavity; they also account for the resistance offered by the tooth to its forcible removal by the forceps.

The pericemental membrane lines the alveolar cavity and surrounds the root of the tooth. Its cellular elements are fibroblasts, osteoblasts, osteoclasts, and epithelial cells, the latter being located between the fibers of the membrane.

The fibers of the pericemental membrane, formed and renewed by the fibroblasts, extend into the cementum and have a transverse direction, being attached at one extremity to the cementum of the root of the tooth, and at the other to the bony wall of the alveolar cavity. Resembling Sharpey's fibers of bone, these fibers of the pericemental membrane are white and inelastic, their function being to increase and renew the fibrous tissue of the membrane by which the tooth is supported in place.

This fibrous tissue consists of two varieties, one of which is coarse and radiating, and forms the bulk of the tissue, and by its strength firmly secures the tooth; the other variety is fine and interlaces with the coarse variety, being connected with the blood vessels permeating the tissue. From the gingival portion of the cementum, the fibers of the pericemental membrane pass horizontally, some of them connecting with the membrane of adjoining teeth, and others passing into the connective tissue of the adjacent mucous membrane, thus giving hardness to the gums. The pericemental membrane is richly supplied with blood, some of the vessels entering the membrane near the apex of the root, others from the Haversian canals, while a third supply is derived from the mucous membrane of the gum near the gingival border.

The teeth, being of dermal origin, are attached by insertion into well-developed cavities in the alveolar processes of the jaws, which are known as alveoli, and which are formed by the outer and inner plates of the alveolar process. The shape, size, and length of the roots of the teeth determine the shape, size and depth of the alveoli. (Fig. 274.) Each alveolus consists of compact bone tissue surrounded by cancellated or spongy tissue, which acts as a cushion against the shocks of mastication. The outer and inner plates of the alveolar process are connected by numerous septa which outline the shapes of the orifice of the cavities of the teeth. Dr. I. Norman Broomell, in his treatise on the "Anatomy and Histology of the Teeth," describes the alveoli as follows (Figs. 275, 276 and 277.): "The first socket, or that next to the mesial surface of the bone, gives support to the central incisor tooth. It forms almost a perfect cone,

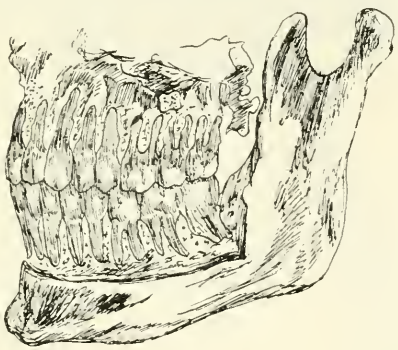

FIG. 274.

and has an average depth of almost half an inch. Its lower border is circular, and the anterior or labial portion describes a larger circle than the posterior or palatal half. The mesial and distal walls are somewhat flattened. The second cavity proceeding backward from the mesial line, supports the lateral incisor tooth. It is also conic, but much smaller than the preceding. It is seldom over $\frac{3}{8}$ to $\frac{5}{16}$ of an inch in depth. It is much flattened on its mesial and distal walls, giving the appearance of an oblong, rather than a round cavity. This socket, as well as that for the central incisor occupies an almost vertical position in the process. Very frequently the socket for the lateral incisor presents a slight distal curve at its upper extremity. The third socket, or that giving support to the cuspid tooth, is much larger and deeper than those previously described. It extends upward, inward, and backward, to the average depth of $\frac{5}{8}$ to $\frac{3}{4}$ of an inch. In transverse section, its labial wall presents a much larger circle than its palatal

margin. The labial and distal walls are much flattened and somewhat convex. The general direction of this socket is to the distal. The socket which supports the first bicuspid is usually divided from mesial to distal by a thin septum of bone, thus forming an outer or

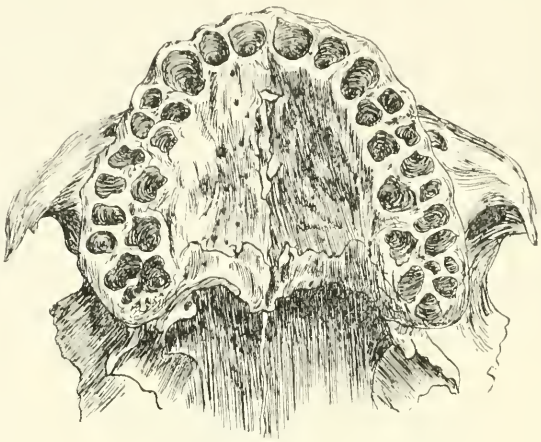

Fig. 275.

buccal socket, and an inner or palatal socket. This division seldom exists to the full depth of the cavity, but usually begins about midway of its length. The lower margin of this socket is oblong or egg-shaped, its outer or buccal portion forming a larger curve than its palatal.

Fig. 276.

The lateral walls are slightly concave or flattened, until the point of separation is reached, when they become more circular, the alveoli above this point becoming cone-shaped.

"It is not uncommon for this socket to be a single cavity, and when

thus formed it resembles a flattened cone, with the buccal and palatal margins rounded.

"The next socket gives support to the second bicuspid tooth, in most instances being a single cavity, but in rare instances it is divided near its upper extremity. In general outline it resembles the socket for the first bicuspid. The socket for the first molar is much larger than any of those previously described; its inferior margin presents a circular outline on its buccal and palatal portions, the former curve being larger than the latter. The mesial and distal walls are flattened and slightly concave. The upper three-fourths of this socket is divided into three separate compartments, being so arranged that two are on the buccal and one upon the palatal side. The septa separating the two buccal cavities from the palatal cavity are heavy and strong, while that placed between the two buccal sockets is thin and frail. The two buccal cavities are usually flattened upon their mesial and distal sides. The palatal socket is larger and somewhat deeper than the buccal, the average depth of all being about ½ an inch.

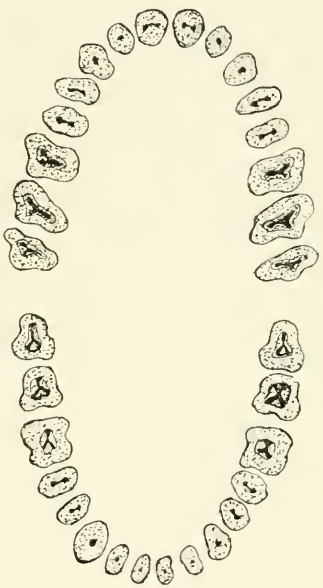

FIG. 277.

"The socket for the second molar is similar in most respects to that for the first molar, except that it is somewhat smaller. The same description might answer for the third molar socket, which in general is similar to the alveoli for the other molars. It is smaller than the second molar socket, and may be a single cavity, or it may be divided into three or more compartments." (Fig. 275.)

The average length of an upper central incisor root in the fraction of an inch is .49; of anupper lateral incisor is .51; of an upper cuspid .68; of an upper first bicuspid .48; of an upper second bicuspid .55; of an upper first molar .51; of an upper second molar .51; of an upper third molar .44; of a lower central incisor .47; of a lower lateral incisor .50; of a lower cuspid .60; of a lower first bicuspid .54; of a lower second bicuspid .56; of a lower first molar .52; of a lower second molar .50; of a lower third molar .36.*

*These measurements are taken from Black's Dental Anatomy.

The upper central incisor has a single root which is of conical form, its labial side more flattened than its lingual. The mesial and distal surfaces of this root are also somewhat flattened, and taper gradually from the base to the apex. The upper lateral incisor has also a single root, which is conical in form, and much more flattened from the mesial to the distal surfaces than the root of the central incisor. At the junction of the root with the crown this root is circular in form, the labial portion forming the segment of a larger circle than the lingual portion; it is generally a straight root. The upper cuspid has also a single root, which is the largest and longest of any of the teeth; it is rounded on the labial and lingual surfaces, the labial forming the segment of a larger circle than the lingual. This root gradually diminishes in size from the neck of the tooth to its apex, and forms a perfect cone. The upper first bicuspid has usually two roots (although sometimes it has but one), which are quite similar in form. The buccal root, however, is usually a little longer than the lingual root, and both roots taper to slender apexes with an inclination to curve at their extremities. The point of bifurcation of these roots is usually some distance above the neck of the tooth.

When this tooth has a single root, it is much flattened from the mesial to the distal surface, indicating a tendency toward the formation of two roots. The second upper bicuspid has usually a single root which is round on the buccal and lingual surfaces, and flattened on the mesial and distal surfaces. The upper first molar has three roots, two buccal and one lingual, the disto-buccal being the smallest, and more rounded than the mesio-buccal root. The lingual root is the largest and longest of the three roots, forming a long curve which ends in a sharp-pointed apex. The upper second molar has also three roots, two buccal and one lingual, which are much smaller than those of the first molar, and are more inclined to converge than to diverge. In general outlines they resemble those of the first molar. The root of the upper third molar, like the crown, is subject to a greater variety of form and number of roots, than any other tooth in the mouth. Normally it has the same number of roots as the two preceding molars, but sometimes as many as four or five are developed. Frequently, the three roots are so fused together as to present a single root with a line of demarcation between them, thus indicating by such an outline the character of the tooth.

The lower central incisor has a single root which is usually smaller than that of any other tooth, and is flattened from the mesial to the distal surface, while its labial and lingual surfaces are rounded. The

broad mesial and distal surfaces of this root, which is straight, taper gradually from the neck to the apex.

The root of a lower lateral incisor is slightly longer, and larger, but, in other respects, is similar to that of the lower central incisor. The root of the lower cuspid is shorter and more flattened on its mesial and distal surfaces than that of the upper cuspid. Its labial and lingual surfaces are convex, and, like that of the upper cuspid, the labial forms the segment of a larger circle than the lingual. The root of the lower first bicuspid is usually single and straight, tapering gradually from the neck to the apex. Its buccal and lingual surfaces are convex, while the mesial and distal surfaces may sometimes be slightly convex, or flattened, and present a slight longitudinal concavity. The root of the lower second bicuspid is also single, and is larger and longer than the root of the lower first bicuspid, and its mesial and distal surfaces are also similar. In some cases it tapers gradually from the neck to the apex, while in others its apex may be blunt and rounded.

The roots of the lower first molar, two in number, situated immediately beneath the mesial and distal halves of the crown, are greatly flattened from the mesial to the distal surfaces, and each is broad at the neck from the buccal to the lingual surface. The mesial root is usually larger and longer than the distal root, the latter having a longitudinal depression which renders it weaker than the mesial root. The distal root is generally straight, and gradually tapers from the neck to the apex, ending in a pointed extremity. The lower second molar has also two roots, a mesial and a distal, which are generally closer together than those of the lower first molar, and are less flattened upon their mesial and distal surfaces, and are more rounded, and taper more gradually from their necks to their apexes, which terminate in rounded ends. The roots of the lower third molars are normally two in number, like those of the lower first and second molars, but frequently a single conical root is presented; in other cases three roots may be developed, which are usually crooked and irregular, with a tendency to diverge from the crown.

Under normal conditions, and if performed on scientific principles, tooth-extraction is not a difficult operation; although cases are sometimes met with, where, owing to abnormal conditions, the operation requires considerable judgment and skill, severely trying the patience of the operator, and the endurance of the patient. It is therefore difficult to formulate special rules which may be literally followed. The axiom, which is an established rule in all surgical procedures, that "every operation is performed quick enough that is performed

well," is particularly applicable to tooth-extraction. A kind manner and a tender regard for the physical and mental suffering of the patients, on the part of the operator, will, in the majority of cases, so impress them, that they will quietly submit to his judgment and skill. It is well never to promise more than it is probable can be performed; and in the case of children, to adhere to the truth, for deception may render a first operation easy of accomplishment, but will react in the case of a second one, and leave such unhappy impressions upon the mind that years cannot entirely efface.

Excessive solicitude should also be avoided upon the part of the operator, and in all cases patience and gentleness should be exercised. The unnecessary display of instruments, together with the preparation of them in the presence of the patient, should also be avoided.

While it is true that the most expressive lamentations by the patient do not invariably indicate acute suffering, yet there are other cases where no outward manifestations of pain may be exhibited, and at the same time the effect on the nervous system be such as to severely tax the vital energy. Hence it is better not to exact too much of a nervous patient, who may heroically nerve herself to quietly endure intense suffering, and show no visible signs of agony.

The question as to "whether or no a tooth is to be extracted" may be answered as follows: "When a tooth or a part thereof can be made of no further use to the patient, or when its retention cannot be accomplished with comfort to its possessor, or when its presence prevents the correction of more important teeth, it should be extracted." Such an answer may embrace all indications for this operation. On the other hand certain conditions which have been termed "contra-indications" against tooth-extraction have been advanced with more or less reason. The following are the more important: The avoidance of such an operation during the periods of menstruation, gestation, and lactation, as it may seriously interfere with these functions. The more prominent of these contra-indications, however, is the condition of pregnancy, as the shock of such an operation as tooth-extraction may, it is asserted, cause miscarriage at certain periods of its existence.

The term "abortion" signifies the expulsion of the product of conception from the womb before the end of the 7th month, and is the great accident of pregnancy.

It is most liable to occur during the 3rd, 4th, and 5th months of gestation, for the reason that at these periods, there is no adhesion between the ovum and uterus. As soon as the chorion and the decidua are developed, separation of these organs becomes more difficult, and

miscarriage is not so prone to occur; hence, the danger of such an accident diminishes as gestation advances.

When it is absolutely necessary to extract a tooth at a certain period in this condition, and palliative measures have failed to give relief, and extraction will prove to be a lighter tax upon the patient's vital powers than a severe and prolonged attack of toothache, and especially if a proneness to abortion exists, the family physician should be consulted, and the dental practitioner be governed by his opinion. The pathological conditions of the uterus which predispose to abortion, comprise all that interfere with the development of the ovum, such as displacement, inflammatory affections of the lining membrane, uterine tumors, disease of the ovaries, rectum and bladder; the most common causes of abortion are to be found in the ovum. An affection which has been regarded as another contra-indication is hemophilia (hemorrhagic diathesis). This condition is characterized by severe bleeding from trivial injuries, and is generally hereditary, and transmitted through the females to their male decendants. It is due to a decrease of coagulability in the blood; also to changes in the vessels, such as may be caused by disease, the vessels becoming so weak so to be unable to withstand the normal pressure. Hemophilia may occur during the course of scurvy, purpura, leukemia, etc. When such a diathesis is present, proper measures should be resorted to for controlling the heart's action and increasing the coagulability of the blood, such as the administration of acetate of lead in two grain doses every two hours, or nux vomica, or aconite, or digitalis, or gallic acid, or chlorid of iron, or the following formula:

℞—Infusi digitalis, ℥ii
Ext. ergotæ, fluidi,
Tincturi of krameriæ, āā ℥j
Dose:—A tablespoonful as required.

Also such styptics for application to the bleeding cavity, as adrenalin chlorid, tannic acid, antipyrin, chloride of iron, powdered subsulphate of iron, orthoform, etc. Extreme debility and nervous depression have also been regarded as contra-indications against tooth-extraction, the latter often resulting from dread of the operation. The pain of an aching tooth may sometimes aggravate the symptoms of an existing disease, or may at least retard recovery, when sedative treatment is indicated, such as the administration of bromid of potassium, or sodium, valerianate of ammonia, etc., with tonics.

The condition of the membranous tissue of the mouth must also be considered, such as erysipelatous inflammation, for example,

owing to its tendency to spread so as to involve the glands and throat, as a result of tooth-extraction. The nervous affection known as epilepsy, characterized by convulsions and loss of consciousness, the existence of which is generally made known by the patient prior to the operation, has also been named as one of the contra-indications against tooth-extraction; but from the fact that proper precautions can be taken to guard the patient against any injury occurring to him during the existence of the paroxysm, this affection need not prevent the performance of the operation.

The extraction of the deciduous teeth requires so little force, owing to the degree of physiological absorption of both their roots and alveolar processes at the period when their removal is required, that it may be considered a simple procedure. Care, however, must be taken not to injure the developing permanent teeth located directly under the deciduous ones. The greatest difficulty met with is the task of gaining the consent of such young patients. A false promise not to hurt will destroy the confidence of the patient in the veracity of the operator, and what the latter may gain by deception at one operation will only increase the difficulty at a subsequent one. The most important matter connected with the extraction of the deciduous teeth, is for the operator to possess an accurate knowledge of the order in which nature proposes to replace these teeth with the permanent ones; for in no instance will any interruption with this order be tolerated, without such results occurring as the irregular arrangement of the teeth of the permanent set. The following is the order of eruption of both the deciduous and permanent teeth:

DECIDUOUS TEETH.		PERMANENT TEETH.	
Central incisors	5 to 8 months	First molars	5 to 6 years
Lateral incisors	7 to 10 "	Central incisors	6 to 8 "
First molars	12 to 16 "	Lateral incisors	7 to 9 "
Cuspids	14 to 20 "	First bicuspids	9 to 10 "
Second molars	20 to 36 "	Second bicuspids	10 to 12 "
		Cuspids	11 to 13 "
		Second molars	12 to 14 "
		Third molars	17 to 21 "

The *first step* in the operation of tooth-extraction is to make a careful examination to determine the location and condition of the tooth to be removed, its relations to the adjoining teeth, and the general state of the mouth; and, if an anesthetic agent is to be employed, the systemic condition of the patient.

The *second step* is to select the proper instruments to be used during the operation. The *third step* is to determine the direction in which the

force it is necessary to employ can be applied in the line of least resistance, owing to the difference in anatomical structure, the number of roots, the class of tooth, and the position of the tooth in the alveolar arch.

The operation itself may also be divided into three stages: 1. The application of the forceps in order to secure a firm hold on the tooth to be removed, which is usually the upper part of the cervical portion or neck (Fig. 274), so that the edges of the beaks of the instrument may be forced between this part of root and the margins of the alveolus; for by thus opening the orifice by expansion, or by a slight fracture of these edges, the removal of a normally formed tooth is greatly facilitated. 2. The application of the required degree of force by which the pericemental attachment of the tooth with its alveolar cavity is loosened. 3. The careful removal of the loosened tooth from its cavity, and from between the jaws and over the lips, in a manner that will prevent injury to the adjacent teeth, and laceration of the lips by the ragged decayed tooth crown; or by the loosened tooth suddenly leaving its cavity, as in the case of a lower tooth, and the forceps fracturing another in the opposite jaw. Hence, the lips of the patient, as well as the fingers of the left hand of the operator holding the lips open, should be protected by a napkin. Each stage of the operation should be completed before beginning the succeeding one, and no movement be made by the forceps more rapidly than the eye can follow. In performing this operation, the object should be the removal of the entire tooth, with as little mutilation of surrounding soft tissues as is possible. The application of three forces is usually regarded as necessary in extracting, namely traction, rotation, and pressure; "traction" is defined as the drawing force, "rotation" is the turning around on an axis or center; "pressure" is the force exerted by one body on another —applied to this operation, it is the force used on a tooth when raising and pushing it from its cavity.

Position of Operator and Patient.—The position of the operator in performing this operation, and also that of the patient, should depend upon the teeth to be extracted—whether upper or lower teeth; whether the teeth are on the right or the left side of the mouth. For extracting the upper teeth, the operator should occupy a position on the right side of the patient, whose head should rest in the depression of the head-rest of the dental chair, the back of which should be lowered at about an angle of forty-five degrees. In such a position the head of the patient is thrown well back, being encircled by the left arm of the operator which rests on the edge of the head-rest, thus giving the head a firm

support by pressure against his breast. The fingers of his left hand are used to distend the lips of the patient, and also to retain a napkin in place, so that injury of the lips may be prevented while the detached tooth is being removed from between them.

For extracting the upper teeth on the right side, the position of the operator should be to the right and a little to the front of the patient, who is seated in the dental chair, with an observance of the directions already given. For extracting the upper teeth on the left side, the position of the operator should be on the right and a little more to the front of the patient, than for the teeth on the right side. For extracting the lower teeth, the operator should occupy a position on the right, but more toward the rear, of the patient, with the palm of his left hand pressed against body of the lower jaw over the cheek, his fingers over the body of the lower jaw, and his thumb depressing the lower lip, and assisting in supporting the jaw. The back of the dental chair, which is lowered, should be almost vertical, permitting the patient to assume a more upright position. A small stool for the operator placed to the rear of the chair, will enable him to overreach the head of the patient, and permit his having more command of his right arm and wrist.

For the successful removal of both upper and lower teeth, it is necessary that the head of the patient should be so firmly supported that the entire force exerted by the operator should be borne by the tooth, and this force so controlled as to prevent injury, either to the adjoining teeth, or to those in the opposite jaw, by a loosened tooth suddenly leaving its cavity.

Instruments Employed for the Extraction of Teeth.—The instruments employed for the extraction of teeth are forceps, elevators, and the screw. There are special recognized forms of forceps adapted to the different classes of teeth, and also other forms which are applicable to teeth presenting abnormal shapes of both crowns and roots. Perhaps the best rule to follow is for the operator, after some experience, to employ those forms with which he is the most successful.

The early dentists employed very uncouth instruments for extracting teeth, and the now almost obsolete turnkey of Garengeo was considered to be a great improvement on the extracting instruments that preceded it. This instrument, the use of which has been productive of many serious accidents, consists of either a straight or bent shaft, and two or more hooks, with a bolster to rest upon the inner surface of the gums over the alveolar cavity of the tooth to be extracted, which forms the fulcrum. After the use of the lancet so separate the gums,

the pointed beaks of the hook are firmly attached to the outside surface of the neck of the tooth, the handle of the key grasped firmly with the right hand, and the tooth raised from its cavity by a firm and steady rotation of the wrist of the operator. With the improved instruments used at the present time, the direction of the force is in the line of the axis of the tooth, while that of the key is made in a lateral direction only.

To perform the operation of tooth-extraction successfully, the operator should be provided with forceps of the best quality, so well tempered that the beaks will spring instead of fracture under the force to which they are subjected, and so shaped as to permit of accurate adjustment without interfering with the adjoining teeth. The beaks should also be so curved as to overreach the crowns of the teeth when their edges are applied to the necks, and thus avoid fractures of the crowns; and so thin and sharp that the use of the gum lancet may be dispensed with in most cases, and permit of the edges of the beaks being introduced between the gum margin and the thin walls of the orifices of the alveolar cavities. A badly adapted forceps presents to the surface to which it is applied but one or two points, which prevent the application of the necessary traction. The handles of these instruments should be wide, and of such a form as will fit the hand of the operator, be perfectly rigid when firmly grasped, and serrated on their outer surfaces to prevent slipping through the hand. A curve on the end of one of the handles is adapted to the little finger of the hand holding the instrument, and materially assists in applying the required force in the case of firmly implanted teeth. The manner of applying and using the forceps may be described as follows: The forceps is firmly grasped in the right hand with the palm of the hand inward and the thumb on the top, with its ball pressed between the handles in the bifurcation, with such force as will regulate and limit the pressure of the beaks after their edges are applied to the portion of the tooth at the neck to be grasped. By using the ball of the thumb in the manner described an increase of the pressure, to a greater degree then is necessary, on the tooth may be avoided without incurring the danger of crushing it.

The first or second finger (according to their length) of the hand holding the forceps should be inserted between the handles near the bifurcation, and employed for separating the beaks, and also to assist in maintaining a firm hold on the instrument. The little finger of the right hand is applied to the curved end at the extremity of the outer handle of the forceps, and, with the serrated outer surface

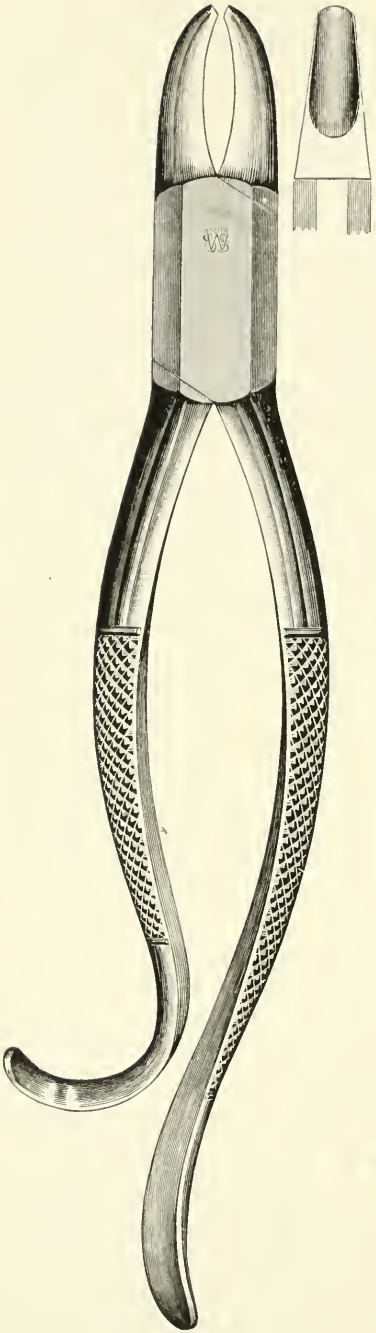

Fig. 278.—Upper Central Incisor Forceps.

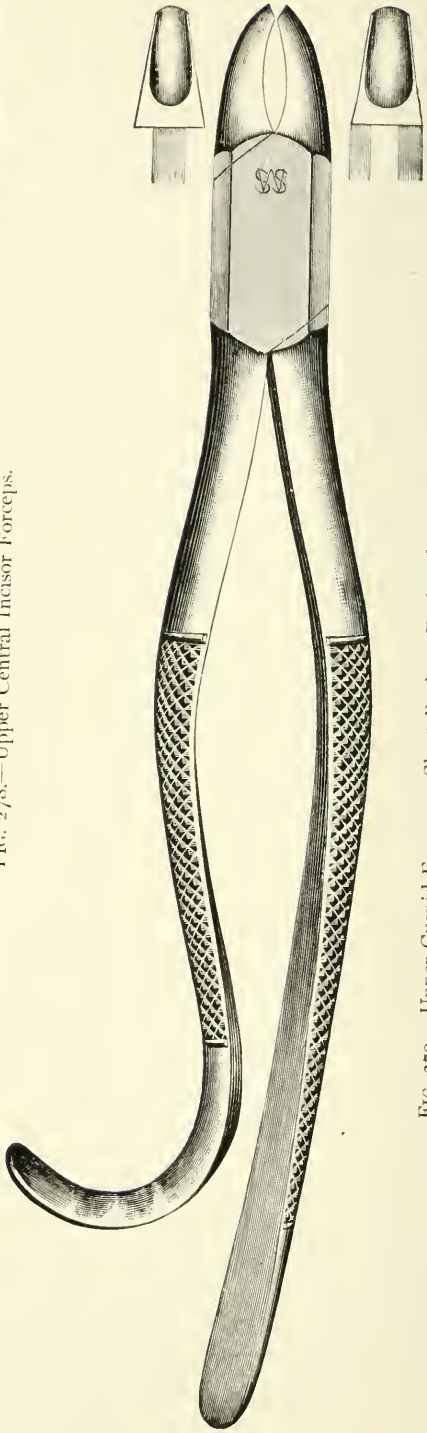

Fig. 279.—Upper Cuspid Forceps. Short Beaks. Designed by Dr. James H. Harris.

of the handles, will prevent the instrument from slipping through the hand. The inner beak of the forceps, when applying it to the neck of the tooth, should be placed in position first, then the outer beak, care being taken to keep these beaks clear of the crown of the tooth, and thus avoid its fracture; then, according to the class of tooth, rotation, or the outward and inward motions are made to break the attachment of the tooth to its alveolar cavity. In some cases, especially of frail roots, it may be necessary to apply forceps with cutting-edged circular beaks to the outside of the outer and inner walls of the alveolar cavity and cut through such walls, in order to obtain a firmer hold on the stronger portions of such roots. What is termed "a cultivated sense of touch" is soon acquired by the operator, when the loosening of a tooth by rotation, or the outward or inward motions (according to the class of tooth) becomes at once apparent; or its yielding in one direction only, when a change in the application of the traction may secure its removal from its cavity with slight effort. Cases have occurred in the practice of the writer where a firmly implanted cuspid tooth has resisted all efforts to remove it, to such a degree as to render it dangerous to apply greater force, when the postponement of the operation to the following day has resulted in its easy extraction, owing to the effects of the inflammation excited in its investing membrane by the previous attempt.

After applying the beaks of the forceps to the neck of the tooth, they should not be pressed together more tightly than is necessary for securing and maintaining a firm hold; otherwise there is danger of fracturing the tooth.

Considering the different classes of teeth, the following rules may be formulated for their removal with the forceps: Beginning with the upper central and lateral incisors, which may be grouped together on account of the similarity of their roots and environment, the force for loosening these teeth should first be applied in the direction of a line drawn through the greatest axis of the tooth at the same time using rotation, as these are single rooted teeth of conical form; should any portion of the alveolar walls of their cavities be in danger of removal by the strong adhesion of their roots, the rotary motion will loosen it.

In all cases the pressure applied should be labial, for the reason that it is in the line of least resistance, the alveolar process on the labial aspect being thinner than on the lingual; another reason is that pressure toward the lingual causes more pain. Labial pressure, when not excessive, will enlarge the orifice of the alveolar cavity, without the danger of fracturing the margins to any degree. (Fig. 278.)

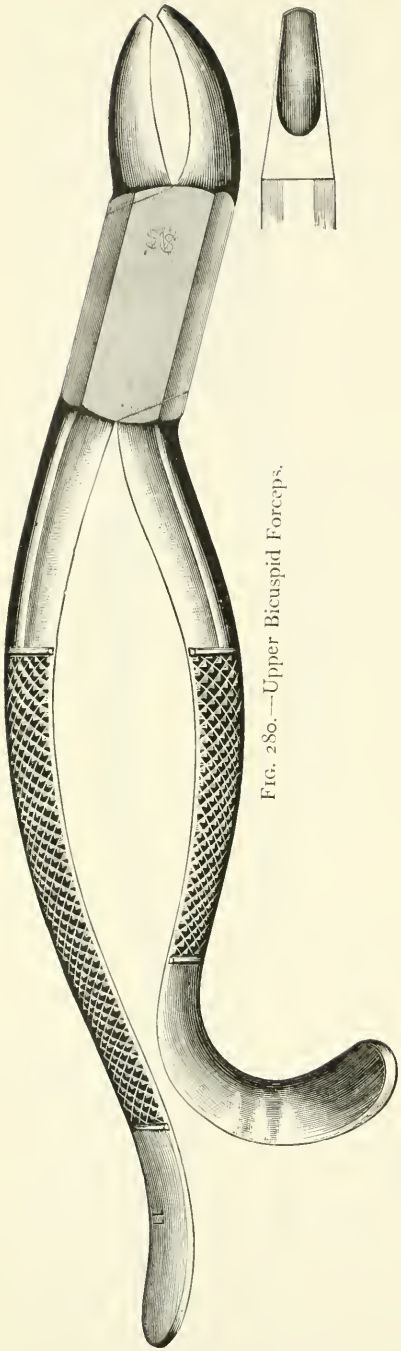

Fig. 280.—Upper Bicuspid Forceps.

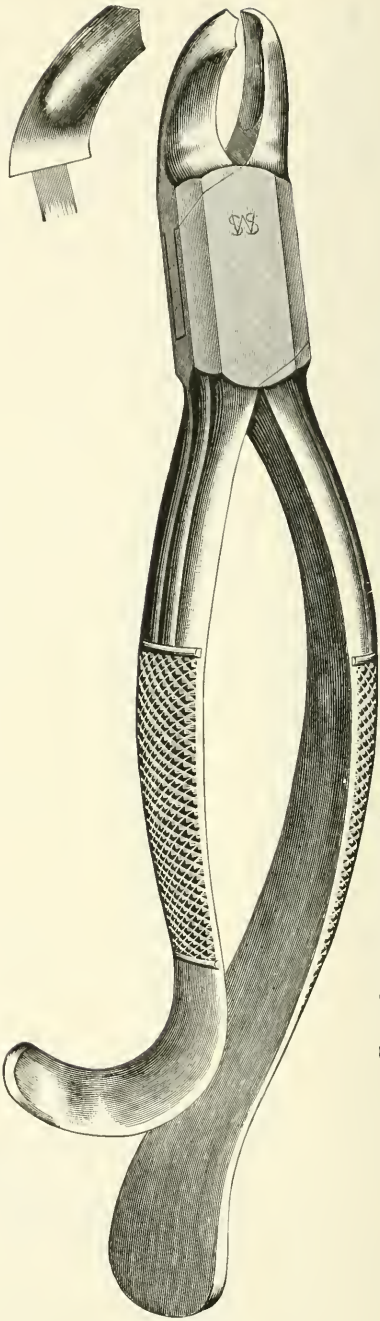

Fig. 281.—Upper Right Molar Forceps. Designed by Dr. Chapin A. Harris.

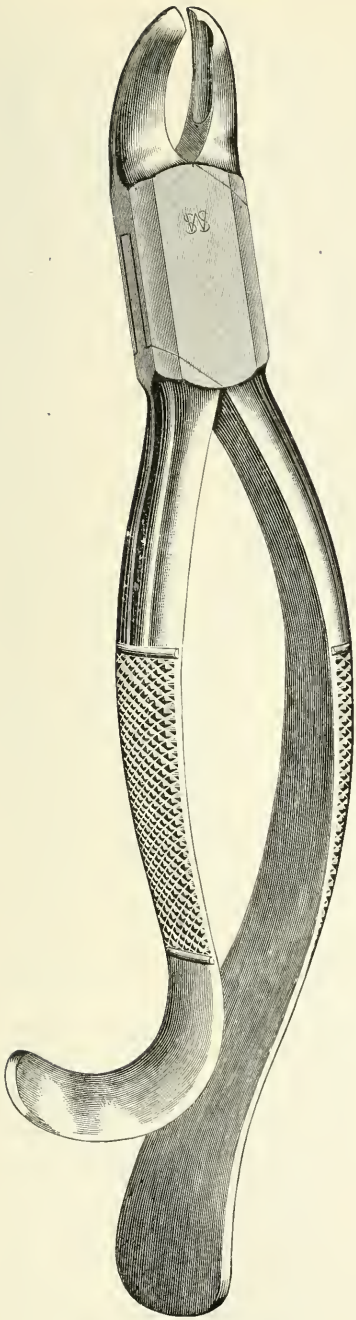

FIG. 282.—Upper Left Molar Forceps. Designed by Dr. Chapin A. Harris.

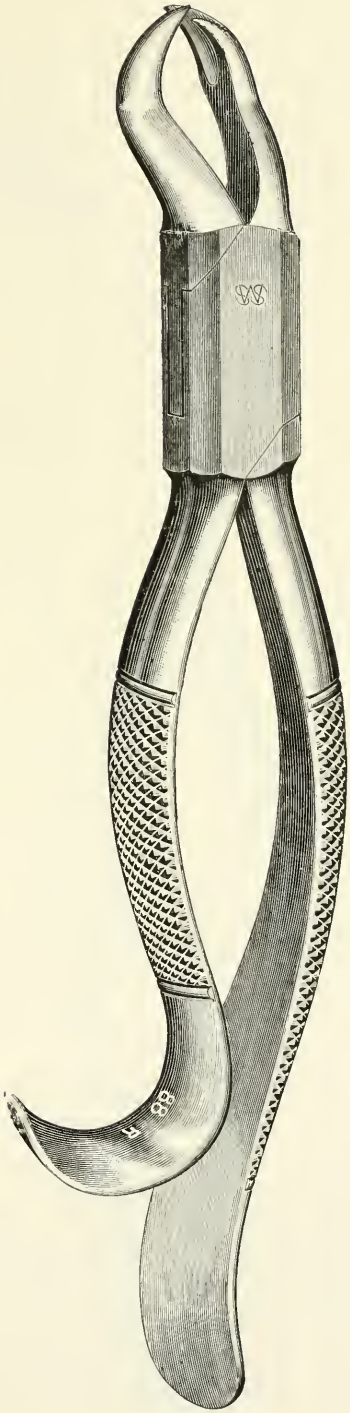

FIG. 283.—Upper Right Molar Forceps. Three Beaks. Bayonet Shape.

For the extraction of the upper cuspids a considerable degree of traction is usually necessary, more, perhaps, than for any other teeth, as these teeth have the longest roots, and are, as a rule, firmly implanted in their cavities. The traction applied should be in the labial direction, as this is in the line of least resistance, and as soon as an impression is made, and the tooth slightly loosened by such force, then slight rotation will assist in displacing it; the rotary motion will also tend to detach any portion of the process which may adhere to the root, as this is by no means an uncommon occurrence. The rotary movement should be applied in such a manner that the labial portion of the tooth is moved toward the median line, from the fact that the root of this tooth frequently has a direction backward. (Fig. 279.) For the extraction of the upper bicuspids, traction is generally employed. In the case of the upper first bicuspid, the force employed should be limited in degree, as this tooth has usually two slender roots and the process over the buccal root is thicker than over the root of the cuspid, hence, there is danger of fracturing this root if great force is employed. On this account the force should be carefully applied, and in the lingual direction to a greater degree than in the buccal direction. The second upper bicuspid has usually a single root which is round on the buccal and lingual surfaces, and flattened on the mesial and distal surfaces, the root being disproportionately long compared with the circumference of the neck. For the extraction of this tooth, traction may be applied in the line of least resistance, which is the buccal—that is according to its outward inclination, and when slightly loosened, the rotary motion may be resorted to completely displace the tooth. (Fig. 280.) For the removal of the upper first and second molars, which may also be grouped together on account of similarity in form, position and environment, traction should be applied first in a buccal direction according to the outward inclination of the tooth, for the reason that the resistance is first offered by a single or lingual root, and when an impression is made upon this root, that of the two buccal roots, the smaller ones, is soon overcome, and a slightly rotary motion, although the roots may diverge to a degree, will displace the tooth; the process is also thinner on the buccal aspect than on the lingual. Care should be taken, however, not to make the buccal pressure too great, for in such a case considerable fracture of the buccal wall of the process may result. (Figs. 281, 282, 283 and 284.) For the extraction of the upper third molars, traction should be made downward and backward. The roots of this tooth are frequently so fused together as to present but one of an irregular form, which permits the use of the rotary

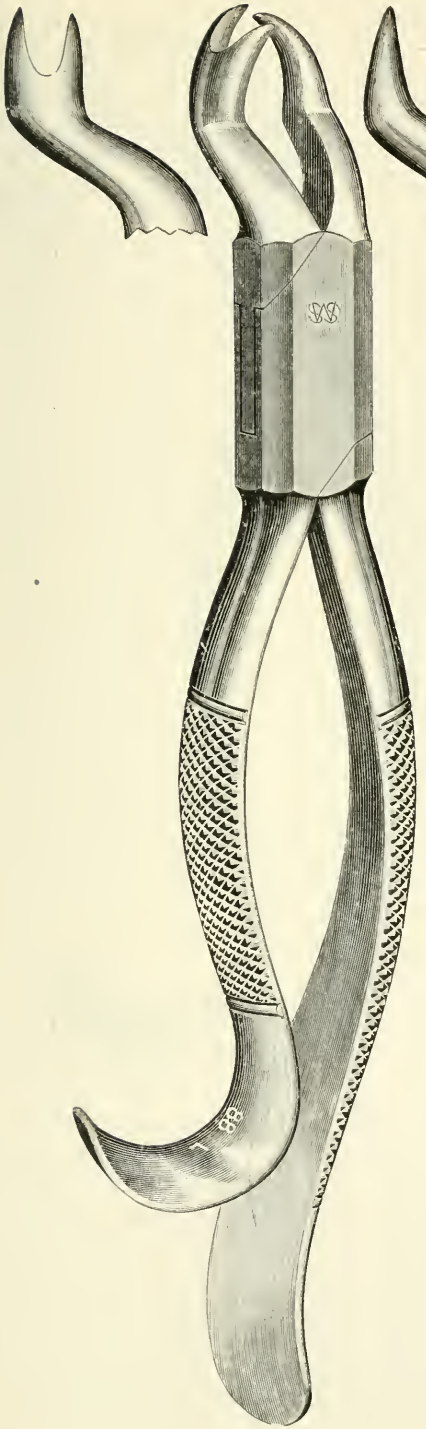

Fig. 284.—Upper Left Molar Forceps. Three Beaks. Bayonet Shaped.

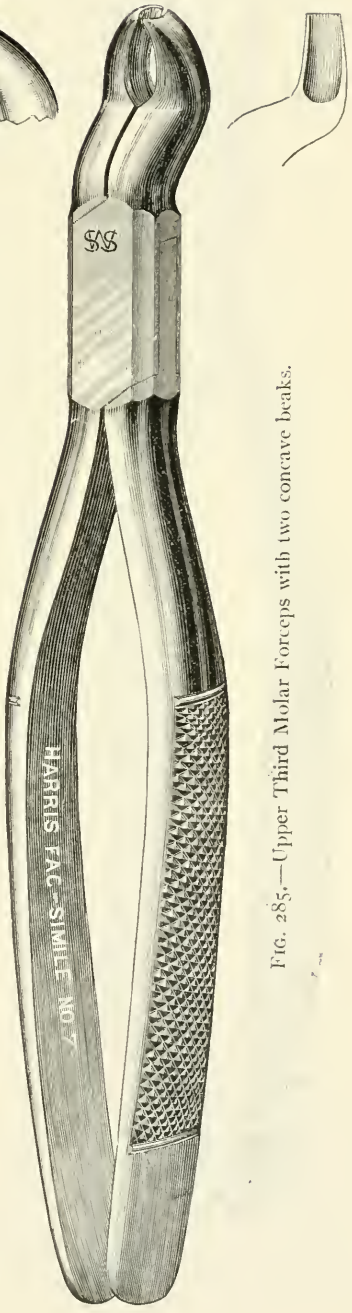

Fig. 285.—Upper Third Molar Forceps with two concave beaks.

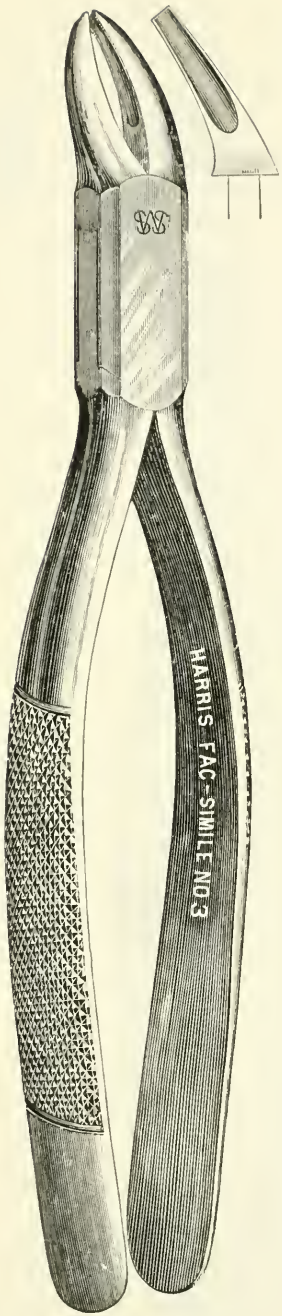

FIG. 286.—Lower Incisor and Universal Lower Root Forceps.

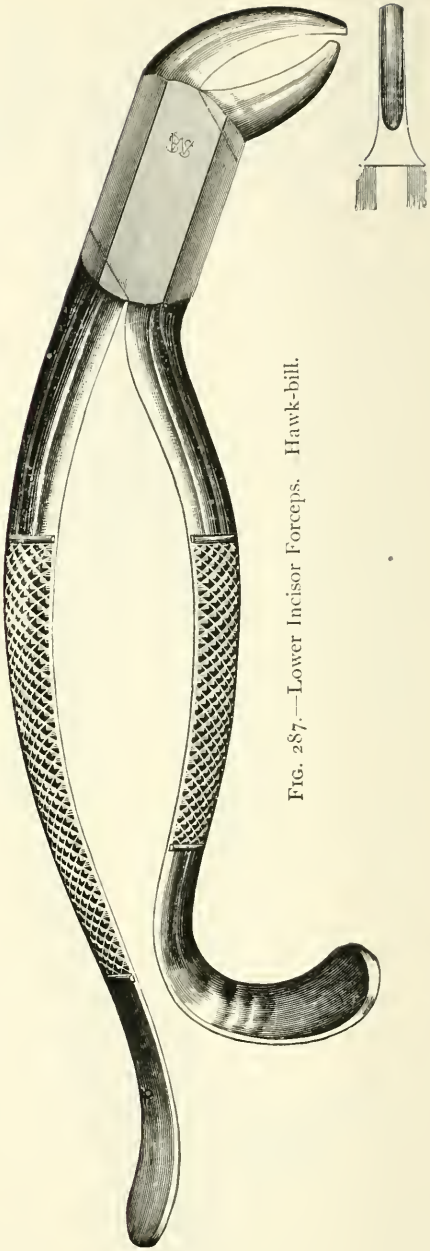

FIG. 287.—Lower Incisor Forceps. Hawk-bill.

motion in the direction of the raphe at the median line of the hard palate or roof of the mouth. These teeth being the last in the upper arch, and near the tuberosity of the process, are not usually very firmly implanted, especially as the alveolar process surrounding the distal surfaces of their necks is but imperfectly developed. Hence care should be taken that a tooth of this class, when loosened by the forceps, does not escape from the instrument, and slipping down the throat enter the larynx (Fig. 285). It is not unusual for the upper third molars to erupt on the outer side of the alveolar ridge with their occlusal surfaces directed toward the cheek; in such cases the direction of the force should be outward and upward, and the mutilation of the tuberosity be avoided on the account of the danger of penetrating the antrum, and also of injuring the vessels and nerves passing through the tuberosity in this locality. As the gum tissue at the distal surface of these teeth often adheres strongly to the neck, it is better to employ the gum lancet to sever the connection, and thus avoid the danger of tearing the gum. The form of lancet represented by Fig. 301 (3) answers for such cases.

The lower teeth are usually more difficult to extract than the upper ones, especially the lower third molars when partly erupted or impacted, owing to the space between the second lower molar and the ascending ramus of the jaw not being sufficient for their accommodation; such a difficulty may be greatly increased when the patient is unable to open the mouth to any extent owing to the inflammation incited by the tooth itself in the adjacent tissues, or by other pathological conditions, such as alveolar abscess for example. The fact that the inferior maxillary bone is a movable one, also adds to the difficulty of extracting the lower teeth, as it is necessary for the operator to hold the jaw immovably, by placing the palm of his left hand over that portion of the cheek covering the body and border of the bone, his fingers under the jaws, and his thumb pressing down the lower lip, and also assisting in supporting the jaw.

The external oblique line extending across the outside surface of the lower jaw, from near the mental process to the base of the ramus, and the mylo-hyoid ridge on the inner surface of this bone, which extends from a point near the base of the bone at the median line, and passes backward and upward to the base of the ascending portion, giving origin to the mylo-hyoid muscle which forms the greater part of the floor of the mouth; both of these prominences add to the thickness of the alveolar ridge over the roots of the lower molars, and increase the difficulty of extracting them; this is especially the case with the

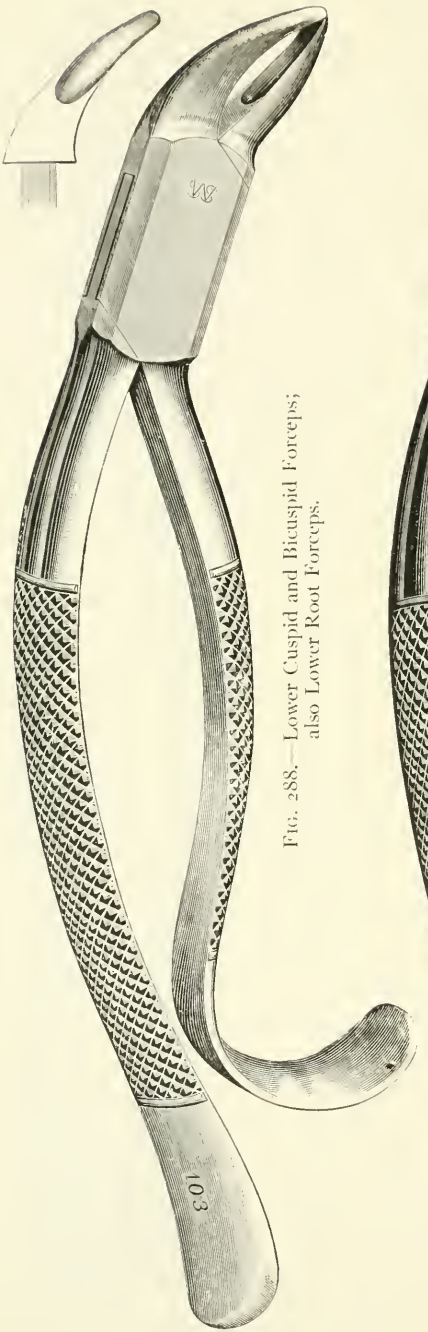

Fig. 288.—Lower Cuspid and Bicuspid Forceps; also Lower Root Forceps.

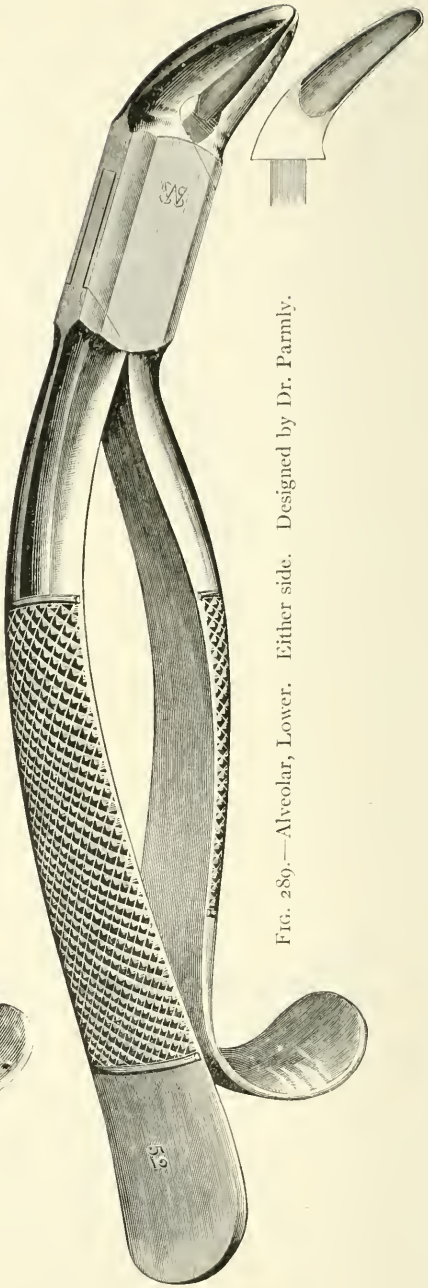

Fig. 289.—Alveolar, Lower. Either side. Designed by Dr. Parmly.



FIG. 290.—Dr. Chapin A. Harris' Lower First and Second Molar Forceps. Either side.

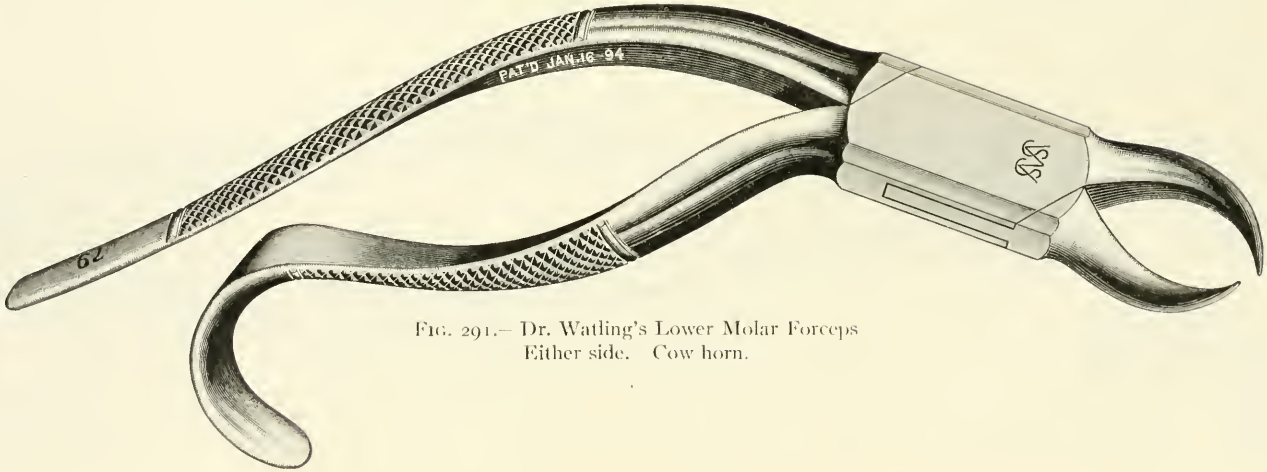

FIG. 291.—Dr. Watling's Lower Molar Forceps
Either side. Cow horn.

lower third molars, when their roots curve posteriorly, or these teeth are but partly erupted, or impacted.

For extracting the lower central and lateral incisors and cuspids, these teeth having single, straight and mesio-distal flattened roots, the operator in removing them occupies a position a little back on the right side of the patient, who is seated more uprightly in the dental chair than for the removal of the upper teeth. A narrow beaked forceps is employed for the removal of the lower central and lateral incisors, such as are represented by Figs. 286 and 287, and the outward and inward motions are applied with a force sufficient to expand, but not to fracture to any degree, the orifices of their alveolar cavities.

The lower cuspids, being larger teeth, and more firmly implanted than the lower incisors, require stronger forceps for their removal; hence, the lower bicuspid forceps, represented by Fig. 288, is generally employed. For extracting the lower first and second bicuspids, which have generally but a single root, which is straight, tapering gradually from the neck to the apex, that of the second being larger and longer than that of the first bicuspid, the motion required should be outward and inward, accompanied with a slight rotary motion as the tooth is yielding, to assist in detaching the process from the root. (Fig. 289.) For extracting the lower first and second molars, the outward and inward motions should be made; the roots of these teeth, two in number, usually diverge and stand across the alveolar ridge, being situated immediately beneath the mesial and distal halves of the crowns.

They are flattened on their mesial and distal surfaces, and broad at the neck from the buccal to the lingual surfaces; the mesial root usually being somewhat larger and longer than the distal root. The instruments adapted for their removal are illustrated by Figs. 290 and 291. The points on the concave edges of beaks of this forceps should be inserted in the space between the roots on each side of the alveolar ridge, the concave surfaces grasping the convex surfaces of the roots. Care should be taken when applying the forceps that no part of the tongue be inclosed between the beaks and the roots; the danger of a lower molar suddenly leaving its cavity after being loosened, and the forceps fracturing teeth in the opposite jaw should be guarded against. Some prefer to apply the first force, in loosening these teeth, in the direction of the inclination of the tooth in its cavity, either outward or inward. When the two roots of a lower molar diverge greatly it may become necessary to use the splitting forceps represented by Fig. 292, the sharp edges of which are carried down over the crown to the space between the roots, and the crown divided at the center of the buccal

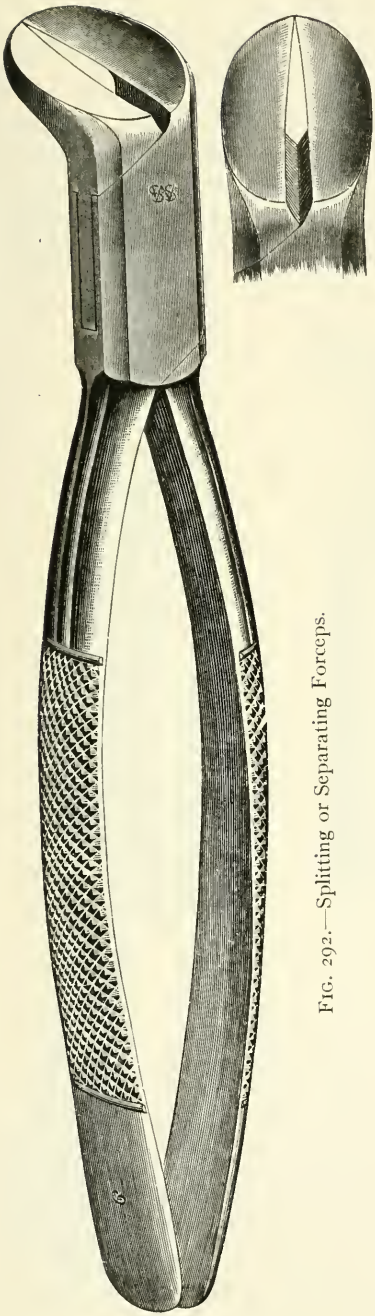

FIG. 292.—Splitting or Separating Forceps.

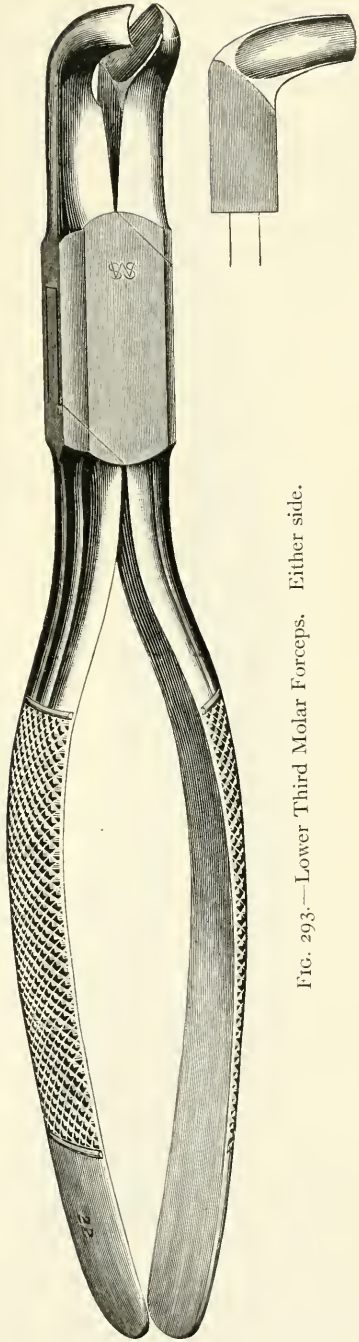

FIG. 293.—Lower Third Molar Forceps. Either side.

and lingual surfaces, using a strong pair of root forceps to remove each root thus separated. The extraction of a lower second molar is usually an easier operation than that of a first molar, for the reason that the roots of the second do not diverge from the neck to the same degree. The extraction of the lower third molar, when the teeth occupying the arch are not unusually large, or irregular in position, is not difficult and can be accomplished by the forceps represented by Fig. 293. The outward and inward motions are usually employed for loosening the lower third molars, except in cases where, owing to

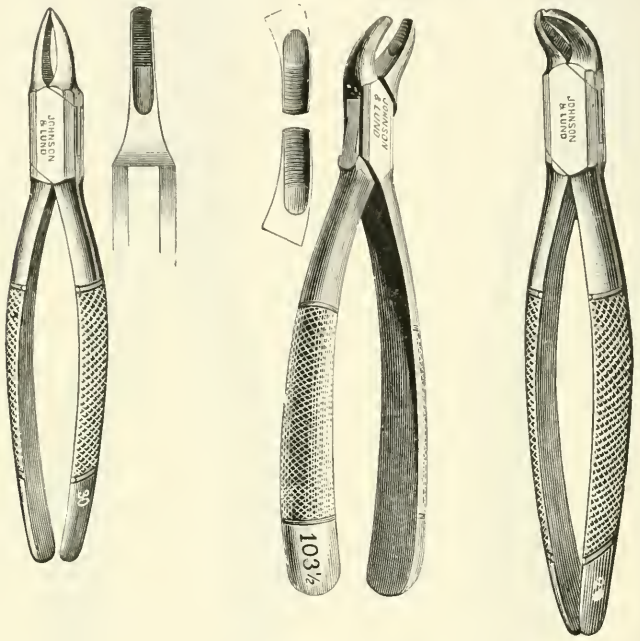

FIG. 294.—Deciduous Teeth Forceps.

irregularity in position, it may be better to apply the first force according to the outward or inward inclination of the tooth.

The operator and patient occupy the same positions in the extraction of both the lower first and second molars. When the force it would be necessary to use in attempting to extract an abnormally shaped, or located lower third molar would endanger the bone of the jaw, and especially when there is a backward curvature of the root, it is better to cut away the process with a bone-cutting bur, operated by the dental engine, until a sufficient portion of the root is exposed to be grasped by the forceps; this method can also be followed in the case of hypercementosed roots of other teeth; also in cases of partly

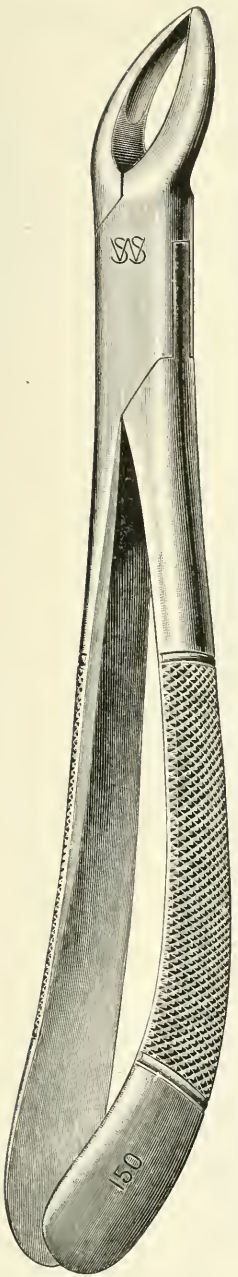

FIG. 295.—Dr. M. H. Cryer's Universal Upper Incisor, Cuspid, Bicuspid, and Root Forceps.

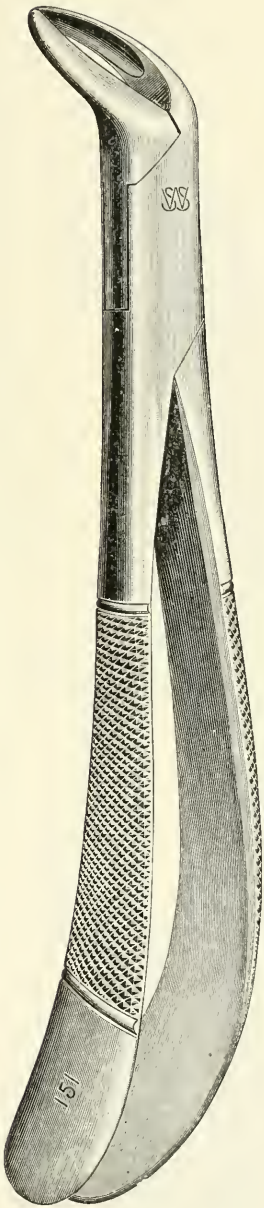

FIG. 296.—Dr. M. H. Cryer's Universal Lower Incisor, Cuspid, Bicuspid, and Root Forceps.

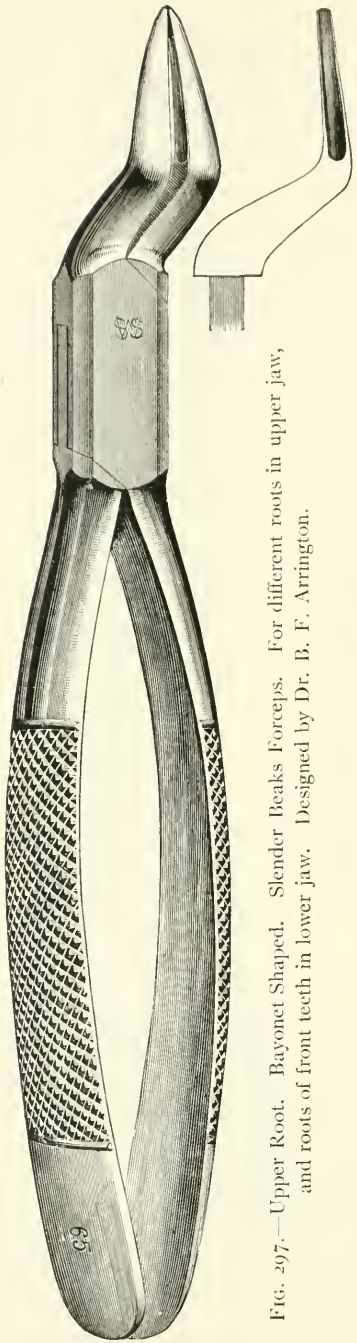

FIG. 297.—Upper Root. Bayonet Shaped. Slender Beaks Forceps. For different roots in upper jaw, and roots of front teeth in lower jaw. Designed by Dr. B. F. Arrington.

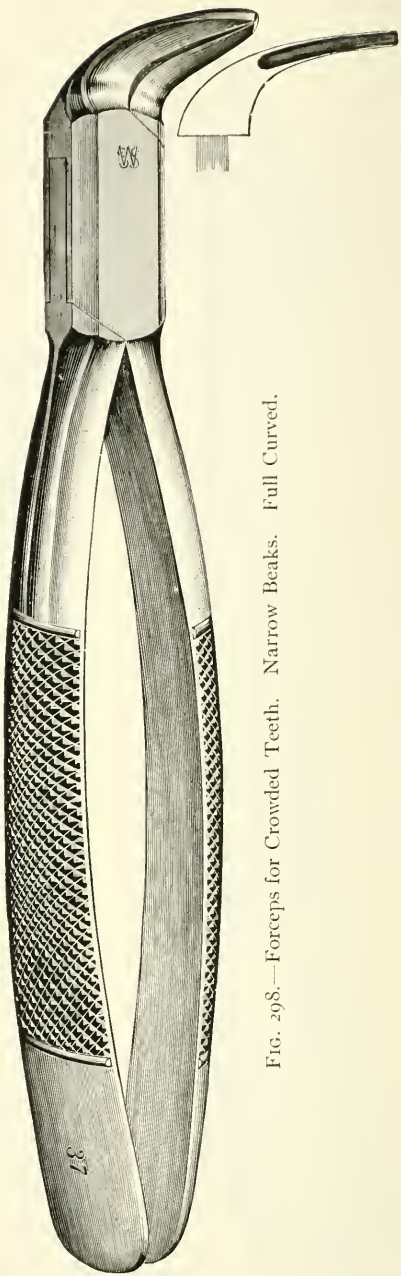

FIG. 298.—Forceps for Crowded Teeth. Narrow Beaks. Full Curved.

erupted, and impacted teeth. In loosening abnormal lower third molars, the direction of the force applied should be outward, backward, and upward. What is known as the elevating forceps is also employed for the extraction of partially erupted lower third molar teeth, the pointed ends of the beaks being applied in the space between such a tooth and the second molar, the latter tooth being used as a fulcrum. When a secure hold is obtained, the handles of the instrument are depressed and the abnormally placed tooth is forced from its cavity, or so loosened that it can be readily seized with the root forceps. After extracting any class of tooth, the expanded margins of the alveolar

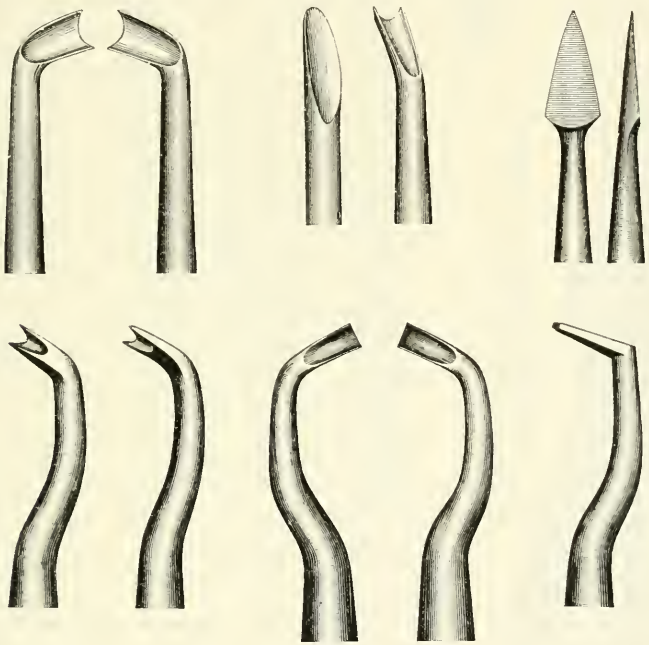

FIG. 299.

cavity should be gently pressed together with the thumb and forefinger. As a preventive against hemorrhage, and the after-pain of extraction, it has been recommended to fill the cavity from which the tooth has been removed with powdered orthoform, or to apply a solution of phenol sodique on a pledget of cotton.

The Extraction of Deciduous Teeth.—The extraction of the deciduous teeth is performed in the same manner as those of the permanent teeth, smaller and fewer instruments, however, being required. Fig. 294 represents a set of three forms of small forceps suitable for the removal of the deciduous teeth, although many operators employ the

smaller beak forceps of the permanent teeth instruments, especially the root-forceps for the removal of such teeth. Less force is required for the extraction of the deciduous teeth for reasons before given, but it is necessary that care should be taken that the operation is performed in such a manner that the developing permanent teeth, or their crypts, are not injured. In some instances the developing crown of a bicuspid has been brought away in extracting a deciduous molar, owing to the position of the crown of the former tooth between the unabsorbed roots of the latter.

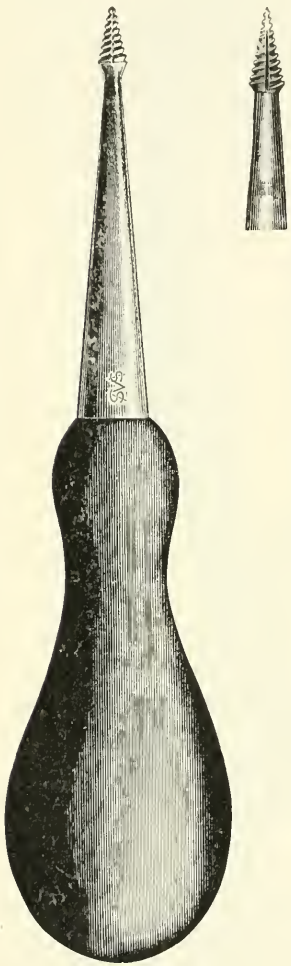

FIG. 300.

The Extraction of Roots of Teeth.—The extraction of roots is sometimes a difficult operation, but usually they are more easily removed than entire teeth, especially when they have remained in the alveoli for a considerable time after the loss of their crowns, and have not become exceedingly fragile from decay. When long retained, the attachment of roots becomes weakened by their loss of substance and absorption of their cavities, together with the deposition of bone at the apexes of their cavities to such a degree as to render their removal easy, as they are held in position simply by their connection with the gum. It often becomes necessary, however, to extract firmly implanted roots, owing to their separation from the crowns when attempting to extract the entire tooth, and great difficulty is often encountered, and to such a degree as to render it necessary to use special instruments devised for these cases. The instruments employed for the extraction of roots are known as root-forceps, and elevators, and, as a general rule, these root forceps have long and slender beaks, which are not adapted for the application of great force; hence the movements made with them should be gentle, as well as effective. Figs. 295, 296, and 297 represent useful forms of root-forceps. Figs. 295 and 296 are designed by Dr. M. H. Cryer for the extraction of any single-rooted tooth, and for third molars, and frail lower incisors.

The slender beak bayonet-shaped forceps, devised by Dr. B. F. Arrington, and represented by Fig. 297 is a useful instrument for difficult upper roots.

Fig. 299 represents the common forms of elevators. In using the elevator, care is necessary that the instrument does not slip and wound the mouth of the patient.

In the employment of the elevator, an adjoining tooth or root, if present, is used as a fulcrum; in other cases, the thumb of the hand of the operator holding the instrument may be thus used. The point or edge of the blade of the elevator is inserted between the root to be removed and the adjoining tooth or root, and by a slight rotary motion the

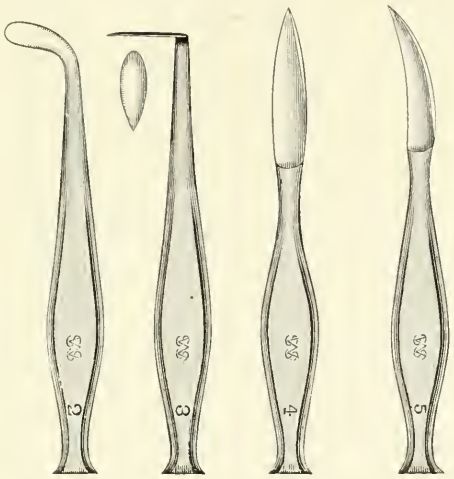

Fig. 301.

root is forced from its cavity. An instrument in the form of a screw is also used for the extraction of frail roots, and single-rooted teeth. (Fig. 300.) Before the screw is introduced into the root, the walls of which have become greatly funnelled out by decay, so as to render them incapable of sustaining the pressure of the forceps, the exposed surface of the root should be reamed out to remove the soft, decomposed matter, and thus a sufficiently firm hold for the screw be secured. The screw is then carefully inserted by half-turns until it obtains a firm hold in the root, and force in the line of the axis of the root is then applied, and its extraction accomplished. The screw, after it is securely fixed in the root, may be detached from its handle and the beaks of a forceps applied to the root, the screw within affording support, and the frail root be successfully extracted.

Gum Lancets.—The use of the lancet, when necessary, precedes the application of the forceps for the purpose of separating the adherent gum tissue at the necks of the teeth. The form of forceps as at present constructed, with thin sharp-edged beaks, renders the use of the lancet only necessary where there is a risk of laceration or tearing the soft tissues surrounding the tooth or root to be extracted; in the case of deeply imbedded roots, and third molar teeth, and teeth standing alone, the gum lancet may be advantageously employed. Fig. 301 represents useful forms of lancets, and Fig. 302 an all-metal lancet which is capable of being effectually sterilized. Fig. 301 (3) represents a useful lancet for separating the gum tissue from the posterior surface of the neck of a third molar tooth.

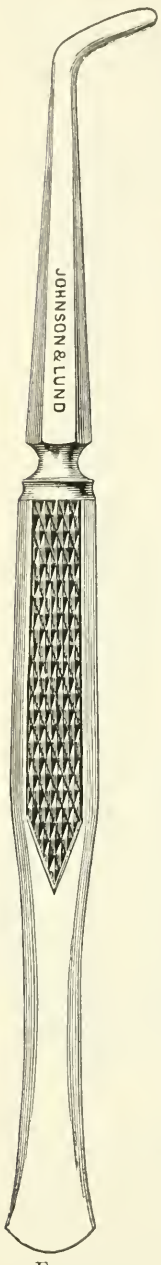

FIG. 302.

Fig. 301 (5) represents a useful form of lancet for liberating erupting deciduous teeth, opening abscesses, and performing other surgical operations. *The manner of using the gum lancet* when extracting teeth is as follows: The sharp edge of the blade is pressed against the neck of the tooth and within the free edge of the gum, and passed around the inner and outer surfaces of the neck as deeply as possible, after which the blade of the instrument is inserted in the interproximal spaces anterior and posterior to the tooth to be extracted. By such a method the membranous attachment of the tooth at its cervical portion is completely severed, and a way is made for inserting the edges of the beaks of the forceps; the danger of the slipping of the lancet is also avoided by applying the edge at an angle to the neck, and a secure hold upon the tooth obtained with the forceps. When extracting the deciduous teeth, the use of the gum lancet is unnecessary and at the same time injudicious, for the reason that these teeth are less firmly implanted than the permanent teeth, the process about them being softer and more yielding, and at the period when their removal is necessary their roots are so much absorbed and their attachment to the alveolar cavity is so greatly weakened that but little force is required to detach them. The employment of the lancet in the case of the deciduous teeth is also injudicious, for the reason that the pain caused by this instrument may be such as to prevent a

further continuance of the operation without force is employed on the patient, which is always unpleasant and to be avoided if possible.

The Casualties Attending Tooth-extraction.—The operator should at all times be prepared to avert and also to successfully meet the dangers attending tooth-extraction, which may be enumerated as follows: *The fracture of the whole or a portion of the crown of the tooth* is the most frequent accident occurring during this operation, and may be occasioned by an ill-adapted instrument being used; by its improper application; by too much force being applied, and too forcible movements made in loosening the tooth. This accident may sometimes be unavoidable, and when such is apparent it is better to inform the patient of its probability.

The extraction of the wrong tooth may occur as the result of failure to make a careful preliminary examination; or from an incorrect diagnosis; or from carelessness in applying the forceps, especially when the teeth are crowded. If the conditions are favorable, replantation may be resorted to.

Fracture of the alveolar process may, to a limited degree, and where it involves the margins of the alveoli only, be a common necessity in extraction, but in no case should the fracture be so extensive as to cause serious injury.

Fracture of the jaws is not probable when using the forceps as at present constructed, without excessive and unnecessary force is employed, or the bone is in a diseased condition.

A sound tooth may be extracted when it is joined by a cemental fusion with the roots of another requiring removal, and in such a case may be an unavoidable accident.

The escape of a posterior tooth or root into the *larynx* or *pharynx* may occur when a tooth, such as a third molar, suddenly leaves its cavity and escapes from the forceps during the operation of extracting it. If the fingers cannot remove the tooth, resort may be had to the pharyngeal forceps.

Dislocation of the lower jaw is an accident only likely to occur from a laxity of the ligaments of the temporo-maxillary articulation, due to a previous luxation from any cause.

Syncope or fainting is a common and unavoidable accident attending tooth-extraction. In such a case the patient should be placed in a horizontal position by lowering the back of the chair to such a degree that the feet are elevated, and the blood gravitates to the brain. Stimulation by wine, whiskey or brandy, or the aromatic spirits of ammonia, in doses of half a dram in half a wine-glass of water, will increase

the heart's action; rubbing and slapping the hands, or the application of cold water to the face and breast, may also prove effective; after which the patient should be kept at rest for some time.

Shock during tooth-extraction is often confounded with syncope, and as far as the ordinary symptoms of this latter condition extend, these two are analogous and differ in degree and duration more than in character. In shock there is a state of prostration, a pallor of the whole surface, pale and bloodless lips, a loss of luster in the eyes, the eyeball partially concealed by the drooping upper eyelid, dilated nostrils, a cold, clammy moisture often gathered in beads upon the forehead, a low temperature, weakness of muscles, bewildered mind, often insensibility, and there may be nausea and vomiting. The aged are slower in recovering from the effects of shock than the young, although they have more power of resistance; in the young the impression is more easily made, but subsides sooner than in the old. The treatment of shock consists in placing the patient flat on the back, and the use of such stimulants as brandy, or aromatic spirits of ammonia, in the same doses as for syncope. Heat applied to the epigastrium by means of flannel wrung out in hot water, or the hot water rubber bag, and mustard plasters are beneficial. Small chips of ice swallowed whole will allay the nausea and vomiting.

Forcing teeth or roots into the antrum in the endeavor to extract them, especially when the alveolus communicates with this cavity owing to absorption occasioned by the action of pus. In such a case, the orifice of the opening into the antrum should be enlarged, and the tooth or root removed with the pharyngeal forceps.

The mutilation of the maxillary tuberosity in extracting an upper molar should always be avoided, as severe hemorrhage may result from the rupture of the posterior dental artery, which may be difficult to control; also injury to the palatine branches of nerves; in some cases deafness has been ascribed to such an accident; also an opening into the antrum, as a result of the mutilation of the tuberosity. When the fracture of the tuberosity is slight, the parts may be pressed together by the thumb and finger to control the hemorrhage when it is severe, and the parts packed with medicated gauze, which should remain for several days before removal.

Alveolar hemorrhage from the extraction of a tooth may result from the condition of the parts involved, such as the character of the blood, which is shown by want of coagulability; also from diseased walls of the vessels, and inflammation in the adjacent tissues; and finally from the predisposition of the patient, as in hemophilia. To

determine whether the blood is coagulable, a small quantity may be caught in a vessel, and if it forms a clot in the course of two or three minutes much cause for alarm is removed, and the line of treatment sufficiently clear, as the diagnosis may indicate the cause to be either vascular or mechanical. A failure in the contraction of the mouths of the bleeding vessels, or adhesion of the vessels to the walls of the surrounding bony canal, or the rupture of an abnormally large vessel may also be causes of alveolar hemorrhage. Usually the hemorrhage after the extraction of teeth ceases within one hour, although a slight oozing may continue longer, and does not require treatment; if it should be more prolonged, as the result of great inflammation in the adjacent parts, or the patient is anemic, or predisposed to the hemorrhagic diathesis (hemophilia), treatment for its arrest is required.

For the arrest of alveolar hemorrhage (arterial), such styptics are useful as tannic acid, gallic acid, iodoform gauze, alum, nitrate of silver, perchlorid or persulphate of iron (either of which may be used in solution or powder), or carbolized resin (resin and phenol in chloroform), or adrenalin chlorid, or styptic-colloid (a combination of tannic acid, collodion, and tincture of benzoin), or orthoform. The preparations of iron and nitrate of silver are considered objectionable on account of the clot formed by them being soluble in the blood, and the escharotic action of the nitrate of silver not being limited to the alveolar cavity, and the surface of the wound thus extended.

The local treatment consists in first removing the clotted blood from the cavity, and this is especially necessary in case of secondary hemorrhage, where the clot may be found protruding from the vacant cavity, and in some cases almost filling the mouth. After the removal of the clot, the alveolar cavity should be syringed with ice-cold water, to which is added a small quantity of phenol sodique (phenate of soda), and a pledget of cotton or lint saturated with the styptic applied to the apex of the cavity and over the mouth of the bleeding vessel.

Dry absorbent cotton is then introduced over the styptic, and firmly condensed, so that the cavity is tightly filled to and a little beyond its orifice. In severe cases of alveolar hemorrhage, a compress is a valuable adjunct, in order to increase the pressure on the cotton plug, filling the cavity. Such a compress may consist of a cork with a concave end to fit over the cotton plug, and of such a length as will permit the opposing teeth to press against it with some force; or it may consist of either semiplastic gutta-percha, or modeling compound; tannic acid, or other styptic, is incorporated in the gutta-percha, a plug of which is held by the pliers for a short time in hot water to

soften it, and after the bleeding cavity is dried with hot absorbent cotton, the warm styptic plug is firmly pressed to the bottom of the cavity, and held there until it hardens; also bathing the root of the extracted tooth, when it is a single root, with the styptic and returning it to its cavity; also a plug of half hardened plaster of Paris; also when the hemorrhage occurs from the cavities of several teeth, a plaster impression of the mouth, or a part of it, taken in the ordinary manner, and allowed to remain in position for some time before attempting its removal. Other mechanical styptics such as matico leaf, spider's web, burnt cork, puff-ball, powdered resin, etc., have been suggested. When matico leaf is employed, the fresh leaf is preferable, or if in a dry state it may be moistened with water and then rolled into a convenient form, with the rough side outward and forced into the cavity. Packing the cavity with cotton moistened with Canada balsam is also recommended, as it does not require any prolonged pressure. Carbolized resin may be applied on a saturated strip of the fungus amdou.

The plugs containing the styptic should be retained in position for from 24 to 48 hours and then be cautiously removed; and if a compress is applied, the jaws should be secured and continuous pressure maintained by a four-tailed bandage passed from the chin over the head. During the treatment the patient should be kept at rest, and abstain from the use of hot fluids, alcohol, and tobacco, as they relax the arteries, and favor a return of the hemorrhage. In connection with the styptic, and in cases where the hemorrhage has resulted from the extraction of a tooth or root which has been held in place only by gum tissue, and the cavity after extraction is of little depth wherein to pack the styptic, the following internal remedy has been suggested by Dr. W. L. Robinson, and can be administered with benefit: Three grains of tannic acid dissolved in one-third of a tumbler of water; two teaspoonsful, to be given every five minutes until three doses are taken, after which the same quantity is given every fifteen minutes. When such measures as have been referred to for the arrest of alveolar hemorrhage fail, resort may be had to the cautery, either the galvano cautery, or the Paquelin benzoline cautery.

The after-pains of extraction when due to pericementitis, or any form of septic infiltration, may be relieved by either filling the vacant cavity with a pledget of cotton soaked with phenol sodique, or with a solution composed of glacial carbolic acid. ℥j, liq. potassæ, ℥j, and water ℥viij; or by applying to such a cavity one drop of a one per cent solution of nitro-glycerin in half a wine-glass of cold water; or a five per cent solution of equal parts of cocain and iodoform. If such local

applications fail, a solution of one-eighth of a grain of morphine may be injected into the gum over the vacant cavity.

The after-treatment of extraction is often of great benefit to the patient. In ordinary cases the use of a twenty per cent solution of phenol sodique is of great service, or a three per cent aqueous solution of pyrozone, especially if the case has been one of pericementitis or alveolar abscess; either of these antiseptic solutions may be used as a mouth wash, and the mouth rinsed for several days. Filling the cavity with powdered orthoform, as soon as the bleeding has subsided, is also beneficial. Where an alveolar abscess has existed for some time previous to the extraction of the tooth, and the process has to a degree become necrosed, the cavity should be syringed with a solution of ten grains of either the sulphate or the iodid of zinc, which will separate the dead from the living portion of the bone, forming a sequestrum.

When extracting teeth a careful observance of the rule before referred to, namely, "that no movement should be made with the forceps faster than the eye can readily follow," may prevent the occurrence of accidents liable to attend this operation—namely, serious fractures, tearing the gums, etc. Should the gum adhere so firmly to the process that it begins to tear away, the operation should be suspended until the attachment is severed by the lancet or curved scissors.

Sterilizing Instruments.—The absolute sterilization of operating instruments, such as forceps, etc., is demanded, inasmuch as infected matter is much more readily communicated by them through wounds than by the fingers of the operator. Sterilization is so easily accomplished that there is no excuse for neglecting it. A simple and effective method is by immersing the instruments in boiling water to which one or two per cent of carbonate of soda has been added to prevent rusting. Five minutes immersion in such a solution will answer for forceps and three minutes for smaller instruments, unless they have become coated with a thick dry coat of infectious matter, when a longer boiling is required, and a subsequent immersion in a one to thirty per cent. solution of phenol. Lysol may be substituted for the phenol as it will not rust the instruments, and, hence, does not require the use of a solution of soda. Trichlorphenol is also an efficient sterilizing agent.

The strictest aseptic and antiseptic precautions should be observed when operating on the mouth.

The extraction of teeth under the influence of anesthetic agents has become so general, and there are so few cases in which either a local or a general anesthetic is not admissible, that a writer on this

subject has declared it to be an almost barbarous procedure, when performed without the aid of such an agent.

The operator should, however, in all cases be governed by the condition of the patient, which can be determined by a physical examination. Local anesthetic agents applied by the hypodermic method are employed to obviate the dangers of general anesthetics, which are administered by inhalation. When using the hypodermic method, several dangers are to be avoided: 1. The needle of the syringe should not penetrate a vein, as the entire dose may be carried to vital centers; hence, a locality should be selected for puncturing that is free from veins, nerves, and large blood vessels; the vascular and soft structures of the cheeks beyond the gum should also be avoided.

2. Both the needle of the syringe, and the anesthetic solution, should be rendered sterile before using; otherwise an abscess may result from infection. The direct application of a strong solution of the anesthetic agent to be used to the area of the gum into which the needle is to be inserted, will enable the puncturing to be made without pain.

The selection of a general anesthetic agent, when one is preferred, should be governed by the condition of the patient and the nature of the operation; and the physiological action of the agent employed should be well understood.

A combination of nitrous oxid and oxygen, although transient in its effects, may answer for the majority of cases of tooth-extraction, especially when few teeth are to be removed; while in other more prolonged operations, as the extraction of a number of teeth and roots, sulphuric ether may be preferable; or after anesthetization by nitrous oxid, the effects may be continued by the inhalation of ether. For the physiological action of the different anesthetic agents, and the manner of their administration, the student should consult authorities on this subject. Before extracting teeth under the influence of an anesthetic agent, the operator should be prepared to meet all dangerous symptoms liable to occur. Restoratives, such as aqua ammonia for inhalation, aromatic spirits of ammonia for internal or subcutaneous use, also brandy or whiskey as stimulants, together with tablets of sulphate of strychnine gr. $\frac{1}{60}$ to $\frac{1}{30}$ for subcutaneous use. For weak and debilitated patients, the subcutaneous injection of morphine, gr. $\frac{1}{8}$ to $\frac{1}{4}$, and gr. $1\frac{1}{100}$ to $2\frac{1}{100}$ of atropine, previous to the inhalation, is recommended. The heart and respiration should be carefully examined previous to the administration of every general anesthetic, as a wise precautionary measure. A suitable mouth prop or gag, for separating

the jaws and keeping them open, is a necessary adjunct, especially in the use of nitrous oxid, on account of the rigidity of the muscles.

All of the instruments necessary to be used should be within easy reach, and in case where a number of teeth are to be extracted, the number of forceps should be limited, so that there may be as little change of instruments as possible, and for this reason the universal forceps are to be preferred.

In the administration of a general anesthetic, the operator should invariably insist on the presence of a third person in the room on account of possible hallucinations on the part of the patient.

As soon as the tooth is removed from the mouth, the head of the patient should be slightly inclined, so that the blood may run into the cuspidor, and the patient kept at rest until complete recovery takes place.

Whether teeth should be extracted when affected by pericementitis, or alveolar abscess, is a mooted question. With the remedies now employed for the relief of the after-pains of extraction, the writer cannot see any necessity for subjecting a patient to prolonged suffering by delaying the removal of the offending tooth.

CHAPTER XXVII.

THE PLANTING OF TEETH.

BY C. EDMUND KELLS, JR., D. D. S.

The planting of teeth in the human jaws may be done under various conditions, and therefore the operations may be classified, chronologically as they were introduced into the practice of dentistry, as follows:

1. Replanting.
2. Transplanting.
3. Implanting.

Replanting.—By this term is designated the operation of restoring to its original socket the tooth which has been torn therefrom either accidentally or intentionally. This operation has been more or less in vogue ever since the days of Ambrose Paré, who died in 1590, and today is considered good practice by many of our ablest operators, under the following conditions:

A. When the tooth has been accidentally removed by force.

B. When a tooth has been accidentally removed by the forceps.

C. As a last resort to cure a refractory alveolar abscess.

A. In almost any case where one or more of the anterior teeth were knocked out, it would be no less than criminal neglect for the operator not to at least attempt their replacement. Under these circumstances the tooth should be carefully washed and examined. If the crown is found fractured or badly cracked, it should be cut off and replaced by an artificial substitute. If carious, it should be filled. Pulp chamber and root canal should be cleansed and filled. The writer prefers to fill from the crown, using oxy-chloride of zinc for filling the pulp chamber and canal, after which the foramen is enlarged and the canal drilled and tapped, and a gold screw inserted, using the S. S. White "anchor" screw instruments for the purpose. This insures the substantial and perfect sealing of the end of the canal. The cavity in the crown is then filled with whatever material is best suited to the case in hand, after which the tooth is placed in an antiseptic solution.

As to the best time to replace the tooth, there appears to be a

difference of opinion. Some operators prefer to await the subsidence of the local inflammation which naturally follows the injury, whilst others insist that the sooner the teeth are replanted, the better.

However, whenever the tooth is replaced, the method of procedure is about the same. The entire mouth *and socket* should first be sprayed with an antiseptic solution, and the region about the socket protected by napkins. The hands having been previously well cleansed by the use of carbolic soap, the blood clot is removed from the socket which is then carefully swabbed out with cotton saturated with the antiseptic solution. The tooth is then taken from its bath, a crystal of resorcin placed upon its apex and then quickly inserted into the socket. If by slow and gentle pressure the tooth cannot be returned to its original position, the writer believes it better practice to enlarge the socket rather than shorten the root.

Just as a surgeon considers it necessary to hold in firm apposition the two ends of a broken bone, so it is essential that the replaced tooth should be firmly fixed in its position. While wire or silk ligatures are used by some, it is undoubtedly better to swage by the usual method a cap of No. 30 pure gold to fit the crown of the replaced tooth and one or more on each side, which, when cemented in place, will hold it firmly in position during the process of repair—usually about four weeks. This splint should not extend quite to the gum line and the proper occlusion of the teeth should be carefully considered.

The after treatment of these cases consists in applying the tincture of aconite and iodin (equal parts) twice daily to the dried gums about the socket and adjoining teeth until all soreness disappears. The patient should be instructed to thoroughly cleanse the region about the replanted tooth after each meal, which can best be done with an antiseptic solution in an ordinary rubber bulb syringe. With this the liquid can be readily and forcibly injected between the teeth and thus keep them free from debris.

The patient should be kept under constant surveillance and should the splint loosen, it should be re-cemented at once. At the end of the fourth week the splint should be carefully removed and if the tooth is not found to be perfectly solid, replaced and worn until perfect union has been obtained.

B. A tooth might be accidentally removed by the forceps by the slipping of the instrument during the operation, due to the movement of the patient, or by the operator in undue haste placing his instrument upon the wrong tooth.

Again, the crown of a lower first molar having been lost, the

second molar may have tipped forward to such an extent that any attempt to remove the ofttimes diverging roots of the first molar would result in dislodging the second bicuspid.

Such roots should be separated by a suitable instrument in the dental engine and each root extracted separately which would remove all possible danger to the second bicuspid.

The same method of treatment previously described should be followed in cases of accidental extraction, and in such instances the teeth always replaced without unnecessary delay.

C. Notwithstanding the advanced methods of treatment of diseased teeth, by amputation of the ends of the roots, removal of necrosed portions of the alveolar process, etc., etc., there still present, from time to time, cases of alveolar abscess which cannot be cured by the ordinary means.

Usually these conditions are caused by either the root filling or a broken instrument protruding through the end of the root, or on the other hand from the failure of the root filling to reach the end of the canal.

Under these circumstances, when all other methods have failed and as a last resort, the operation of replanting is justified, and usually results in a cure.

Here again the operative procedure differs radically with different operators. Some always cut off the end of the root and do not replace the tooth for some time, waiting for the conditions about the socket to improve. Others never alter the roots if it can be avoided, and replant at once. The writer uses the latter method.

In extracting a tooth for the purpose of replanting, the utmost care must be exercised in selecting forceps that fit the tooth and will not check or mar the crown.

Once it is in hand, the cause of the trouble will be seen and must be removed. The tooth is then treated as previously described. The socket is carefully washed out, making sure to include and cleanse the pus pocket thoroughly, curetted if necessary, and the tooth replaced under antiseptic conditions and splinted firmly in place. Under these circumstances the splint should have been made before the tooth was extracted.

Replanting for the cure of pyorrhea is practically impossible. The operation is not warranted when the disease is in its incipiency, *at which time the operation might prove successful in eradicating the disease*, and later on when it would be tolerated, the loss of the socket renders it impracticable.

Prognosis.—Usually, sooner or later, the roots of replanted teeth become absorbed and finally the teeth are lost. However, such teeth have been reported still in good condition twenty years after replanting. The writer has under observation a first lower molar still in good condition which he replanted over fifteen years ago.

Fig. 303 shows model and a skiagraph of this case taken during the preparation of this chapter.

These roots present a very unusual appearance for a replanted tooth. As will be stated later on, the pericementum shows in a skiagraphic picture as a white line around a *normal* root. In this instance this white line is present in its entirety, and it assuredly appears

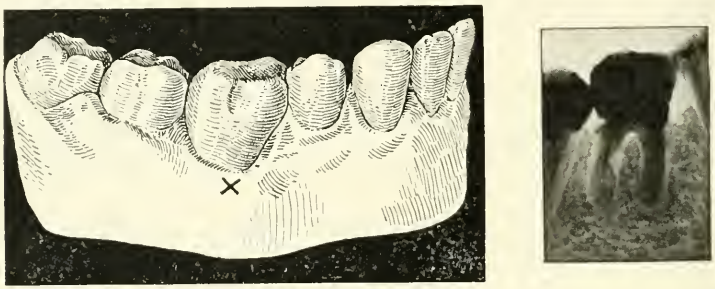

Fig. 303.

that the pericementum was revivified and not obliterated as usual, which is most remarkable. This tooth was replanted in less than two hours after extraction.

Transplanting is the operation of introducing into a fresh natural socket a root either freshly extracted or not. This operation also dates back to the days of Paré, and has always been practiced more or less until recent years.

However, at this date, we may safely say it has become obsolete, the necessity for it having been overcome by present methods of crown and bridge work, and the more modern operation of implanting.

Implanting.—By this is meant the drilling of a socket into the alveolar process, and implanting therein a natural root.

In 1885 Dr. W. J. Younger, of San Francisco, conceived and performed this operation, and it was at once and without much thought adopted by very many operators.

It being decidedly the most spectacular operation ever devised for clinics, scores of teeth were publicly implanted within the following year or two, and as most of these operations were performed under

decidedly unfavorable conditions, failure was the almost universal result. These unfortunate results proved so very disastrous that the operation so far as the profession in general was concerned was discontinued almost as abruptly as it was adopted.

Notwithstanding these general results, here and there a careful operator appreciated that implanting with discretion was to a certain extent a success, and therefore had a field of usefulness decidedly its own.

At this writing, when we know that implanted teeth have rendered service from five to fourteen years, it is not rational to absolutely condemn the operation.

Indications.—When a case presents with one or several of the eight anterior teeth missing in single spaces and the alveolar process is full, hard and healthy, it may be stated without fear of contradiction that a denture is the least desirable method of their replacement. A bridge is satisfactory while it lasts, but in the present stage of the art, such is by no means permanent work, and when it does fail it leaves the patient in a worse than his original condition, through the loss of the supporting roots. If therefore the patient is a good healthy subject, implantation is certainly indicated, and if that fails, bridging may still be resorted to.

Again, cases present where the temporary lateral remains in situ for many years after it should have been succeeded by a permanent tooth. Finally the tooth is lost and a skiagraph reveals the absence of the permanent tooth in the alveolus.

In these cases, the alveolar process is full and there is plenty of space therein for the making of a socket, and if the patient is in good health, certainly it would be better to at least first attempt implantation before mutilating the adjoining tooth by bridging.

Precautions.—The drilling of a socket in the alveolus sounds like a very heroic operation, while as a matter of fact when compared to some others, such for example as the extraction of impacted third molars, it is very simple.

As before stated, if the alveolar process is not sufficiently large to contain the socket, it should not be attempted. Otherwise the only precautions necessary are to sufficiently comprehend the anatomy of the parts so as to avoid entering the nasal fossa or the antrum, or injuring the contents of the anterior palatine canal in the upper jaw, or the inferior dental nerve in the lower.

The suggestions for the antiseptic treatment given for replanting hold good in implanting.

It has been found that mature roots are most desirable for implanting as they appear to withstand the process of absorption more successfully than young teeth, and only small straight roots should be used.

In drilling the socket, great care must be taken not to perforate either the external or internal alveolar plate, which would insure failure of the operation.

Procedure.—As a natural tooth can rarely be found to suit the case in hand for implanting, any desirable root may be used and a suitable artificial crown, preferably porcelain, mounted thereon after the canal has been filled. An impression is first taken, and in the model made therefrom, a hole is drilled to represent the socket to be made in the jaw. In this the root is placed while the crown is made. The complete and absolute fixation of the implanted tooth

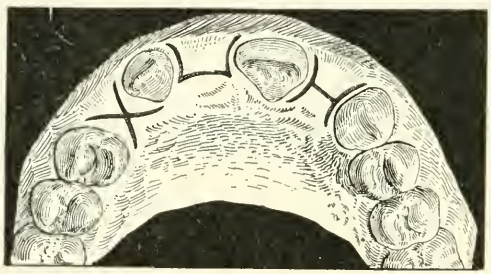

Fig. 304.

being necessary, the writer considers that the gold splint as recommended for replanted teeth should be used here as well, and this can be made from this model after the crown is completed.

The root and its finished crown mounted thereon is now carefully cleansed and placed in an antiseptic bath.

There is nothing better than a compressed air spray for use in the planting of teeth, but if that is not at hand, a good atomizer should be used with a sterilizing bath. The mouth is thus sterilized as for replanting, the hands carefully cleansed, and the points of all instruments to be used immersed in a sterilizing bath.

Small pieces of sponge, having been previously boiled, are also placed in the bath.

Cocain or eucain, as preferred, is then injected so as to thoroughly anesthetize the territory to be operated upon, whereupon all is in readiness for the first step of the operation, which is

The cutting of the flap, which has been done in three ways:

1. The ordinary X incision which leaves four small corners of the gum to be turned up.

2. The letter H cut which gives the operator two small flaps to take care of, and

3. The (__) shaped cut which gives him but one.

These are shown in Figure 304, and an instrument well shaped for their execution in Figure 305.

The cuts should be clean and to the bone, and with this instrument the *periosteum and gum* are separated from the alveolar process and turned upwards.

Fig. 305.

If coarse bladed round burs are to be used for drilling the socket, the flaps of the gum in the first and second method may not be much injured, but if the reamers are used they would undoubtedly be badly cut, it being impossible to hold them out of their way.

Experience has proven that if provision is made for ample restoration of the gum upon the labial surface of the implanted tooth, the lingual surface need not be much considered. In fact the satisfactory restoration of the gum tissue appears to be about the least of the difficulties of implanting.

If, therefore, the reamers are used the third cut should be made, as the flap being large and single can be held away from the cutter by any suitable instrument.

Drilling of the Socket.—For this purpose the following instruments are listed in the dental catalogues. (Fig. 306.)

The writer prefers the Ottolengui reamers, and proceeds as follows (Fig. 307):

A, being the tooth to be implanted, three reamers are selected, one of each size of the root at the points marked B C D. Setting the collar upon the smallest to gauge the full depth of the socket, the flap is held away, the parts again sprayed and the socket quickly drilled to this depth. The gauge on the second reamer is set to the point D, and the socket is correspondingly enlarged to this depth. This operation is repeated with the third reamer to the point C. We now have a socket which we are assured is of the required depth and of the shape shown in Fig. 308.

Resuming our medium size reamer, and being careful to maintain our antiseptic precautions, the steps of the cavity are gradually trimmed away, and we find that with few fittings of the root (after

each of which it is returned to the antiseptic bath), we have expeditiously accomplished the making of a satisfactory socket.

Dr. Robert Eugene Payne, of New York, has used the following: An old tooth brush handle is trimmed at one end to as near the shape and size of the root to be implanted as is possible—and it is then boiled in distilled water for two hours—after which it is placed in the sterilizing solution. When the socket is nearly finished, this "form" is pushed in with considerable force and the alveolar process being more or less yielding is crowded away and the root will fit the socket snugly.

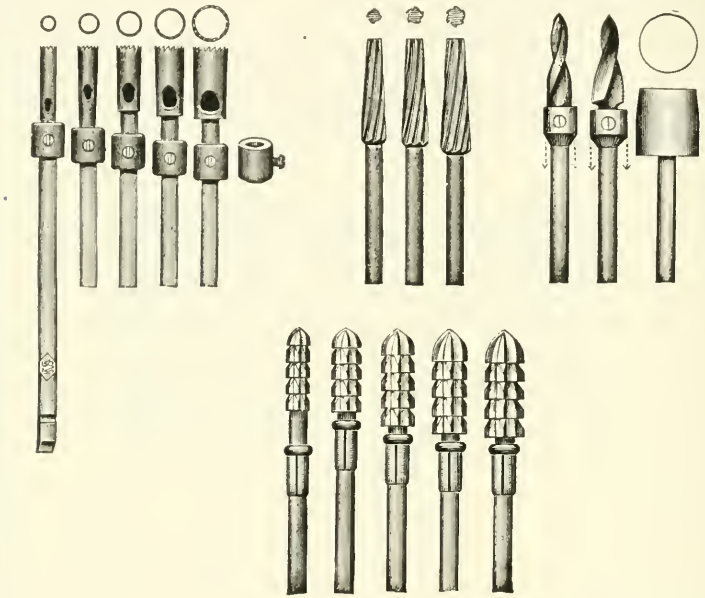

FIG. 300.

The socket is then well sprayed, and carefully swabbed out with prepared pieces of sponge that no debris be allowed to remain therein. A few crystals of resorcin are placed upon the apex of the root, when it is pressed into place and splinted firmly into position, where it must be held from four to ten weeks, as may be necessary.

The same after treatment as described for replanting should be followed here. Strange as it may appear, but little after trouble need be expected.

Difficulties to be Met.—The problem of holding the implanted tooth firmly in place is often a difficult one. Likewise is it often impossible to mount the crown in such alignment upon the root as to have it exactly correct when placed in position in the jaw, this

being due to the socket in the mouth not corresponding exactly with the one made in the plaster cast.

To overcome these the writer has fitted the coping and post to the root and set it with gutta-percha as shown in Fig. 309, and implanted this only. A clasp band is then fitted to the adjoining teeth with a projecting arm and tube, the latter fitting the post exactly. In Fig. 310 is shown such method as it appears in the mouth. By this means is avoided the thickness of the gold splint upon the occlusal surfaces of the teeth, and the opportunity for maintaining aseptic conditions about the implanted root is the best.

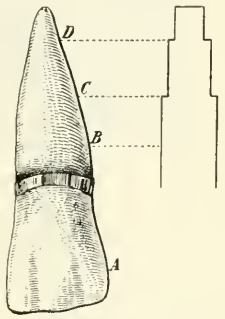

Fig. 307. Fig. 308.

After the root has become firm, the post is readily heated and removed, when the porcelain crown can be added and a perfectly satisfactory alignment of the same be obtained.

By means of the Roentgen Ray the conditions about the roots of planted teeth may be studied with great satisfaction. In Fig. 311 at A is shown a skiagraph of a replanted tooth, and its normal neighbors are seen at B. B. The pericementum is more or less clearly shown around the latter, while it has been obliterated about the planted tooth, the distinct outlines of its root having faded away.

This clearly proves the accepted theory of the attachment of planted teeth, which is as follows: The root of the planted tooth becomes attacked and absorbed at different points, which places are immediately filled in with a deposit of bone. Thus a solid union is formed between the cementum and the socket, the pericementum becoming obliterated.

Fig. 309.

Implanted teeth may be detected in the mouth by tapping their crowns lightly with a steel instrument, the resultant sound being very different from that given off by a normal tooth the root of which is surrounded by pericementum.

The duration of the root evidently depends upon the relative ratio of damage and repair. In some cases, the absorption proceeds exceedingly slowly, in others much more rapidly; but the day finally comes when the attachment becomes too weak to support the crown and it is exfoliated like a temporary tooth. In Figure 312 is shown the remains of an implanted tooth which had stood in the mouth but little over a year.

Figure 313 is a skiagraph of an implanted root, the crown from which had come off. This is a splended illustration of the causes at work around such roots. The lines surrounding the cuspid and central roots upon either side, represent the pericementum. This is absent about the implanted root, it having been obliterated by the process of anchylosis which has taken place. Near its apex can be seen the first stages of the process of absorption.

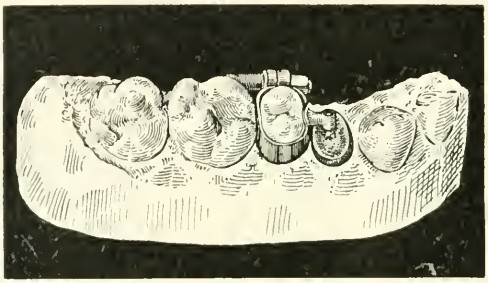

Fig. 310.

In Fig. 314 is shown a skiagraph of a replanted tooth nearing its last days of usefulness. The gold screw with which its apical foramen had been sealed is plainly shown. Notwithstanding the extensive absorption, this tooth is still quite solid and gives no external evidence of its early fate.

Many implanted teeth have lasted from three to six years, while



Fig. 311.

Fig. 312.

Fig. 313.

a few have been reported from ten to fourteen years. The majority, however, fail within two years and some secure no attachment whatever.

The writer considers that implanted teeth which prove of service for five years should be classed amongst the successful and satisfactory dental operations.

Artificial Roots.—Immediately upon the discovery of the loss of implanted teeth by absorption various operators experimented with artificial roots of numerous materials and shapes. Posts, screws, and cribs of silver, tin, gold, platinum, lead and porcelain; all these, and probably others were tried but all proved failures. Dr. R. E. Payne conceived the idea of drilling a perfectly circular socket and enlarging it at the bottom. In this was placed a closely fitting cylindrical capsule which was then filled with soft rubber which upon pressure expanded the capsule and rendered it solid at once. An ordinary continuous gum tooth was then cemented in the capsule as shown in Figure 315.

Fig. 314.

But unfortunately the tissues of the jaw will not tolerate these capsules and they remain in place but a few weeks. One might suppose that if a silver elbow-joint could be successfully inserted in an arm and made to do good service, and silver nails remain in bones in which they have been driven, that a silver capsule carefully expanded in the jaw would also remain in place, but such does not follow, the reason being that the structure of the long bones is different from that of the alveolar process.

Fig. 315.

Fig. 316.

In Figure 316 is shown a platinum capsule which was expanded in the jaw, by an instrument devised for the purpose, where it remained but a few weeks.

In Figure 317 is shown a skiagraph of another of the forms of capsules implanted by the writer, the picture having been taken shortly after the operation. This was held in place by a clamp and tube for three weeks, when this retaining appliance was removed and the capsule appeared perfectly solid. However, about six weeks later it loosened and came out.



Fig. 317.

Sterilizing Agents.—Mercury bichloride, 1 to 1000, forms a good bath for all purposes in connection with these operations. However, natural crowns should not remain in it indefinitely, or they may become discolored.

Hydronapthol dissolved in hot distilled water to the point of

saturation and then filtered, forms an excellent spray for the mouth as well as a bath for the instruments and roots.

Conclusions.—Before writing this chapter a circular letter was sent to many prominent dentists of this and other countries. From the replies thereto, the writer is lead to the following conclusions:

Replanting is practiced by many conscientious operators of this day.

Transplanting is not practiced at all.

Implanting is still practiced by some operators, who, like the writer, believe that under certain circumstances it is advisable.

CHAPTER XXVIII.

PYORRHEA ALVEOLARIS.

BY JOHN DEANS PATTERSON, D. D. S.

The work of writing upon the subject of "Pyorrhea Alveolaris" in a way to enable the dental practitioner to more successfully cope with that most distressing and destructive condition surrounding the dental organs becomes difficult only on account of the fact that members of the dental profession have so often been led to believe by a majority of the writers upon the subject that the disease is the expression of systemic conditions, and that until those conditions are corrected the treatment is well-nigh hopeless.

The operator who is a student of disease, if he gives credence to these statements is also well aware of the fact that the diseases of faulty metabolism, or those resulting in faulty metabolism—which, according to these writers, are largely causative of the condition known as "pyorrhea alveolaris"—are diseases rarely cured or even greatly modified; and we can then readily see that logically the operator hesitates to undertake a task which promises so little success to the operator or benefit to the patient.

At the outset of this brief consideration of the subject the author desires to state, with a confidence based upon observation and experience for over twenty-five years, that the condition or disease commonly known as "pyorrhea alveolaris" is amenable to treatment, effecting a cure as readily and satisfactorily as the other lesions of the dental organs, whether the systemic conditions which affect the progress of the disease are present or absent. The writer is not alone in this belief, as many careful observers and practitioners have proved in their clinical experience the correctness of the statement.

No sane member of the dental profession can rely upon cures in any or every dental pathological condition with an absolute precision, nor can he promise that when a cure is brought about it will be permanent, for always a disease will again be reproduced when like conditions environ which produced the original lesion; but the chances for relief to the sufferer are as promising and as positive in pyorrhea alveolaris as the relief and cure following the process of filling a majority of carious teeth.

The prime object of this writing is to disabuse the mind of the dental operator of a belief in the incurability of the condition in question, and to teach that he should avail himself of all the ways and means to do this work, just as he does for the best methods of filling, crown- and bridge-work, inlay-work, or any other of the usual operative procedures, or he will not do his duty to suffering human beings.

GENERAL REMARKS UPON THE NATURE OF PYORRHEA ALVEOLARIS; ITS ETIOLOGY AND PATHOLOGY.

Upon the best of authority it may be stated that the susceptibility of tissues to the attack of irritants of whatever nature varies greatly in different individuals; and that tissue character is largely of heredity. This is markedly observed in the oral mucous membrane. It is well known that a slight irritant in a given case produces distressing inflammation, and that in another case with the same amount of irritation the mucous membrane is not in the least prejudiced. A small point of calcic deposit which encroaches upon the gingival border at the cervix of a tooth will in one case produce pain and inflammation, and in another, larger amounts of calculus are scarcely appreciable to the patient.

In the last edition of Stengel's work upon "Pathology" this predisposition of tissue to irritation is commented upon as follows:

"The normal system is able to cope with the determining causes of disease to a certain point by its general vitality and regulative functions." "The degree of resistance to irritation differs in different individuals in different races, or with people living in varying climatic conditions. In some the degree of resistance may be so great that certain diseases are never contracted. In other persons there is a recognizable weakness of resistance in one direction or another, which constitutes a definite predisposition. The latter may be either hereditary or acquired. By hereditary predisposition is designated abnormal weakness of resistance transmitted from father or mother to offspring. They predispose to a number of allied affections. This is striking in the case of neuropathic heredity, in which various forms of nervous disease may appear alternately or irregularly in members of a family. In the occurrence of hemophilia we have another notable example."

The disease under consideration is observed by all careful clinicians to often affect each member of a family and their offspring, and the explanation must be found in the character of tissue which exhibits a weakness of resistance and which is handed down from one generation

to another. It cannot be held, however, that this difference is always due to heredity, although it may be safely said this is generally true; for the tissue is brought to a weak condition at times, which has been acquired. General debility from ill health and a starved condition of tissues from lack of nutritive supply frequently prejudice to the attack of irritants. It is quite doubtful, however, that the acquired predisposing conditions, which require usually a long period for the establishment of prejudiced tissue, is more than a minor factor in the causation of pyorrhea.

The mucous surfaces are ever under suspicion of certain characteristic inflammations and ulcerations, but it can scarcely be said that diseases like pyorrhea alveolaris have their inception without local irritation, whatever the predisposing factors may be.

For nearly half a century the most advanced pathologists have granted that even tumors no doubt have a local cause. Whatever the predisposition found in heredity or environment, yet without local irritation of some description the proliferation of cells found in hypertrophy does not ensue. If investigators in pathology tell us this, well may we put at once aside the claim often made, that the condition under consideration is *per se* of constitutional origin or caused by a specific micro-organism. Those who seek for the etiology of pyorrhea in obsure forces should return to the plain and provable logic of cause and effect, and forsake the speculative and unreliable. In the etiology of the condition the following statement may be safely made: *Any irritant, of whatever nature, which impairs the integrity and continuity of the gingival gum margin, may cause pyorrhea; and without this impairment the condition will not be established.* This may be followed by another proposition; viz., *Systemic conditions or a constitutional diathesis without local irritation do not destroy the integrity of the gingival border.*

The irritation which may dissolve the integrity of the gingival border may be presented in various forms. The deposition of the calcareous salts from the saliva upon the necks of the teeth is the usual form of irritation; next in importance may be classed the nests of putrefaction and fermentation about the gingival border and interproximal spaces; again, mouth-breathing dries the delicate border, and thus function is interfered with; and in all these irritations we have the protective reaction of inflammation against a common enemy—irritation. Other irritations may also be mentioned, and include most prominently, banded crowns, careless use of ligatures, the use of wedges, the presence of cavities holding food matter and which is wedged in the process of masti-

cation into the interproximal spaces; also careless operative procedures. It is the firm opinion of the writer, however, that calcic deposits from the salivary secretions combined with food detritus, the nests of fermentation and putrefaction, the changes caused in the mucous membranes by mouth-breathing, the unnatural cervical tooth surface formed by banded crowns, and proximal decay, must be considered the primal and usual causes of interference with and destruction of the relation of the gingival margin of the gum with the cervix of the tooth. The lesion of the gingival border is a result of *continued* (*generally long-continued* and persistent) irritation, such as is found under conditions above stated; and the factor of causation found in wedging, ligaturing, and other temporary interference with the gingival border consequent on operative procedures, can scarcely be cited as active causes for the establishment of pyorrhea alveolaris. In summing up the positive and possible causative factors in producing this disease, the writer's close observation of hundreds of cases confirms the statement that less than five per cent have other origin than that found in irritation from calcic deposits from the mouth-fluids combined with decomposing food remains.

When the first stages of the disease are established by a solution of the integrity of the gingival border from any one of the causes stated, the disease will progress, slowly or with rapid steps, until the tooth is eventually lost. The rapidity of the course of the disease will depend upon the amount of local irritation and the predisposition present; but without hygienic care, remedial measures, or surgical interference, it remains in the majority of cases but a question of time when the tooth investment will be entirely lost and the affected organ exfoliated.

Let us now trace more minutely the pathology involved from the first untoward symptoms.

With the initial lesion and the inflammation of the gingival border there is at once established the condition found in all inflamed territory —viz., the exudation of the contents of the nutritive vehicles, which with the presence of micro-organisms eventually introduces the breaking up of the exuded vessel contents and the adjacent tissue into pus. There rarely is found an exudation which does not soon exhibit suppurative processes. This condition in which exudates and pus are exhibited gives rise to the precipitation of the calcic matter which is invariably present in all exudations, and is deposited wherever a convenient bursa for its reception is afforded. The explanation of the source of the serumal or sanguinary points and plaques found in pyorrhea is the simple and reasonable one, that in all inflammatory con-

ditions there are exudations, and whether they are simple serum, as in the first stages, or pus, as in the later suppurative stages, there is in this matter calcium phosphate, calcium carbonate and magnesium phosphate, and in the changed environment caused by functional disturbance these salts are logically precipitated, and thus form an irritant to the tissue about which it is deposited, inciting by its impact or touch, inflammation of soft tissue and absorption of bony tissue until the tooth organ is exfoliated. In the opinion of the writer, the serumal deposits in pyorrhea are subsequent to the initial inflammation, and are directly from the inflammatory products.

In 1889, in a paper read before the joint meeting of the American and Southern Dental Associations at Louisville, Kentucky, the writer made the claim as stated above, and in substantiation spoke as follows (p. 172–173, Transactions of the American Dental Association, published 1889):

"Now, as a matter of fact, all prominent pathologists agree that accretions of calcic matter may make their appearance as a deposit from purulent matter from inflamed territory *in any part of the human body*. Upon this subject I desire to quote from the Hand Book of Medical Sciences, Vol. I, p. 743, as follows: 'Calcification consists in the abnormal deposit of earthy matter in or around the elements of a tissue, or *in the morbid product of a pre-existing inflammatory process*.' 'The circulation of the blood may be retarded and thus favor the precipitation of the calcareous matter which it normally holds in solution.' 'Calcification rarely, if ever, depends solely upon general causes. There is always a local influence—very often it is due to a pre-existing inflammation. Old accumulations of pus, extravasations and exudations are exceedingly prone to calcification.' 'The simplest mode of explanation is as follows: A certain amount of calcareous matter is a normal constituent of the blood, in which it is held in solution by the carbonic acid always present in sufficient quantity to keep in solution twice the normal amount of earthy matter. When the circulation is impeded, the carbonic acid, because of its great diffusibility, is readily absorbed by the tissues, or goes to form new compounds, necessitating a precipitation of the calcareous matter. *This is likely to occur in all tissues of the body.*'"

After quoting the foregoing high authority, the writer said: "With these facts before us, does the presence of calcic deposits in the pockets of pyorrhea alveolaris still surprise us, and must we yet indulge in vague surmises over its origin?" What I said at that time is a firm conviction today. These deposits are from purulent matter and are the con-

sequence of irritation and inflammation from the various local causes referred to. They are *not precedent* to a lesion, but invariably *are subsequent* to irritation and exudation.

The inflammatory process established with the precipitation of serumal calculus from inflammatory products, the continuation of the disease goes on to the breaking down of tissue as before mentioned, from the impact or touch—the mechanical irritation; and this force is supplemented by the presence of pyogenic bacteria, which in their life processes cause toxins, purulency, suppuration, which by gravitation and capillary attraction, infect and destroy the tooth investment. Soon there is noticed at certain points pockets of increased depth, and they indicate their presence upon the gum by a reddish or purple line. Now the tooth often commences to change its position. It elongates, protrudes, or rotates—drawn by the remaining normal attachments, or by the protective reaction of tissues which seek to rid the economy of a diseased member. This looseness, and the consequent malocclusion, is also an irritant factor. These conditions soon cause a profuse formation of pus from about the diseased teeth, which exudes about the teeth, and in deep constricted pockets the pus at times finds its way through the tissue at the lower point of the pocket and the abscessed condition points as in ordinary alveolar abscess.

When the disease reaches the apical territory, the nutritive vessels to the pulp frequently are deprived of their function, and the pulp takes on a pathological condition which results in its death; and so is added the additional irritation of common alveolar abscess. If the condition of pyorrhea is of long continuance, the root of the tooth in some cases is found to be attacked and absorbed in spots at the focus of inflammation. This has been noticed without the complication of the death of the pulp, though more frequently when the disorganized pulp tissue assists in the irritation. The giant cells often present in continued inflammatory territory in their strenuous attempt to protect tissues are found to destroy them. In pyorrhea the root of the tooth is occasionally observed indented in this manner immediately beyond the subgingival territory.

The above related conditions continuing unalleviated, the entire attachment of the tooth becomes diseased and obliterated and the organ is exfoliated.

In this brief description of the etiology and pathology of pyorrhea the writer has made no attempt to differentiate the various aspects found in the condition which are noticed, and which, in his opinion, need not be classed as distinct conditions simply because the degree of

irritation and the degree of predisposition are different in the different cases and produce various degrees of destructiveness. A "true pyorrhea" and one that is not true is a distinction to the writer not warranted. Because in one patient the predisposition of poorly nourished tissue is present and an apparent (!) absence of local irritation, there is no reason why the condition should receive some specific name, when compared to a perfectly normal patient whose teeth are exfoliated by a disease whose pathology is similar. There can be no objection to denominating pyorrhea alveolaris "simple" or "complex," and when that is done, let us be content to observe its various phases exhibited when observed in patients who have various diatheses influencing its rapidity or destructiveness; but let us eliminate a so-called distinctive nomenclature for the various phases of this disease, unless it demonstrates a better scientific title to such distinction than is as yet made plain.

THE TREATMENT.

Referring to the etiology of caries of the teeth, the late Dr. W. H. Atkinson once said to the writer: "We all have our differences of opinion as to the cause of tooth decay, but one thing remains true: that if we absolutely knew the cause, it isn't likely we could fill teeth a bit better." This leads me to remark that it is very fortunate that while writers and speakers seem far apart upon the etiology of pyorrhea alveolaris, there is a great unanimity of opinion as to the treatment. Upon this we are upon comparatively safe ground, and upon consulting all, we find that whether the disease is considered systemic or local, hereditary or acquired, from degeneracy or faulty metabolism, syphilis or scrofula, catarrh or calomel, mouth-breathing or micro-organisms, ligatures or lithemia, indolence or insanity, wedges or whisky—the treatment is the same. Those who name the condition "interstitial gingivitis," "alveolar ulitis," "phagedenic pericementitis," "calcic pericementitis," "pyalogenic pericementitis," "hematogenic pericementitis," "infectious alveolitis," "odontolithus," etc., etc., agree almost literally in treatment with those who call the conditon "Riggs' disease," or "pyorrhea alveolaris." There is a growing conviction among all that with the removal of all irritating and infectious matter from and about the teeth, and the maintenance of a vigorous oral asepsis, pyorrhea alveolaris, if not too far advanced, is curable.

DIAGNOSIS.

To the inexperienced, rules by which a correct diagnosis may be reached, thus framing a ground for remedial treatment which will

promise a cure, are well-nigh impossible; but it can be safely stated that if a tooth has lost three-fourths of its normal attachment, or exhibits a looseness indicating that nothing remains save a fibrous or ligamentous attachment, the loss of the tooth is usually inevitable and extraction is advised. It has been proved, however, that where it is practicable to place a permanent retainer upon such tooth or teeth, attaching them to those comparatively firm, freeing them from deposits, sometimes changing their position in order to stimulate repair of investment, and maintaining scrupulous hygienic conditions, even these ordinarily hopeless cases are given long life, and the patient is freed from the necessity of bridge work or plates. This must, however, be said: that the loss of teeth is far better than the continuance of those in the economy from which a pathological condition producing infection of good tissue cannot be divorced. Too many practitioners in the treatment of the dental organs, whether for pyorrhea or other morbid conditions of tooth roots, lay too great stress upon the evils resulting from a broken denture from extraction; even if substitution is possible, they subject patients to discomfort and infection, often to an alarming extent, because of their horror of sacrificing a tooth, pretending to argue that mastication, digestion, and nutrition are thereby so interfered with that they choose the lesser of two evils. It must be patent to those of experience and observation that more than one-half of the human family manage very cleverly to exist, and in robust health, with a very limited masticatory apparatus. With a few bicuspids and molars more time is required for sufficient mastication than if the full complement of teeth is present; but it is nevertheless true that with care, a very few pounds pressure, and more time, the ordinary foods can be most properly prepared for deglutition. It is very comfortable to have teeth like a rhinoceros to champ and gnash with a pressure of hundreds of pounds; but the average citizen is not a dockhand who must consume his meals in a few minutes, and if his choice grinders cannot be made comfortable or sanitary by the best skill, then let them be as "the eye that offends."

When the diagnosis is completed and the hopeless teeth and roots are out of the way, the next step is the eradication of disease causes and disease results by surgical procedure; the all-important step, without which no amount of systemic treatment or no amount of local therapeutics will avail to cure or much alleviate the condition.

Preparatory to establishing the surgical work the operator should first obtain a complete history of each case. First as to heredity; find if there is a history in progenitors of loose teeth and loss of teeth with-

out caries; find how long the condition has existed, the character of the discomfort, whether there has been annoyance from bleeding gums, swelling, or a foul taste or odor. Enquire as to possible acquired predisposition and as to what remedial measures or operative procedures have previously been instituted. Examine carefully with delicate explorers, mouth-mirror, and electric mouth-lamp all affected surfaces as to depth of the disease galleries and as to looseness of the teeth.

At this point the next question is to determine if the pulps should be removed from any of the affected teeth upon which operations are to be performed. Some years ago it was quite a popular belief that these affected teeth were in better condition for future usefulness minus the pulps. It was argued that after pulp removal the nutritive supply formerly going to the pulp was switched to the pericementum; so thousands of pulps were sacrificed needlessly and harmfully. Careful observers afterward came to the conclusion that in the treatment of pyorrhea a more rapid and more perfect cure was brought about when the pulp remained, and that the assertion of more nutrition and strength to the tooth's investment when pulp removal was practiced was without scientific basis. It is, however, true that there are two situations in which the pulp should be obliterated before further operative procedures are instituted: first, in case the diagnosis convinces that the pulp is in a pathological condition; and second, to afford anchorage for a permanently adjusted splint for retention. If in the progress of the disease the solution of the integrity of tissue at the apical territory has been accomplished, it may safely be said that the pulp is probably affected, its usefulness past, and it should at once be removed. Again, the irritation causing the pulp to be in a state of chronic irritation may be occasioned by the exposed condition at the cervix of the tooth or below it, on account of gum recession introducing thermal shocks. If this condition is present, the pulp should also be removed. In the second class of cases, the removal of the pulp in order to properly adjust an appliance to retain loose teeth, the operation should be, as in the former case, prior to the scaling operation, as upon the surface of the root from which the pulp has been removed the operation of scaling for obvious reasons is less painful.

There is yet another operation which frequently may be properly performed before proceeding further, and that is the making and cementing to place the retainer to be worn. This will guard against starting the tooth from its socket in forcing deposits away, and also prevent movement of the root causing pain.

RETAINERS.

The operator's ingenuity will show him which of the great number of retaining appliances will serve best in a particular case. Many of the splints or retainers used in orthodontia serve admirably. The purpose of the splint or retainer is to prevent discomfort from movement, to obtain complete surgical rest, without which the formation of repair tissue is prevented.

Now commences the preparation of the mouth by the removal of all micro-organisms and fermentative or putrefactive matter by irrigation. First this should be done by the patient with warm water, followed by water at an increased temperature, up to 140° F. This should be followed by Dobell's solution, which is superior in removing remaining viscid fluids found in the mouth. Now the operator will follow with vigorous use of the syringe of strong force with blunt point, and following with a slim point which will enter the deep pockets and flush out all inflammatory products which are movable. After all possible poisonous micro-organisms and infectious detritus have been removed, the next step is to obtund the tissues to be operated upon, so that the operation may be rendered as painless as may be possible. The injection of the tissue is not advised.

OBTUNDENTS.

For the purpose of obtunding, many preparations have been advocated and many methods advised. It is not our purpose to canvass all of them, on account of necessary brevity, but only to advise, after repeated trial, what seems most effective for the purpose. When the field of operation has been selected, dry the parts and pockets and saturate with the following mixture, for which we are indebted to Dr. Cravens, of Indianapolis:

"Put half an ounce of chloroform in a suitable bottle, add freshly pulverized hydrochlorate of cocain, shaking and waiting a few seconds after each addition of the akaloid until the solution clears. To this add six to eight drops each of oil of cloves, cassia, and menthol, and add to all a flavoring extract to render agreeable."

This mixture seems greatly more effective in obtunding the tissue than all other cocaine solutions used by the writer, and when placed upon a pledget of cotton and pressed into the interproximal space gently at first and then with force, the relief from the pain of removing the serumal deposits is marked. It may here be said that the strongest solutions of cocain may be used in the mouth for various purposes without danger of unpleasant results if the patient is instructed not to

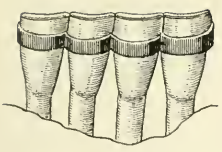

FIG. 318.

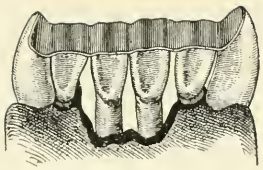

FIG. 319.

FIG. 320.

FIG. 321.

FIG. 322.

FIG. 323.

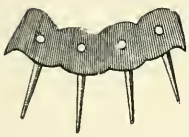

FIG. 324.

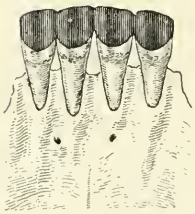

FIG. 325.

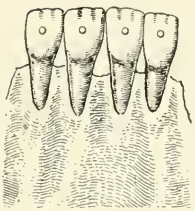

FIG. 326.

DESCRIPTION OF RETAINERS.

FIG. 318 illustrates the commonly adopted method of retaining in a fixed position the lower incisors.

FIG. 319 shows a splint retainer.

FIGS. 320, 321, 322, illustrate the retention of the superior six anterior teeth. FIG. 320 the teeth devitalized and prepared to receive a strong post, FIG. 321 shows the retainer before adjustment. FIG. 322 the appliance cemented to place and completed.

FIG. 323 shows a method of retention for posterior teeth. Pulps usually removed and channels cut in the occlusal surfaces for a strong brace, the appliance is most satisfactory when ihe channel is filled as an inlay.

FIGS. 324, 325, 326 illustrate the authors original device for retention of loose lower incisors. FIG. 324 is the skeleton. FIG. 325 the lingual aspect after completion. FIG. 326 the labial aspect after completion.

The description and making of this retainer is as follows:—

Ligate the teeth firmly in the proper position. In cases of Pyorrhea very often the position of the teeth is changed, but they can be ligated and placed in the position desired. The next step is with the proper drills, a No. 1 round bur followed by No. 2, make a hole through the upper portion of the tooth, within about an eighth of an inch from the incisal edge which will accommodate 21-gauge gold wire. When these cases present we know very well the horn of the pulp has receded, so that there is little danger from encroachment upon the pulp. The next step is to take an impression with red base plate guttapercha of the lingual aspect of the teeth, surround this impression and pour upon it the low fusing metal, which can be done in a very few minutes. In this way a very good model will be obtained. Swage upon that a piece of 22-karat gold plate 36 gauge, place it in the mouth, and indicate with an instument through the holes where the pins should be. Punch the holes, place the wire and solder upon the lingual side. Then put it in the mouth and arrange it and burnish gold to fit exact. Use pure gold if desired. Remove this very carefully without changing its position. Then reinforce with solder the lingual side until sufficient strength is gained. Before putting it on finally, grind or file the plate to the proper shape and polish, and when it is finally completed, place the rubber dam upon the teeth and cement it in place.

After the cement is thoroughly hardened, cut off the pins and rivet them with a round smooth burnisher in the engine, dress off the extra cement and the operation is completed.

There is no other appliance for the retention of the lower front teeth that is so delightful and permanent and that is so readily cleansed. All the gold that shows is the end of the 21 gauge gold wire, which cannot be seen by any one standing two or three feet from the patient.

swallow one drop of saliva, but to eject every particle of mouth fluids. The mixture is also forced into the pockets with the delicate-pointed syringe, and thus penetrates deeper than when introduced with a broach wound with a shred of cotton.

Dr. Austin James, of Chicago, recommends a method of further rendering the use of scaling instruments less painful, by polishing all portions of the diseased root with various forms of wood points used in a porte-polisher and charged with pumice and phenol sodique, and burnishing with suitable forms of burnishers. A test of this method by the writer has given most excellent results. Before this polishing, if there are large plaques of salivary concretions, of course they should be dislodged. Dr. James also advises that only this polishing be done at the first sitting, and that in a day or two the sensitiveness will be less than if the instrumentation immediately followed the polishing.

SURGICAL TREATMENT.

Now comes the instrumentation, and it may at once be said that the instrument which will accomplish the work of removing all deposits and irritant matter from the root, leave it smooth so that repair tissue will form about it, and do this with the least mutilation of the soft tissue, is the instrument to be advised. In all operations involving the gingival tissue it is extremely important that the rope-like border surrounding the cervix of the tooth be not severed or mutilated, on account of the fact that with serious lesion it recovers slowly and is seldom reproduced like the original. So the instruments must be of a form, strength, delicacy and effectiveness not perhaps demanded for any other operation in dental surgery.

Until in recent years, the instruments used and advised have been chiefly those doing their work with a *pushing motion.* In 1886 Dr. G. V. Black, in the "American System of Dentistry," wrote as follows: "The instruments for this operation should for the most part be formed to work with a *pushing motion.* Curved and hooked instruments formed to work toward the hand with a *pulling motion* may be of service in removing the bulk of the larger concretions of salivary calculus, but they are of inferior value in the removal of the last portions of the deposits or for serumal deposits high up under the gum. For this purpose all hook instruments, no matter how delicately formed should be discarded, and slender points made to work with a *pushing motion* substituted."

The advice of Dr. Black, in the experience of all who sought to

treat pyorrhea was deemed good; and while various instruments with a draw motion were formulated, they were found generally to be inadequate, and the *push* instrument first prominently brought to notice by the late Geo. H. Cushing with his admirable and delicate set of six scalers, and other sets with modifications of the Cushing forms, have been the reliance of nearly all who operated for pyorrhea. But the instrument with a *pushing motion* has had its day. Even the stoic cried out against it. It was the despair of those treating the disease with the *push* instrument to daily hear: "Well, my teeth can go; I'll never stand that pain again." Notwithstanding this, many patients, appreciating the beneficent results, would return and submit to the subsequent minor operations often necessary to control the situation. In the meantime those who appreciated and demanded more humane instruments, upon the principle of placing a point beyond the deposits or other irritant matter and displacing it with a drawing motion, were continually advising and devising less painful methods, and with the result that more perfect results with less pain can be secured with properly formed hook instruments.

The dental operator has many times in the past expressed opinions denying the possibility of bettering methods and instruments, but subsequently they have been so improved as to bear little resemblance to what was once considered all that could be desired. The clumsy and impracticable instruments used by Dr. Riggs, which operators at that time thought were well-nigh perfect for the cure of pyorrhea, are now nowhere used save for removal of larger crusts of salivary calculus, and it seems to us an astonishing thing that Dr. Riggs secured such a measure of success with them without first entirely dissecting away the soft and underlying tissues surrounding the root of a tooth. So now we find that the vaunted push instrument must give place to the more perfectly constructed draw instrument, which avoids pain and which leaves the surface of the root in a much smoother condition, insuring better repair of tissue.

The description and illustration of instruments for the treatment of pyorrhea alveolaris which have been evolved by various inventors, and which have led to more or less of success in removing irritant matter from the roots of teeth and brought a measure of success to the originators and those who have placed reliance upon them, is not the purpose of this presentation; but it is the purpose to present in the following illustrations forms of instruments deemed greatly superior in effectiveness to any heretofore offered, their use causing less pain, and of such shapes that all surfaces of affected teeth can be scaled and smoothed,

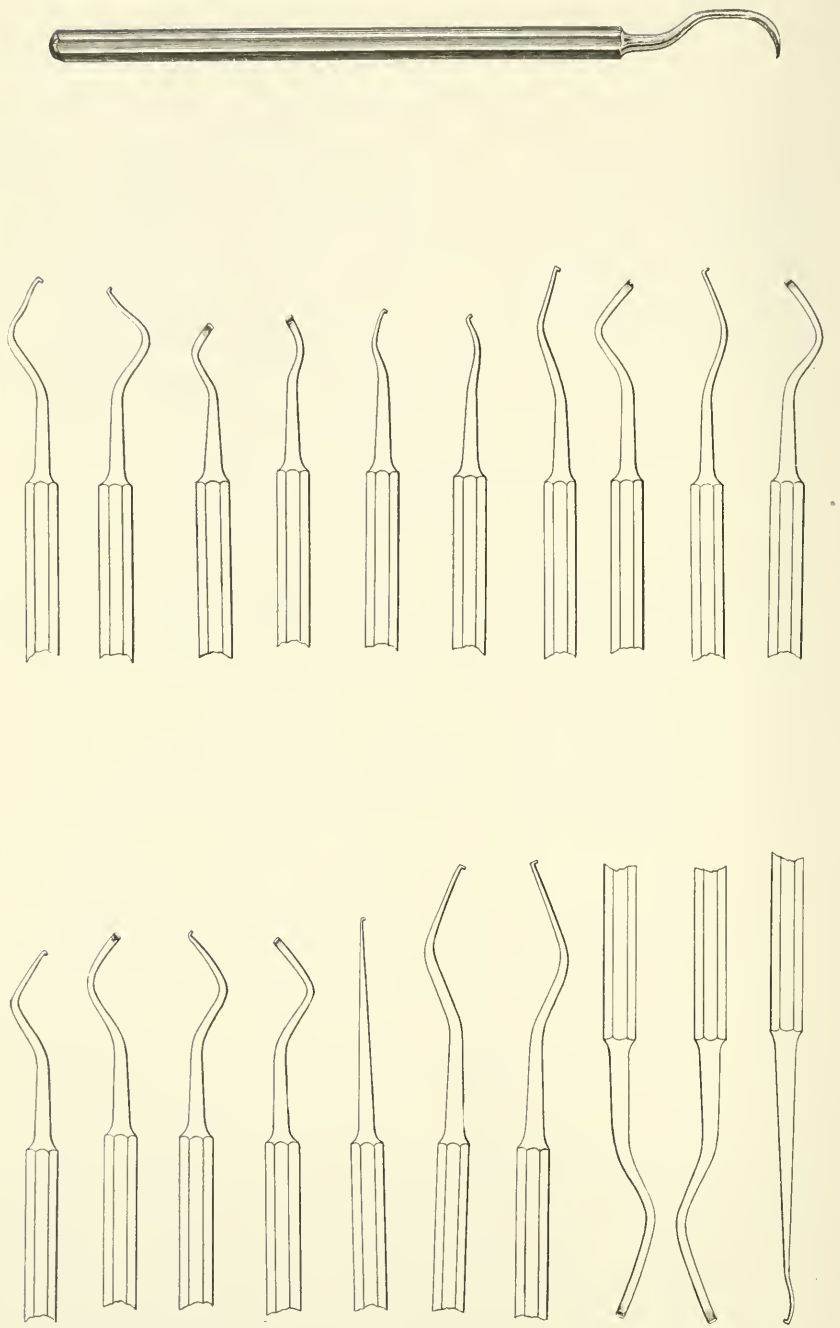

Fig. 327.

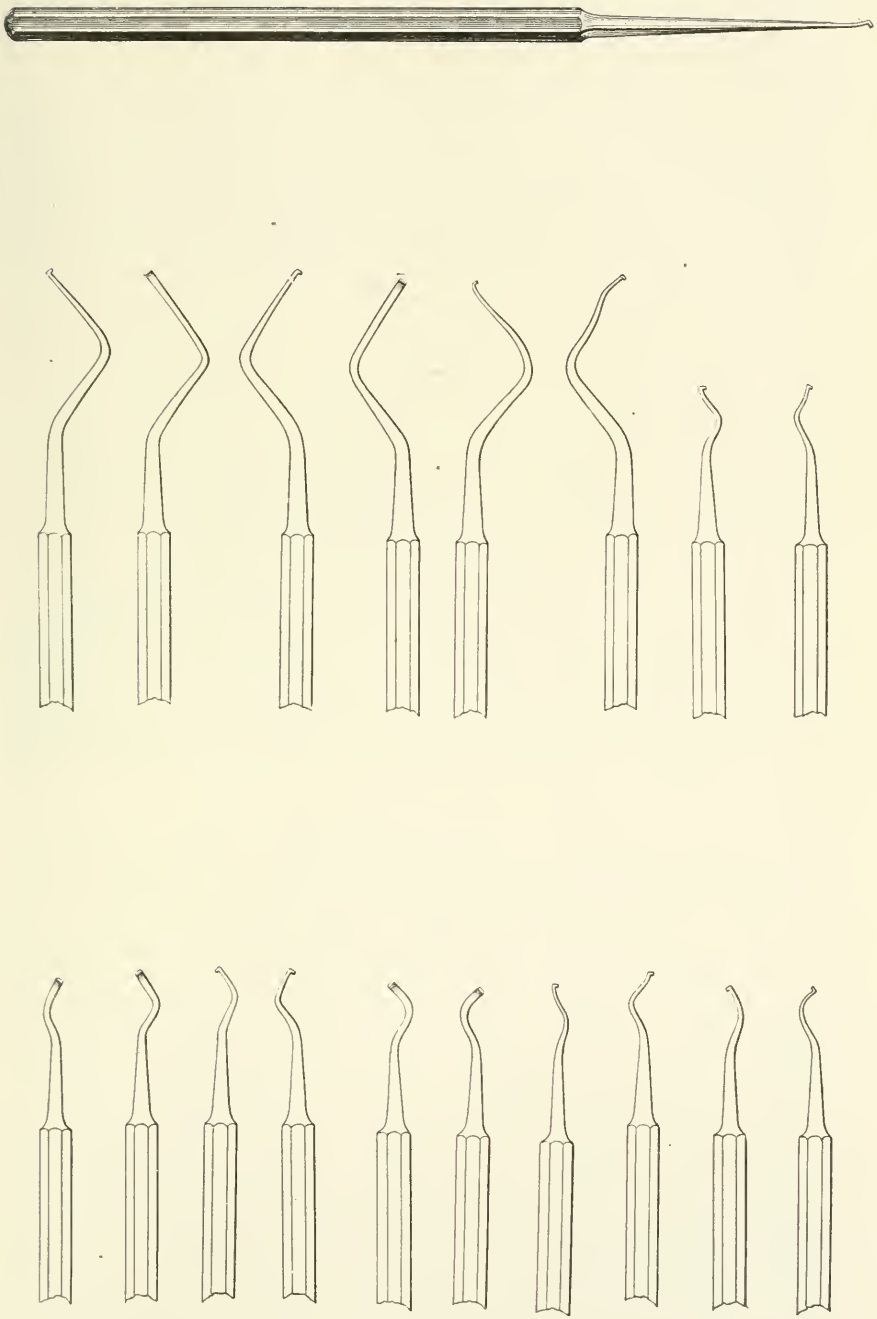

Fig. 327.

which, in the opinion of the writer, cannot be accomplished with instruments heretofore commonly used for the purpose.

The principle upon which these instruments are planned can only be imperfectly described, but may be outlined as follows: The working point is a delicate yet strong hook, designed to be thrust beyond the plaques of calcic matter, which are drawn towards the crown of the tooth, thus dislodging and removing the irritant. Each instrument is so formed that a short distance from the hook the blade rests upon the root, and thus guides and steadies the working point, and also prevents undue furrowing of the root. The hook is rounded upon all corners and surfaces save upon the immediate or cutting edge, so as not to tear or lacerate the soft tissues. The great variety of forms allow the operator to follow the tooth contour with a minimum of pressure upon the inflamed tissue. Thus, the extreme apical territory can be reached and operated upon, if desired, with an entrance between the gum margin and the root of not more than a thirty-second of an inch, which is the usual distance from the working point to the back of the hook. These instruments have little spring, the great variety of shapes precludes that necessity, and the rigidity enables the operator to use great force, which is often essential in removing deposits which have long existed. The working point is constantly on line with the handle of each instrument; thus turning or slipping is prevented, and greater precision without undue force is attained. These instruments have but recently been placed upon the market. The inventor is Dr. C. M. Carr.

The illustrations show some of the primal forms. In the full set each primal form has a number of variant angles and curves, with which different but allied contours of each root and cervix can be reached most perfectly and without unnecessary wounding of tissues. In beginning the operation of scaling, it is wise to select only that number of teeth for one operation which can be entirely finished at the sitting. If the disease is in the incipient stages, frequently a number of teeth can be treated; if the condition is in the advanced stages, from one to four should be the limit. In all cases each operation should be limited to an hour, for, in the first place, whatever the means used for obtunding, the operation is more or less painful; the teeth operated upon are also left in a condition acutely sensitive to thermal changes, and if many teeth are treated at one siting, the discomfort is distressing for many days on this account, so it is surely best to confine this discomfort and the painful scaling to a limited time and a limited area to prevent accumulated discomfort in cervical terri-

tory on account of thermal irritation, and to prevent shock from the unavoidable pain of the operation. With the correct diagnosis as to the extent of the disease and the selection of the suitable instruments, there must be a determination upon the part of the operator that the roots selected to be operated upon at any sitting shall be entirely freed from irritating deposits and the surfaces left in a condition to encourage the new tissue of repair to form. The surgical part is not complete upon the removal of deposits, but after that these surfaces should be smoothed and polished as perfectly as may be. About the crowns and the cervix of the tooth engine instruments with brushes, strips, rubber cones, etc., of a great variety of shapes, are applicable; beyond the gum margin hand instruments must be used. The various wood and other points, held in a suitable porte-polisher and charged with an abrasive, must reach all possible surfaces. Experience has taught that the time spent in smoothing the roots is well worth the endeavor, for the rapidity and permanency of the recovery is greatly enhanced, and the operation cannot be considered completed until as much time is given to the polishing as to the removal of deposits.

The polishing concluded, then comes the removal of all loosened detritus with the hot water used in a strong force syringe with slender special points which will reach well down into the pockets; these points are best made of silver or German silver, and can be fashioned by any instrument-maker.

MEDICATION.

The Pharmacopeia has been searched for the drugs which will best assist to a cure. Each operator has a favorite remedy among the germicides, antiseptics, or stimulants. Some form of an acid has strong supporters; those usually relied upon are sulphuric acid in the form of the aromatic, and lactic acid. There can be little doubt of the efficacy of the acid treatment for the removal of broken-down tissue and the stimulation of involved alveolar processes, but there is a very grave objection to the use of the acids, on account of the fact that the exposed necks of teeth are thereby rendered more sensitive to thermal shocks. The surfaces from which the coating of deposit is removed in any event are a source of great discomfort to the patient in whatever manner they may be treated, and as the acid treatment seems to greatly increase this tenderness, the writer has abandoned its use and substituted a 10 per cent solution of silver nitrate, which, as is well known, renders those surfaces much less painful. Indeed, in very

depraved conditions and pockets of this disease, when the discoloration is not an objection, a saturated solution of the silver nitrate brings results not secured with other drugs. The 10 per cent solution is just short of the discoloring strength. In using the silver solution the parts should be protected from saliva for a few seconds. After this treatment all inflamed and diseased gum tissue should be bathed with drugs or combinations of drugs which stimulate absorption, act as counter-irritants and obtund irritated surfaces.

This completes the surgical treatment, and if the different proceedings described have been faithfully performed, the cure to be in time established now rests largely with the patient. This is an all-important consideration, for it is patent to all that the disease will recur if conditions permitting the original trouble are not entirely corrected. *Each patient must be thoroughly imbued with the plain statement that however faithfully the surgical operation has been, there can be little hope of more than transient relief unless there is a determination that the mouth must continually be kept in a sanitary state.* Observation

Fig. 328.

has taught us how hopeless often is the task of changing habits which are ingrained during a lifetime and betoken a lack of physical cleanliness. Patients suffering from pyorrhea *must be taught by positive and sometimes abrupt but earnest words*, that when they declare their mouths receive the most scrupulous care, they are simply deceiving themselves, and that the supposed care must be doubled and trebled ere a hygienic mouth condition will be present. They must especially be warned that the mouth must be cleansed of food detritus after each meal, and that once during twenty-four hours brushing with unlimited use of a powder for three minutes must faithfully be performed. The usual and universal swishing and dabbing for a few seconds upon only the buccal surfaces must be shown to be well-nigh useless, and that especially the lingual and interproximal surfaces are the points most needing friction. The position of holding the brush and the cleansing movements can best be shown upon the actual teeth in a skeleton or dummy. The brush recommended is one in which the tufts of bristles stand well apart, admitting their reaching between the teeth, and is illustrated in Fig. 328. After the brushing, show

in the mouth how the gums should be massaged with the finger and thumb, firmly pressing the receded gum toward the cervix, thus pressing foreign matter out of pockets and coaxing it to its original anatomical position. Finally, direct that nothing is equal to the cleansing and exercise and scouring in mastication of fibrinous foods, and that the more sensitive the gums are the more the teeth need their natural use. There is scarcely a dental arch affected with pyorrhea where one-half of the arch does not exhibit great difference in the disease progress, and it will be found that the worst condition is invariably upon the side not used or little used in mastication. This neglect of universal use comes of habit, but more often because of a defective arch or tenderness in teeth or gums. Patients must be instructed that safety lies in the use of *all* teeth, and the operator must see to it that he has rendered that possible not only in correcting the gum disease, but in making faulty arches as perfect as may be possible. The frequent use of an antiseptic mouth wash for rinsing the mouth, and to be forced into the interproximal spaces with a blunt-pointed strong force syringe, must also be instituted. A trial of the syringe for home treatment will soon convince any observant operator that therein he has a great help toward a cure. It will be found that after the most vigorous rinsing and brushing, food particles and matter in the imperfect interproximal spaces are dislodged with the syringe which were undisturbed with the brush. Especially is the syringe to be used until repair tissue fills the pockets of disease with new material.

SUBSEQUENT TREATMENT.

If the operation has been well done, it is inadvisable to disturb the pockets, which are soon filled with the plasma out of which repair comes. The very common practice of frequent probing and medicating is *strongly condemned.* Give Nature an opportunity to do the mending, and do not stab the protoplasm thrown from the nutritive vessels with medicine or touch. In sixty or ninety days examination should be made, and if any point of calcic deposit has escaped the initial operation, its position will be easily indicated by an inflamed tissue. This examination will also determine as to the degree of care being given by the patient. If it is found to be very lax, prove it so by asking the patient to take the hand glass, and with a suitable instrument remove the cheesy putrefactive matter, which can only remain under careless brushing. Then comes your opportunity for a lecture containing few words, but they will be emphatic in explaining the uselessness of any possible surgical operation unless followed by directions originally

given. Sometimes we find those instructions entirely forgotten and their repetition asked. On the other hand, do we find that great care has manifestly been observed, never fail to give warm compliment.

SYSTEMIC TREATMENT.

When pyorrhea is accompanied with any predisposition, whether hereditary or acquired, which lends to the virulence of the disease, such systemic treatment for the correction of the predisposition as found advisable should always be relegated to the patient's medical adviser. It is a breach of ethics if the doctor of dental surgery invades the general field of medicinal treatment by the administration of internal remedies for the correction of faulty metabolism or systemic conditions from whatever cause.

CHAPTER XXIX.

EROSION.

BY GEO. W. COOK, D. D. S.

The word erosion is taken from the Latin erodere, which means to gnaw away. Under some conditions the term is applied to ulceration. In geological parlance the word is synonymous with denudation. The term is frequently used in pathological conditions of plants; as, for instance, if an insect has stung or poisoned a plant, causing a loss of substance to a particular locality, the diseased part becomes perfectly smooth on its surface; this process is also called erosion. The word is likewise occasionally applied to certain conditions of the mucous surfaces of tissue where it is aphthous. In some of the ancient medical writings aphtha and erosion were commonly used as meaning one and the same thing; but at the present time the connotation of these two terms applies to different conditions. The term erosion, as applied to the teeth, is usually looked upon today as a process whereby certain surfaces of the teeth gradually disintegrate, leaving a perfectly smooth expanse. However, it must be remembered that when these surfaces disintegrate, that is, when they occlude with the opposing teeth, it is not considered erosion but abrasion.

Dental erosion, as it is understood at the present time, is for the most part confined to certain surfaces of the teeth in which only the mucous surfaces of certain soft tissue come into direct contact with the tooth substance. However, it has been observed that this pathological process sometimes appears on tooth substances where the surface of a tooth does not come in contact with the soft tissue. Hutchinson, of England, applied the term to certain conditions where the incisal edge of a tooth showed marked imperfections in the form of a semilunar appearance; a tooth in which these conditions are found we speak of as the Hutchinson tooth. But this in the stricter sense of the term is not erosion. Dr. G. V. Black, of Chicago, associates this class of condition and many other forms of congenital imperfections of the teeth with atrophy; but in no sense are erosion and atrophy alike.

As we have just stated, dental erosion is now used to mean a gradual wasting away of tooth substance, leaving the surfaces of teeth as if they had been carefully polished. The condition may be present

on only one tooth, or on a large number of teeth, sometimes involving practically the entire set of teeth. Sometimes it appears as if a fine rat-tail file had been the instrument used to make these notches or grooves. The condition more commonly appears in the anterior teeth. The labial surface of cuspids, laterals and central incisors are the ones that are most commonly involved in this process. It may attack the lingual surface of the bicuspids and molars along the gingival border, but this is by no means as common as on the buccal surface. My attention was called to a case in the infirmary, in which the surface of almost every tooth in the mouth was involved. I think, however, that such cases are very rare in comparison with those of the more common attacks, which, as I have already stated, usually take place in the six anterior upper and lower teeth. In another case there was a notched or grooved appearance on the lingual surface of a lower lateral incisor, extending diagonally across its lingual surface; the groove starting on the mesial and extending diagonally from the upper third of the incisal edge to almost a point of the juncture of the enamel with the cementum, and in the deeper portion extending well into the dentin of the tooth.

The tooth surface that becomes involved in this affection is ordinarily situated where there is friction, which is made by the tooth-brush or some other like means of cleansing the teeth. It might also be said that erosion appears in individuals who have never known the use of a tooth-brush, or who cleanse their teeth by any other means such as by chewing food. I have in mind two cases in which there was extended involvement in the ten anterior teeth of the upper jaws, the individuals claiming that they had never used a tooth-brush, or any other means by which it may be said that friction could play a part in the conditions of these cases.

So far as the writer has been able to find out, John Hunter, of England, in his natural history of "Human Teeth," is the first to give a description of this affection. Since that time a number of authors have contributed many hypotheses for this pathological process, and each has tried to explain the reasons for believing that such and such factors are the real cause of this affection. Hunter's original idea was that the disease was inherent in the tooth substance itself, and that the disease appeared later in life because of certain circumstances, but these circumstances he did not account for.

Bell, who was among the early writers upon this subject, held that this process was a mechanical one. This author's principal reason was based upon the circular deposits of the enamel substance.

Garretson considered the difficulty to be due to an impression, such as that from inheritance, upon the individual at the time of the formation of the enamel, in which it left a predisposition in the tooth substance to the formation of the future lesion. Fox laid considerable stress upon the fact that the affection was due to the friction of the lip, assisted by the saliva. Harris and Taft place the cause as due to an acid condition of the buccal mucus. Nuhn explained that erosion on the cutting edge of the front teeth was caused by an acid mucus excreted from certain glands in the tip of the tongue. Weal's observation was that this affection never occurred on the lingual surface of teeth, and that the trouble must be sought on the buccal and labial surfaces. His explanation of this was that the folds of the mucous membrane of the dental arch gradually become narrower, and terminate with a ridge of connective tissue which is attached to the necks of the bicuspid and molar teeth, a condition which may extend along the facial surface of the gums of the lower jaw.

In the *Dental Cosmos*, 1873, Dr. Charles Koch gave a descriptive explanation of the difference between mechanical abrasion, caries, and erosion of teeth. He believed that because erosion could not be produced artificially or mechanically, just as it appeared in the mouth, that the pathological process was a congenital or acquired predisposition aided or abated by chemical reagents, or perhaps by mechanical means. In this particular there seems to be some confusion as to just what the author did mean.

Baum believes that where the dentin of the tooth is not covered by gum tissue or enamel, this exposed surface of dentin exfoliates and mechanically falls out of its position, and by the friction of the lips and brush the surface of the tooth becomes polished. In 1880, W. Finley Thompson made an extensive study of the difference between caries and erosion, and wrote a very interesting paper on this subject at that time. He says, "caries of the teeth may attack apparently strong tooth structure and semi-decalcify the dentin of the tooth, which will retain with great tenacity its connections with the normal tooth tissue, but erosion seems fated to complete disorganization and this continues until considerable surface of the tooth is destroyed, leaving a polished surface."

Dr. Edwin T. Darby expressed his opinion that the general affection known as erosion was produced by an acid in the buccal mucosa, which was intimately associated with rheumatic and gouty conditions. C. Edmund Kells expresses the belief that it is due to an acid excreted by the mucous glands on the labial and buccal sides of the teeth.

Fairbanks, of England, laid stress on the fact that erosion of the teeth was due to the decomposition of undigested food in the stomach, and usually appeared in mouths that were exceptionally clean. Stockton held the opinion that erosion of the teeth was due to certain gouty conditions which produced a general acidity, and that an alkaline tooth powder arrested the progress of the disease. Bailey laid considerable stress on the mechanical action of the fluids of the mouth. He says: "In the first place, all cases of erosion are in a position subject to the action of the oral fluid currents, which take varying directions in different mouths and even in the same mouth." He further says: "We know that a running stream can easily be changed, and in this way we are liable to have the mechanical friction produced by the current of flow of the fluids of the mouth."

Billetter, of Zürich, also holds to the mechanical theory. W. H. Trueman believes that it is due to chemo-vital causes and that the excreting of the fluid is necessarily a chemical process. The idea that this destructive agent must be an acid having affinity for the lime salts of the teeth has but little tradition to support it. The little cap which we frequently see, mainly of enamel, and all that remains of a baby molar, is sufficient evidence that there may be, and is, formed in the oral cavity a true solvent of tooth tissue. This effect has been produced by a normal physiological process. He farther suggests the stomachic digestion as being parallel to erosion and excludes "chemism" as being only a minor agent. Prof. James Truman considers the process of erosion and abrasion as extremely simple; he says that they are governed by the law of chemical action and that erosion is unquestionably the result of a chemical solution.

Dr. G. V. Black, in the American System of Dental Surgery, published the results of some experiments in using the dilute solution of hydrochloric acid 1–400. He recorded in one experiment how he took two fresh, healthy bicuspids and covered the greater portions of them, roots and all, with gutta-percha, exposing only the crown. These were then placed in a jar containing diluted hydrochloric acid, the teeth being arranged in such a way that the current would impinge upon the outer surface of one tooth with greater force than upon the other. This resulted in the disappearance of the cusps and the formation of the groove between the teeth. The groove was more marked upon the one receiving the greater force of the current. A large number of other observations were carried out and it was found that the strong solutions produced general softening of the teeth, while a solution of 1 of acid in 5000 of water had no appreciable effect

after three months. Dr. Black, however, did not try this experiment with any other substance than hydrochloric acid. I tried to duplicate Dr. Black's experiments but did not get the marked effect that I had expected. I took a U-shaped tube that was somewhat similar to the tube used in the apparatus designed by Kohlrausch. In this tube was placed a perfectly sound tooth, of which all but a small portion was covered with wax. Various solutions of acids and neutral salts were placed in this tube and an electrical current was passed through these solutions at alternate intervals. It was found that all the neutral salts, with but one or two exceptions, did not produce any disintegration of tooth substance. But all of the acids, even though they were in the most diluted form, did produce disintegration of the tooth substance when a mild current was passed through the solution. There are so many points of physical chemistry that enter into this process that it would be quite out of place to detail them here. But we might say this, that the conductivity of saliva differs in different individuals, and that those suffering from dental caries have a saliva with a high conductivity, which shows that there might be some of the strong acids present; while in the simpler form, or we might say in the mild forms of erosion, the saliva has a low conductivity, showing that there is some difference in either the acids or basic salts in the colloids in the saliva. The organic acids affect teeth very differently when an electric current is passed through the solution from the way the mineral acids (monobasic acid) affect them.

The above observations, to a certain degree, help to substantiate the electrical theory. In other words, in the saliva of mouths, whether or not we have acids, we have many of the electrolytic salts which exist there not as salts so much but as associated ions. This means that an atom of sodium, potassium, magnesium, etc., is charged with electricity. Therefore, they are in constant motion in the solution, it matters not how apparently quiet the solution may be. The substance in the saliva containing the negative ions is constantly passing and combining with the ions of a positive nature. Consequently all the fluids of the body that contain electrolytic salts are constantly producing molecular activity of the solution. Thus, in the acids, atoms that make up the acid groups in the saliva have a very low activity.

Tomes was of the opinion that the true and only cause of the difficulty was a mechanical one. Schlenker, Walkoff, Scheff, Bastyr and Brandt have all expressed their opinions that the disease is the result of a chemo-mechanical process. They have placed stress on the

chemical side of the question, thus suggesting that its one cause is a thin layer of decalcification of tooth substance, which is removed by the cleansing process.

Miller's recent investigation seems to indicate, from his viewpoint, that the mechanical action of substances such as tooth powders, or any agents that will produce friction, is the main factor in causing the wearing away of the surfaces of teeth. From all the observations, with but few exceptions, it seems to me that this is true. However, there are physical and chemical properties of saliva that, beyond any question of doubt, must play some rôle in this obscure process. I have in only a few instances been able to produce the eroded surface exactly as it appears in the mouth. I have produced erosion of teeth with practically all of the tooth powders and mouth washes that are today on the market, but in the vast majority of instances it does not appear identical with the cases found in the human mouth. I have in mind a patient suffering from erosion, in whom the care of the mouth has been practically neglected, so far as brushing the teeth is concerned. She tells me that she was trained from childhood up not to scrub her teeth, but to wash them with a smooth, soft cloth, and to do so once or twice a week only. The rest of the time the mouth had no care except a rinsing with water. She has well-defined eroded surfaces on the cuspids, lateral and central incisors, and more recently on the bicuspids. This case, with similar observations, would hardly justify us laying much stress upon the mechanical cause of erosion of tooth surfaces. I think the majority of observations that have been recorded are to the effect that the diverted activity of the mucous glands is the principal cause of the disease. This is the most prevalent opinion held by the majority of writers upon the subject; and beyond any question of doubt in my mind, it is to an explanation of this nature that we are to look for the best light on this pathological lesion.

W. X. Sudduth brought forth the hypothesis that this affection was due to a lowered nervous condition which resulted in a salivary acid. There may be an element of truth in this statement. According to the investigation of Halliburton most all tissue contains a mucoid-like substance; and according to Mörner there is to be found in such tissues a chondromucoid, which has the composition of the following elements: C. 47.30, H. 6.42, N. 12.58, S. 2.42, O. 31.28. When this is extracted from the tissues it has an acid reaction and becomes insoluble in water. If it were possible to take living tissue, the activity of which is largely confined to excreting a mucoid-like substance,

we should find that this tissue goes through certain chemical reactions in which hydrogen plays an important part.

There are a number of acid molecules which appear in the chemical manipulation of that group of acids belonging to glycuronic acid. Galactose is also present in mucoid substances, occurring for most part among the hexoses. When split apart the latter will yield dextrin and furfurol, which can be oxidized into mucic acid. In the *Dental Review*, May, 1906, was published a brief article entitled, "The Rôle Played by Certain Acid Derivatives of Lactose in Erosion of Teeth." At that time I was strongly of the opinion that mucic acid would dissolve tooth substance with perhaps a degree of success. But an interesting fact developed that this acid was easily and rapidly broken up by certain bacteria, and especially by those that are constant inhabitants of the oral cavity. Thus it was found that mucic acid had to be kept under aseptic conditions when acting on the tooth substance, otherwise it became quickly broken up, forming alkali that did not affect the tooth. It was also found that the teeth had to be kept in fresh solutions of the reagent, for as soon as it had acted for a few hours on a tooth it extracted enough of the neutral salts out of the tooth substance to neutralize the mucic acid solution. I have also noted a vast difference in the teeth to be acted upon by the mucic acid as well as many other agents, and that some teeth are far more easily acted upon by an agent than others.

As I have stated before, experimentally I can produce erosion with a large number of agents, but I have never yet been able to produce any but what were atypical, rather than typical, by anything except mucic acid.

However, it will be remembered that galactose is not always one of the derivatives of the hydrolytic splitting. In the article above mentioned, it was shown that the saliva might contain relatively large quantities of mucoid substance, containing the precursor of mucic acid; and by hydrolytic oxidation these substances would easily give rise to mucic acid. For instance, in such conditions as pregnancy, and various other constitutional changes in which these agents are present, this combined material might under favorable circumstances produce what is usually designated as acidosis and hyperacid secretions of the mouth, which might furnish a mucin easily oxidized into the various agents above mentioned. I am now more convinced of the possibility of such changes being so produced than I was at the time the article, referred to, was published.

I followed experiments on animals by bathing the mucous surfaces

for a considerable time, using many times friction with various agents. It was observed that many of the substances that we use for the purpose of producing disinfection of the oral cavity, when used at intervals for some time on the mucous surface, produced degeneration of the tissue cells. The tissue, removed and stained by me, immediately gave an acid reaction. The micro-chemical process is one which at the present time is looked upon as one of the valuable means of determining the alkalinity or acidity of the tissue elements. It would be quite out of place here to give the methods used in this connection. Suffice it to say that any one who is interested in this phase of the subject is referred to the work of Cross and Bevan.

According to the investigation carried out by Acree and Hinkins, they found that acid saliva containing sufficient amount of acid to produce erosion or wasting away of tooth substance may flow directly from the salivary glands. In nearly all of the works on physiology we are told that the saliva may be neutral or alkaline under ordinary circumstances; but, according to the investigations of the authors just mentioned, acid saliva is more common than we are ordinarily led to believe. It is not only possible for the mucous membrane to have an acid reaction given off from it; but it is also possible for the saliva, taken directly from the salivary glands, to contain acid in sufficient quantity to give a reaction. Many times the acidity of the saliva taken from the salivary glands contained as much acid as was found in the oral cavity where it had been under the influence of bacterial changes.

All of this goes to show conclusively that the body substance, under ordinary circumstances, and that certain organs and tissues, are specially subjected to certain physiological changes that bring about an acid condition of the cells and tissues, as well as of the organs from which the secretion is taken.

The investigations by McGuigan and myself have clearly demonstrated to my mind that we seldom, if ever, have lactic acid present in the oral cavity. With all of the tests we could make, by electrical conductivity and by optical determination, in which we polarized the saliva that was acid, we did not find an optically active, lactic acid. From these and other tests we are led to believe that the acid saliva of individuals affected by erosion, and of many suffering from dental caries, does not contain lactic acid. However, I might say that we did take the scrapings from decayed teeth and placed them on a microscopic slide and found, with the additionof metallic zinc, that had been previously prepared for this purpose, that there were crystals formed

that gave the appearance of lactate of zinc crystals. But our work on this particular phase did not give very satisfactory explanation as to the kind of the acid.

There were so many isomers of lactic acid formed and these differed so materially from the molecule formation, one from the other, that it was extremely difficult to say whether or not we had a lactic acid or some other organic acid present. We found many crystals that assumed practically the shape of the zinc lactate crystals. I think a careful review of the work of Hinkins and Acree will show that the crystals formed under such circumstances are very unreliable. Owing to the lack of space we cannot discuss this phase of the subject at this time; suffice it to say, however, that our opinion up to the present time is that lactic acid does not play any role in the cause of erosion of teeth. We are, however, of the opinion that an acid is present in all of these conditions, but that in the majority of instances friction must be applied in order that the dissolution of the surface of these teeth will assume a smooth, glassy-like appearance.

Monobasic acids never give a typical eroded surface. The acids that come the nearest to giving a typical erosion are those organic acids that contain the largest number of the hydroxyl group.

If we review with care these theories which I have quoted, it will be observed that all these theories deal with but one or perhaps two factors. The work I have done leads me to but one conclusion, and that is we have dealt with this problem in an elementary way. It should be remembered that all vital processes are of a complex chemical nature, and that erosion of teeth is a physico-chemical change of a greater complexity than most of those that have been suggested up to the present time. I can, as has already been stated, produce erosion with almost anything, even with water and a stick, but it is not typical under the microscope. Therefore we cannot say but what erosion of tooth substance is a complex process and not a simple one, in the sense that most writers have placed this subject.

TREATMENT OF EROSION.

The treatment of erosion is for the most part mechanical, and involves the cutting out of the eroded surface and the filling it in the ordinary way. One of the great advances made in dentistry is that of the application of porcelain in just this class of cases. However, I have met with considerable success in using certain agents in the treatment of this affection, and my greatest success has principally been in the use of nitrate of silver, especially in the first stages of this

process. In the early use of this agent I thought its effects were produced by its action on the eroded surface of the tooth, but later I observed that its benefits were principally due to the action that it had on the mucous secretions in the location where the treatment was applied. In other words, when the treatment was applied to the eroded surface of a tooth, it would necessarily come in contact with the mucous glands, and in this way change the secretions of these glands; so that whatever chemical agent was acting upon the tooth surface was in some way or other destroyed.

Dr. D. M. Cattell called my attention to a case in his practice in which I advised the use of nitrate of silver, as a painting over the mucous surface which came in contact with the eroded portion of the tooth. He followed this treatment at intervals for six months or a year, and he tells me that the erosion has practically subsided. The care of the patient's mouth has been just the same as it had been previous to the treatment with nitrate of silver. This, with a number of other cases, demonstrates to my mind that we have to look to the mucous surface more or less for the stoppage of this process.

There are certain forms of tooth degeneration that are not strictly, in all respects, like that of erosion. Sensitive cavities appear at the gingival margin, so sensitive many times that it is quite impossible to touch them. This class of cases sometimes can be successfully treated with the application of a saturated solution of caustic alkalies like sodium and potassium hydrate. After two or three applications of this saturated solution, from one to three days apart, take a dull engine bur and run it over these surfaces at a rapid speed, which will lessen the sensitiveness of the cavity. If such applications do not suffice to relieve or arrest this process, then a saturated solution of silver nitrate should be applied. When the discoloration from the silver nitrate has fully formed, which always gives an unsightly appearance, an application of tincture of iodine to the discolored tooth tissue, followed by ammonia, will usually remove all the stain. In the application of nitrate of silver to eroded surfaces, regardless of where these surfaces may appear, I use a saturated solution. I then remove the stain, in the manner above described, or by polishing; the former being much better than the latter.

In writing this article I have tried to weigh with care the theories and ideas heretofore held by different authors regarding the cause of erosion. I have only quoted from those who seem to give the most reasonable hypotheses on the subject. I have arranged the subject matter, as near as possible so that the readers might analyze the sub-

ject for themselves, and possibly aid them in a more careful observation of the cases that come under their care. Time and space do not permit me to quote all of the writers upon the subject as I should like. Suffice it to say that much of the material that has been written is very hard to analyze and secure the exact interpretation of the authors' ideas and just what was being formulated.

CHAPTER XXX.

THE MANAGEMENT OF AN OFFICE PRACTICE.

BY ELLISON HILLYER, D. D. S.

When college and state board requirements have been fulfilled the graduate student faces the problem of applying the result of his preparatory training to its ultimate object—the practice of his profession.

Two paths open before him; either he may enlist as the assistant of another practitioner with the aim of acquiring by close contact that experience which only the atmosphere and surroundings of an office can give; or, he may elect to begin at once his career upon his own account, relying upon his college training as sufficient. In either case it is but a beginning and each should feel that nothing but an assiduous devotion to the highest ideals and constant pursuit of further knowledge can lead to any measure of success.

By the time a student has received his degree and license to practice he should have learned to regard his profession as among the most dignified and worthy of all he can give to it. If a student regards it as but "a means to an end" he should press the question further and ask himself "what is the end?"

He has probably heard it said many times that he will hardly grow wealthy by the practice of dentistry alone; if wealth is what he seeks, then let him choose some other path. The status of the profession was never elevated by one of its members seeking affluence through its channels but it has been raised to its present high position by the self-sacrifice of *those who have given more to it than it to them.*

Embued with this spirit and settled in conviction as to just what "success" really means, let each go forth prepared to do all in his power for those who will come into his care; let him remember that he has been trained to serve and that it is his place to give the best that is in him with no thought of the public as existing for his benefit.

Were this spirit to animate all our graduates the quackery which is the bane of our profession, as it is of all professions, would cease to exist. The beginner argues that "he must make his living" and proceeds to make it by whatever means present. This is short sighted as no great

success, in the highest sense, was ever achieved by lightning strides but by slow consistent proceeding. Thus only can a man hold his place as a professional man. If he prefers to prostitute his ideals and make of his profession a "business," with fillings and dentures at so much per filling and denture—that "so much" being usually as much as he can make the patient pay—he must be satisfied to take his place outside the professional pale and realize he has none but himself to blame.

In the locating of his prospective office the student has to consider several things; surroundings, ease of access, availability of space and arrangement of reception and operating rooms. Of the first two nothing need here be said; of the latter much might be noted.

For the best results three rooms are needed; the reception room, operative office and prosthetic laboratory. To the first may well be added a retiring room fitted with various toilet requisites. The reception room should be made as attractive as possible. The general atmosphere should be one of refinement and good taste with everything to detract from the unpleasant side of a visit. Good literature, magazines and books should be at hand to occupy any spare moments of a waiting patient. Attractive fittings and interesting pictures should be provided to catch the eye and by suggestion take the attention of the patient away from himself. Have some one—preferably a lady—in attendance, as much more ease is given to both patient and operator by the judicious services of a competent lady assistant.

In the fitting of the operating room two plans are offered; one upon the design of a general surgical operating room, accomplished by having a cemented or inlaid floor, enameled walls and ceiling, enameled (usually white) iron chair with leather fittings, enameled iron cabinet, etc., with glass for all shelf work. These fittings are all obtainable and make an admirable outfit for anyone who cares to go to that extent.

The other plan admits of cheerful surroundings; hard wood floors with rugs, pleasing draperies and pictures with the use of glass *wherever instruments are to come in contact with tables, brackets, etc.* Several illustrations of offices may be found in the pages of the *Items of Interest*, Vol. XXI, which would give many valuable ideas to beginners regarding the fittings of an office.

Difference of opinion exists as to the proper size of the operating room; this need be no larger than is required for the operator to stand by the operating chair within easy reaching distance of the instrument cabinet, dental engine apparatus and electrical equipment; much time is saved by having everything within easy reach. When

a larger room is used *this same arrangement should still be maintained about the chair* while other appurtenances, such as an office laboratory work-bench, tables for porcelain furnaces and an office desk may be introduced.

While many beginners may not plan to make a start in what today is considered a thoroughly equipped dental office, yet sooner or later



FIG. 329.

each will come to the point where he will desire to so equip his office and he will find many labor and time saving devices at his disposal.

Electricity admits a large field of application, used as it is in the dental engine, lathe, sterilizer, annealer, heaters of various kinds, syringes, both air and water, cauteries, etc., to say nothing of the light, illuminating the room and providing by low power lamps for oral, and by higher power for antral examinations.

Compressed air is another most useful ally. A convenient tank of the capacity desired may be placed either within the operating room or in a place as far removed as the operator wishes. This tank may be filled by means of either hand, foot, electric, or hydraulic pump (Fig. 329). The latter two keep the pressure at the full capacity of the tank —operating automatically as the air is used.

The uses of compressed air are legion; primarily, with the air syringe attached, any force—up to the capacity of the tank—may be registered upon the dial, giving a continuous "chip-blower" action. If this syringe be supplied with the hot air electric coil attachment, by the turning on of the current, regulated to any degree of heat desired, the air becomes a warm blast.

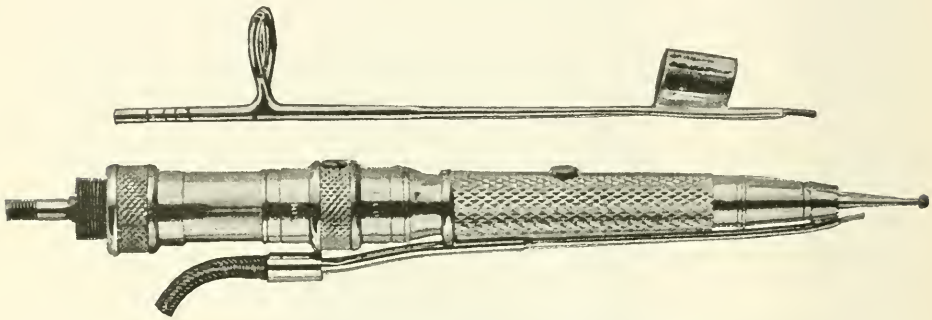

Above cut shows its application to the hand-piece.

FIG. 330.—ENGINE HAND PIECE—CHIP BLOWER.

This instrument keeps the field of operation free from debris, permits of continued operation, thereby shortening the time at least 50%. It also minimizes the pain produced by the heat due to the friction of the burr in excavation.

A very practical compressed air syringe attachment has been devised by Dr. F. T. Van Woert, of Brooklyn, N. Y., and manufactured by L. Green, of New York, N. Y. (Fig. 330).

It consists of a very fine silk covered tube, leading from a controlled outlet to an atomizer nozzle attachable to the engine hand-piece. This gives a direct blast of air upon the surface requiring operation, freeing the area from debris of cutting and acting as an obtunder by overcoming the heat incident to the friction of the burr in cutting.

Both electricity and compressed air may be controlled upon one switch-board (Fig. 331) within reach of the operator's hand while standing at the chair.

In choosing an instrument cabinet certain things should be considered, whether the cabinet be an inexpensive or a costly one; compactness, adaptability to personal needs, and, if fitted for medicines,

that there should be provided for them a separate compartment—one which will as effectually as possible prevent any odors from escaping. Many practitioners keep medicaments in common use in their re-

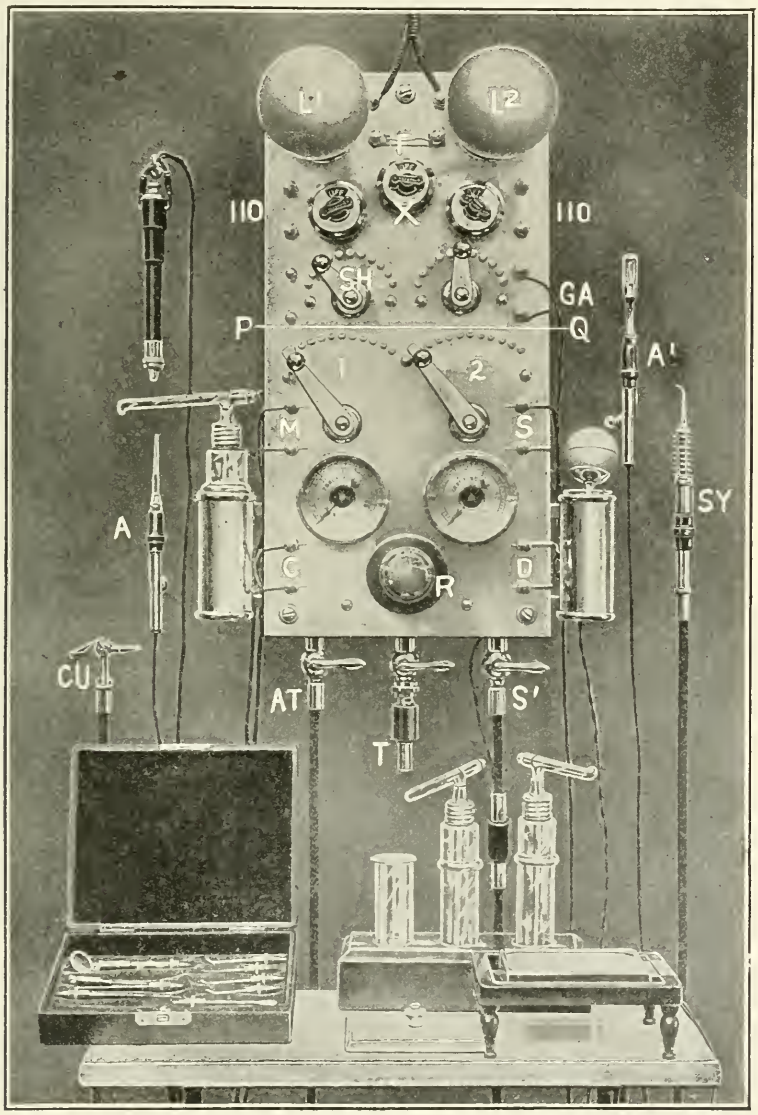

Fig. 331.

spective vials under a glass cover. No office is atttactive if permeated with odors of any kind and the greatest care should be exercised to prevent their presence.

Running water is essential in the operating room. Fountain cuspidors may be obtained in great variety, suited in price to any purse, and offering one of the most indispensable aids to the operator. This may be stationary or attached to the chair. A wash basin should be in plain sight that the patient may be assured that the operator follows out the necessary ablutions before each operation.

The prosthetic laboratory should be within easy communication, but sufficiently removed from the other rooms to insure freedom from

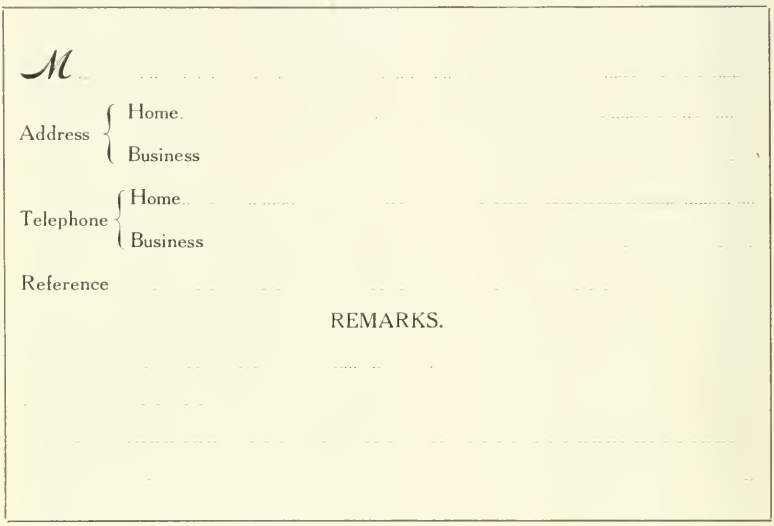

FIG. 332.

odors or noise reaching them. The description of the fitting of the laboratory is best delegated to works upon prosthetic dentistry.

If extraction forms a part of one's practice, a separate room should be provided for the specific purpose, fitted with the necessary chair, anesthetizing apparatus, cabinet, running water, etc.

RECEPTION OF PATIENTS.

The manner of the reception of patients should be given careful consideration. The beginner will naturally commence his operations upon such of his personal friends and acquaintances as seek his care. These in turn will be the means of sending others. The referring of a new patient, by either friend or fellow practitioner, should always be acknowledged by note or in person.

When a practice has assumed normal proportions, a systematic record should be at hand to give the necessary data regarding each pa-

tient. To obtain such record the following method is advised: A new patient making his first visit is confronted with the following card (Fig. 332) which is filled out and filed in a cabinet (or drawer) and the reference given looked up; if satisfactory, much is gained in establishing cordial relations and the possibility of financial loss greatly diminished.

PERSONAL TREATMENT OF PATIENTS.

The success of an operator is commensurate with his ability to "measure up" to the needs of those who require his services. No two patients can be treated alike; some are particularly nervous and should be given every assistance in their endeavor to overcome the condition. Help such to think of something other than the operation itself. Some time is well spent if used for the patient's good in this manner. Allow conversation to pass to a congenial channel, while progressing as rapidly as possible with the operation required. Much more can be done upon such cases with this procedure than could otherwise be accomplished. In fact, many patients will voluntarily offer to pay for extra time and labor thus spent in their behalf rather than endure the stress of a strenuous sitting.

On the other hand there are those who can endure any operation with little or no ill effect. Upon such the operator may proceed with no hesitation. Patients appreciate the care that is paid their individual peculiarities. There is no surer way to build up a practice than by such treatment as this, added to sincere, loyal service rendered and honest operations performed.

Children should receive the same consideration as their elders. Dr. Ottolengui, when questioned regarding his apparent success with children, expressed his belief that it was due to the fact that he treated them like "grown folks;" and, he added, the longer he practiced the more he treated "grown folks" like children.

A little one may come to an operator for the first time with no previous knowledge of or dread concerning a pending operation. The utmost care should be exercised to prolong that condition of mind. Let a child once acquire a dread of a dental visit and a serious handicap is placed upon the effective service of the operator—a handicap which years of diplomacy may be necessary to overcome. If a child receives other than the most considerate care in the hands of an operator he has only himself to blame for much unnecessary trouble. It has been most wisely said, "Take heed lest ye offend one of the least of these little ones." The young practitioner should consider that these are

the ones who, if treated carefully and conscientiously, are to be the mainstay of his later practice, and the ones whose operations he will look back upon in after years as his long standing successes.

ASSISTANTS.

The subject of assistants has already been referred to; it seems wise, however, to lay some stress upon the advantage of the presence of some one—preferably a lady assistant—at the chair to render aid to the operator, care for the personal comfort of the patient and assist in innumerable ways in furthering an operation, thus saving time for both operator and patient.

Great aid is found in having such an assistant trained to select and handle instruments; provide treatments; prepare cement and amalgam fillings ready for insertion and assist in the operation of filling; understand the mechanism and control of the electric switch-board and attend to it if desired during an operation; prepare gold for filling purposes and assist in carrying it to the cavity and malleting if desired; manipulate impression material preparatory to taking impressions; care for the cleaning and sterilizing of all instruments after an operation and note their return to their proper places. To these duties some add the making of inlays and kindred matters.

A comparatively new field has opened, also, for a trained assistant in the occupation of a "dental nurse." This has been fully described by Dr. M. L. Rhein, of New York, before the New York State Dental Society in an essay at the May, 1903, meeting; (see *Dental Cosmos*, Vol. 45, p. 628). The duties of such a nurse include the treatment of pyorrhea cases as well as the general prophylactic treatment of the oral cavity under the direction of the dentist. Such an assistant is exceedingly valuable and in time will become an almost indispensable adjunct to the general office practice.

UTILIZATION OF TIME.

The important assets of a dental practitioner are his skill—the result of his training and education—and time. To misuse either is to fail to attain the highest possible success.

Primarily, a beginner should endeavor to fill his time full. Arrange for definite hours of work and fill those hours; if not occupied with the immediate care of patients—for all will not be blessed with an abundance at once—consume the time either in experimental work upon lines already laid down in college, or in study. As time goes by less and less opportunity will present itself to the busy practitioner and he

looks back with regret upon time wasted when it might have been used to advantage. Do not be afraid to accept work even if the most moderate compensation is to accrue. Consider early practice in the light of valuable post-graduate experience and count the cost of apparent loss as chargeable to a personal "profit and loss" account. Be ready to make sacrifices for the good of others at all times, but especially now when time is not of such value as it will be later in practice. Many young practitioners accept infirmary and dispensary positions with little or no monetary compensation and reap golden harvests of experience.

As practice increases time becomes more valuable and justly should be devoted to the personal clientele. Here comes an important consideration; many men seem to feel that their own time is the only thing to be considered. Just as much importance should be attached to the time of the patient. As is indicated by the appointment card (Fig. 333), a patient is given an appointment for a definite day and hour; that hour belongs to that patient and should be as nearly as possible fulfilled to the minute. Habit can accomplish much in preparing for the proper arrangement of a day's work so that the various appointments may not conflict or overlap too greatly. Nothing but a serious complication is a sufficient excuse for the consuming of one patient's hour for the benefit of another. It is just that a broken appointment, *i. e.*, one broken without due notice, should be charged for, and it is equally just that a patient should receive full value in time for an appointment set, and without delay. There are occasions when a patient's time may be of vastly greater commercial value than the operator's and if the rule of charging for "broken appointments" were reversed and the dentist were the one to be charged for unfulfilled obligations, the full force of the justice of this statement would be acknowledged.

EXAMINATION RECORDS.

Too great value cannot be placed upon accurate records of all operations performed. Three forms of examination cards are here given, any one of which is ample for the requirement, and a choice of which is a matter of individual taste. (Fig. 344, Nos. 1, 2 and 3.)

When a patient first presents himself, in addition to the reference card already mentioned (Fig. 332), the results of the oral examination should be recorded and filed in proper case or cabinet in alphabetical order. This card may be kept separate from record cards of operations performed, or used as both examination and record card till filled,

when a second card for the same patient, marked Number 2 on its upper left hand corner, may be substituted and the old card filed away.

Some practitioners dispose of old cards, but it is a wise practice to file all such away so that at any future time a consecutive history of

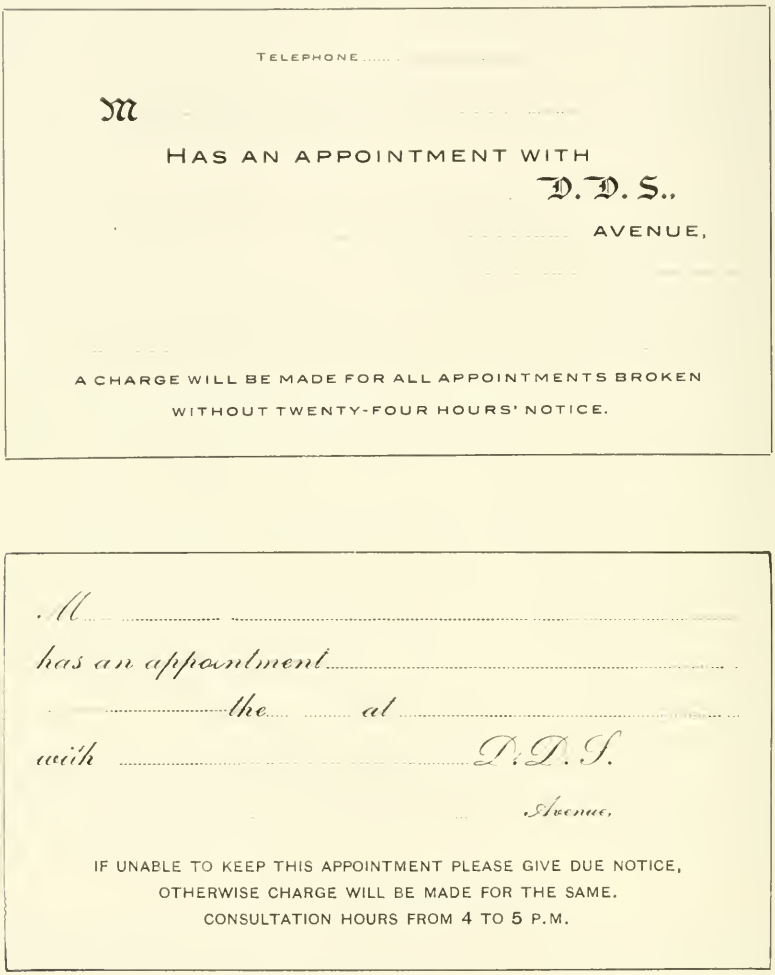

FIG. 333.—(Appointment Cards.)

every operation performed may be at hand. Many times these records are invaluable for legal purposes if any question or statement should arise demanding enlightenment or verification. Also, much value has been given them as means of identification of those who have lost their lives by accident.

Examination Blank No. 1.

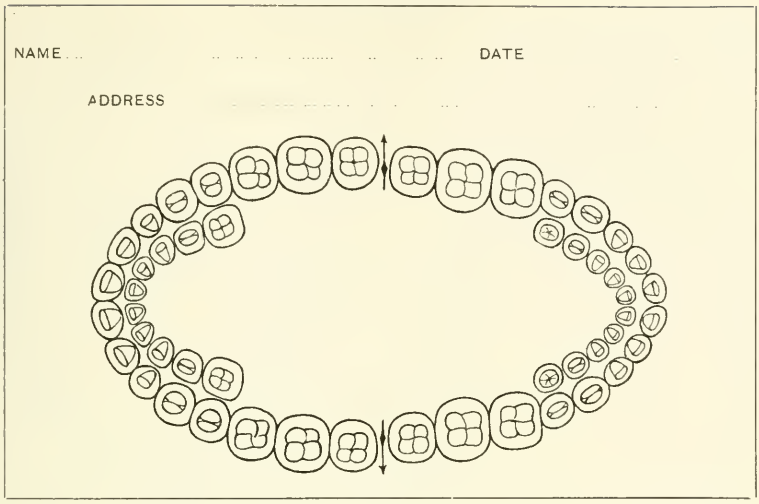

(Front)



(Back)

FIG 334.—(One of three Examination Blank Forms.)

Examination Blank No. 2.

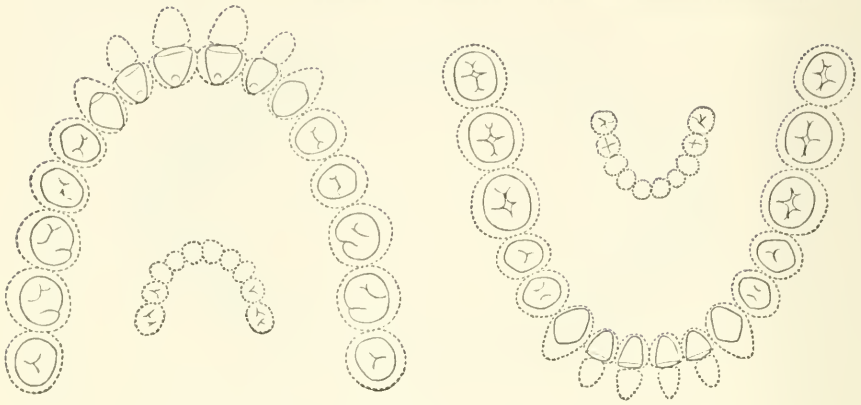

Suggested by S. H. Guilford, A. M., D. D. S.,

Examination Blank No. 3.

Date 190

Examination of M... *teeth.*

Remarks: .....

Fig. 334.—(Nos. 2 and 3 of Examination Blank Forms.)

DAILY RECORDS.

As each operation is performed it should be marked upon the diagram and either by sign or number its character recorded upon that part of the chart assigned for such record. This should be done immediately to avoid error. Some practitioners make no further daily record than this; others prefer to add a record upon a separate daily record card (Fig. 335) showing all operations done during the day, which, when transferred to the proper accounts, may be filed away among a collection which may be referred to at any time for information regarding any particular day's transactions. Still others make a record in a daily record book. As each patient's operation is completed the time consumed is marked, operations indicated, etc. The advantage of the daily record book is that it gives an opportunity to insert every important event of the day, as, for instance, the visit of a patient to pay a bill or to leave an important message which should receive prompt attention at the end of the day's duties. A portion of a page of such a record may include items as follows:

MONDAY, DECEMBER 17, 1906.

8:30. John Jones.
Root treated | 2
1 Amalgam | 8 dis.
Bill paid $18.00

9:30. Mrs. N. Smith.
1 Gold | 4 mes. cor.
(Send appoint. to
Miss Smith for Jan'y.)

Reference to various teeth should be made by numbers as indicated:

Upper

8	7	6	5	4	3	2	1	1	2	3	4	5	6	7	8
8	7	6	5	4	3	2	1	1	2	3	4	5	6	7	8

Lower

The various surfaces should be affixed.

CARD SYSTEMS.

All these record cards demand system and today little in the way of business method is not applicable to systematic arrangement. That systems are time savers is an undoubted fact. Such being the case, there is no excuse for their non-adoption. There are many laudable systems which may be found on sale at the various dental depots. One system, arranged by Dr. Guilford, of Philadelphia (Fig. 336), comprises a full set of cards, with guide cards, and places arranged for the tabulation of all necessary data including charges, etc.,

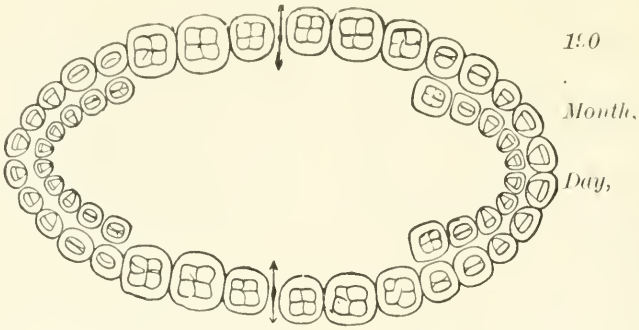

NAME.	REMARKS.	CHARGES.	

FIG. 335.

thus doing away with all necessity of other book-keeping. Other systems have this same object in view. This feature appeals to many while others prefer to have no record of charges upon cards.

The cards in these systems are usually divided into three sections each arranged alphabetically; the first division is for cards of patients whose operations are incomplete; second, for those whose operations

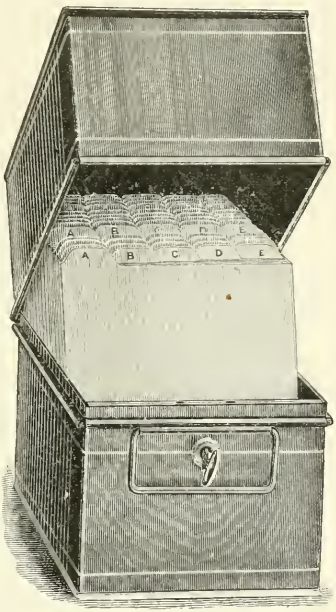

Reduced Illustration of Guilford's Tin Case Outfit.
Actual size, 5 inches wide, 8½ inches long, 7½ inches high.

The accompanying method is an adaptation of the Card Index System to the use of the dentist. It takes the place of the Ledger, Cash-book and Bill-book, all of these accounts being kept on separate cards in the same box under suitable headings.

FIG. 336.

have been completed but whose bills are not paid; the third for completed cases whose accounts are closed.

The advantage of having an added record in book form is that it gives a duplicate in case a card should be mislaid or destroyed, and also affords an opportunity to have at a glance all data desired for long periods. The following (Fig. 337) is a page from a loose leaf ledger which is an admirable example of what concise records may be. This page has 45 lines upon it, but the number may be made whatever is

M

DATE

Gold Fillings
Alloy "
Gutta-Percha "
Cement "
Root "
Combination "
Nerve Cap
Crown
Bridge
Inlay
Plate
Regulating
Treatment
X Ray
Operation No.
CHART No.
OPERATOR

Dr. | Cr. | Remarks.

45 lines

(Front side.)

M

(Reverse side—4 charts to a page.)

Fig. 337.

desired. If books are kept no charges need be displayed upon the cards themselves.

Another excellent system is that of having a set of envelopes to be filed alphabetically. These are intended as a depository for inlays, crowns or dentures ready for insertion or for whatever is of any personal interest or value connected with a patient, such as X-ray skiagraphs, anomalous teeth, etc. Whatever is deposited within the envelope is marked upon the face under the patient's name for immediate reference. In this day when so many are using the impression method of preparing both gold and porcelain inlays this system commends itself as the resultant dies may be filed away in their proper envelopes, and duplicate inlays may be made at a moment's notice, if required.

NOTIFICATION OF PATIENTS.

The gratifying increase in prophylactic measures in dental practice today makes it essential that a distinct supervision of the patient's visits should be maintained by the attending dentist. To regulate these visits some system is necessary as some patients require more frequent examinations than others. There are some practitioners who expect a visit from their patients at least once a month. The results which follow such a course are wonderfully satisfactory in preserving the patient's teeth. Others extend the time to two, three and six months. Few patients, if any, should be allowed to go without examination for a longer period. Several plans are in vogue to accomplish the supervision sought. A simple one is to have one card for each month in the year on file. When a patient's operations are complete and he is dismissed his name is placed upon the month card —one, two or more months in advance—with the date and time of day preferred. Just prior to the first of every month the next month's card is taken out and the notification cards transmitted. (Fig 338.)

This month's card then becomes "ancient history" and the next month's card takes its place in the front rank to be taken up in its proper time. The old card, however, may be kept and the result of the notification noted, *i. e.*, if the appointment is kept or not, and, if not, the reason given for its rejection or postponement—opportunity being then given for a change of date with no break in the continuity of procedure by oversight.

A very excellent plan has been devised by Dr. W. A. Cotton, of New York, to meet these several card requirements upon the patient's original record card (Fig. 339).

This gives the months upon the upper margin with the dates just

M

THE CUSTOMARY INTERVAL HAVING ELAPSED SINCE YOUR LAST CALL, I APPOINT

.....

FOR AN EXAMINATION.

SHOULD THIS TIME PROVE INCONVENIENT TO YOU, KINDLY INFORM ME AND I WILL MAKE ANOTHER APPOINTMENT.

VERY TRULY YOURS,

D. D. S.

AVENUE

TELEPHONE

(THIS APPOINTMENT IS FOR EXAMINATION ONLY.)

..... 190

M

In compliance with your request, we beg to inform you that we have appointed the at o'clock to examine your teeth, months having elapsed since your last call. Should this prove inconvenient kindly advise us at once, that we may arrange another date.

Respectfully yours.

Dr.

Avenue,

FIG. 338.—(Notification Cards.)

underneath. Two little clips are used, one solid and colored red to be placed upon the month desired for the next appointment; the other a cut out clip to show the day. To this might be added a third to indicate a special hour if desired.

That the practice of continuous appointments is a growing one is certain, and to the intelligent public it is a great blessing, as it provides constant care of their dental welfare with no personal obligation to remember the proper periods between visits and an assurance that, barring accidents, their teeth will be kept in the best condition and in

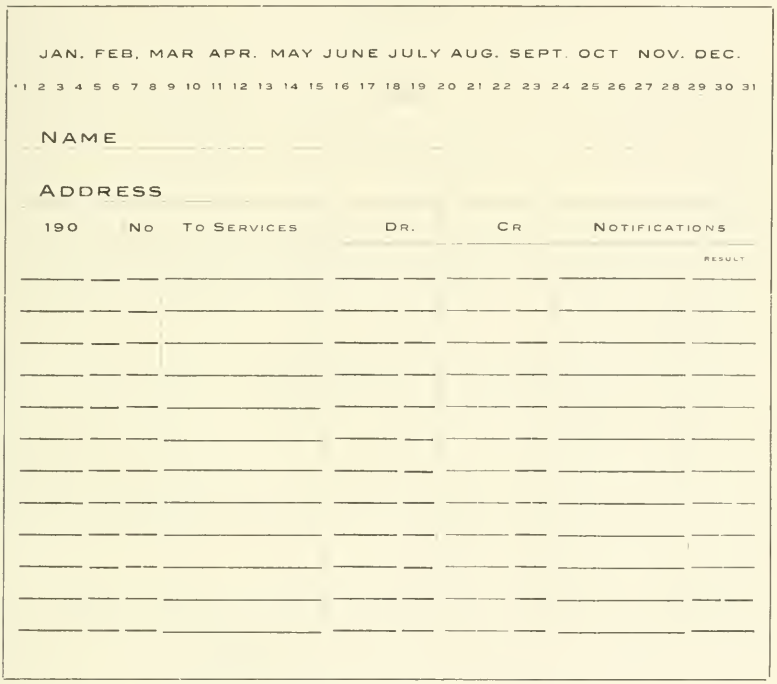

Fig. 330.—(Chart of teeth upon reverse side.)

the most economical manner. When the practice becomes general we may expect to find less and less prosthesis and more and more prophylaxis.

FEES.

The subject of fees is a difficult one to discuss from any standpoint and especially so in dealing, as is the intention of this chapter, with under-graduates about to start upon their professional career. I stated at the opening of this chapter that one need not expect to grow wealthy practicing dentistry. Wealth, however, is a flexible term and I must leave that to each individual. Charges for services should be

computed upon the basis of several considerations; first, "How much is the operation as I have performed it worth, considering all things?" This last phrase covers much ground. The beginner does not expect to value his time as highly as that of the man who has practiced for years, nor are his services as valuable in result—except in rare cases—as those of the more experienced. Hence the fee for the same operation by one man need not necessarily be the same as that of his fellow practitioner.

Environment has a bearing upon fees; a man in a small village with little expense can afford to charge less than his confrere in costly surroundings with proportionate increased expenses of a city practice.

Another very important consideration is this: "Can this patient afford to pay my usual fee?" Many a time in making up the estimate of the value of an operation will this question obtrude itself and it must be met conscientiously. There should be no such thing as a fixed and unalterable price for an operation. There are some who will need your care; give it cheerfully, and, whether or not the exact remuneration in dollars and cents results, the satisfaction of duty performed will always remain with you and the successful building up of a practice will be assured.

The basis of calculation of fees differs with different men. Some charge for each filling, denture, etc., rating the fee according to the size and character of the operation; others charge a certain fee for an hour's services, not considering the character of the operation performed. There are faults in each system, and the only satisfactory one seems to be in a combination of both.

That some operations, while taking a short time, may be exceedingly arduous upon the operator yet extremely valuable to the patient is an accepted fact; and the question arises should such an operation be charged for upon the same basis as one which, while taking considerable time, is neither a severe task for the operator, nor of great value *per se* to the patient.

Then, too, some operators are rapid in their operations and accomplish much in an hour of thoroughly satisfactory work. A confrere, with the same conscientious care and results takes twice as long. Should they receive the same compensation?

STATIONERY, BILLS, ETC.

It has been said that "we are judged by the company we keep" and a professional man is often rated by the stationery he uses. This should be as neat and unobtrusive as possible. Anything beyond one's

Avenue,

190

M

To ..... D. D. S., Dr.

For professional services:

Fig. 340.

Received payment.

Bills rendered at the completion of operation.

degree and address is unnecessary upon professional cards or note-heads. The addition of "Dental Surgeon" or "Surgeon Dentist," etc., is needless except as a covert attempt to enhance by the term the degree which should need no such enhancement to sustain its professional dignity.

The rendering of bills for professional services may be accomplished in several ways to advantage. Upon the bottom of the bill a clause is placed which reads "Bills rendered upon completion of operations" (Fig. 340).

This may be a rule from which deviations are permissible. Many prefer to render statements for all work accomplished during a month; others at the end of two months; still others at the expiration of six months, in which case June 1st and December 1st are the dates preferred.

Questions arise from time to time regarding the best manner of rendering a bill; should such be itemized or not? This must be left to the practitioner to decide for himself.

Some prefer to enclose with the bill, for the exact information of the patient, a chart showing just what has been done—practically a duplicate of the record card—indicating the time spent upon and the charge for each operation; others enclose the record card but omit the individual item charges; others omit all record cards (unless requested for them) feeling certain that their patients have all confidence in their honest intentions in rendering statements.

When bills have been prepared an accurate alphabetically arranged list should be made with the amounts affixed. As returns are received the name and amount should be erased from the list and the credit recorded in its proper place. When subsequent bills are required to be rendered, delinquents are thus easily traced and duplicate statements marked as such. Failure to respond by a client places one in the position where he may require either the services of a collector or, *in extremis*, a lawyer to enforce a settlement.

When all is said the great secret of the management of a successful office practice lies in the spirit of the well-known lines:

> "To thine own self be true,
> And it must follow, as the night the day,
> Thou canst not then be false to any man."

Exact of yourself the highest standards of attainment, ideals and culture. Strive to live up to these standards and the result will be in other hands than yours.

CHAPTER XXXI.

ORTHODONTIA.

BY HERBERT A. PULLEN, D.M.D.

I. DEVELOPMENT OF THE DENTAL ARCHES, OCCLUSION AND ARTICULATION.

Orthodontia, as a progressively advancing science, embraces within its sphere much more than the art of correction of malocclusion, since diagnostic considerations have become of such import as to demand a deeper insight into the physiological processes of the normal, and the etiological factors of the abnormal development of the dental and maxillary arches, and adjacent internal anatomical structures, together with their relationship to the contour of the face.

In the light of recent advances in the treatment of dental and maxillary deformities in very young children, orthodontia must be viewed from the standpoint of such early developmental processes as precede occlusion of the second dentition, which by their normal attainment, provide for the harmonious and proportionate development of the maxillæ and related structures, or which, by their abnormal tendency, cause insufficient or disproportionate development in the same regions.

If the normal in the development of the dental arches and related structures occurs, normal relations of occlusion are inevitable; if, through any cause, development in these regions is arrested, the abnormal in occlusal relations must supervene.

Arch Development a Primary Factor.—Occlusion, whether normal or otherwise, being thus dependent upon earlier developmental conditions, is not the factor of primary import in the study of orthodontia, since it is governed entirely by certain factors in development which precede its attainment by several years.

From the earliest infancy to old age, the problems of malocclusion are problems of the abnormal in development, the study of the etiology of which alone reveals the inception and causative factors of the resultant malocclusions.

NOTE.—A large number of the cuts for the section on Orthodontia have been supplied through the courtesy of "*Items of Interest*," and the "*Dental Cosmos*." Credit should also be given to Mr. Phil. J. Knapp, of Buffalo, who made all the photographs.

A proper comprehension of the field of orthodontia should include these considerations in its definition, which, in brief, is as follows:

Orthodontia *is that science which treats of the etiology, diagnosis, and treatment of the abnormal in development of the dental and maxillary arches, and of their relation to asymmetrical contour of the face.*

Normal Arch Development.—The recognition of the dependence of the normal function and development of the second dentition upon certain physiological factors of the primary dentition necessitates a knowledge of the sequence of developmental processes leading up to the eruption and attainment of normal occlusion of the permanent teeth.

The Arches of the Temporary Teeth.—In order to have a logical and chronological succession of recorded observation of facts, it is necessary to study the arch at its latest period before the eruption of any of the permanent teeth, at a time when the deciduous teeth are all *in situ*, and certain physiological processes are about to take place subsequent to the shedding of these teeth and their replacement by the permanent set; these changes, according to the degree of perfection of their physiological performance, having much to do with the normal or abnormal development of the second dentition.

FIG. 341.

Many cases of malocclusion date their inception back to the time when these processes are taking place, and a proper cognizance of them would suggest that assistance be given to these natural processes, if necessary to intervene, rather than to hinder or subvert them through ignorance of their normal function, and consequent ill-advised treatment of certain conditions which may present.

Fig. 341 shows a perfect development of the deciduous teeth, in normal occlusion, at the age of four years, at which time all of the deciduous teeth are in position and accomplishing the function of mastication to the degree necessary for the nutrition of a child of this tender age.

The retention of these teeth until the initiative in eruption of the permanent successors has taken place, is a feature of great importance in its bearing upon the normal development of the arches of the permanent teeth, since their premature loss invariably causes a retardation

of development of the arch which is always productive of a more or less serious malocclusion of the permanent teeth.

All of the laws of occlusion which pertain to the preservation of the integrity of the permanent arches of teeth are in evidence likewise in the arches of deciduous teeth, both as to the interdependence of one arch upon the other for the preservation of form and normal cusp interdigitation, and to the normal growth and functional activity necessary to the completion of the second dentition.

Occlusal Relations.—It will be observed that there is a slight overbite in the incisor region, and that each upper central incisor overlaps the labial surface of the lower central and one-half of the lateral incisor; each upper lateral incisor overlapping the distal half of the labial

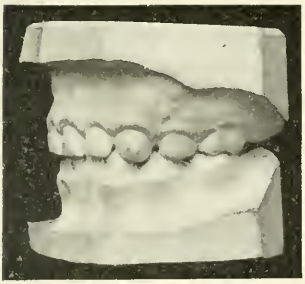

FIG. 342.

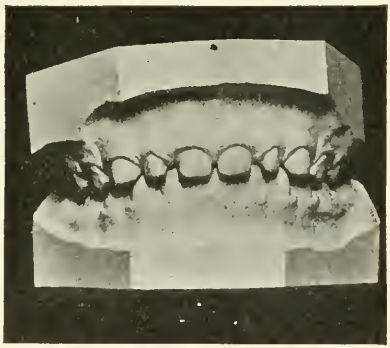

FIG. 343.

surface of the lower lateral incisor, and the mesial incline of the lower cuspid.

The antero-posterior interdigitation of the cusps of the cuspids, and first and second deciduous molars is likewise conformative to a normal occlusion and arrangement as in Fig. 342.

It is well known that the integrity of the arches of the deciduous teeth is a very important factor in the normal development of the maxilla and mandible, and in the production of normal occlusion of the permanent teeth.

Developmental Spaces.—While the deciduous arch still retains its full complement of teeth, between the second and fifth year, the coordinate and coincident growth of maxilla and mandible are taking place not only in the forward, downward and lateral development, but in an interstitial growth in the alveolar process and maxillæ, which is evidenced by a separation of the deciduous incisors as development progresses.

Fig. 343, illustrates the arches of deciduous teeth in occlusion just previous to the eruption of the permanent incisors in a patient six and one-half years old, a case in which the anterior development of the process has taken place normally, as noted by the spacing between the deciduous incisors. When the dental arches present this appearance just prior to the eruptive period of the incisors, there is every assurance that the eruption of the permanent incisors will occur without crowding.

Sectional Development.—The maxillary arches do not develop uniformly, as might be supposed, but in sections corresponding to the periods of eruption of the different teeth. For example, the incisive region increases in width at the time of the approaching eruption of the incisors, above and below, the arches lengthening at about the same time, for the accommodation of the first permanent molars, as in Fig. 344, which is a picture of the same mouth as in Fig. 341. at the age of six years.

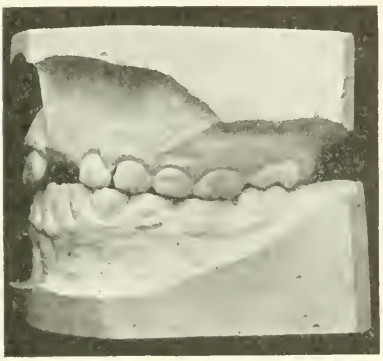

Fig. 344.

At this age, the alveolar processes have likewise grown downward and upward, and the first molar teeth have come into occlusion, holding the dental arches the proper distance apart, affording new and broad masticating surfaces for use during the shedding of the deciduous teeth, and by their deep cusp interdigitation, accentuating the perfect mesio-distal registration of the dental arches, which the deciduous teeth initiated.

The later eruption of the bicuspids and cuspids is in accordance with similar developmental processes which have been going on in the lateral halves of the arches anterior to the first permanent molars. The greatest development of the arches after this period takes place in the region of the second and third molars as they erupt into positions of occlusion with their antagonists in arches in which the function of mastication is up to a normal standard.

Occlusal Relations of Permanent Teeth.—A proper understanding of the normal in occlusion of the permanent dentition enables the diagnostician to determine by comparison, the abnormal variation, not not only in cusp interdigitation, but in arrested development of the dental and maxillary arches, the etiology of which may date back to the earliest period of childhood.

Anatomy, or normal structure, and physiology, or normal function, form the basis of the science of medicine. It would be impossible to diagnose and treat pathological conditions without a correct knowledge of the normal structure and function.

The fulfillment of natural and normal development in the dental and maxillary arches in the completed dentition constitutes a normal and ideal relationship of occlusion of the teeth from which it is possible to note deviations in malocclusion, and a guide for comparison in the restoration of normal conditions, viz., normal occlusion.

The characteristics of this normal dental and maxillary development, including the normal development of adjacent structures, are necessarily specified and limited, and may be comprehended in the following definition.

Normal Occlusion *is a condition of perfect relationship existing between the normally formed and arranged teeth of normally developed dental arches when in antagonism, the mandible being in its farthest posterior position, and in exact median register with the maxilla, and both in normal relationship with contiguous tissues.*

A Malocclusion *is any variation from a normal occlusion either in size, shape or relation of dental arches, or perversion of inclined cusp planes.*

Normal occlusion, in the ideal, is seldom found in any type of individual, although the approximation of it in many cases varies but little from the ideal anatomical occlusion.

Characteristics of Normal Occlusion.—Fig. 345 exhibits a skull in which normal occlusion is present, and in which the following characteristics may be noted:

1. The normal shape and size (according to type) of each arch.
2. The normal position of each tooth in each arch.
3. The normal shape and size of each tooth (varying with type) in each arch.
4. The normal relationship of each arch to the other, and of the occlusal inclined planes of the cusps of the teeth in one arch to those of the other.

The bilateral arrangement of the muscles, the shape of the arches of teeth, and their harmonious relation to each other; the form, size, and position of the teeth with their cusps interdigitating for mutual support, the proximal contact, the upward curve of the ramus, and the relations of the occlusal planes, all serve the purpose of increasing the efficiency of the organs of mastication, by providing the means, whereby a co-ordination and equilibrium of forces are secured, which are

essential for the preservation and function of the organs themselves, as well as for economy of force, and the production of lines of beauty not possible in any other arrangement.

In examining the interdigitation of the teeth upon each lateral half, it will be seen that each tooth has two antagonists in the opposite arch, except the lower central incisor and upper third molar; this

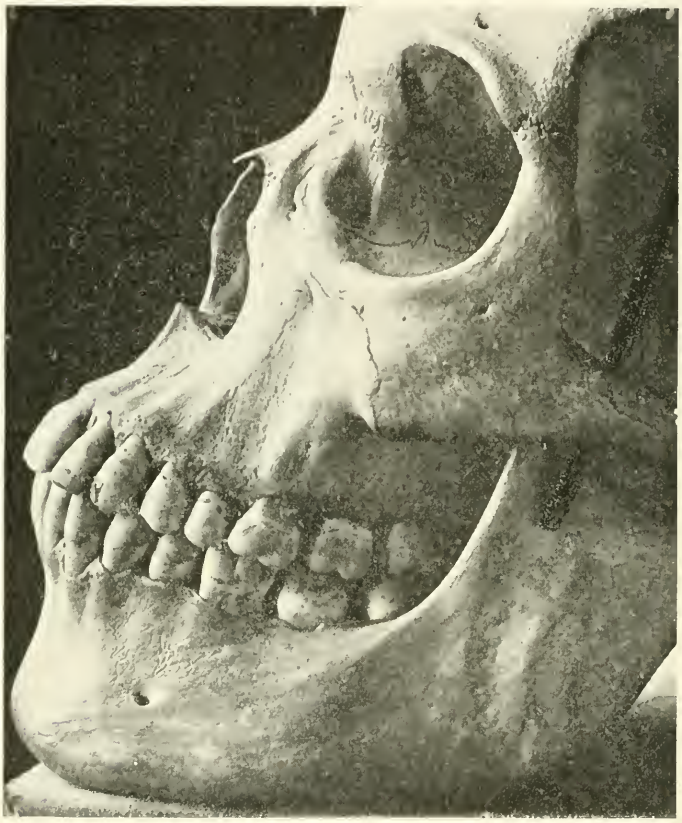

Fig. 345. (*Broomell.*)

arrangement not only providing the greatest support for the teeth individually and collectively, but also allowing the inclined planes of the cusps of bicuspids and molars the best opportunity for articulating during the lateral excursions of the mandible.

Relations of Inclined Planes.—Beginning at the median line of the dental arches in normal occlusion the following cusp relations may be noted which are conformative to the normal in the bucco-occlusal relations of the teeth. The upper central incisor is

in occlusal contact with the incisal edges of the lower central incisor and one-third to one-half of the lower lateral incisor; the upper lateral incisor is in occlusal contact with the remaining two-thirds or one-half of the incisal edge of the lower lateral incisor, and the mesio-incisal angle of the lower cuspid; the upper cuspid occludes with its mesial incline in contact with the distal incline of the lower cuspid, and its distal incline in contact with the mesial incline of the buccal cusp of the lower first bicuspid; the buccal cusp of the upper first bicuspid occludes with its mesial incline in contact with the distal incline of the buccal cusp of the lower first bicuspid, and its distal incline in contact with the mesial incline of the buccal cusp of the lower second bicuspid; the buccal cusp of the upper second bicuspid occludes with its mesial incline in contact with the distal incline of the buccal cusp of the lower second bicuspid, and its distal incline in contact with the mesial incline of the mesio-buccal cusp of the lower first molar; the mesial inclines of the mesio- and disto-buccal cusps of the upper first molar occlude with the distal inclines of the mesio- and disto-buccal cusps of the lower first molar; the distal incline of the disto-buccal cusp comes into occlusal contact with the mesial incline of the mesio-buccal cusp of the lower second molar; similar relations of the inclined cusp planes are in evidence in the second and third molars, except that the upper third molar has no antagonizing plane for the distal incline of its disto-buccal cusp. A similar arrangement of the lingual cusps of the upper teeth in their occlusal relations with the lower renders the interdigitation of cusps for mutual support still more pronounced.

The object of this complex interdigitation of cusps is to give the greatest support, not only to the teeth individually, but as a whole, their sizes, forms and positions of cusps and inclined planes being best adapted for this purpose.

Preservative Forces of Arch Integrity.—Having outlined the positions of the individual teeth in normal occlusion, it is quite important that cognizance be taken of the forces which tend to preserve this normal arrangement, viz.:

1. The interdigitation of the cusps of the teeth.
2. The reaction and dependence of one arch upon the other.
3. The muscular influence of the lips, cheeks, and tongue, labially, buccally and lingually.

As one arch is dependent upon the other for its regularity, it follows that a malocclusion in one arch implies a similar condition in the other, and the maintenance of the malocclusion is just as effectual as through the normal influence of the above mentioned forces.

If the lower arch is contracted and the teeth crowded, the same conditions will be found in the upper arch as a result of the operation of these forces.

Nomenclature in Malocclusion.—In order to avoid confusion in nomenclature the author has conformed the text to the nomenclature adopted by Dr. Angle, which has been in quite general use for several years.

In brief, this nomenclature is based upon the variation of individual teeth from the line of occlusion; a tooth outside this line being in *labial or buccal occlusion*, inside of this line, in *lingual occlusion;* if it is forward of the line, it is in *mesial occlusion*, if in the reverse direction, in *distal occlusion;* if rotated upon itself, in *torso-occlusion*. Teeth which have elongated beyond normal relations are in *supra-occlusion*, and those which are insufficiently elevated are in *infra-occlusion*.

In all branches of art, such as sculpture, painting, architecture, etc., a model of perfect art is chosen as a guide to reproductions which represent the highest conceptions of a certain type, whether it be the Apollo in sculpture, the Madonna in painting, or the Renaissance in architecture.

Normal occlusion is the highest conception of a type, not a relative or approximate condition. It is an ideal state of physical integrity, and can only be perfectly conceived in a perfect anatomical subject, which would necessitate, therefore, the normal, typical, and perfect development and relationship of contiguous tissues of the hard and soft anatomy, the osseous and muscular tissues of the head and face, and the harmonious and proportionate development of the facial lines which are conformative to beauty and harmony of the profile.

It has been suggested that the word "occlusion" alone be used to designate this ideal relationship; that the word "normal" is unnecessary, since if occlusion is anything, it is normal; otherwise, malocclusion is the proper term, but the acceptance of this term without the limiting characteristic which the word "normal" adds to it would be confusing and unwarrantable in referring to the typically ideal anatomical occlusion.

The commonly accepted use of "occlusion" is in reference to the relation of the interdigitating cusps of the teeth, whether there is a normal, or a malocclusion present, and it may be definitely described as follows:

Occlusion *is the most constant static relationship of the antagonizing surfaces of the arches of teeth in interdigitation.*

Distinction between Occlusion and Articulation.—The syn-

onymous use of the terms "occlusion" and "articulation" is not in accordance with their specifically different meanings, as generally understood by those who have carefully studied them.

Articulation *is the relation between the antagonizing surfaces of the teeth of maxilla and mandible during the lateral and protrusive excursions of the latter, dependent upon its universal articulation at the glenoid fossa.*

There are three distinct stages of articulation, viz., *prehension*, *attrition*, and *occlusion*. The first two stages represent the mandible in motion, the last, the mandible at rest, the teeth being closed.

Occlusion is the passive phase of articulation, as compared to the active phases of prehension and attrition.

Occlusion represents the static, and articulation the dynamic, relation between the arches of teeth.

Some recent writers have argued that occlusion should represent all that is meant by articulation in its relation to orthodontia, but such a generalization of the term would be absurd, and any attempts at diagnosis of malocclusion from such a variable base would only result in confusion. However, it is impossible to completely separate these terms in their bearing upon the normal relationship of the arches of teeth, so intimately are they connected.

A normal occlusion necessitates a normal articulation, and a normal articulation necessitates a normal occlusion.

The laws of articulation produced the perfectly formed arches of teeth, the depth of the overbite, the length of cusps, and relations of occlusal inclined planes, so that the definite form and positions of the teeth and relations of the arches known as normal occlusion was a possibility.

In occlusion, the lines of force are constant in their direction, in articulation, they are ever changing, varying as the relationship between the arches of teeth causes stress to be made between antagonizing tooth surfaces in constantly changing angles.

Articulation.—By carefully studying the forms and positions of the inclined planes of the cusps of the individual teeth, the length of cusps, decreasing in depth from the first bicuspid to the last molar, the depth of the overbite, and the compensating curve of the arches, it will be noticed that there is a distinct relationship existing between the length of the cusps in bicuspids and molars, the overbite, and the compensating curves, which, as pointed out by Bonwill, serves the purpose of supporting the arches of teeth in all positions of articulation, and affords the greatest surface for the mastication of the food.

It is not to be concluded that function primarily of the masticatory

organs produces this relationship of the arches, for the full development of the crowns and cusps of the teeth is far in advance of any suggestion of the function, and only upon eruption to occlusion do the cusps of the teeth come under the influence of each other in opposing arches in articulation and occlusion.

On examination of the arches of teeth in normal articulation, in the movement of the mandible to the left from the position of occlusion the following articular relations may be observed, as described by Bonwill: "The right condyle moves forward and downward in the glenoid cavity one-eighth of an inch, when at its farthest limit, causing the outer and inner cusps of the upper teeth, from the centrals to the last molar, to touch the outer and inner, or buccal and lingual cusps of the lower on the same side—the left; and on the opposite side—the right—we find only the inner cusps of the bicuspids and molars of the upper, to come in contact with the outer of the lower, and the right central to the cuspid do not touch."

In moving the mandible to the right, these positions are just reversed

"Again, if the mandible is moved directly forward from the position of occlusion, until the incisors touch edge to edge, the buccal and lingual cusps of the upper second molars touch the buccal and lingual cusps of the lower second molars."

"In order that this articulation of cusps in the above movement may take place, the overbite must not only be proportionate in depth to the depth of the grooves in bicuspids and molars, but also the curvature upward of the ramus must be in the same proportion."

"The depth of the cusps in the upper first bicuspids corresponds almost exactly with the depth of the overbite, the cusps diminishing in depth from first bicuspids to last molar."

"The necessity for the touching of so many teeth during articulation is evident when we recall that the muscles of the jaws should act equally on both sides, even though but one side is in use at one time, the other side touching to balance the forces at work on the opposite side."

"It is mechanical law and that of motion, to obtain a certain result for the perpetuation of the organs themselves, but the life of the whole organization, and the grooves, fissures and cusps are so arranged . . . that where each is in its normal position in the jaws all surfaces wear alike, and the shapes are kept in harmony."

Development of Associated Anatomical Structures.—In order that a clearer idea of the field of the orthodontist may be engendered, a study of the internal facial anatomy from a vertical transverse bilateral section of the head, as illustrated in one of Dr. Cryer's

dissections, Fig. 346, revealing comparatively normal development of the maxillary arches and associated structures and sinuses, may serve to illustrate how closely the internal structures are associated, and to what extent they are interdependent for normal growth and function.

Immediately above the floor of the hard palate may be observed a straight nasal septum, dividing the internal nose into two large and well formed meati, adjacent to which, the fully developed maxillary sinuses are situated.

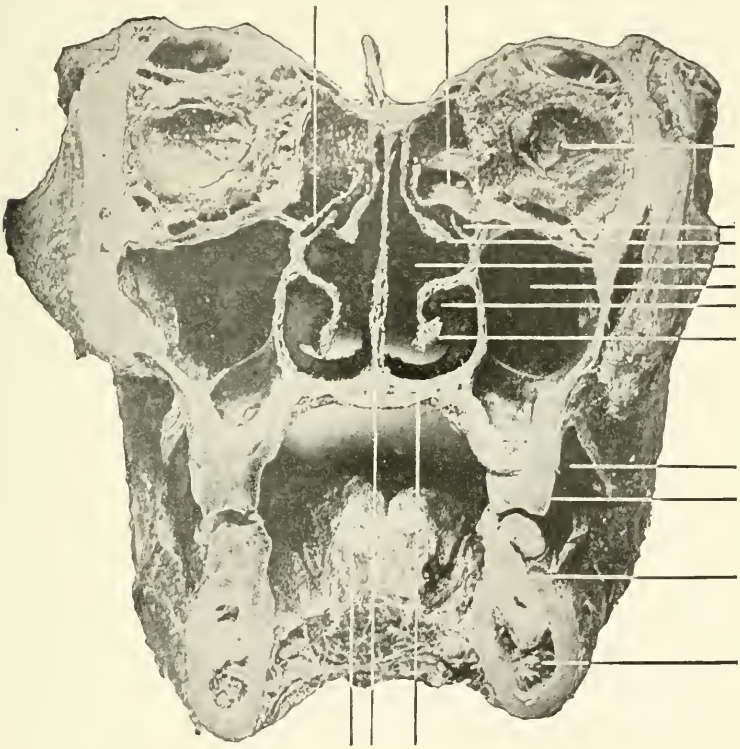

FIG. 346. (*Cryer.*)

This normal and proportionate development of associated anatomical structures of the internal face is not a chance coincidence, but the result of a functional and structural relationship which is most important to the diagnostician.

Of first importance to the development of the dental and maxillary arches is the function of normal nasal breathing, which is only possible with properly developed nasal meati.

Second, in importance is the function of mastication, the natural action and reaction of the teeth of mandible against those of the maxilla

serving to further development of the dental and maxillary arches, and thereby assist in the development of the floor of the nose and associated sinuses, etc.

Normal breathing is given first place in important developmental functions, because with deficient respiratory powers, as in the mouth-breather, the teeth seldom come into contact sufficiently to obtain the requisite amount of occlusion and articulation necessary for proper development of the arches.

Co-ordination of Functions.—It will be therefore apparent that co-ordination of normal function of respiration and occlusion are the most potent factors in the symmetrical and proportionate development of the internal face, the nasal cavities and associated sinuses, and the maxillary and dental arches.

Such symmetrical development of related parts implies as well the existence of full nutrition, and the absence of any untoward etiological factors which would tend to diminish functional influence or lower the vitality in any way.

Any local functional and developmental disturbance may be the result of general systemic conditions, of lowered vitality from whatever cause, so that any local pathological manifestations in diminished or perverted function and consequent modified anatomical structures should be considered in relation to the health of the whole organism.

The association of nasal stenosis, mouth-breathing, and arrested development of the maxillæ, and dental malocclusion, is sufficient evidence of the interdependence of function and structure in these associated regions to convince the most skeptical of the importance of the study of the anatomy of the internal face with a view to the discovery of certain causative factors which will assist in the remedy or cure of abnormal developmental conditions, which require an intelligent differential diagnosis.

II. SYMMETRY AND ASYMMETRY OF THE FACE.

Orthodontia has advanced beyond the teachings which its name might imply to the field of orthopedia to such an extent that there can scarcely be any orthodontic treatment which does not include orthopedic considerations.

The restoration of esthetic facial contour through orthodontic and orthopedic treatment, although included in the field of orthodontia, may correctly be styled dento-facial orthopedia, and be defined as follows:

Dento-facial Orthopedia *is that art which deals with the restoration*

of facial symmetry through the prevention and treatment of abnormal development of dental and maxillary arches.

Physical Relations of Beauty.—The broadening of the field of orthodontia to embrace the field of facial orthopedia has necessitated a closer study of the art relations of the human face with a view of ascertaining those qualities of beauty which are related to the normal and typical in development, rather than those qualities of facial beauty which appeal to the esthetic faculties because of the influence of the mind upon the physical expression.

Beauty is defined as "the assemblage of graces or properties which are pleasing to the eye, the ear, the intellect, the esthetic faculty, or the moral sense," "the multiplicity of symmetrical parts uniting in a consistent whole."

FIG. 347.

It has been pointed out by artists that no fixed "line of harmony" exists in relation to the profile, but that beauty of the face consists in a proper balance of the features according to type.

Limited then, as the orthodontist is to a consideration of the physical relations of the various parts of the face, the qualities of symmetry and proportion alone, as indicated by the normal and harmonious development of the face as a whole, including the underlying osseous structures as well as the muscular tissues overlying them, can be consistently studied by him in the determination of the normal or abnormal.

Facial Symmetry *consists of the normal and proportionate development of facial contour dependent upon the corresponding development and growth of the underlying osseous structures and sinuses.*

Harmony of the Facial Profile.—Viewed from the standpoint of the artist, the harmony of proportions of the profile consists in a correspondence in measurement of prominent divisions of the

profile from the top of the head to the chin; from the hair to the bottom of the chin should measure three-quarters of the height of the whole head; the forehead to the root of the nose measures one-fourth; the nose one-fourth, and the mouth and chin one-fourth.

Fig. 348.

A very comprehensive illustration of these measurements may be seen in Fig. 347, in which at the same time may be noted the correspondence of the facial curves of the forehead, nose and chin, and the normal development of each separate third of the face so that a proper balance of the face as a whole is attained.

In the consideration of the development of anatomical structures, the normal growth of tissues depends upon proper functional activity, and deficient functional activity from any cause is productive of structural defects in growth.

For the full development of the lower two-thirds of the face, there must not only be perfect function in the respiratory mechanism resulting in normal nasal breathing, and development of the whole middle third of the face, but also there must be proper functional activity in mastication, and the absence of any untoward influence in tooth or arch development, either through mechanical interference or local effects of deficient nutrition due to nervous or circulatory impediment of any kind.

Fig. 349.

A very well-proportioned profile with a correspondence of curves of the forehead, nose, lips and chin, is illustrated in Fig. 348. According to the principles of facial symmetry, it would be expected that the functions of respiration and mastication were unimpaired in this individual in order to have produced the correlation of symmetrical parts of the profile as seen in the illustration.

The middle third of the face is well developed, the nostril wide and

dilated and there was no indication upon examination of any nasal obstruction or inflammation which might induce a diminution of the normal breathing function.

The proportions of the lower third of the face are also so perfect that the prognosis of almost perfect development of the arches of teeth

FIG. 350. (*Cryer.*)

and the absence of any marked malocclusion might be made with a degree of certainty, and upon examination of the model of the mouth in Fig. 349, the correctness of this prognosis may be seen, there being but very slight deviation from the normal relationship of occlusion.

Relations of External and Internal Anatomy.—A very interesting illustration of the relation of external and internal facial

development may be observed in a sagittal section of a typical skull, Fig. 350, made by Dr. M. H. Cryer. The profile appears proportionate in the development of its various divisions, and a view of the internal anatomy reveals well-developed osseous structures and sinuses in the middle third of the face and a typically normal development of the maxilla and mandible, and a tongue which almost completely fills the oral cavity.

Dr. Cryer has demonstrated by many sections of the frozen heads of cadavers that variation of the internal anatomy of the face and head is of such frequent occurrence that typical and symmetrical development of the corresponding osseous structures and sinuses of the two lateral halves of the head is the exception rather than the rule, thus accounting for such variation in development of the superficial muscular and other tissues, which are often so pronounced as to to be noticeably deformed.

Fig. 351. (*Parke Lewis.*)

Facial Asymmetry *consists of the abnormal and disproportionate development of the contour of the face, dependent upon a corresponding abnormal development and growth of the underlying osseous structures and sinuses.*

In the consideration of facial asymmetry, as related to development, it is necessary to exclude the facial defects caused by such nervous lesions as paralysis, or the structural lesions of tumors, and other similar pathological manifestations not bearing directly upon the general laws of facial development, except such developmental neuroses as are admitted to be embryonic in character, and which, whether degenerative or not, must be taken into consideration by the diagnostician of structural deformities in any part of the body.

Inequalities of Growth.—The ophthalmologist recognizes the inequalities of structural growth in the variation from the normal anatomical similarity and relationship of the eyes; one eye may be larger than the other, or more deeply set; one eye may be higher than the other, as in Fig. 351, producing lack of co-ordination of function of these organs, and the resultant strain of the muscular tissues of the face in the effort to attain binocular vision is evidenced by the facial expression.

The screen method of measuring the face, illustrated in Fig. 352, affords a means of determining the variations in height of the corre-

sponding halves of the face, and also the variation from symmetry of the facial thirds, and the anatomical deviation from the central facial line.

The Scope of Orthodontia.—In the study of the face, we must encroach upon the field of the ophthalmologist and the rhinologist in order to have a comprehensive idea of the normal and abnormal in development of the structural anatomy of the regions in which they are working, and the symptomatic and pathological relationship of diseased conditions in these regions and in those of the orthodontist.

The facial orthopedist should never lose sight of the fact that there are a great many types of faces, varying with nationality, and climate and environment, and that the features conform with great persistency to racial characteristics in particular.

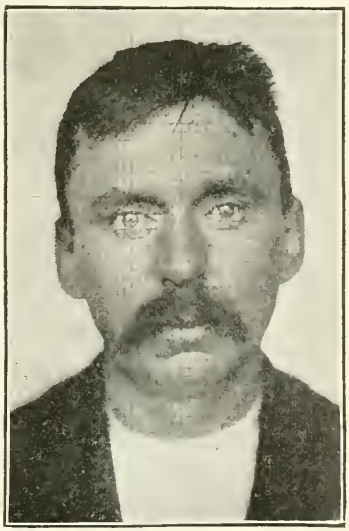

FIG. 352. (*Parke Lewis.*)

Inharmony of the Profile.—A face may be perfect in its type except for some slight deformity in the lower third which may exhibit lack of harmonious development.

For example, in Fig. 353, the profile conforms in most of its lines to its type, and contains many of the elements of beauty in some of its proportions, but the apparent prominence of the lower lip offsets all the esthetic characteristics of the other parts of the face. A study of this profile will convince the careful observer that the apparent deformity or protrusion of the lower lip and of the mandible is an optical illusion, and that the upper lip alone is out of harmony with the rest of the profile, being retruded from the normal pose which it should occupy.

As proof of this diagnosis, a study of the occlusal relations of the arches of teeth in Fig. 354 exhibits a normal relationship in the molar region, and an abnormal position of the upper anterior teeth alone, they being in lingual occlusion.

Deformities of this nature often affect the welfare and happiness of the unfortunate possessors for a whole lifetime, so keenly sensitive are they to public notice and unfavorable comment by those with whom they come into daily contract.

Any variation from normal and symmetrical development of the

two sides of the face may be detected by drawing an imaginary line through the center of the face from the forehead to the chin, as in Fig. 355, in which a marked deviation from this line is noticed in the lower

FIG. 353.

third of the face, and caused by the malocclusion of the teeth, which forced the mandible to one side.

FIG. 354.

An examination of the profile of this case, Fig. 356, exhibits the extent of the deformity, the chin being considerably protruded, giving the individual a senile appearance.

The model of the mouth of this young lady in Fig. 536 exhibits just such a lack of harmony in occlusion as we would expect from a study of the facial inharmony.

The functions of speech and mastication are seriously impaired,

FIG. 355.

FIG. 356.

and were it not for the skill of the orthodontist, there would be no remedy for the alleviation of the deformed condition which is such a handicap to the one having such a facial disfigurement.

III. ETIOLOGY.

Deductions From Early Symptoms of Developing Malocclusion.—The advent of diagnostic interpretations from the basis of occlusion has caused an earnest study of early symptoms of developing malocclusion, a very large percentage exhibiting such peculiarities of maldevelopment of the arches as a whole, as to claim a most serious consideration of the possible etiological characteristics, and their probable bearing upon operative treatment of abnormal conditions present.

The exclusion of such local etiological factors as premature loss of deciduous teeth, etc., in the production of small and crowded arches of teeth have led to the conclusion that malpositions of the teeth, individually and collectively, are but superficial symptoms or results of arrested function and development of the arches as a whole, including the alveolar process and underlying bone, and even extending into the associated nasal structures and sinuses.

The concomitant arrest of development of the nasal cavities, and a diagnosis of similar local or remote etiological factors, furnishes the

strongest proof of the wisdom of observing and preventing abnormalities in development during the earliest period of child life, when functional insufficiency interferes most profoundly with the normal growth of developing anatomical structures.

Very marked malocclusions of the deciduous teeth, such as pronounced protrusions, have been not infrequently observed by the author and others in children of two years of age and younger, exhibiting some form of functional derangement, especially in the nose and throat, and indicating defects in development which may be of congenital origin.

These disturbances in development occur very early in life, and if remedial treatment is not instituted before the sixth or seventh year, or even earlier in some cases, the possibility of permanent benefit, especially in the establishment of normal nasal respiration, where it is perverted, is greatly lessened.

Intra-uterine Influences upon Arch Development.—The normal development of the dental arch, including the eruption of its deciduous and permanent teeth and their alveolar base, preconceives primarily, the healthy structure and the molding and development of the maxilla and mandible during embryonic life, which are naturally dependent upon the nutritive and other conditions in which they are surrounded in intra-uterine life.

It is conceded that prenatal influences, whether they be of a nutritional, functional or nervous type, have a definite bearing upon the metabolic processes which tend toward symmetry or asymmetry of development of the embryo in whole or part.

Hare-lip and cleft palate are recognized as simply lack of complete development in the embryo through some retardation in intra-uterine development, the causes for which are obscure only because of the inability to directly trace the particular influences which might arise from a neurotic or other tendency, which in turn affects the growth and development of cellular structures in those parts of the human organism peculiarly open to such influences.

Talbot remarks: "The structures of the mouth and nose being exceedingly variable in evolution, and the structures of the jaws and teeth having taken an embryonic trend for the benefit of the body as a whole, under the law of economy of growth, *disturbances of balance* are peculiarly apt to occur here."

"Not only is actual growth upset by the operation of this disturbance of balance, but certain potentialities are likewise interfered with."

Influence of the Pituitary Body.—"In dealing with the development of the palate, both pre- and post-congenitally, the relations of the hypophysis, or pituitary body, have to be taken into account, since it has been well demonstrated that this body exerts an influence over body growth and the structures thereto related."

"Strain on the development of the hypophysis after birth cannot only produce undue growth of bone, but can also check development of it." (Talbot, Etiology of Cleft Palate, Sec. V, Page 195; Trans. Fourth Internat. Dental Congress.)

Whatever the particular stress may be which lowers potentiality or retards development in the embryo, it is enough to know that such influences exist, and invariably affect the development of particular parts of the organism in greater or lesser degree.

Post-natal Factors in Arch Development.—After birth the normal development of the dental arch is largely a question of proper nutrition and function, recognizing also, the possibility of an insufficiency of nutrition and perversion of function with which the child may be born into the world, and from which inadequate foundation normal function and normal structure are not readily developed.

Heredity and Environment.—Just at this point it may be necessary to distinguish between the influences of heredity and environment, in order that a clearer conception of the two may be engendered.

Quoting from Dr. W. J. Brady, "The Influence of Heredity on Malocclusion:" "The tendency to resemble ancestry is called heredity, and a character or condition that appears prominently through a series of generations is said to be hereditary or inherited. The surroundings of an organism are called its environment, and include every possible condition which might have any effect upon its development, such as food, climate, light, air, moisture, heat, cold, cultivation, artificial benefits, natural enemies, companionship, mental condition, method of living, exercise, in fact, any and all things capable of exerting any influence for better or worse."

"Heredity is the force that holds all life to its true forms throughout the ages, and its power is not set aside in a few years even under an intensely changeable environment."

"Heredity always tends to promote the normal, the healthful, not the abnormal or diseased."

"Aside from the fact that heredity promotes the normal instead of the abnormal, it is also very questionable if a feature like malocclusion can be transmitted at all. A violent change is much less likely to be transmitted than a slight one, and a bad case of mal-

occlusion is certainly a great change from the normal. Weismann, the great writer on heredity, gives it as his opinion after years of observation that only slight acquired conditions are ever transmitted, and scientists are very cautious as to their statements of what changes may become hereditary and what may not."

"If a similar condition exists in parent and child, let us not jump to the conclusion that the defect is inherited, but rather let us investigate the environment. If we find contracted dental arches in the same family it is a sign that all members have lived upon the same kind of food, and all have failed to give normal exercise to the teeth and jaws. If nasal or pharyngeal hypertrophies exist from one generation to another, we will find the environment is inherited rather than the disease."

Functional Influences.—After birth, the influences which tend to normal arch development are largely functional, influenced of course by environment.

Succeeding mammary function, which is believed to have considerable influence upon general developmental conditions in infancy, the function of mastication, and the proper use of the muscles of the tongue, cheeks and lips, are the most important factors in the development of the dental arch after dentition is complete. The exclusion of other factors which would tend to retard development, such as anemia influenced by malnutrition, and other constitutional conditions, and the absence of nasal or post-nasal obstruction to normal breathing, are essential to the normal growth of maxillary structures and the proper sequence of functions.

Normal Muscular Action.—As illustrative of the effect of normal muscular action upon the development of bone in the maxilla and mandible, the lines of stress in developing bone caused by muscular action as seen with the X-ray by Walkhoff, offer sufficient evidence of the influence of muscular action in development, not only in embryo and infancy, but also during the entire period of development of the dental arches up to the time of the eruption of the last permanent tooth.

This investigator has demonstrated conclusively that the stress upon the surface of the bone through the muscular attachments was directly related to the internal development of and arrangement of the bone spicules, which form themselves in lines parallel to the direction of the exertion of the muscular force upon the external surface of the bone.

Disuse of the muscles of mastication, or their abnormal use,

therefore, must have its effect in the deficiency and abnormality of development in the dental arches.

The disappearance of the angle formed by the rami and body of the mandible in certain pronounced mouth-breathers of Class III is an evidence of the influence of abnormal muscular action upon the shape of the underlying bone.

Inflammatory Changes in Alveolar Tissues.—The thickening and hardening of the cancellated and cortical portions of the alveolar process through suppurative conditions caused by diseased teeth interferes with normal and uniform development of the bony tissues in which these changes take place, and no doubt are causative of some of the peculiarities of development of the dental arches, especially of tooth impaction.

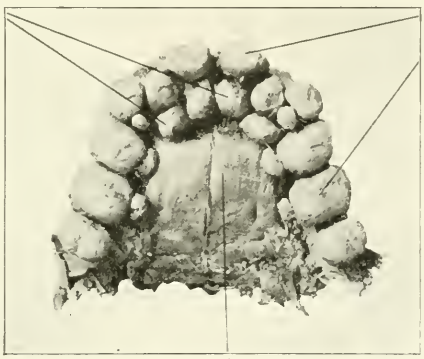

FIG. 357.—Tooth-follicles for deciduous and permanent teeth, three months after birth. (*Broomell.*)

Disease.—The influence of such diseases as rickets, syphilis, and others may seriously affect the development of the osseous structures of the maxillæ. Malocclusion is peculiarly a result of pyorrhea, the teeth becoming elongated, and forced into malpositions through the undue influence of their own inclined planes.

Abnormal Arch Development.—In consideration of the factors in arch development which have been stated, it is interesting to note the positions of the permanent tooth follicles at a period in child life when the deciduous teeth are unerupted, and speculate upon the possibilities of arrested development upon the permanent arches of teeth.

Fig. 357, represents the dissected tooth follicles of the deciduous and permanent teeth in the mouth of a child three months after birth, the

FIG. 358.

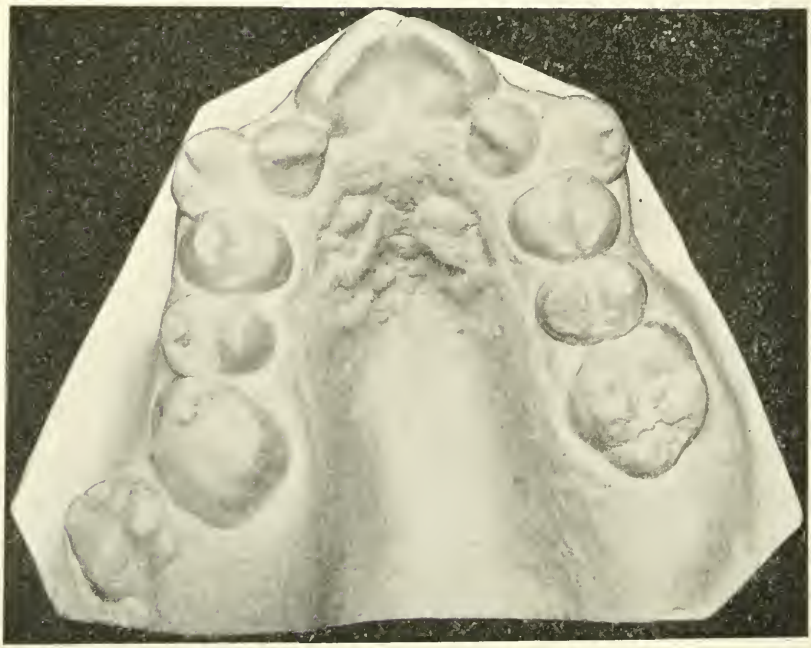

FIG. 359

plastic tissues in the center of the cut being the periosteum covering the hard palate, the tooth follicles being imbedded and firmly adherent to the fibrous tissues laterally and anteriorly.

The tooth sacs of the deciduous teeth are upon the periphery, being external to, and larger than the sacs of the permanent teeth. The arch of the deciduous teeth, which are nearly ready for eruption anteriorly, is very nearly uniform in shape and development, while that of the permanent teeth has not at this age even assumed any definiteness of uniformity or position of its teeth, the four permanent incisors being more fully developed than the cuspids and bicuspids, but the lingual position of the laterals indicates that considerable

FIG. 360.

FIG. 361.

arch development must take place before there will be sufficient space for these teeth to erupt into their normal positions in line with the centrals.

If, by reason of any infantile cachexia, such as malnutrition, from whatever cause, arrest of arch development should occur at this age, or even later up to five or six years of age, the resultant effect upon the arch of the permanent teeth might be such as is illustrated in the two casts shown in Figs. 358 and 359 at the ages of seven and twenty-seven, in which the positions of the central and lateral incisors are seen to be almost identical with that of the permanent incisor follicles in the previous illustration.

It will be observed that the adult arch in Fig. 359 did not develop any larger than the arch of the deciduous teeth in Fig. 358, the arrest of development being almost permanent except for the eruption of the permanent teeth into positions of irregularity, so great was



FIG. 362.

the functional disturbance which left its impress upon the maxilla and overlying processes.

Another interesting feature about the case of this adult is that there was no apparent facial deformity except the slightly marked

deviation of the central facial line at the age of four, see Fig. 360, but at the age of twenty-seven, see Fig. 361, the distortion of the facial lines indicates serious malocclusion and maldevelopment.

Again, in Fig. 362, is compared the upper deciduous arch of a four year old child, with the undeveloped upper arch of a ten year old child. The feature of striking interest in the case is the fact that the arch of the ten year old child is scarcely larger and is not more developed than that of the child of four with which it is compared.

Such studies as these prove to the observer that, although the func-

Fig. 363.

tion of occlusion is perverted, and its beneficial influence upon the growth of the dental arches lacking, there are still present causative factors of the arrested development, possibly of prenatal origin, which must be given due consideration.

Mouth-breathing.—One of the most serious abnormal conditions with which the rhinologist and the orthodontist have to deal, and one as intimately connected with the disturbance of normal function and structure in the field of the one as in that of the other, is the partial or complete loss of normal respiratory function through the obstruction of the nasal, naso-pharyngeal, and oro-pharyngeal air passages, causing oral respiration, commonly known as mouth-breathing.

That this condition, with all of its injurious results upon the development of the bones of the head and face, the disfiguring of the features, and the undermining of the general health, is becoming more prevalent, one hardly needs statistics to show, in view of the great numbers of those afflicted with this trouble in all walks of life.

Fig. 363 represents the face mask of a typical mouth-breather, the characteristic features noticeable being the open and drooping mouth, the short upper lip, the undeveloped nose, and undilated nostril, and the malocclusion of the teeth.

The vacant stare especially accompanies the presence of large adenoids, and is said to be caused chiefly by the stagnation of lymph at the base of the skull.

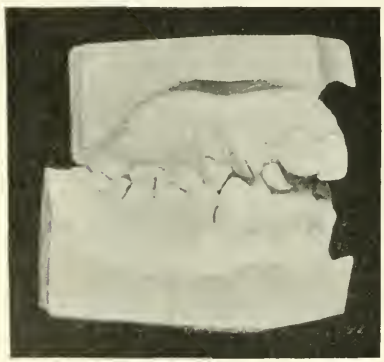

Fig. 364.

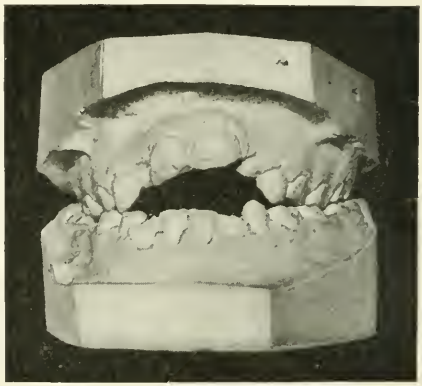

Fig. 365.

On examination of the relations of the arches of teeth (Fig. 364) of the patient whose face mask is illustrated in the previous figure, it will be noticed that arrested and abnormal development of the arches of teeth is in evidence, sufficient to cause a very great lack of harmony of the facial lines. The upper arch is narrow and elongated, the upper bicuspids and molars being in lingual occlusion, and the lower arch distal to its normal position, a case of the first division of Class II, Angle's classification.

It has been the observation of the author that a mouth-breather may present a malocclusion of any one of the different classes into which it is possible to divide the abnormal relations of occlusion, rather than of only one or two of them, as has been suggested by some writers, and the shapes of the arches of teeth are varied, and the extent of the malocclusion measured somewhat by the degree to which oral respiration is resorted to.

One of the most aggravating forms of malocclusion associated with mouth-breathing is that of the "open-bite" malocclusion, as it has been termed by some writers. Lack of anterior occlusion and "infra-occlusion" are similar designations for the same condition. Fig. 365 illustrates such a case belonging to Class I. There is a noticeable lack of development of both arches in this case, there being insufficient growth for the eruption of the permanent teeth, especially in the incisor region. The treatment of this case is illustrated in Fig. 467 in the chapter on treatment. A rather late operation for adenoids assisted in restoring normal respiration, and the correction of the mal-occlusion restored the function of the arches so that subsequent development along normal lines, both of the arches and the face, seemed assured.

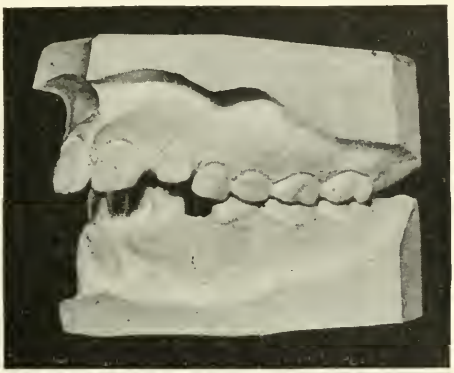

Fig. 366.

Fig. 366 exhibits a very common form of malocclusion, Class II, Div. 1, found among mouth-breathers, the lower arch being distal to normal in occlusion, and the shortness of the upper lip, and therefore lack of function in supporting the incisors, allowing them to protrude to a considerable extent, a condition which is aggravated or intensified by the lower lip adjusting itself between the upper and lower incisors and forcing the upper incisors still farther forward, and the wrong tension of the muscles of the upper lip over the canine region.

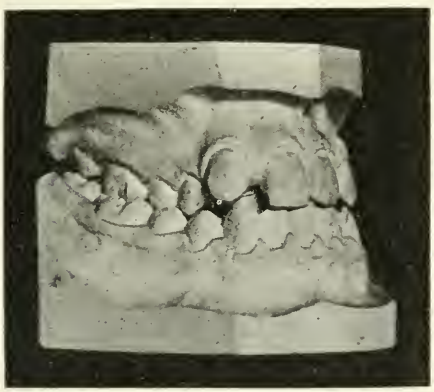

Fig. 367.

The elongation of the incisors from non-support of the lower incisors follows, and the articular motions of the mandible still farther extends the protrusion of the upper incisors. A very similar inharmony

of occlusion of the anterior teeth and disfigurement of facial lines is often seen in the protrusions of Class 1. See Figs. 479 and 481.

It is believed that the distal position of the lower arch in cases of this class is caused primarily by the lack of lateral development of the upper arch, because expansion of the upper arch in the early treatment of these cases often restores the normal relations of occlusion in the molar region, by allowing a farther forward position of the mandible without cusp interference. The author has had a great many cases in which retention of this position was unnecessary after the teeth of the mandible had once been allowed to assume a normal relation with the upper arch through expansion of the latter.

Fig. 368.

Figs. 367 and 368 exhibit two cases of malocclusion, belonging to Class I and II, Div. 2 respectively, both of which are associated with mouth-breathing, yet presenting very different objective symptoms, and necessitating essentially different methods of treatment in the restoration of harmonious occlusal relations.

It is of interest to note the variation of the inharmony in the forms of the two upper arches of these cases from the occlusal view in Figs. 369 and 370, the former being high and narrow, with inlocked laterals, and the latter comparatively low, and much broader, with outstanding cuspids.

Fig. 369.

The high and narrow arch, however is most frequently associated with mouth-breathing, varying in height and width somewhat according to the extent of the respiratory insufficiency and lack of develop-

ment of nasal cavities and adjoining structures, as well as in the peculiar relations of occlusion which may exist in each case.

The lingual occlusion of the upper molars and bicuspids in Fig. 367 produces an arrested development of the upper arch which cannot be

FIG. 370.

rectified until the labial occlusion of these teeth is restored through treatment.

Figs. 371 and 372 represent a mouth-breather at the ages of six months and seven years respectively, and it will be noted that the open and

FIG. 371.

FIG. 372.

drooping mouth and other symptoms are plainly noticeable in both pictures, showing that the mouth-breathing was of early origin, and had persisted and become more aggravated in its symptoms as the child grew older.

The casts of the child's teeth in occlusion in Fig. 373 exhibit a malocclusion of Class II, Div. 1 (Angle). Both arches are contracted and undeveloped, there being insufficient space for the eruption of the upper and lower lateral incisors, and in addition, the lack of anterior occlusion.

Mouth-breathing is usually called a habit, but in reality is a necessity, because of the inability to breathe properly through the nose, there being some impediment in the nasal tract which will not allow the air to pass by it.

Obstructions to Nasal Breathing.—Among the various obstructions to nasal breathing may be mentioned deflection of the nasal septum, hypertrophied tonsils, and turbinate bones, adenoids, and the diseased conditions resulting from syphilis, tumors, polypi, and cysts.

Fig. 373.

"If the nasal and post-nasal passages are unobstructed, every inspiration empties the ethmoid veins and through them the longitudinal sinus and cavernous plexus. When there is obstruction to nasal respiration, the circulation at the base of the skull is interfered with, and a long train of ills brought which interferes very greatly with the health of the individual. In the first place, the quantity of air aspirated through the mouth in a case of nasal obstruction is not equal to that of normal nasal respiration, and the system suffers from lack of sufficient oxygenation" (Grünwald).

Ziem's experiments in producing nasal stenosis in young animals by occluding one-half of the nose artificially, with the result of the asymmetrical development of the two sides of the nose and adjacent bony tissues, the obstructed half being arrested in development, as well as the contiguous tissues on that side of the face, are worthy of

note as proof of the correctness of the theory that nasal obstruction is causative of arrest of development in the human head and face.

It is important that the diagnosis of the obstruction of the air passages should be made as early as possible after its incipiency, so that by proper treatment and operation, if necessary, normal development may not be more seriously interfered with, and the health of the child seriously impaired.

There are so many local symptoms of this abnormal condition that even the novice ought to be able to diagnose it.

Vocalization is impaired, especially in the pronunciation of the

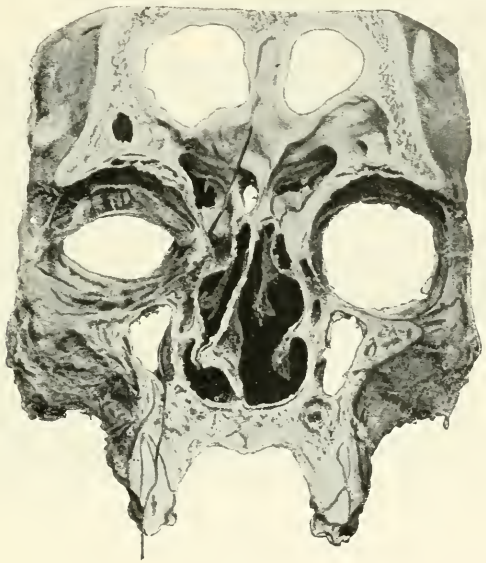

FIG. 374.

letters m and n, which, in the muffled voice of the mouth-breathers sound like b.

A persistent catarrhal condition, often mistaken by parents for an ordinary cold, together with an unusual dryness of the pharyngeal mucous membrane, and the continued drooping open of the mouth, ought to give warning of the beginning of serious nasal obstruction.

If allowed to continue, deficient nasal respiration may be causative of arrested development, not only in the face and head, but in other parts of the body, insufficient oxygenation causing anemic conditions of the general system, the dulling of the mental faculties, and a favorable opportunity for the inception of infectious diseases, especially tuberculosis.

Deviation of Nasal Septum.—In the normal subject the nasal septum occupies a position in the nasal cavity dividing one-half of the nose from the other.

Slight deviations are frequently seen in people who are not troubled with nasal stenosis to any degree, but where there is an extensive deviation from the median line, occlusion of the side toward which the deviation takes place occurs, with consequent deficient nasal and enforced mouth-breathing. Fig. 346 illustrates a skull section (from Cryer) in which the nasal septum is in its normal median position, the choanæ on each side being equal in size.

Fig. 375.

Fig. 374 portrays a marked deviation of the septum to the right. The choana on the side toward which the septum is deflected is very much smaller than the other, and must have been almost completely occluded during life, and there is every reason to believe that the subject was a mouth-breather.

Operations for the straightening or partial removal of the septum when deflected, are of common occurrence, and are usually followed by immediate relief to the deficient nasal respiration.

Hypertrophy of Faucial Tonsil.—Another cause of nasal stenosis is the hypertrophy of the faucial tonsils, and from the frequency with which operations for their removal are performed, their diseased condition and obstruction to nasal breathing cannot be judged uncommon.



Fig. 376.

The faucial tonsils are frequently the seat of infection and disease because of the hypertrophied condition and improper performance of function.

The large globular masses of tissue in Fig. 375 are the faucial tonsils removed from the throat of a two year old child, and are so hypertrophied that they are considerably larger than the same glands in the adult.

Hypertrophy of the turbinate bones, especially the inferior, is not an infrequent cause of nasal stenosis, and consequent mouth-

breathing. Fig. 376 exhibits a portion of the inferior turbinate which was removed from the nose of one of the author's patients who was suffering from partial nasal stenosis.

Adenoids.—One of the most common causes of mouth-breathing is found in the hypertrophy of the pharyngeal, or Luschka's tonsil, which is situated in the vault of the naso-pharynx, usually just out of sight above the uvula.

A mass of this enlarged glandular tissue may be seen in Fig. 377, being a posterior rhinoscopic view of the naso-pharynx, and it can be readily observed that the nasal passages may become completely occluded by the downward growth of this tissue.

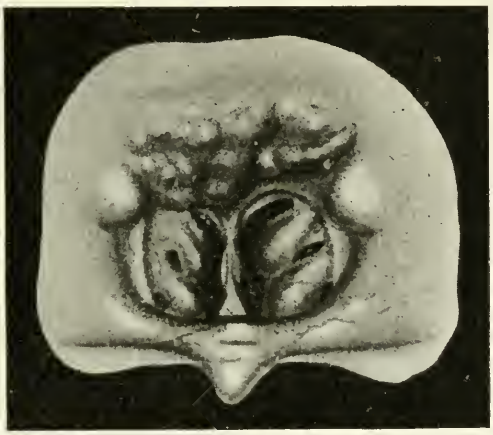

Fig. 377.

Dr. F. Park Lewis has called attention to the possibility of impairment of function of nutritive vessels passing through the carotid canal, which bears the carotid artery, the superior cervical sympathetic and the lymphatics, through the pressure of adventitious growths in the naso-pharynx upon the tissues which pass through the foramen lacerum medium, which is immediately above the site occupied by the adenoid tissues, and opening into the carotid canal.

His conclusions are based upon those of Sajous in regard to the control of all oxygenation processes in the body through the pituitary bodies, which are very closely associated with the nutrient vessels passing through the carotid canal.

Sajous' Theory.—Sajous indicates the significance of these organs and their physiological and pathological importance in this connection

as follows: "It will be apparent that any lesion capable of blocking the afferent and efferent impulses that travers it at all times, and which represent the aggregate of the organism, inciting and governing energy, must necessarily compromise life, or the functions of an organ to which the blocked nerves are distributed."

"The large mortality under chloroform in adenectomy is in all probability due to the shock conveyed to the posterior pituitary body through the foramen lacerum medium immediately over the lymphatic enlargements."

"It will readily be seen, therefore, that whatever interferes with

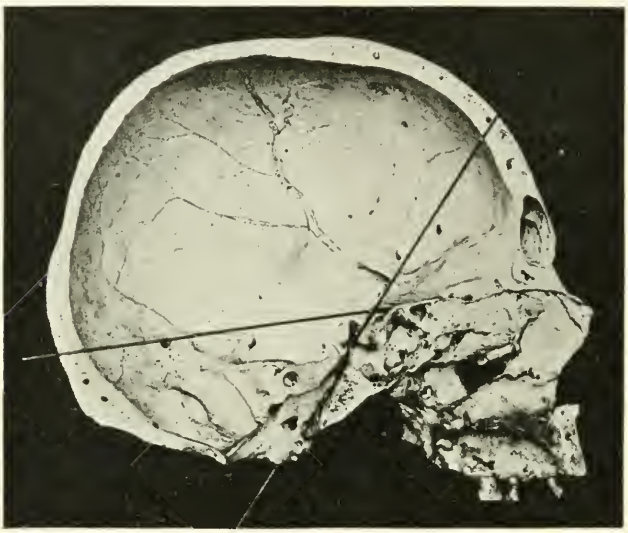

Fig. 378.

the nutritive functions at the vault of the pharynx may disturb the subsequent development of the whole skull and its contents."

The very close relationship which exists between the tissues of the pharynx, and the nutritive vessels of the carotid canal may be seen from observation of the position and direction of the more nearly vertical of the two probes passing through the skull section in Fig. 378, it being passed through the foramen lacerum medium and emerging into the space occupied by the pituitary body. The inferior opening of the foramen lacerum medium is in the adenoid region, and the vessels which enter it are very apt to be impinged upon by hypertrophy of the pharyngeal tonsils, and the nutrient and nerve supply to the pituitary bodies cut off enough to materially affect the proper

performance of the functions of these organs, with consequent disturbance of development of the whole skull and its contents, as well as that of the whole organism.

The horizontal probe in Fig. 378 passes through the optic foramen into the space occupied by the pituitary bodies, illustrating the very close relationship between the vessels of the eye and the pituitaries, and suggesting the probability of visual defects and insufficiencies from hypertrophied tissues in the naso-pharynx.

Fig. 379.

Removal of Adventitious Growths.—Even granting that these theories should not prove to be all that has been claimed for them, it would hardly seem to be necessary to argue the necessity of early treatment of malocclusion and the removal of all nasal and post-nasal obstructions to nasal respiration, thus insuring development before the period of normal and rapid growth has passed, together with the opportunity of greatest benefit to the patient.

Irreparable damage may be done by the neglect to observe the early symptoms of nasal obstruction, and the immediate placing of the patient in the hands of a competent rhinologist for operative treatment.

Deformed arches of teeth and disfigured features become confirmed

in their abnormality after a long period of abnormal development, and neither the local tissues nor the general system will respond to remedial measures to anything like the degree that they would had they been operated upon at an early age.

Fig. 379 represents a very characteristic expression of a mouth-breather of four years of age, who later, at the age of seven, was brought to the author for treatment of malocclusion.

The segregated mass of tonsillar adenoid tissue shown in Fig. 380 was removed from the naso-pharynx of this patient by a rhinologist, before treatment of the malocclusion was instituted.

Fig. 380

A diagnosis of the malocclusion revealed the mesial occlusion of the lower arch of teeth as seen in Fig. 526, and the restoration of the normal mesio-distal relations of the arches resulted in the change of occlusion noted in Fig. 527, the operation being performed entirely upon the deciduous teeth. The change in the appearance of the boy from the mouth-breather in Fig. 381, with his features all distorted in his efforts to close the mouth, to the calm, peaceful facial lines after the removal of these obstructing growths and correction of the malocclusion, in Fig. 382, indicates the advantage gained by early operating in this class of cases.

The development of this face along normal lines of growth is now assured and there is nothing left undone to insure the very best results in the restoration of facial harmony and normal respiration,

and consequently the attainment of proper physical development which in this case, was already deficient.

Mechanical assistance in holding the mouth closed after removal of nasal obstructions and correction of malocclusion, such as the wearing of head bandages and mouth plasters, is beneficial in the treatment.

Irreparable damage is done by the oft repeated advice to "wait until the permanent teeth are all erupted before beginning operations for correction of malocclusion," and even greater damage may be done by the neglect to observe the early symptoms of nasal obstruction,

FIG. 381.

FIG. 382.

and the immediate placing of the patient in the hands of a competent rhinologist for operative treatment.

Deformed arches of teeth and disfigured features become confirmed in their abnormality after a long period of abnormal development, and neither the local tissues nor the general system will respond to remedial measures to anything like the degree that they would had they been operated on at an early stage.

The head contains the portals of the human body, and it should be the duty of the orthodontist to guard against any ill effects to the health through the neglect of the oral cavity, its teeth, and related structures of nose and throat. Mouth-breathing, especially, should be prevented by such means as are at our command, with the aid of the rhinologist, and the correction of such resulting defects in occlusion

of the teeth and inharmony of the facial lines as may be necessary at the time the case presents with the symptoms of nasal stenosis.

Local Factors in Malocclusion.—Among the local causes of malocclusion of the teeth may be mentioned prolonged retention of deciduous teeth, premature loss of deciduous teeth, loss of permanent teeth, thumb-sucking and lip-biting, supernumeraries, and abnormal frenum labium.

Prolonged Retention of Deciduous Teeth.—The retention of a deciduous rooth beyond the time for its natural loss through absorption of its roots forms a mechanical barrier to the normal eruption of its permanent successor, which is deflected labially, buccally, or lingually. The permanent central incisors in Fig. 383 were deflected lingually

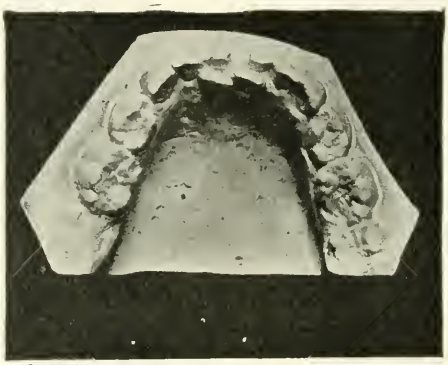

Fig. 383.

through the prolonged retention of the deciduous centrals, the roots of which did not absorb.

As soon as these conditions are observed, the deciduous teeth which have been retained beyond the time for their natural loss should be extracted, and the permanent teeth which have been deflected assisted into normal positions in the arch.

Premature Loss of Deciduous Teeth.—One of the prolific secondary causes of malocclusion and lack of arch development is the premature loss of the deciduous teeth, especially of the incisors and cuspids. That the mechanical influence of the deciduous teeth in assisting in the development of the arch is a necessity up to the time when natural absorption of the roots of the deciduous teeth should take place, one has only to observe the contraction of the spaces occupied by prematurely lost deciduous teeth to readily understand.

An illustration of the retarded development caused by the pre-

mature extraction of all deciduous teeth at eight years of age may be seen in Fig. 384. It is easy to prognosticate a serious malocclusion upon the eruption of the remaining permanent teeth.

The loss of the approximal surfaces of the deciduous teeth by caries is also causative of lack of arch development through the loss of the mechanical influence of the deciduous teeth in their entire mesio-distal diameters, and such carious conditions should be observed in their earliest stages and fillings inserted to restore full approximal contour.

The loss of permanent teeth through extraction or disease, by destroying arch integrity is another frequent cause of malocclusion, which is considered under the heading, "The Problem of Extraction."

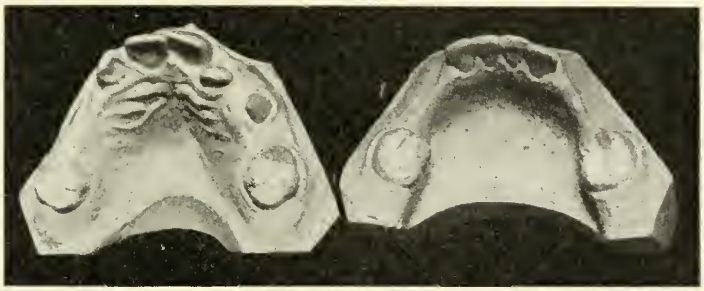

Fig. 384.

Thumb-sucking and Lip-biting.—The habits of thumb-sucking, lip and tongue biting are responsible for the inception of some malocclusions, and for the aggravation of a very great many cases, with other primary causative factors.

Thumb-sucking is not as frequent a causative factor in malocclusion as is generally supposed, but that it does affect the development of the arch is certain. Usually, but one side of the mouth is affected, according as to which thumb is used, although it is not uncommon to find that the thumb is held in the center of the mouth, protruding the upper central incisors. When the thumb is held on either side of the center, the upper incisors on the side in which the habit is induced are protruded.

In Class I and II cases in which the upper incisors are protruded, the habit of biting the lower lip has a pernicious influence in increasing the extent of the malocclusion, and in some cases is believed to be the initial cause of the abnormal occlusal relations.

The inculcation of a similar habit with the tongue is productive

of more or less deviations from the normal in occlusal relations, and the observance of any of these habits by the parent or dentist should be followed by efforts on their part to overcome the habit and the damage already done.

Prevention of Thumb-sucking.—A very practical method of

Fig. 385.

preventing a child from sucking the thumb is to enclose its hands in polished aluminum balls, such as is shown in Fig. 385, attached by a sleeve to the child's arm, and worn as much of the time as possible, especially at night, until the habit is broken up. Such a device is on the market by the name of Hand-I-Hold Babe Mit.*

The wearing of mits of this kind will enable the child to use its

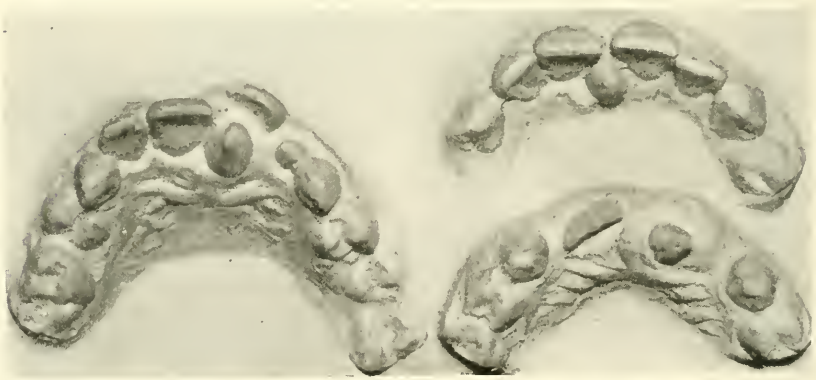

Fig. 386.

arms, yet at the same time, prevent the possibility of getting the fingers or thumbs into the mouth, and is much more humane than tying the arms. The balls are ventilated by several small holes, and the sleeve and ball may be easily sterilized by boiling.

Supernumeraries.—Supernumerary teeth are occasionally found

* Manufactured by the R. M. Clarke Co., Boston, Mass.

in the mouth, and are usually of the peg-shaped variety shown in Fig. 386, although sometimes resembling an adjacent normally developed tooth to such an extent that an X-ray diagnosis is necessary to differentiate between them.

Their removal is usually indicated, and the restoration to normal position of the teeth which have been forced out of their alignment.

Abnormal Frenum Labium.—The abnormal attachment of the frenum labium sometimes causes the separation of the upper central incisors, acting as a rubber cushion to force these two teeth apart. Cases of this character are somewhat difficult to treat, unless operative measures are resorted to for the partial removal of the ligament, so as to render it incapable of exerting lateral pressure. This operation is described under operative technique.

IV. DIAGNOSIS.

General Considerations.—A thorough diagnosis of any case of malocclusion should include the observance of every pathological indication in the oral cavity and adjacent parts of the head and face, for only with a full understanding of the variations from normal conditions is it possible to produce the best results in treatment.

If the deciduous teeth are present in part or whole, it should be noted whether they occupy their full mesio-distal space, and are assisting by their presence in the development of the arches. Their premature loss is usually indicated by a closing up of part or all of the space which they originally occupied, and indicates non-development.

A primary examination of the permanent denture should first deal directly with each individual arch, noting the absence of teeth, and their effect upon each arch, tracing minutely the changes incident to their removal in the contraction of the arch, and secondarily the effect upon the occlusion and articulation.

Accurate plaster models should be made and the normal sizes of the arches determined by a method of arch pre-determination to be described.

The case should be classified, and the etiological characteristics present carefully observed.

The variation of the facial lines from harmony should be studied in relation to the occlusion, and an inquiry into the history and habits should, by exclusion, remove any doubt as to their signification in the case.

Mouth-breathing, especially, will be readily detected from an observance of the distortion of the face and mouth peculiar to this pathological condition. The presence of enlarged tonsils may be easily seen with the tongue depressed slightly, and adenoids may be felt with the index finger carefully and quickly inserted into the throat above the uvulæ. The examination for adenoids and deflected septa and other nasal obstructions should be made by the rhinologist as soon as there is any suspicious indication of there being such pathological conditions present in the case.

The patient's general health should be inquired into, and the advisability of beginning or deferring treatment considered.

The principles of diagnosis in orthodontia are necessarily based upon anatomical variation in development of the maxillary and dental arches, including the variation from the normal in the occlusal relations of the teeth, with especial reference to etiological considerations, described in the preceding chapter.

As any diagnostic interpretation is only of value insofar as it is of use in prognosis, it will be recognized that the greatest benefits to be secured from treatment can only be assured by an intelligent perception of all the etiological and pathological factors involved in the case, no one of which is so obscure as not to be considered.

The history of the patient, with carefully detailed subjective and objective symptoms of pathological significance should be a matter of careful detail and should be recorded systemically for future reference in the treatment of the case.

Classification of Malocclusion.—In contrast to the chaotic designation of deformities of the dental arches in use a decade ago, it has remained for Dr. E. H. Angle to point out to the profession the natural divisions and subdivisions into which malocclusion is divided, and upon which the scientific treatment of malocclusion is founded, the successful results of which are in evidence in the practices of the specialists working along these lines throughout the world.

The Angle classification of malocclusion is based upon the mesio-distal variation of the dental arches from the harmonious relationship of normal occlusion, three distinct classes being represented, and an occasionally found fourth class.

Class I.—To the **first class** belong those cases of malocclusion which are characterized by normal mesio-distal relations of the dental arches, with contracted and undeveloped maxillary arches, especially in the anterior portion, in which the teeth often assume varied forms of individual malocclusion, and often simulating in this anterior region,

the peculiarities of Classes II and III, both in the occlusion and facial deformity.

Class II.—In the **second class** of malocclusion are placed all those cases in which the lower dental arch is distal to the upper on one or both lateral halves, having two divisions of bilateral distal occlusion, the **first division** being characterized by protruding upper incisors, usually mouth-breathers, and having a **subdivision** in which the distal occlusion is confined to one lateral half, the other half being in normal mesio-distal relations; the **second division** having retruded upper incisors, usually normal breathers, and its **subdivision** having the distal occlusion on one lateral half of the dental arches only.

The facial profile of a case of the **first division of Class II** is usually diagnostic of the occlusal relations, the upper lip being short, and revealing the protruded upper incisors, and the receding chin indicating the distal occlusion. As these cases are usually mouth-breathers, the characteristic open drooping mouth and peculiar tension of the facial muscles is a sure indication of naso-pharyngeal obstruction of present or previous date.

The facial deformity is not so pronounced in the **second division,** the patients usually being normal breathers, the upper lip being of proper length, but the features disfigured by the receding chin and lower third of the face.

Class III is characterized by a position of the lower arch which is mesial to the upper, with protruding lower incisors, having a **division** in which the mesial occlusion is bilateral and a **subdivision** in which the mesio-distal relation to the upper is normal in one lateral half of the lower arch and mesial to normal in the other.

The facial profile is correspondingly deformed, the chin being prominent, the middle third of the face undeveloped, the angle of the rami of the mandible being more obtuse than normal, and, in some cases of long duration, there being scarcely any discernable angle between the point of the chin and the articular ends of the condyles.

Mouth-breathing is frequently observed in this class, and its existence in any case serves to increase the inharmonious lines of the already deformed face.

Class IV.—A very rare class, although found to exist in sufficient numbers to be worthy of record, and treatment, is **Class IV,** in which the occlusal relations of the dental arches present the peculiar condition of being in distal occlusion upon one lateral half, and in mesial occlusion upon the other half of the mouth.

As diagnostic of these various classes, the variation from the normal

mesio-distal relations is usually best indicated by the relative mesio-distal relations of the upper and lower first permanent molars in occlusion, since they present a history of the longest lived occlusion during the ages in which malocclusion usually presents, and having such an important part in the building of the permanent dentition as to be appropriately styled "the bulwarks of the dental arches."

Classification Chart.—In order that the principles upon which this classification is based may be the more readily understood, the author has arranged the four classes in comprehensive chart form in Fig. 387, the right and left lateral halves in occlusion being represented in each section, with the line of diagnosis intersecting the occlusion of the mesio-buccal cusps of the first permanent molars of each class, and illustrating at a glance, the deviation from the normal mesio-distal relations of each lateral half in each class, division and subdivision.

The use of the upper first molar for the purpose of noting mesio-distal variation of the lower dental arch presupposes a certain unvarying stability or a fixed position of this tooth in relation to the maxilla and the adjacent anatomical regions, which might be understood as being absolute, but such is not the case.

Cases have been reported in which the upper first molar was mesial or distal to its normal position in the arch, although the infrequence of these cases and their observance only affects the classification as far as certain details of the treatment is concerned, the main points of the treatment indicated thereby being essentially unaffected.

In simple, the indications for treatment as observed in the chart are, first, the restoration of normal shape and size of the dental arches in each class, second, the restoration of the normal mesio-distal relations of the arches in Classes II, III, and IV.

Notwithstanding the various criticisms which this classification has received from a theoretical standpoint, it has been proven beyond question to be of greater practical value than a more complicated classification in which the minute details of arch malformation and facial inharmony are combined. The especial criticism which has been made against this classification is in regard to the particular relationships of the maxilla and mandible to the internal face in Class II and III, the claim being made that cases are found in which in Class II, for example, the upper arch of the maxilla is protruded in relation to the internal skull, and the mandible retruded from a normal relationship to the internal skull, and vice versa, in Class III. Very few records have been found of this class of cases, and their paucity only strengthens the classification of Dr. Angle, since they represent

individual characteristics of forces operating in malocclusion which have to be taken into account in any class, and which require only mention in a context in the same manner that open-bite malocclusions are noted, their treatment following along the same lines as the class they simulate or exaggerate, aided by the individual skill and judgment of the operator.

Infra-occlusion.—Infra-occlusion, or lack of occlusion of the teeth, is a condition of abnormal development occurring in several different forms, and more or less common to all classes of malocclusion requiring special description in a classification based upon the mesio-distal variations only of malocclusion.

Varying as it does from the slight infra-occlusion of one or two teeth to complex cases in which the entire dental apparatus is involved, its diagnosis, in any extensive form, places the presenting case in the class of the most difficult to treat.

Associated as it usually is, with mouth-breathing, the functions of normal breathing must be restored before treatment is successful, as it is believed that mouth-breathing is the greatest causative factor in its production.

Add to this the overdevelopment of one region and the under-development of another part in the same maxillary arch, and the extent of the abnormal conditions present may be understood.

Variations of Infra-occlusion.—Infra-occlusion occurs in several forms, best described by the designation of the region in which it is observed, as infra-occlusion of incisors, cuspids and bicuspids, infra-occlusion of bicuspids and molars, and full bimaxillary infra-occlusion.

Infra-occlusion of Incisors, Cuspids, and Bicuspids.—By far the most common form of infra-occlusion is observed in the lack of occlusion of the incisors, cuspids, and bicuspids, sometimes including the first and second permanent molars, varying usually with the extent of the mouth-breathing.

It is especially characterized by lack of development of the premaxillary portion of the arches, and oftentimes overdevelopment of the posterior portion of the same arches.

Fig. 388 illustrates an extensive case of infra-occlusion extending distally as far as the molar region.

Bilateral Infra-occlusion of Bicuspids and Molars.—Extensive infra-occlusions involving the molars and bicuspids on one or both sides, may occur in any of the various classes of malocclusion. Fig. 469 represents acase of bilateral infra-occlusion of the molars and bicuspids, and in its mesio-distal relations, it may be classified as a Class I case.

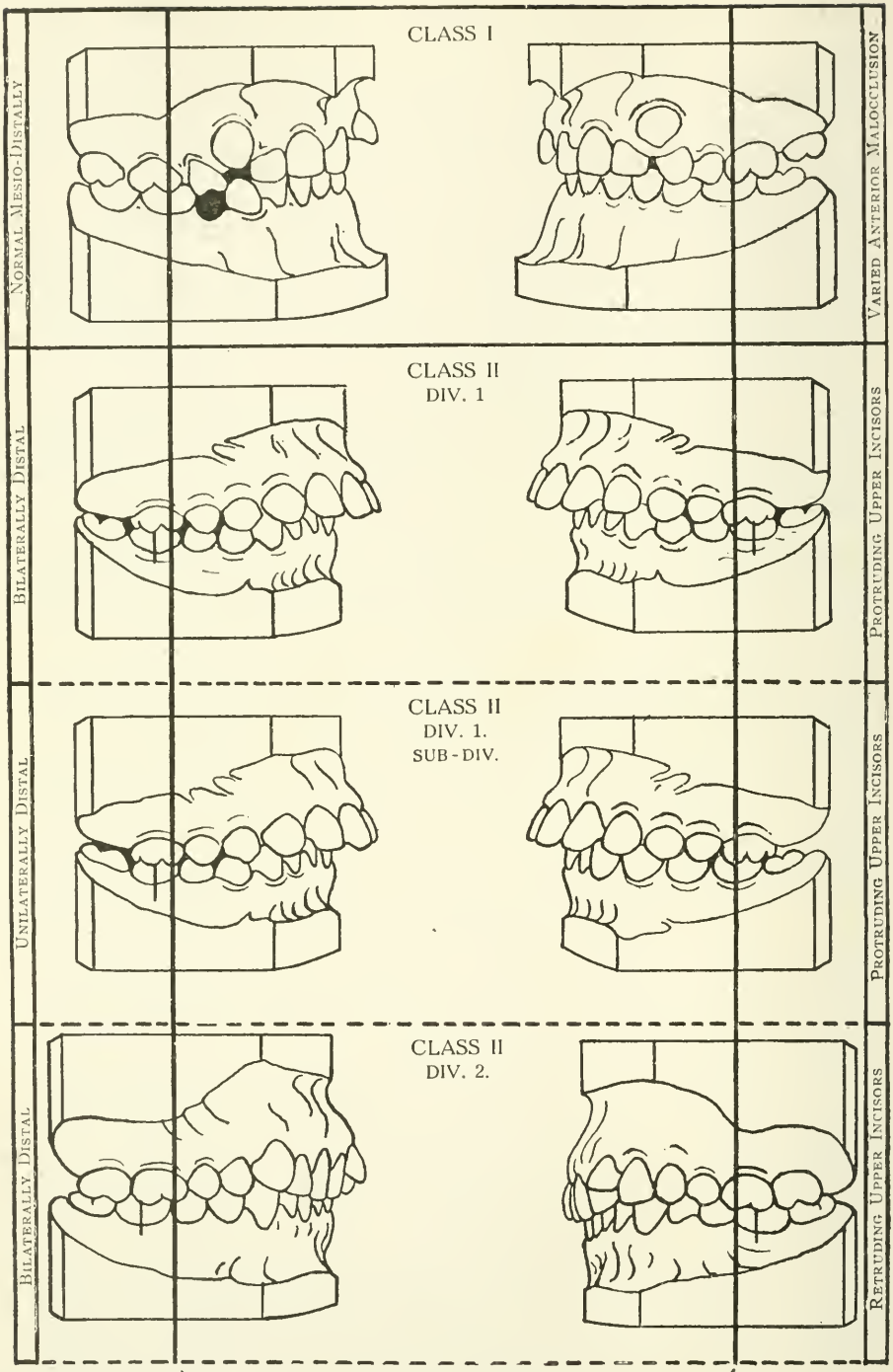

FIG. 387.—Diagnostic chart of the mesio-distal variations in malocclusion. Based upon the Angle classification.

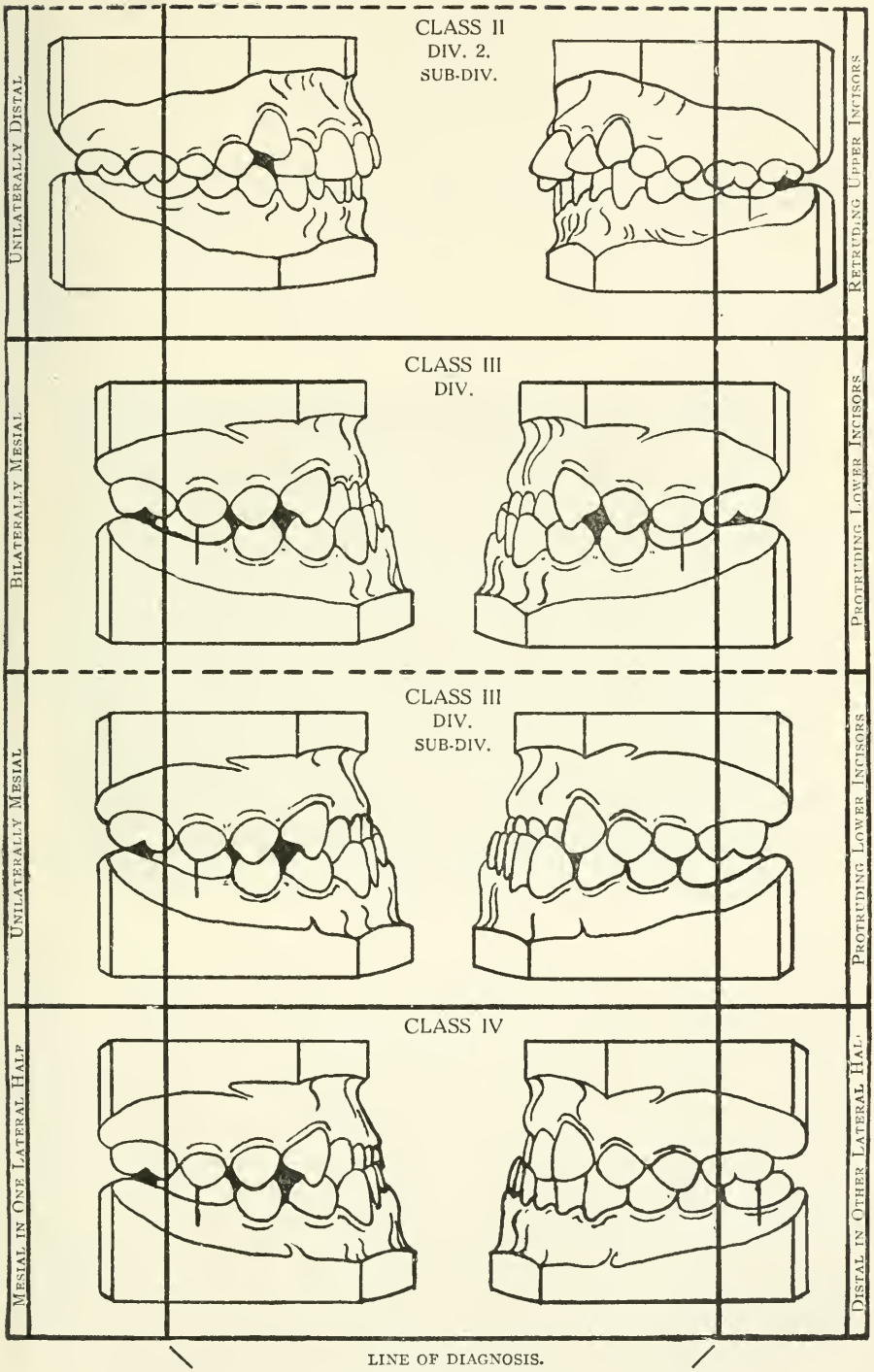

Fig. 387.—Diagnostic chart of the mesio-distal variations in malocclusion. Based upon the Angle classification.

Unilateral Infra-occlusion of molars and bicuspids is a condition more commonly observed as the result of arch mutilation through extraction especially of the first permanent molars.

Full Bimaxillary Infra-occlusion.—Another extensive case of infra-occlusion, involving all of the teeth of both arches, described by Dr. C. S. Case, in the *Dental Cosmos*, for December, 1905, page 1411, is worthy of especial notice, as requiring special classification.

As seen in the cast on the right of the cut, Fig. 389, the teeth, anteriorly and posteriorly, are very much too short in relation to the plane of occlusion, although being comparatively normally related mesio-distally, and the arches quite fully developed and of normal

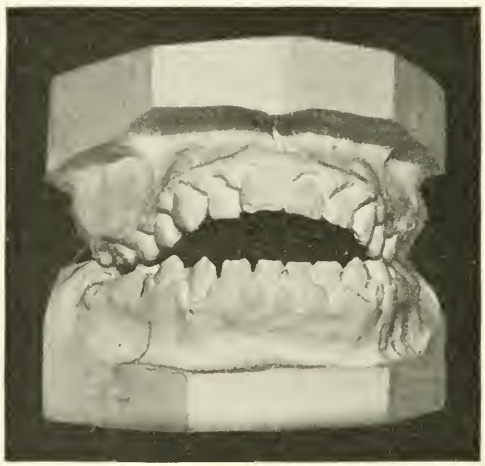

Fig. 388.

shape. When the jaws are closed, as in the model on the left of this figure, the facial appearance is that of an edentulous mouth, with its lines of senility caused by the approximation of the nose and chin, and the unnatural fullness of the lips and cheeks, as illustrated in the face mask on the left of the cut. The model and face mask on the right, the normal pose of the profile, was obtained by placing a piece of modeling compound between the teeth, and the distance between the arches of teeth adjusted until the profile appeared normal.

Arch Predetermination.—An accurate conception of the normal size and shape of the dental arches in malocclusion is no longer a matter of guesswork since the mechanically and anatomically reconstructed arch has been made a possibility by the application of the laws of Bonwill in the synthetic reproduction of the normal arch for

any given case, as worked out geometrically by Dr. C. A. Hawley who by a reversal of the method of triangle construction of Bonwill, has succeeded in predetermining the size of the arch by constructing a triangle from a primary measurement of the arc of the centrals, laterals and cuspids.

A scientific determination of the normal arch in any case of malocclusion not only removes any doubt as to the extent of arch expansion in treatment, but provides for the establishment of the normal function of articulation, which is most important in mastication, and preservation of arch integrity, which the construction from an equi-

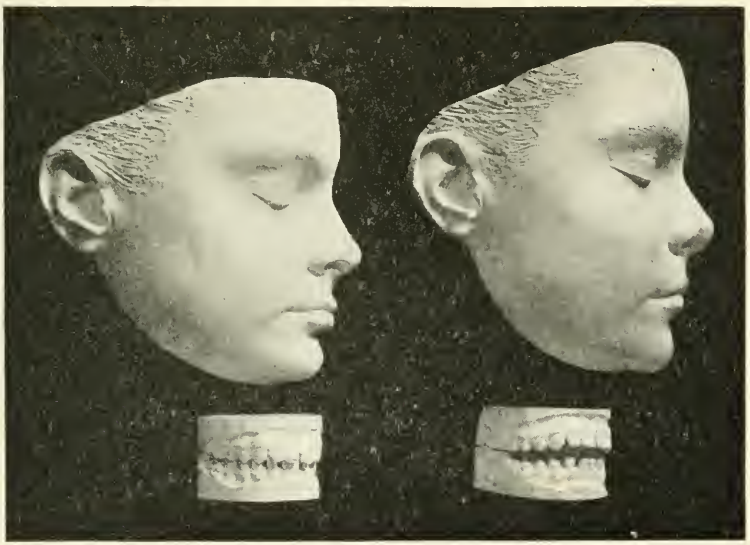

Fig. 389.

lateral triangle, aided by the relationship of length of cusps to depth of overbite, and the compensating curves from cuspid to molars, affords by the harmonious working of these laws.

Quoting from Dr. Hawley's article on arch determination, the construction of the triangles and reproduction of the normal arch for any given case is as follows:

Dr. Bonwill's Diagram.—"In Fig. 390, we have Dr. Bonwill's geometrical figure, an equilateral triangle, AFG, inscribed within a circle, its base FG representing the distance between the condyles, which varies in the living subject from three to five inches. According to his plan, in artificial dentures, the teeth are arranged with the

cuspids and incisors in the arc of the circle AJCH, the size of which varies according to the size of the teeth selected for the case, and this selection is left to the judgment of the operator."

Dr. Hawley's Diagram.—"In order to use this principle in orthodontia, where we have the size of the teeth given us, and from their widths the diameter of the circle AJCH, we must reverse the order of procedure and find a connecting relation between this circle and the equilateral triangle AFG, or the circle within which it is inscribed.

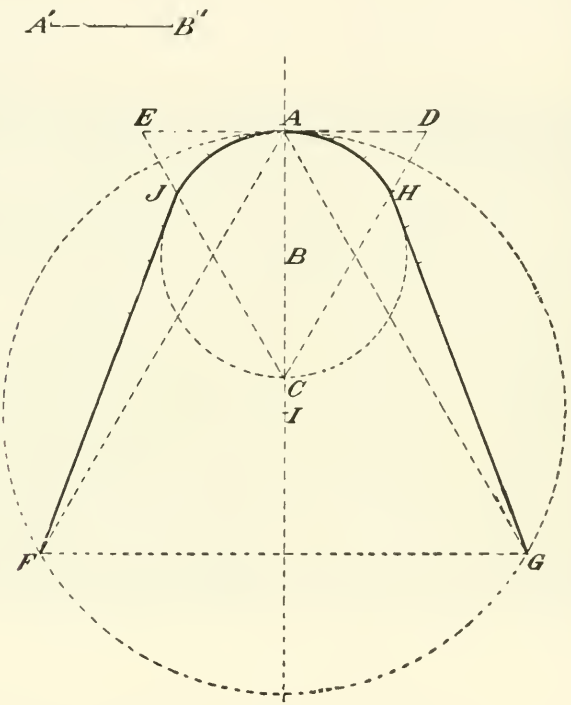

Fig. 390.

This connection is not described in Dr. Bonwill's writings so far as I have been able to find. It is found in the triangle EDC, constructed with its apex at the point C, on the diameter of the circle AJCH, and its base tangent to the same circle at A, the sides passing through the points J and H, located on the circle by the distance of the radius from A."

"In application, to construct the diagram, we take the radius of the circle AJCH from the combined widths of the central, lateral, and cuspid teeth shown at AB. With this radius AB, upon the line

AC, which becomes the extended diameter of the circle, draw the circle AJCH, and with the point of the compass at A, mark off the radius upon the circumference at H and J. We have here the arc of the circle upon which the six front teeth are to be arranged, but know nothing of the size of the triangle AFG."

"From C draw the lines CE and CD, through H and J, extending them indefinitely and draw a tangent to the circle A, cutting these lines at E and D, and forming an equilateral triangle ECD. Take one side of this triangle as a radius, and with one point of the compass at A, and the other upon the extension of the diameter at I, describe the large triangle AFG. Then draw the lines FJ and GH, and we have the desired diagram or arch upon which we may measure off the teeth with the width as found in the mouth."

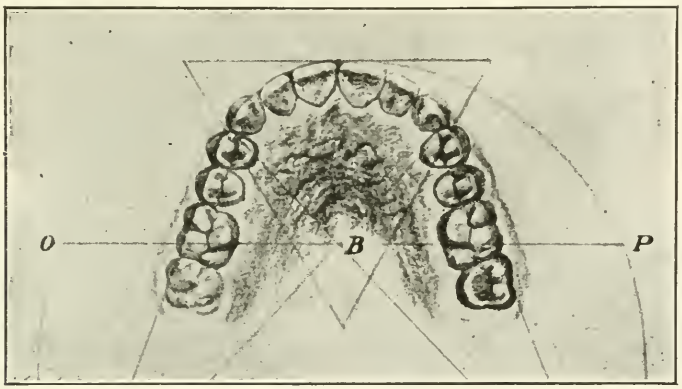

FIG. 391.

Fig. 391 represents the upper arch of teeth drawn in position on the predetermined arch, after their mesio-distal diameters had been measured off from each side of the median line.

The Simplified Method.—Although this gives a very graphic idea of the normal arch for a given case, Dr. Hawley's second method is more practical because of its not requiring special artistic ability in drawing, and but a short time is needed to complete it.

The line drawing of the predetermined arch is transferred to a piece of transparent celluloid, a suggestion of Dr. L. P. Bethel's, and by placing this in position over the occlusal surfaces of the teeth of an upper or lower cast of the case before treatment, the extent of expansion, and change in the shape of the arch, laterally and anteriorly, is very plainly indicated.

Fig. 392 represents a case of malocclusion of Class II, Div. 1, (Angle) in which it was desired to determine the normal size and shape the arches of teeth should assume after treatment.

The superimposed diagrams are seen in Fig. 393 upon the upper and lower casts of the case before treatment and indicate considerable widening and shortening of the upper arch, and but very little ex-

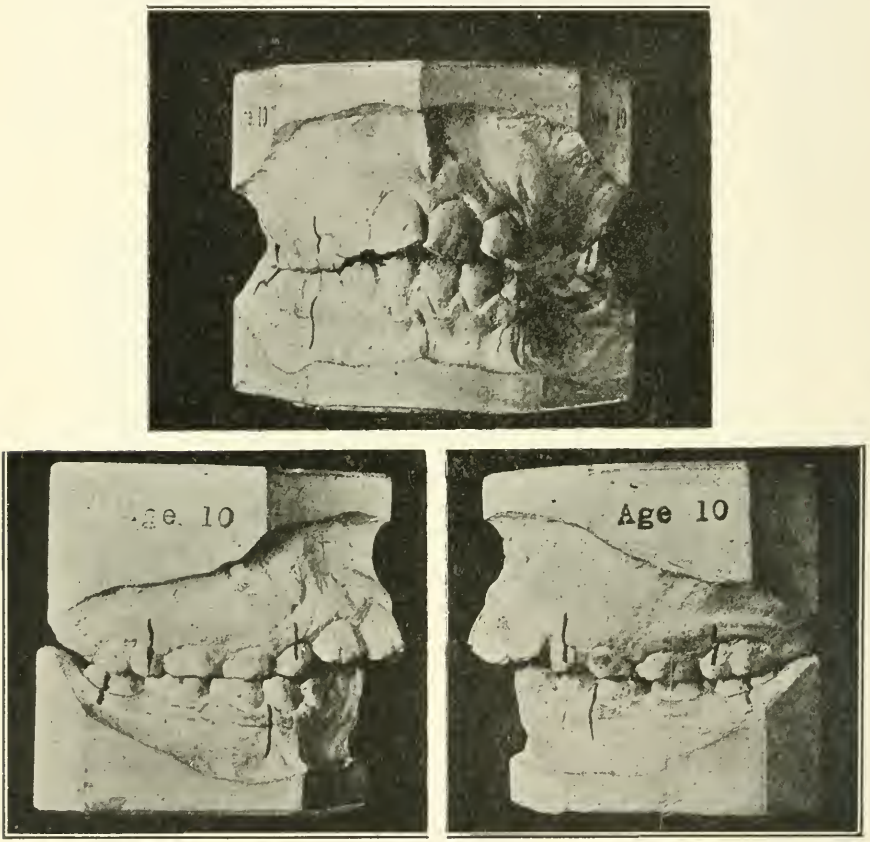

Fig. 392.

pansion of the lower, the apparent disparity being explained by the fact that the lower arch is very nearly its normal size, and only requiring the forward shifting of its teeth to harmonize in occlusion with the upper arch, the distal position having been assumed because of the narrowing of the upper arch.

Fig. 394 illustrates the occlusal views of the finished case with

the diagrams in position, and the new "line of occlusion" (Angle) coinciding with the predetermined arch.

The front and side view of the completed case in Fig. 395, in harmonious relations of occlusion, testify to the accuracy and correctness of the method, and to its value in diagnosis, prognosis and treatment.

Comparative arch and tooth measurements in the mouth and on

FIG. 393.

the diagram in the progress of a case, will serve as a constant guide to the attainment of the predetermined arch. These measurements are made with a scale graduated in hundredths of an inch, and one with specially fine points has been adapted by Dr. Hawley for the purpose. (See Fig. 396.)

Table of Average Measurements.—So far, in the use of this

FIG. 394.

method, the measurements have been taken from arches in which the full complement of permanent teeth is present, but, by means of a system of comparative tooth measurements in a large number of cases in which the permanent teeth are all present, Dr. Hawley has succeeded in formulating a table of average measurements, especially of the cen-

trals, laterals and cuspids, so that by the measurement of a single central incisor in a case in which the permanent centrals and first molars were the only teeth erupted of the permanent dentition, the width of the permanent lateral and cuspid to be erupted later may be quite accurately gauged, and consequently the arc of the anterior teeth from which the entire permanent arch is determined.

Quoting from Dr. Hawley, the method of making these tables and

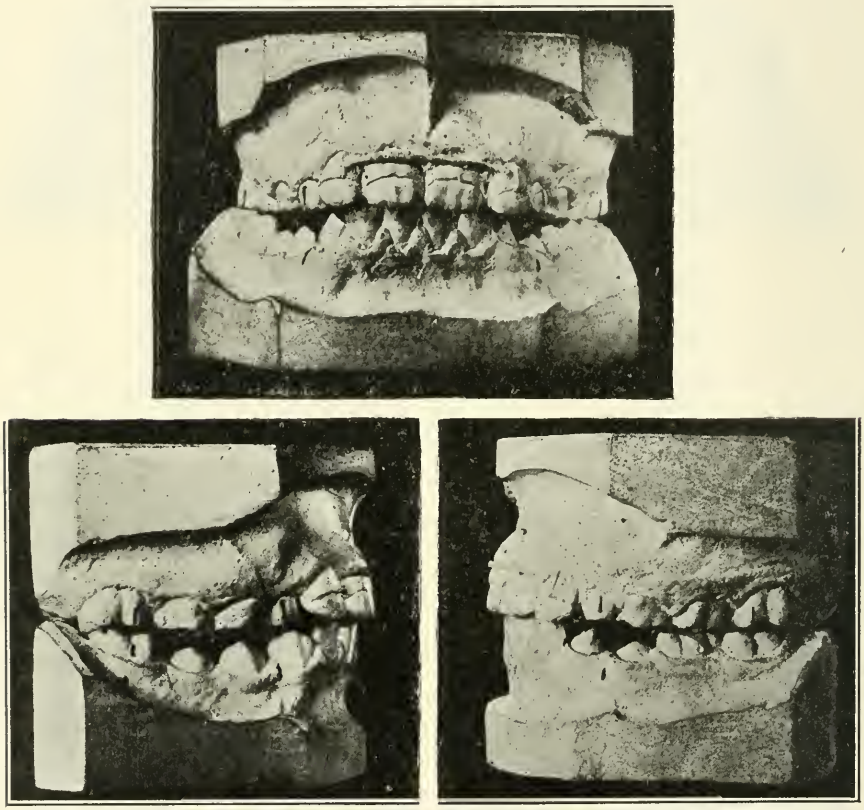

Fig. 395.

their applicability may be more clearly shown as follows: "Now, if the teeth were found in the mouth in the same proportion in respect to their greatest and least width, that is, if with a .31 central, we would find a .19 lateral, a .27 cuspid, a .27 first bicuspid, a .23 second bicuspid, and a .35 molar, and so on with each size of central, we could make out the radius of each size central, and from these draw proportional diagrams. But such is not by any means the case, for, with a .31

central, we often, in fact usually, find a lateral .26 or .27, and the cuspid may be quite well up in the scale, or we may have a central and lateral in good proportion and the cuspids much larger."

"In order to discover the nature of this variation, I selected from the 100 measurements all the cases of each width of central, and made of each of them a table."

"The number of cases of each size central was .31, fifteen, .32,



FIG. 396.

seven, .33, sixteen, .34, sixteen, .35, nine, .36, fourteen, .37, thirteen, .38, five, and .39, two.

Collecting each of these sets, nine tables were made, each representing the variation in width of the laterals, cuspids, bicuspids, and first molars in arches in which the central incisors were all of the same width, of which the table below of the .35 central is an example:

CENTRAL	LATERAL	CUSPID	1ST BIC	2D BIC	1ST MOLAR
.35	.24	.31	.27	.27	.41
.35	.28	.31	.29	.30	.41
.35	.25	.30	.25	.25	.42
.35	.28	.31	.28	.27	.42
.35	.27	.33	.29	.29	.44
.35	.24	.30	.30	.28	.41
.35	.28	.33	.29	.26	.40
.35	.26	.30	.27	.27	.43
.35	.27	.32	.27	.27	.41
Average:					
.35	.27	.31	.28	.27	.42

The average measurements of the nine tables were then computed, forming an average table with centrals of varying width from .31 to

.39, and the average widths of the other teeth, as in the following table:

Cent'l	Lateral	Cuspid	1st Bic	2d Bic	1st Molar	Radius	Corrected radius
.31	.26	.29	.26	.26	.39	.86	.86
.32	.26	.30	.27	.26	.40	.88	.88
.33	.27	.30	.28	.27	.41	.89	.90
.34	.28	.30	.28	.28	.42	.92	.92
.35	.27	.31	.28	27	.42	.93	.94
.36	.28	.32	.28	.28	.42	.96	.96
.37	28	.32	.30	.29	.42	.97	.98
.38	.28	.34	.30	.29	.44	100	100
.39	.31	.34	.31	.29	.44	104	102

The combined widths of the central, lateral and cuspid in each one of the nine tables, represents the radius that may be used for the predetermination of the arch.

The Corrected Radius.—A corrected radius at the extreme right of the table is based upon a uniform variation of .02 of an inch from .86 to .102.

Quoting again from Dr. Hawley: "Now, taking these corrected radii, we will get an arch for each width of central, and I will propose these as a basis of diagnosis, study and treatment of cases where only part of the teeth are erupted, or under the age of twelve."

"Or using the radius in hundredths of an inch for comparison, they may be used as a guide for all cases, for where we can measure all the teeth, we have only to select the diagram with the correct radius, and measure in the teeth. Remembering that these arches are only averages, and smaller or larger teeth will constantly occur in connection with the particular central, is there any indication by which we can judge in which direction this variation will occur, *i. e.*, toward smaller or larger teeth? I think we have this in the first molar, and this tooth is always present at the time of eruption of the central incisor. As the first molar varies up or down from the average width, I believe the rest of the teeth will vary. For instance, we will suppose we have a case in which the central incisor is .34 and the first molar is .42. If I had a second case with the same size central, but with the first molar .44, I would presume that the lateral and cuspid, and all the rest of the teeth would be likely to be large, and would select the next larger arch. In this way I think we have the key to a fairly accurate judgment of the future denture."

"In making up these averages, I have tried to err, if at all, on the side of the larger arch, believing if we do get the arch slightly larger than the teeth will fill, if it is properly shaped, and the teeth are placed in normal occlusion, as the excess will, at the worst, be only a few

hundreths of an inch, the pressure of the checks and lips, the influence of the occlusal planes and the pressure forward of the second molar in eruption will close the spaces."

Illustrations of Practical Cases.—"In illustration of my use of these arches, let us take the case of a child eight years of age, Fig. 397. We have here erupted of the permanent upper teeth, only the centrals and first molars, and in the lower, the centrals, laterals, and first molars. All of the lower deciduous molars have been extracted, as well as the lower first deciduous molars. The arches are consequently contracted, especially the upper, in which the centrals are in

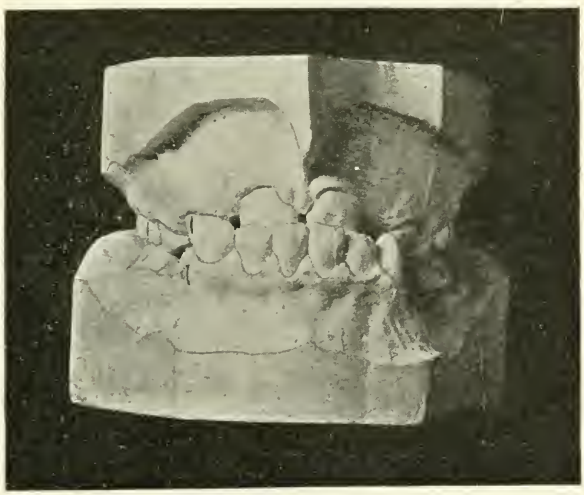

FIG. 397.

lingual occlusion. The centrals are .33 wide and the molars .37, while the average molar for that diagram is .41. As the molar is small, I judge we are likely to find small laterals and possibly small bicuspids, as these are the teeth that vary most, so I would select no larger arch than that for .33.

"Fig. 398 shows the development that will be necessary."

"Similar tables were made for the lower teeth, and the result makes it evident that the uniformity of lower arches, drawn from the measurements of the lower incisors and cuspids, is not to be depended upon. While the lower bicuspids and molars are fairly uniform in their relation to the upper, within the same mouth, the incisors and cuspids are not. This lack of uniformity is probably compensated for in the inclination of the teeth and the overbite. . . . . I wish to advise that

instead of drawing the lower arch from measurements of the lower teeth, ... the radius for the lower be taken from .13 to .23 of an inch shorter than the upper, depending within this variation on the size

Fig. 398.

of the teeth or the distance from the line of occlusion to the crest of the buccal cusps."*

"Fears have been expressed that, in bringing into orthodontia a mathematically and geometrically calculated plan, we would restrict

Fig. 399.

or eliminate the feature of artistic judgment, and that the method leaves no room for the exercise of judgment in changing the form of the arch to satisfy the requirements of the various types. These

* For the sake of convenience, accurately drawn charts on transparent celluloid of the upper and lower arches, with radii of varying widths from .86 to 1.04 in the upper and .70 to .90 in the lower, have been prepared and placed in the depots.

fears or objections have been due to misconception of the elasticity of the method in its application. . . . . In so far as hampering, in any way, the use of judgment in the art requirements of orthodontia, this method lays down the most valuable principles, and forms the most important basis upon which artistic results in orthodontia must be accomplished; and instead of restricting the variation of the arch to correspond to different types, it forms the only safe guide for procedure in such variation."

FIG. 400.

"By restoring normal occlusion, and a form of arch in harmony with the size of the teeth, that will admit the natural movement of the mandible, we will thus, so far as the mechanism is concerned, obtain the natural development of the denture. And in retention, we will guard against any final retrogressive changes that might take place, by conforming the arch to the natural mechanical forces of articulation."

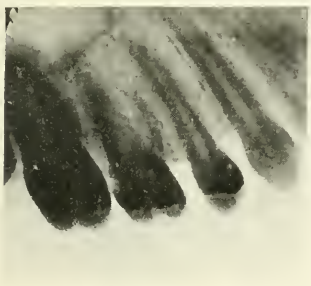

FIG. 401.

The Line of Occlusion.—Until the pre-determination of the arch became a possibility, the "line of occlusion" defined by Angle "as the line of greatest normal occlusal contact," seemed to answer the purpose of a fixed, though imaginary line of the normal arch from which to note deviations of individual teeth from the normal line of the arch, such as would be interpreted from "an incisor in lingual occlusion," etc.

FIG. 402.

Dr. Angle's later definition of this line "as being the line with which, in form and position according to type, the teeth must be in harmony if in normal occlusion," is very comprehensive as to its characteristics, except as to the determination of this line in a case of malocclusion, where it should be of the most practical value in noting deviations from the normal lines of the arches to have a somewhat

accurate idea of the location of this line, as inaccuracy in this respect would lead to much confusion.

The pre-determined arch line, not only accurately locates the proper "line of occlusion," but enables one to more exactly designate malpositions of the teeth in relation to it.

It is true that the line of the pre-determined arch is not strictly conformative to type, but this is unessential, since the typal form of the arches is best produced through the attainment of the proper working of the mechanics of the laws of articulation from which the line of the pre-determined arch is derived.

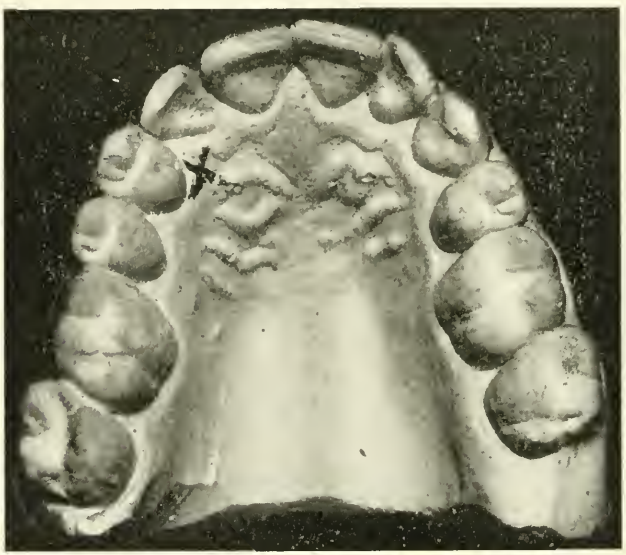

FIG. 403.

Roentgen Rays.—The use of the Roentgen rays has been of inestimable value to the orthodontist, in enabling him to pre-determine the location of unerupted teeth, if present, as well as the shapes of the roots of the teeth and their angles of inclination, diseased areas, etc.

It is properly considered under diagnosis, for with such foreknowledge of the anatomical defects, if any, that the radiograph shows, the operator is able to progress with any doubtful case without delay, or the possibility of a mistake in treatment due to lack of previous knowledge of the exact conditions present.

Not infrequently, is the orthodontist called upon to diagnose the presence or absence of a permanent successor to a deciduous tooth,

which the radiograph alone will determine. Such a case is seen in Fig. 399.

The long retention of the deciduous pre-molars on both lateral halves of the arch caused some anxiety on the part of the family dentist in charge of the case, as he thought they ought to be extracted to allow the permanent successors to erupt.

An X-ray was secured of both lateral halves and the radiographs printed (Figs. 400 and 401) proved that the second bicuspids were not present, having failed to develop, and the deciduous molars retaining their full length of roots bid fair to act as efficient substitutes of the undeveloped bicuspids for many years.

Frequently the cuspid will assume such a position in the alveolar process that its proper eruption would require surgical interference, as in Fig. 402, a radiograph loaned by Dr. C. Edmund Kells.

Fig. 404.

Fig. 403 represents the cast of an upper arch in which the cuspid is missing on the right side, and the space for its eruption entirely closed up. The radiograph of this case, Fig. 404, also by Dr. Kells, represents the cuspid in an unerupted stage slightly lingual to its position, and the indications for its eruption into position by opening up the space for it between the lateral and first bicuspid, are very favorable.

V. DYNAMICS AND ANCHORAGE.

Force and Resistance.—The relations of force and resistance in the application of mechanical apparatus for the correction of malocclusion, and development of the dental arches, represent the basic factors which, in the attainment of desired results in treatment in orthodontia, must be considered together in order that a proper utilization and conservation of both may at all times be correctly proportioned in respect to their requirements in any given case.

In the consideration of these factors, it must be remembered that applied force is active, and to a degree directly opposed to the other factor, resistance, which is passive or latent energy, incapable of being measured, except by the corresponding degree of active energy necessary to overcome it in the applied force.

Resistance, although latent, is nevertheless energy, and the degree of one's success in the restoration of harmony in occlusion and facial

lines is to a great extent dependable upon the intelligent use of this inert energy, which should always be accurately proportioned to the dynamical requirements of the necessary tooth movements.

In regard to the mechanical requirements of anchorage, the limitations in the quality and quantity of the applied force, because of the danger of injuring the living tissues involved, present a striking contrast to the application of similar forces in the field of general mechanics where resistance may be accurately measured and scientifically adjusted so that its stability in relation to any dynamical requirements may always be positively known.

In the field of applied mechanics in the arts, a force acting against an unstable resistance is not considered within the limits of practicability, but in the application of dynamics to living dental and alveolar tissues, the mechanical problems in the development of the dental arches and correction of malocclusion are not infrequently solved by the operation of a force acting from a more or less unstable base.

It oftens happens that the resistance to tooth movement may be located in a single anchor tooth, which is antagonizing the delivery of a force in another part of the arch, and is itself being moved at the same time in a direction in line with, or at opposing angles to the direction of the applied force.

In other respects, appliances which are used for the development of the dental arches and the correction of malocclusion, conform to the same laws as other machines used for the transformation of energy.

Force Producing Appliances.—The force required for tooth movement which has been found most adaptable to the unfavorable conditions in the mouth, is embodied in the principles of the spring, the screw, the lever, the elasticity of rubber, and the contraction of silk when moistened.

One entire system of correcting malpositions of the teeth is based upon the elasticity of the spring in a removable appliance to the exclusion of all other means of producing force, but lacking the advantage of absolute fixation, is not equal to the expansion arch in point of efficiency, although possessing decided mechanical advantage where its use is indicated, in those cases where a greater potential is required than is obtainable with the expansion arch.

The principle of elasticity in the stretching and contraction of the rubber band or ligature is also made use of as an important primary and auxiliary force, especially in connection with the expansion arch.

The expansion arch embodies the principles of the spring and a double jackscrew in one mechanism with all of the mechanical advant-

ages of both, and when properly adjusted, with its possibilities of fixation of anchor clamp bands, offers a combination of essential features in an appliance which is not possessed by any other force producing mechanisms in orthodontia.

Dynamics of the Expansion Arch.—A close observation of the expansion arch in operation and a knowledge of the tooth movements performed by its action as a spring alone, will prove its distribution of force to be similar to that of any spring placed on a tension under the same mechanical restrictions outside the mouth.

For example, in Fig. 405, the arch BNE represents an expansion arch at the limit of its lateral spring, which has been adjusted for the expansion of an arch of teeth. The arch JHI represents the same arch

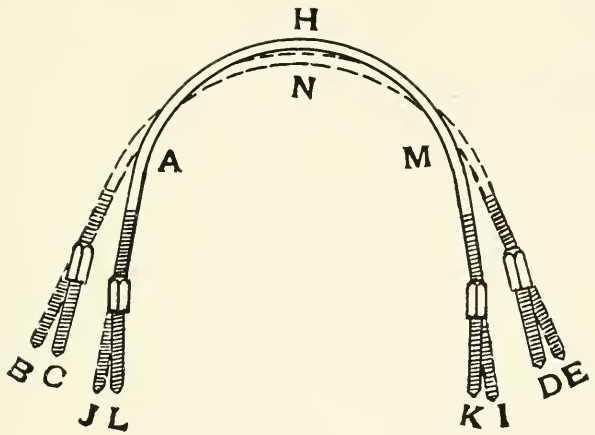

Fig. 405.

after it has been placed in the anchor tubes on molar clamp bands in the mouth, and it will be noticed that the center of the bow of the arch has bent outward, forming a shorter arc of a circle than before.

The action of any spring being to return to its original shape, the arch JHI will in time return to the shape BNE, the effect upon the teeth being to force the anterior teeth backward, through the pressure of the expansion arch in this region. At the same time, the lateral spring of the arch is expanding in the molar and bicuspid region, and it will be seen from the drawing that the expansion at A and M in the region of the first bicuspids is almost zero, while at B and E, the extreme of arch expansion has taken place.

The anchor tubes on the molar clamp bands being usually aligned about parallel with the buccal cusps, the distal angle of the molar would

travel a greater distance buccally than the mesial corner, or, in other words, the molar would be rotated in any case where much expansion had taken place. To obviate this, it has been suggested by Dr. J. L. Young that the ends of the expansion arch be bent lingually from a point directly in front of the nuts on the arch, so that the arch will have the appearance of LHK when in position, and in lateral movement will tend to counteract the tendency to rotate the molar, for while the ends of the arch do not travel in parallel lines buccally, the variation from the parallel lines is very slight as seen in the arch CND which represents the arch LHK in the extreme limit of expansion.

Dynamics of the Traction Screw.—The force embodied in the traction screw is limited to the positive action of the principle through the turning up of a nut against the end of a tube which is securely fastened to the base of anchorage, the right angled end engaging with a short tube attached to a band at the point of delivery of the force.



FIG. 406.

By simply changing the position of the nut from one end of the long tube to the other, the direction of the force exerted may be reversed, *i.e.*, it may be made to exert a pulling or a pushing force from its base of anchorage.

The form of traction screw illustrated in Fig. 406 is the design of Dr. Angle, its especial feature of value being that the point of delivery of the force may be always on a pivot through the engagement of the right angled end of the traction screw with a tube soldered to the band transversely to the axial diameter of the tooth which is to be moved.

Its principal use is as an auxiliary to the expansion arch in securing certain individual tooth movements which cannot be so directly and accurately accomplished with the arch alone.

Detailed descriptions of its use are illustrated in the chapter on treatment.

Mechanical Advantage.—The dynamical features presenting in the correction of malocclusion, require that only that appliance should be used which shall possess the greatest mechanical advantage in its application, and consequently, conserving all of the energy possible, both of force and resistance.

In the conformation of appliances to the principle of the conservation of energy, we must recognize the primary axiom, "the work done by the effort must equal the work done in overcoming the resistance," and that the test of the efficiency of any appliance is the nearest approach to the securing of resistance and application of force which

shall be the most useful and the least wasteful of the energy which is being used.

"If a machine could be made which wasted no energy, the resistance being all useful, and not wasteful, the machine would be perfect, and its efficiency would be unity."

Theoretically, we can imagine an appliance for moving teeth, having every mechanical advantage, sufficient resistance in anchor teeth, sufficient and controllable potential, and direct application of its force, with no loss of energy at any point, but in practice we are confronted with such obstacles as friction, insufficient and unstable resistance, indirect application of force, etc.

The efficiency of any appliance, therefore, can be expressed in a proper fraction, or a percentage of the total amount of energy put into it.

Simplicity of construction and operation is a prime factor in the determination of the efficiency of an appliance, since the least number of working parts reduces the amount of friction and other wasteful energy.

The stability or fixation of the basal attachments of an appliance, the material of which they are constructed, the size and temper of wires and ligatures, and the amount of power capable of being produced, are likewise essential factors in the efficiency of any force producing mechanism used in orthodontia.

It is obvious that an appliance should not only have the most stable attachments, sufficient resistance to the applied force, which is most direct in its application, but also that the force itself should be great enough and under such control that the time, rate, or power of accomplishment of certain desired tooth movements may be somewhat accurately gauged.

Resistance Values in Anchorage.—The first study of resistance values in anchorage should naturally be that of the teeth, individually and collectively in occlusion.

The integrity of the arches of teeth in occlusion exhibits such equilibrium of force and resistance in its maintainment through the anatomical construction and the order and economy of arrangement, that perfection of contour and stability of structure are assured.

The interdigitation of the cusps of the teeth, the length of the overbite, the proximate contact, the forms and sizes of the teeth, all conform to the requirements of function and structure so uniquely, that in the performance of their natural function of mastication, the anatomical structure is conserved or maintained in its integrity.

Likewise in the study of resistance values is to be considered the relative thickness of the alveolar process of the arches of teeth, and the lesser resistance to mesial than to distal movement of both upper and lower teeth; as well also, the age at which correction of malocclusion is begun, and the lesser density of the alveolar process in the earlier years of childhood affording the best opportunity for treatment, since the cartilaginous structure of the alveolar process, together with the lesser number of permanent teeth, if any, present, offers the minimum amount of resistance to tooth movement.

Anchorage *is the resistance selected as a base from which force is to be delivered for the movement of teeth.*

This resistance may be obtained from the teeth singly, or in multiple, or from the top and back of the head by means of the headgear, and except in reciprocation of anchorage, should always be greater than the force to be delivered from it in the movement of teeth.

The laws of action and reaction govern the application of force appliances to the teeth, and a failure to observe their requirements in the securing of sufficient anchorage for any tooth movements, will certainly result in the failure of production of the desired results, as well as dangerous tipping and displacement of the anchor teeth in some cases.

Efficiency of Appliances.—The efficiency of any appliance depends upon, first, sufficient anchorage; second, the direct application of force in the direction of the desired movement; third, the skillful manipulation of the appliance so that the least resistance will always be offered to the applied force, thus conserving the anchorage; e. g. in the restoration of inlocked laterals to occlusion, a proper conservation of anchorage would require that the space for the laterals in the arch be first obtained before attempting their movement into line.

The cast on the left of Figure 407 illustrates a case of this character before treatment. If the laterals were ligated to the arch together with the centrals and cuspids at the beginning of treatment, the resistance to forward movement of all of these teeth would be greater than that of the molars to distal movement, and the anchorage would soon be weakened to such an extent that the case could not be completed without resting the anchor teeth for some time. The cast on the right of this figure illustrates the manipulation of the expansion arch so as to offer the least resistance during the entire treatment of the case, the centrals being ligated first, the cuspids and the bicuspids next, and when sufficient space has been made for the laterals, they, too, are ligated and drawn into alignment.

The stability of teeth used for the anchorage appliance varies with their power of resistance, which is determined by their size and location, the length and number of their roots, and the direction and manner of application of the required force, as well as the period of development of teeth and process.

From the size and number of their roots and advantageous location in the posterior part of the arch, the molars are most commonly selected as anchor teeth.

Comparative Measures of Resistance.—Anchorage is largely a question of comparative measures of resistance, each individual tooth having a certain resistance value, which varies with its normal or

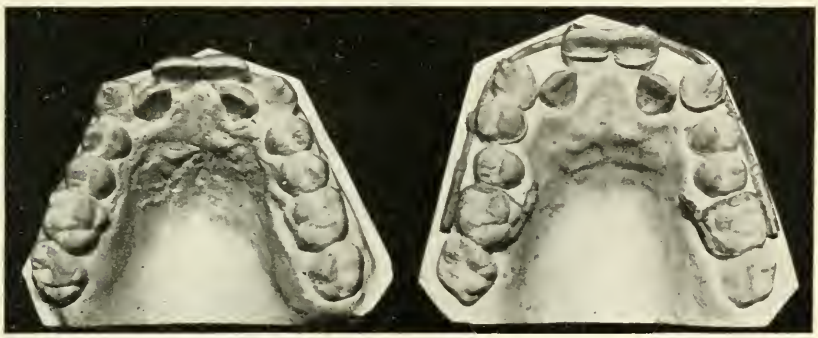

FIG. 407.

malocclusion, and whether it has teeth adjacent to it or not. By first moving the teeth adjacent to the inlocked lateral in Fig. 407, the greatest resistance to their movement is removed.

Simple anchorage *is the obtaining of a sufficient resistance in one part of the arch for tooth movement in another part of the same arch, the anchorage resistance being relatively greater than that of the teeth to be moved, although admitting of some instability of the anchor teeth.*

Re-enforced anchorage *is the adding of the resistance of teeth in the same arch or opposite arch, through the use of other forms of anchorage, as auxiliaries, in combination with the already established simple anchorage.*

Reciprocal anchorage *represents the counterbalancing of anchorage resistance between teeth located in different parts of the same arch, or in opposite arches, to the mutual advantage of tooth movements.*

A combination of several of the various forms of anchorage which may be secured in the same arch is exhibited in Fig. 408.

Simple anchorage would be here represented by the first molars

in their opposition to the movement of the three incisors, B, B, B, which are ligated to the arch, the measure of the resistance of the latter teeth being comparatively less than that of the first molars to distal movement.

If the forward movement of the cuspid were attempted without re-enforcement of the anchorage, as in the ligation of the second bicuspids to the molars at D, undue tipping of the first molars might follow with the loss of simple anchorage.

In lateral expansion of the arch, without much forward movement of the incisors and cuspids, the simple primary anchorage of the first molars is usually sufficient, and also in many cases of forward movement of the six anterior teeth, if the second molars are present to add their resistance to the first molars to distal movement.

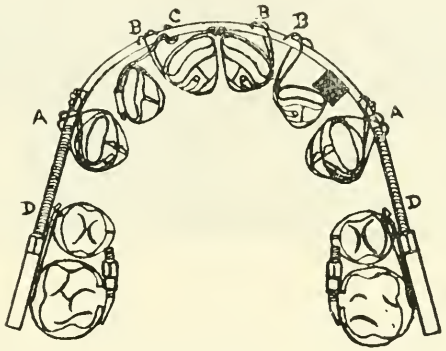

Fig. 408.

Reciprocal anchorage in connection with the expansion arch, is a secondary anchorage, and is represented in Fig. 408, A, A, B, B, B and C.

The resistance of the right cuspid to buccal movement through its ligation to the arch is opposed and counterbalanced by a similar attachment of the left cuspid to the arch at A, and neither affecting to any degree, the primary first molar anchorage, since their lines of resistance are at right angles to the established line of resistance.

The expansion arch being a reciprocating spring, attachments to the arch as at B in the rotation of a lateral can be made to perform tooth movement through this reciprocating tendency, especially when aided by the rubber wedge.

The two centrals ligated together, are reciprocating in their resistance to mesial movement, and at the same time reciprocating force, from the ligation to the arch as B, B, is rotating them in their sockets.

The lever also, at C, exerts a reciprocal force in the rotation of the right lateral incisor.

The banding and ligation of the second bicuspid to the first molar anchorage serves as a sufficient re-enforcement of this anchorage, for the tooth movements to be made.

Without considering in this connection the advisability of the extraction of the first bicuspid, and retraction of the cuspid into its space in a case of Class II, Div. 11, Subdivision (Angle), it may be well to illustrate, in Fig. 409, a form of anchorage devised by Dr. Angle, the application of the traction screw and expansion arch in efficient combination for the successful attainment of the result desired of harmonizing the

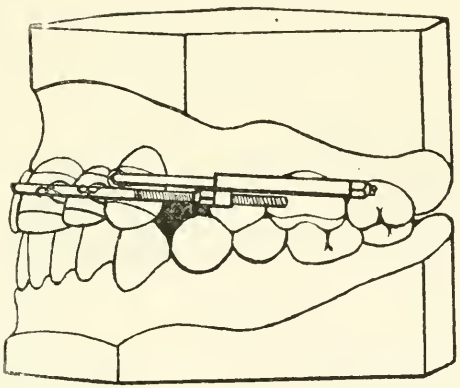

FIG. 409.

size of the arches without shifting the occlusion in the molar region, an operation which is unnecessary from the standpoint of perfect occlusal restoration, yet is here illustrated for the purpose of exhibiting the reciprocation of force from one appliance to the other in the attainment of the result.

It will be observed that the long sheath of the traction screw is attached directly to the molar clamp band, and the short tube on the cuspid band, which engages the right angled end of the traction screw is attached at one corner only, at right angles to the direction of the desired movement.

The expansion arch is supported by a short tube soldered to the under side of the forward end of the sheath of the traction screw on this side, the other end being supported by the usual tube on the molar clamp band.

The reciprocating of the force acting to rotate the incisors through the forward movement of the expansion arch, to the distal movement

of the traction screw in drawing the cuspid backward, is the feature of especial value.

The Case Reciprocating Arches.—One of the most ingenious examples of a reciprocal and a re-inforced anchorage is embodied in the principle of an appliance in Fig. 410, devised by Dr. C. S. Case.

It consists of two buccal arches, supported by tubes soldered to each other at slightly diverging angles, the inner one united to a molar band and supporting a threaded arch of about 19 gauge, which is attached to the incisal ends of vertical bands upon the incisor teeth, the outer tube supporting an ordinary expansion arch, which is somewhat flattened as it engages with hooks at the gingival end of the same vertical bars upon the incisor bands.

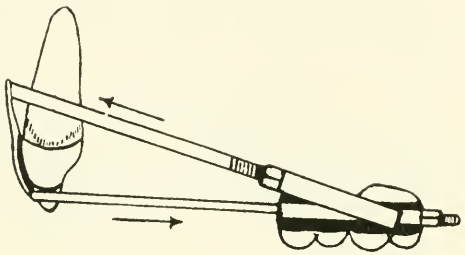

Fig. 410.

Turning up the nuts in front of the tube supporting the upper arch, the roots of the incisors are pushed forward and the crowns inhibited in movement or retruded slightly as desired by control of the nuts behind the anchor tubes supporting the lower arch. The resulting effect of these opposite acting forces is to produce an equilibrium of forces in the region of the molar anchorage, and this unique application of the arches can be classed under reciprocal anchorage when the force and resistance are equally balanced. The necessity of the use of this appliance also, has greatly diminished since the utilization of other simpler forms of anchorage in the shifting of the occlusion of the teeth, mesially or distally, has come to be more generally understood.

Stationary anchorage *represents an anchorage which is stable and unvarying in its resistance for tooth movement.*

Although stationary anchorage in the absolute, is probably never secured in the mouth, yet in the use of the expansion arch for movements of one or two incisor teeth, in which the primary anchorage is re-enforced, there is no doubt that stationary anchorage is secured, at least to all practical purposes.

First Molar Anchorage.—The first molar is so often chosen as an anchor tooth for the basal attachment of appliances in the correction of malocclusion, because of certain anatomical and mechanical features that enter into the selection of an efficient anchor tooth.

At six or seven years of age, the first permanent molar is usually in position, and, as its name implies, is the only permanent molar ready to be used as an anchor tooth.

If the relations of these teeth are incorrect with their mates in the opposite arch, it is to them that attention has to be first directed and their relative positions corrected and retained until occlusion of enough of the permanent teeth has been established to secure the normal relationship of the arches as a whole.

Again, later in life, when the second molars have erupted, the use

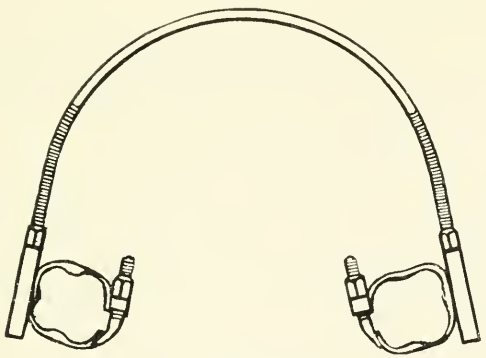

Fig. 411.

of the first permanent molar as an anchor tooth receives an efficient re-enforcement to its resistance to tooth movement anteriorly, from the fact of its being supported by the second molar and the strong alveolar process surrounding it.

The roots of the first molar are also more diverging than those of the second, so that the first molar has a greater comparative resistance value than the second molar because of the greater force required to displace it.

The eruption of the third molar adds still greater resisting power in movement of teeth anteriorly to the first molar as an anchor tooth.

In the use of "fixed" appliances for the correction of malocclusion, an expansion arch, supported by clamp bands, upon molar or bicuspid teeth forms the usual basal attachment in each arch of teeth for the obtaining of sufficient resistance for the tooth movements in that arch.

Primary Anchorage.—This attachment to single molar or bicuspid

teeth, on each side of the arch, may be designated as *primary anchorage* (Fig. 411).

Secondary Anchorage.—Should it be desired to add the resistance of other teeth in the same arch, or in the opposite arch, or the resistance from the teeth of the opposite arch, the additional anchorage obtained would be designated as *secondary anchorage*, and would include any of the other forms of anchorage.

It will be seen that in the use of the expansion arch, the control of all the units of resistance of individual teeth within the arch is obtained, and usually by the simple attachment of ligatures around the teeth and over the arch.

Often the arch is ligated to the incisors firmly, simply as a secondary anchorage, or support for the arch, during the movement of cuspids or bicuspids to alignment.

It is necessary in many cases, to secure the resistance of the arch as a whole, to oppose tooth movement in the opposite arch, when the resistance of every tooth in the arch may be obtained by proper ligation.

Mention has already been made of the use of ligatures in connection with the expansion arch for the purpose of securing the added resistance of individual teeth to the primary established anchorage, and the attachment of ligatures for adding resistance, or for tooth movement, varies but little, if any.

In order to secure the direct application of force in the direction of the desired movement, a knowledge of the relative position of a tooth to the "line of occlusion," will, by indication of its malposition, whether in labial, lingual, mesial, distal, infra-, supra-, or torso- malocclusion, enable one to determine the exact direction in which the force should be applied.

This being determined, the application of the force from the expansion arch is obtained by the firmest attachment of the ligature to the tooth that is essential.

If there should be any possibility of slipping, or if rotation is necessary, the use of the Magill band with lugs, is a necessity, as a continued slipping off of ligatures will delay the completion of a case for months.

Intermaxillary anchorage *is the opposing of the resistance of the teeth in one arch against that of the other, partially or completely, to the advantage of tooth movement in the arch in which the lesser resistance is established.*

This is secured by the attachment of rubber elastics from one arch to the other, exerting a force termed **intermaxillary force.**

Fig. 412 illustrates the application of the intermaxillary elastics to the Angle expansion arches and clamp bands, for shifting the occlusion in Classes II and III, being attached in Class II from hooks upon the upper expansion arch to the distal end of tube on lower molar clamp band, and in Class III from hooks upon the lower expansion arch to the distal end of tubes on upper molar clamp bands.

The use of intermaxillary anchorage is called for in all classes of malocclusion, either for the direct application of intermaxillary force or for purposes of auxiliary resistance, and will be further described under treatment.

Uses of Intermaxillary Anchorage.—Briefly stated, the various methods of application of intermaxillary anchorage are as follows:

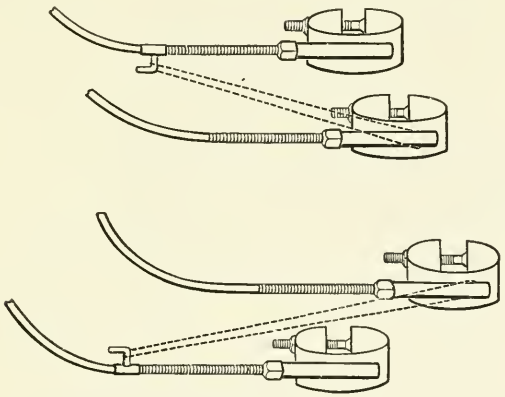

Fig. 412.

The use of either arch of teeth, en phalanx, as anchorage for the attachment of the rubber ligature to effect the movement of one or more teeth in the opposite arch.

The upper arch used (en phalanx) as resistance for the consecutive mesial movement of the lower incisors, cuspids, bicuspids, and molars.

The lower arch used (en phalanx) as resistance for the consecutive mesial movement of the upper incisors, cuspids, bicuspids and molars.

The use of either arch of teeth in whole or part as anchorage for a simultaneous mesial movement of teeth in one arch and a distal movement of teeth in the other.

The use of the intermaxillary anchorage to sustain, or as an auxiliary to other established methods of anchorage.

The elevation of teeth in either arch.

The use of intermaxillary anchorage between single teeth of oppo-

site arches, in opposing their resistance to mutual advantage in mesial or distal, and buccal or lingual movement.

The reciprocation of the movement of teeth in the use of intermaxillary anchorage, is not claimed, although it may and does occur under proper conditions, as when the anchorage resistance in one arch exactly balances that of the other.

It is necessary to distinguish between intermaxillary anchorage and intermaxillary force, the former referring to the opposing of resistance of teeth of maxilla and mandible, the latter to the force, which in the use of the rubber elastic, must be equally exerted on teeth of both arches.

Intermaxillary force is always reciprocal; intermaxillary anchorage may be reciprocal or not, *i. e.*, the resistance in one arch may be equal to that of the other, or it may be greater or less.

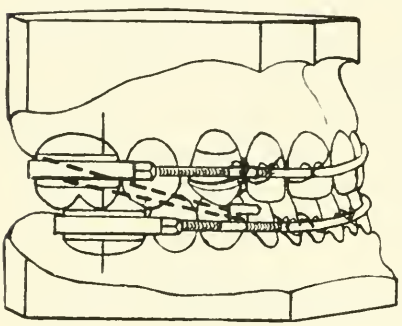

Fig. 413.

Intermaxillary anchorage is a valuable adjunct in Class I, in which it is not desirable to change the molar occlusion. An example of its use in a case of this class is seen in Fig. 413, the expansion arch on the upper arch of teeth being adjusted so as to regain the space for a second bicuspid, the resistance to a forward movement of the anterior teeth falling entirely on the first permanent molar, which is prevented from distal movement by an intermaxillary force acting in the opposite direction through the attachment of the intermaxillary elastic to a hook in the region of the cuspid on lower expansion arch.

It will be observed that the resultant of these two opposite forces can be made to be zero—by a proper gauging of the strength of the elastic—thus preserving the stability of the first molar, as is desired.

Occipital anchorage *is the resistance obtained through the use of the top and back of the head in connection with the headgear for assisting tooth movement or maxillary and mandibular movements not obtained by other forms of anchorage.*

This valuable form of anchorage has dropped somewhat into disuse, because of the splendid results which are now obtainable by the use of the intermaxillary anchorage.

The chief use of this method of anchorage was formerly in connection with the treatment of Class II and III cases, in which the anchor-

age within the mouth was not sufficient to meet the requirements of the case.

Fig. 414 shows the Angle headgear and traction bar in position for the application of occipital anchorage, the socket of the traction bar engaging with the ball soldered on the front of the expansion arch.

Occipital anchorage is seldom indicated except in unusually refractory cases of Class II or III, in which it is an efficient auxiliary.

Summary of Anchorage Principles.—In summing up our remarks on the subject of anchorage, we are led to the following conclusions:

Fig. 414.

First, that the primary principles of force and resistance in action and reaction apply equally well in the attachment of the applicances for orthodontia as in other machines.

Second, the subject of anchorage resolves itself into that of comparative measures of resistance, always, however, with the securing of a greater resistance at the base of attachment of an appliance than that to be overcome at the point of delivery of the force.

Third, that the applied force shall be sufficient for the required tooth movements, and under perfect control.

Fourth, that the force be applied in the most direct manner for tooth movement, but not so rapidly as to endanger its own basal attachments,

or cause undue strain on the teeth and consequent pain, or loss of the anchorage.

Fifth, that the force producing appliance be simple and yet correct in principle for the restoration of normal occlusion.

Sixth, that the addition of re-enforced anchorage of any kind is advisable where the primary anchorage is not sufficient for the desired tooth movements.

Seventh, that advantage should be taken of reciprocal anchorage whenever possible, either in the same arch, or opposing arches, for sustaining the stability and integrity of the primary anchorage, as well as increasing the efficiency of the appliance.

Eighth, in the use of intermaxillary anchorage, especially in connection with the primary established anchorage in both arches, the greatest attainment in the scientific application of anchorage is achieved, and the most difficult results obtained in the treatment of malocclusion.

Ninth, that the appliances must be kept up to their highest standard of efficiency at all times during the progress of treatment in order to conserve anchorage and the length of time for operation.

VI. OPERATIVE TECHNIQUE.

Qualifications of Appliances.—The chief qualification that an appliance should possess is that of efficiency, the virtue of simplicity of construction naturally being included, since it is the *sine qua non* of all machines which have proven of any value in the scientific world.

The efficiency of an appliance for the correction of malocclusion consists of the fewness and proper proportion of adaptable parts, capable of appropriating sufficient and varied forms of anchorage, and having within its compass the positive control of all of the teeth of one dental arch, conserving time and energy through the proper adjustment of each part so as to secure a perfect working mechanism, capable of transmitting force as rapidly and in such quantity as is consistent with physiological maintenance in operations on vital structures.

Simplicity in appliance construction and efficiency in operation has evolved the modern expansion arch, which, examined very carefully with its anchor bands, Fig. 415, will be found to possess certain characteristics which stamp it as the most superior of all appliances for the complex requirements in orthodontia. Chief among these qualities are its universality of application and efficiency of mechanism.

Its principal mechanical features are its possession of the principles of the spring and the screw, the center of the spring being in the center of the bow of the arch, which, from end to end, presents the

appearance of a double jack-screw, with all the advantages of the fine gradations, yet strong and efficient force of the screw principle.

When anchored in position upon molar clamp bands upon the teeth, it can be used as a reciprocating spring for the balancing of force and resistance from one side of the arch to the other, for lateral and anterior expansion, and for the rotation and elevation of teeth within its compass, and as a base of anchorage for tooth movement in the opposite arch.

Whether constructed of gold or German silver, the expansion arch should be possessed of a very hard temper, so as to be capable of the greatest possible amount of spring for expansion purposes, and should be furnished in sizes according to the size of the dental arches, and degrees of resistance to be encountered.

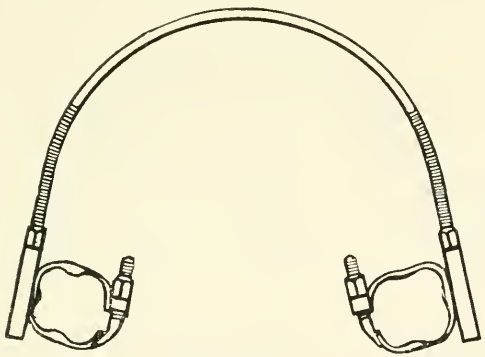

Fig. 415.

The author prefers three different gauges, 16, 17, and 18 Brown and Sharpe gauge, the smaller sizes being especially adapted for treatment of malocclusion in the small mouths in which the deciduous teeth are predominant in number, and the larger size for the adult arch, in which greater strength is required.

Adaptation of the Arch.—While possessing a very hard temper, the expansion arch is capable of being bent to any form which is most adaptable to the case in hand, care being taken to make the bends with the round nosed portion of the arch and ligature pliers (Fig. 431) so as to avoid breaking the wire.

The general form the arch should assume for any case should be determined somewhat by the normal arch as pre-determined by the method illustrated in the chapter on diagnosis. However, in many cases, the arch in this form would be so large that it would extend too far outward from the labial and buccal surfaces of the teeth for

comfort, and the ligatures would have a tendency to slip off from the teeth because of their unusual length, so that the anterior arc will have to be made a little shorter at first and later on changed as it is found that the increased expansion of the arch will allow of enlarging the arc to the size of the pre-determined arch.

Often it will be necessary to bend the arch wire in and around a certain tooth which is so far in labial or buccal occlusion that it interferes with the adaptation of the expansion arch to the rest of the teeth to too great an extent for comfort or practicability.

These bends may be gradually worked out as the case progresses, and the arch is restored to normal size and shape.

The tendency of the amateur is to give the expansion arch too much lateral spring when first applied, and to force the incisors and cuspids forward by turning up the nuts in front of the anchor tubes,

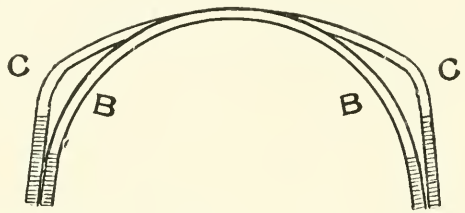

Fig. 416.

too frequently, instead of performing sufficient lateral expansion, both anteriorly and posteriorly.

It is advisable in any case, to adjust the expansion arch to its position for a few days without any lateral spring in it, so as to allow the patient to become used to the bulk alone at first, and afterward, increase the lateral spring to suit the case.

In the expansion of the anterior portion of the arch only, it is necessary to have but little lateral spring in the expansion arch, and it should conform to the labial surfaces of the incisors and cuspids, as would be secured in the short arc BB, Fig. 416, for cases of slight expansion or the movement of one or two incisors into normal positions, but in severe cases, and in those in which considerable lateral development is desired, the bow of the expansion arch should be bent with the arch and ligature pliers so as to form a longer arc, CC, the ends of the arch slipping into the anchor tubes with the lateral tension gauged according to the amount of posterior expansion indicated by diagrammatic measurements.

Whenever it is necessary to provide for considerable anterior

expansion, such as in a case in which the cuspids are in labial occlusion, it will always be found necessary to expand posteriorly as well, and in fact the Hawley diagrams of the pre-determined arch indicate anterior and posterior expansion in the majority of cases, and the arch should be bent so that it will have sufficient lateral spring to meet the requirements of the case, remembering that the difference in resisting power of the teeth and alveolar process is varied according to the age and number of permanent teeth present. The adult arch will resist an expansive force which would be impossible to use in the case of an arch in which the deciduous teeth were not all shed.

The author has found it advantageous and conservative of anchorage to perform anterior expansion in advance of very much posterior expansion in many cases, since the resistance power of the molar anchorage is only opposed in one direction through the turning up of the nuts in front of the anchor tubes, while in performing anterior and posterior expansion simultaneously, the resistance power of the molar anchorage is being opposed in a lateral as well as a distal direction, tending to make it more unstable than by the other method.

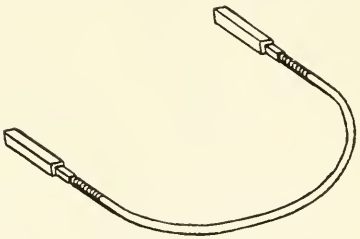

FIG. 417.

Bodily Control of Anchor Teeth.—The round buccal tube on molar clamp bands which receives the round end of the expansion arch allows of a bucco-lingual tipping of the anchor teeth which is not especially desirable in many cases.

One of the best methods of obviating this difficulty is the use of the square hole buccal tube, and square ended expansion arch illustrated in Fig. 417, as designed by Dr. F. C. Kemple.

Their adjustment is a matter of some little care as to the detail in order to secure an accurately fitting and efficient appliance.

The square hole tubes are first soldered upon the buccal surface of the molar clamp bands, according to the alignment of the plain expansion arch which is slid into the square orifices for this purpose. The surplus length of the expansion arch extending beyond the distal end of the tubes is then cut off, and its ends filed square to fit a smaller square holed tube which perfectly fits the larger buccal tube on the clamp band. These smaller tubes are about one-eighth of an inch long, and should be soldered upon the filed ends of the expansion arch one at a time, being careful to preserve the proper relations with the

larger buccal tubes by such adjustment of each of the smaller tubes upon the ends of the expansion arch as will preserve its proper alignment and allow it to slide easily to position.

The arch may be manipulated by turning up the nuts in front of the anchor tubes, or as any expansion arch adjusted with the round tubes on the molar clamp bands.

Any lateral spring in the expansion arch will be exerted upon the anchor teeth in such a manner as to move them bodily through the process.

The application of the square hole tube upon one side of the dental arch, and the round hole tube upon the other, is often of advantage in securing stationary anchorage upon the lateral half upon which the square hole tube and square end of the expansion arch is used.

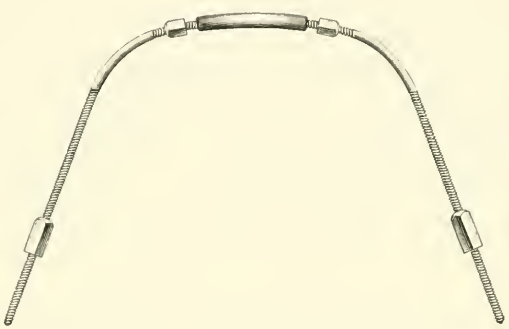

FIG. 418.

The Divided Expansion Arch.—In order to obviate the removal of the plain expansion arch at intervals to rebend the anterior portion into a larger arc to meet the requirements of increased expansion the author has been using the divided expansion arch illustrated in Fig. 418, especially in extreme cases of expansion, to a decided advantage over the plain arch.

The principle is not entirely new, except in its application to the outside of the dental arch, for the purpose of anterior expansion, The author is indebted to Dr. L. P. Bethel for valuable suggestions and assistance in the application of the divided arch principle.

This arch has the power of four jack screws and at the same time retains the elasticity and power of the reciprocal spring as exhibited in the plain arch if it is properly made. It also can be made to exert force in the directions indicated by the arrows in the illustration, Fig. 419.

The divided ends of the arch fit snugly into the central tube, so

that the lateral spring of the two halves is as great as in the undivided arch. It is adjusted the same as the plain arch, and can be used in Class II or III, where considerable expansion and a mesial or distal change in the occlusion is needed at the same time.

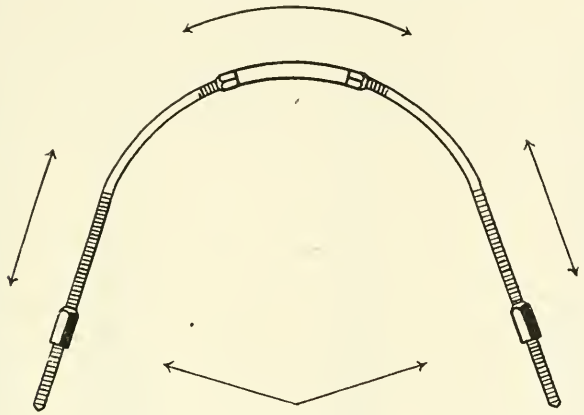

Fig. 419.

With this divided arch the operation of expansion is performed in one-third of the time that the same work is done with the plain expansion arch.

Another form in which the divided arch may be constructed is shown in Fig. 420, a long central nut, being right and left threaded from

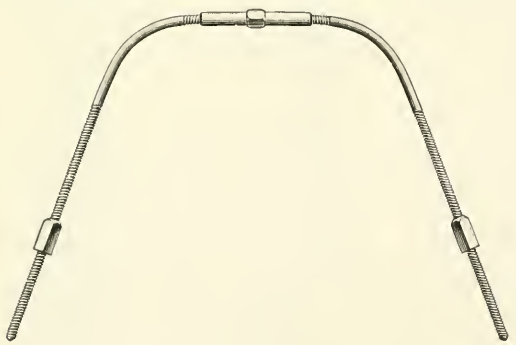

Fig. 420.

each end to the center, operates upon each lateral half of the arch, which are threaded to correspond. This arch has the power of six jack screws, having the power of contracting by reversing the direction of the nut from that which is necessary in expansion.

Being composed of fewer pieces, this arch is a little simpler, al-

though not being so perfectly adaptable to a rounded arch on account of the long straight nut in the center.

Adjustment of Anchor Clamp Bands.—In the adjustment of the anchor clamp bands to molar or bicuspid teeth, the lingual nut should first be loosened, and the circumference of the band made to correspond somewhat to that of the tooth it is to placed upon, bending the lower edge to the tooth form, after which it is slipped over the crown of the tooth with the fingers, the lingual screw pointing mesially, and gently but uniformly pressed between the adjoining teeth on each side. Usually, the bands can be forced into place with the thumbs, pressing it downward uniformly mesially and distally, but occasionally it will be necessary to apply a stronger pressure on each mesial and distal upper edge of the band with a flat bone spatula and with the band driver working it downward alternately, lingually and buccally, over the swell of the crown.

FIG. 421.

When in position, the anchor clamp band should have the appearance of the band fitted to a molar tooth in Fig. 421, the lingual nut being screwed tightly down, with the end of the threaded wire close to the lingual surfaces and the upper edge of the band burnished into the buccal groove and against the inclines of the cusps. A very efficient form of burnisher, in right and left patterns, and heavy octagonal handles affording a very secure grip, and designed by Dr. Murless, is illustrated in Fig. 422. Anchor clamp bands should be cemented into place at the first sitting after its adjustment with expansion arch in correct position, so that it will easily slip into position, and not have to be removed for alignment of anchor tubes, etc.

If the bands are to be left on but two or three months, they may be set with chloro-percha or gutta-percha, which fills up the intervening space between band and tooth, and prevents any tendency to caries.

Wrenches.—As the wrench is the most commonly used instrument of the orthodontist, it should be so constructed that it will represent in material of construction, adaptation and finish, the most perfect of instruments. In the first place, it should be made of steel, which allows greater rigidity with less bulk than iron. The handle should be octagonal, giving a firm grip, and the whole instrument about $5\frac{1}{2}$ inches long.

The socket ought not to be deeper than the width of the nut, and should fit quite accurately. The arms of the socket should be circular in form tapering down upon the handle.

Fig. 423 represents the double ended oblique angled instrument.

Band Driver.—The band driver should primarily have a large handle which will afford a strong grip, and the tip should have a groove which will engage with the top edge of a band. Fig. 424 is a band

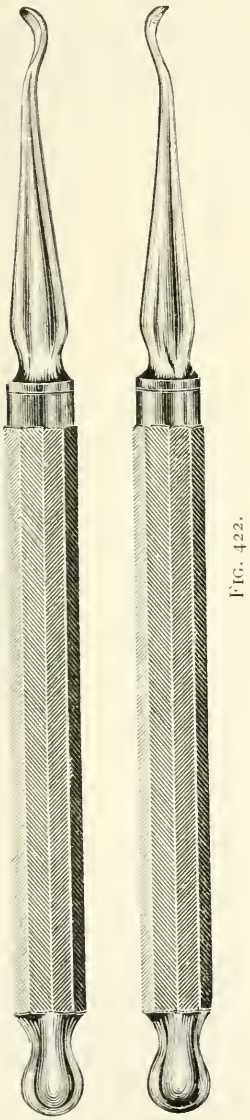

Fig. 422.

Fig. 423.

Fig. 424.

driver of this character, which may also be used for bending the ends of ligatures out of the way under the arch.

Bucco-lingual Alignment of the Anchor Tubes.—If the clamp band is one in which the buccal tube is soldered directly to the band,

care should be taken in adjusting the band so that the tubes will be aligned parallel to the buccal cusps of the molar, or if a bicuspid, parallel to the buccal surfaces of the bicuspids, so that the expansion arch may be easily slipped into the tubes without unequal tension at either mesial or distal end of the tube on either anchor clamp band.

Fig. 425 illustrates diagrammatically the relationship of the expansion arch to the tubes on anchor clamp bands, B and F, representing the positions of anchor tubes in which the ends of the expansion arch will slip easily and uniformly into them, and A and C, positions in which the tubes are so far from the parallel that the arch cannot be

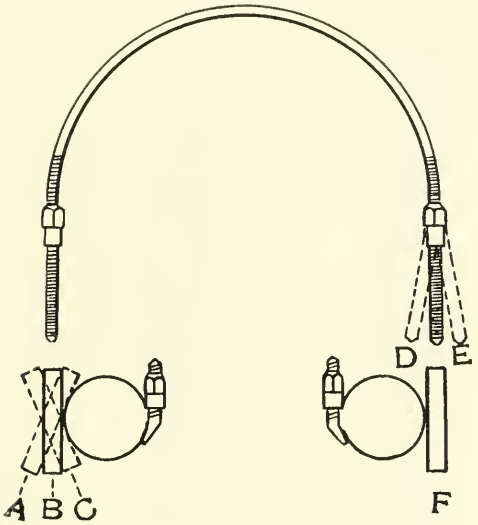

Fig. 425.

readily inserted, and which would be creative of unequal tension upon the molar to such a degree that rotation of this tooth would be inevitable, and the easy manipulation of the arch interfered with.

Where it is desired to rotate the molar on which the anchor clamp band is placed, the end of the expansion arch may be bent lingually from a point in front of the nut as in D, Fig. 425, and the expansion arch sprung into place, causing the mesial angle of the molar to turn buccally and the distal angle lingually as suggested by Dr. E. H. Angle. A buccal bend as at E will cause the tooth to rotate in the opposite direction.

Vertical Alignment of Expansion Arch.—Although the anchor tubes may be aligned so that they allow the arch to be readily slipped into them as just described, it will usually be found that the bow of

the arch is either too high or too low on the labial surface of the incisors, often as at AED, Fig. 426, the arch resting against the incisal edges. To establish a correct vertical alignment of the front of the arch without unsoldering the anchor tubes, if the upward or downward inclination of the arch is not too great, the mesial and distal edges of the band may be slightly raised or lowered so that the arch will rest against the labial surface of the incisors near the necks, and by burnishing the edges

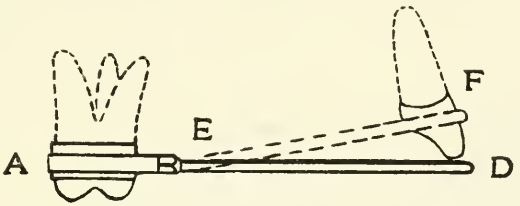

Fig. 426.

of the band tightly in these positions, and re-tightening the lingual nut, the security of the clamp band will not be endangered.

Another method that is of advantage in some cases is to bend the expansion arch in front of the nuts, as at E, Fig. 426, so the front of the arch will rest in its proper position, AEF, upon the labial surfaces of the incisors.

The author prefers to unsolder the anchor tubes in case of any great variation from the desired alignment, and realign them so that the arch and anchor tubes will be in the same plane when in proper

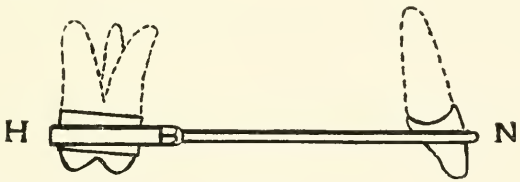

Fig. 427.

position, as at HN in Fig. 427, the force being delivered more directly, and the ligation of bicuspids to the arch being much more readily performed. The change of alignment by this method is very easily accomplished by the use of the soldering clamps as illustrated in Fig. 599 in the chapter on constructive technique.

The author prefers the anchor clamp band with the pivotal tube for many cases, as it allows of a change of inclination of the tube at any time before or during treatment, without unsoldering the tube or taking off the arch or clamp bands, the tube being attached by a short, round

piece of wire to the clamp band, and capable of being twisted with the pliers upward or downward to any position desired, as in Fig. 90.

The saving of time and the possibility of always keeping up the standard of efficiency in the arch through its being properly related to tooth surfaces is of great advantage in the use of this anchor clamp band.

Ligatures.—After the proper adjustment of the arch and molar bands upon the teeth, a study of the case should be made with regard to the most advantageous use of the wire ligatures, so that the most direct and positive force may be exerted upon the teeth which are to be moved, and a proper balancing of the lateral expansive force obtained so that reciprocation of force may be secured from one side of the arch to the other.

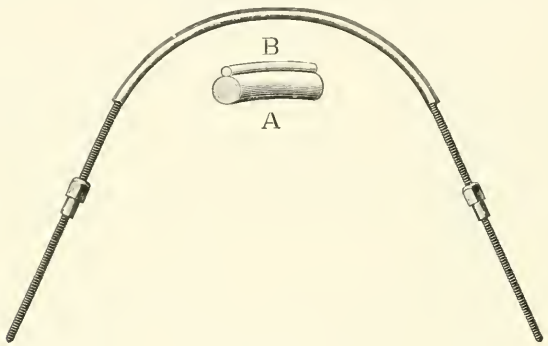

FIG. 428.

At the present time, five sizes of ligature wire are in use for this purpose, their respective diameters being .013, .014, .015, .017 and .018 of an inch.

For gentle traction force, the finest ligatures are most serviceable, especially in the movement of the deciduous teeth, and in the ligation of permanent teeth at the beginning of treatment when the proximation of the surfaces of the adjoining teeth render it difficult and sometimes impossible to use the heavier ligatures.

The heavier ligatures are suitable for accurate and efficient work in any position where they can be used, their efficiency increasing with their diameter.

The greatest usefulness of the ligature is obtained only when the expansion arch is slightly free from contact with the teeth to be ligated, so as to secure the fullest spring of the arch wire outward where general expansion is desired.

Spurs.—Again, the effectiveness of the ligature may depend upon

the fixedness and location of its attachment to the expansion arch, which may be accomplished by the raised spur upon the surface of the arch wire located in such a position as to cause the movement of the teeth in a certain desired direction.

In one style of the Angle expansion arch, the same purpose is accomplished by filing a notch in a re-enforced ridge which is on the buccal surface of the arch wire, this notch interfering in no way with the tensile strength of the wire since it does not penetrate its surface (see Fig. 428).

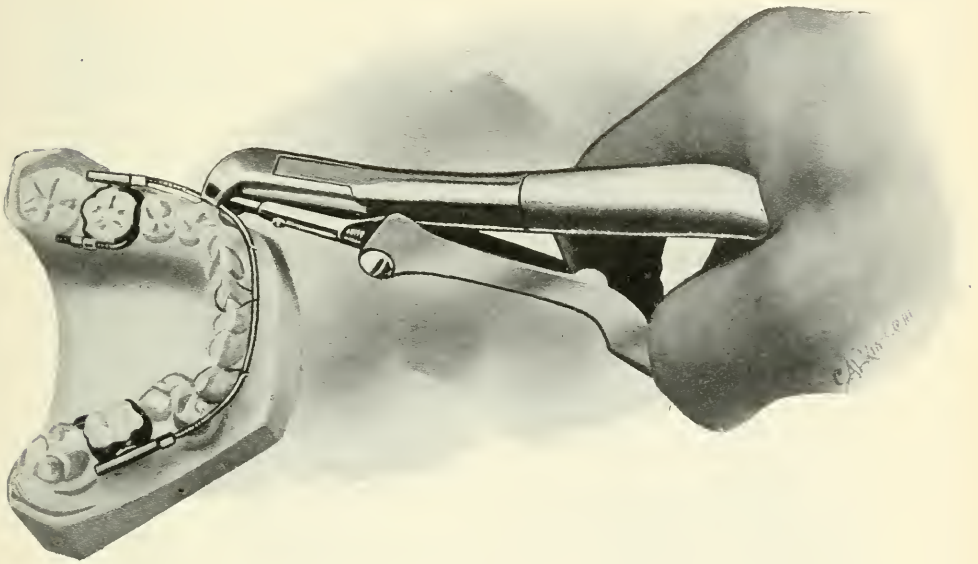

Fig. 429.

Spur Pliers.—Spurs may be easily and quickly made on the plain arch by means of the arch wire barber, or spur pliers shown in Fig. 429, an invention of Dr. L. S. Lourie.

This instrument, applied while the arch is in position, seizes the arch firmly between its two beaks, and by a slight pressure upon the lever at the side, at the same time, a small chisel is forced against the surface of the wire at an acute angle, raising a spur, which is hardly perceptible to the eye, but which is capable of holding the heaviest ligature from slipping.

When any particular barb or spur is no longer in use, it may be burnished down upon the surface of the arch wire, so as not to interfere with the lip or cheek. The spring of the arch is not in the least impaired by the spurs made in this manner.

When a longer and stronger spur is required, it may be made of a half cylindrical piece of band material previously fitted to the arch wire, and having soldered to its convex surface a piece of 21 gauge German silver wire, as illustrated in Fig. 596. The concavity of the band material should be polished with a sandpaper disk, touched with a drop of phosphoric acid, and a small portion of soft solder melted into it, after which it is united to the arch in the desired position and the end cut off to the length required, and finished with the disk so as to leave no rough surface to the cheek.

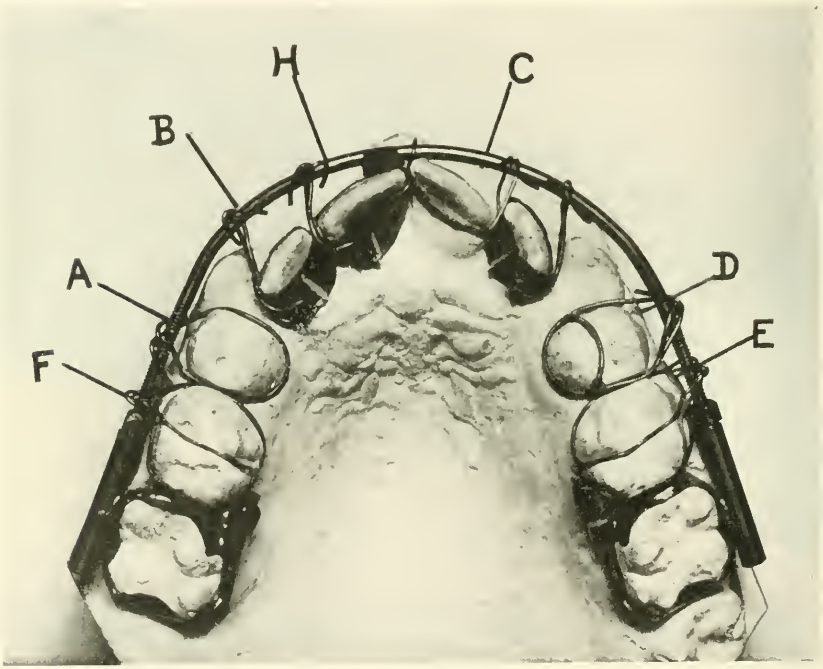

Fig. 430.

Variety of Ligatures.—The advantages to be gained by the use of a variety of styles of ligatures may be understood from a comparative study of the different methods of attachment to the arch according to the desirability of the attainment of such qualities as directness and positiveness of action, freedom from pain, and inconspicuousness of appliances through the use of the least number of bands upon incisors.

The most commonly used ligature is that illustrated at A upon the first bicuspid in Fig. 430, and is properly used in ligating teeth

which are to be moved in a straight line outward to the arch, without rotation.

When the direction of the tooth movement is forward and outward, especially if rotation is necessary at the same time, as in the case of the lateral incisor at B, Fig. 430, the band with lingual spur should be cemented upon the tooth, and the direction of the ligature guided by the location of a spur on the arch wire. As soon as the teeth which need rotation approach the arch sufficiently near, the rubber wedge should be placed between the arch and the nearest approaching labial angle of the tooth, as in the manner of rotating the central incisor at H in the same figure.

In favorable cases, the band need not be used, but the double loop ligature, shown at C, suggested by Dr. Angle, will be found serviceable in rotation.



Fig. 431.

In the ligation of bicuspids to the arch, the plain ligature often has a tendency to slip under the gum at the neck of the tooth, and not only cause pain but possible injury to the peridental membrane. To prevent this, the stirrup ligature, suggested by Dr. Lourie, and shown in position on the bicuspid at D, Fig. 430, is most efficient, the loop extending across the sulcus of the bicuspid and soft soldered to the plain ligature at the mesial and distal angles of the lingual surface of the tooth effectually preventing any movement of the ligature toward the gingiva.

A modified form of this ligature, known as the T ligature, has been devised by the author for the prevention of the slipping of ligatures upon the deciduous teeth, the necks of which are so constricted that plain ligatures invariably tend to slip beneath the gingiva, a class of cases in which the greatest care should be taken that there is no discomfort from this cause. The T ligature is seen at F and E, Fig. 430, and is constructed by soft soldering one piece of ligature wire at right angles to another, the one ligature at right angles being carried over

the occlusal surface of the tooth to engage in the twist of the other two ligature ends which pass through the interproximate spaces to the arch wire, one above and the other below.

By forming a curved hook upon the end of the ligatures before inserting, they will easily pass through the interproximate space without injury to the gum tissue, as the ligature will follow this curve upward or downward through the space until it reappears free from the gums on the lingual or buccal surface of the teeth.

Ligatures should be pulled taut over the buccal surface of the arch, and pressure between the tooth and arch brought to bear with the thumb and finger, the long end of the ligature then being grasped with the left hand, and the short end with the arch and ligature pliers illustrated in Fig. 431, and twisted a full turn to the left, preferably

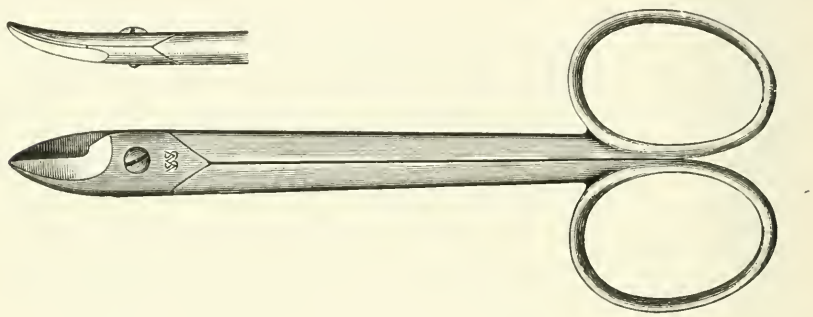

Fig. 432.

always twisting in the same direction. The ends of the ligatures should be clipped to one-eighth inch lengths and bent either above or below the arch to positions where they will cause no irritation.

The arch and ligature pliers, devised by the author, have rounded beaks except the tips, so that the lips or cheek will not be caught between them as in a flat nosed plier. They are useful also for bending the expansion arch to shape as previously described.

An improved form of ligature cutting snips in which the points of the beaks are especially long and slender and which allow of a little more delicate work is illustrated in Fig. 432.

Lingual Bar and Ligature.—The alignment of the lower incisors is sometimes easily effected by the use of a lingual bar to which is soldered one ligature to prevent displacement, and another ligature extending around the bar and through the interproximate space between the central and lateral on one side to the arch wire. For example, in A, Fig. 433, one ligature on each side between the central

and lateral, and encircling the lingual bar, will easily align the incisors without the use of a single band, even where there is considerable torsion of any of these teeth.

Closing up Spaces between Incisors.—If it is desired to close up spaces between the incisors, the ligatures may be applied in the manner shown in Fig. 433 at B, the two centrals being surrounded by a single ligature which also encloses the arch; at the same time, the laterals on either side may be similarly ligated to the centrals. This method of ligation may be extended around as far as the second bicuspid to advantage in some cases.

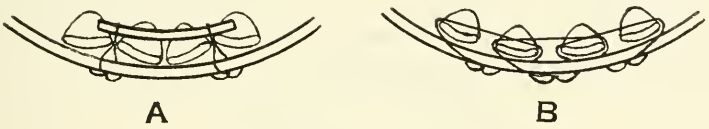

FIG. 433.

Elevation of Cuspid.—In the elevation of the cuspid, the Magill band should be formed high up on the labial surface of the tooth, and soldered on this surface, and trimmed so that a projecting portion of the united ends of the band material is left for the attachment of a ligature to the arch as in Fig. 434. This method of attachment of the ligature is to be preferred to the spur, and saves the time of soldering the latter to the band.

The author has succeeded in having these ligatures made in a filled gold wire which possesses the softness of the annealed brass wire without the oxidizing of the latter, if used with the gold arch. The all gold ligature wire may also be used if preferred.

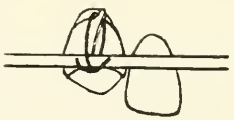

FIG. 434.

The operator should form the habit of twisting all ligatures in the same direction, preferably to the left. The ligature wire may be economically used by grasping the long strand with the left hand and the short one, about two inches in length, with the pliers in the right hand, and the twist should be a complete one, so as to avoid all danger of its being unloosened between sittings.

In cutting off the surplus ends of the ligature wire, about one-eighth of an inch of wire should be left, which should be bent above or below and around the arch where it will not irritate the lips or cheek.

The silk ligature is again coming into use, for in the hands of the skilled operator, it may be manipulated in such a way as to avoid the

use of bands to a large extent, and rendering the operation less painful, and the appearance of the mouth more esthetic than when many bands and metal ligatures are used.

Mesial and Distal Movements of Incisors.—The mesial or distal movement of incisors is often necessary, and can be readily accomplished by the use of the ligatures alone in connection with spurs upon the arch for directing the movement as desired, as in Fig. 435. The spurs are made upon the arch so as to incline the ligatures in the desired direction, mesially or distally, and the nut at L is tightened, and at M is loosened, causing the arch to shift laterally in the direction of the arrow, JK, and carrying the incisors with it. The cuspids and bicuspids may be similarly ligated to the arch and share in the movement.

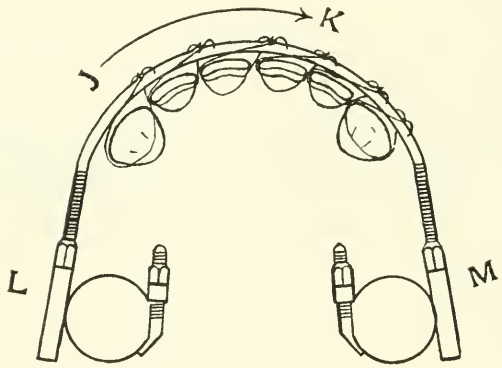

Fig. 435.

Distal Movement of Molars.—Oftentimes it is necessary, in opening up spaces for lost first molars, to pit the resistance of the ten anterior teeth against that of the second molars, which, in these cases, usually drift forward into the space of the lost first molars, and must be moved distally by a proper manipulation of the anchorage.

Reversal of Base of Anchorage.—The reversal of the base of anchorage from the molars to the anterior teeth for the distal movement of the molars, may be effected by ligating a sufficient number of the anterior teeth to the arch so that their combined resistance will be greater than that of the molars to be moved distally.

The combined resistance of the ten anterior teeth, as secured through ligation to the expansion arch as in Fig. 436, is greater than that of the second molars to distal movement, and turning up the nuts in front of the anchor tubes will force the molars distally and regain the spaces

of the lost first molars. The use of intermaxillary force as a re-enforcement is advisable in many cases.

To prevent the ligatures from slipping upon the expansion arch in the region of the bicuspids, spurs should be soldered upon the arch and the ligatures attached in front of them as at A and B, for securing the resistance of the second bicuspids more perfectly. The proximate contact with the first bicuspids will suffice to obtain the resistance of these teeth in line with the required movements without spurs to attach ligatures.

The arrows indicate the direction of tooth movement, in the region of least resistance, or the distal movement of the second molar teeth.

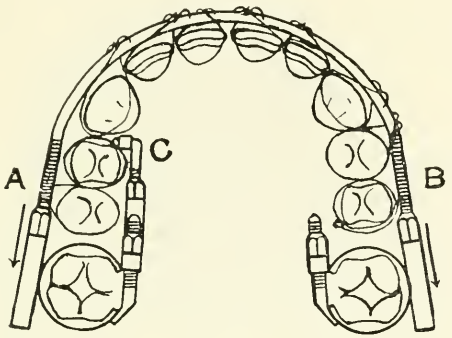

FIG. 436.

Hooks may be attached to the expansion arch for the use of intermaxillary anchorage, extending the elastic rubbers from hooks on the lower expansion arch to the distal ends of the anchor tubes of the upper expansion arch, in case the resistance of the single molars should prove to be greater than the anterior teeth to forward movement, thus preventing or inhibiting such undesired movement.

As there may often be found in these cases some distal positions of the anterior teeth as a whole, having traveled distally into the space of the lost molars, it may be found necessary to use the second molars as simple anchorage at first, and successively move the anterior teeth forward, ligating and moving the two centrals, then the two laterals, and the cuspids next, and so on, turning up the nuts, in front of the anchor tubes and reversing the anchorage to the anterior teeth for the distal movement of the molars as soon as the anterior movement of the incisors and cuspids is well started.

A traction screw operating on the lingual side of the molar clamp band directly against the bicuspid, as at C, will materially assist in

opening up the space for the lost molar because of the positive character of the force applied in as direct a manner as possible.

Spaces occurring between the anterior teeth during their forward movement, should be closed up by ligating the anterior teeth in pairs from either side of the median line, as in Fig. 433–B, the centrals being ligated together first, and the laterals to the centrals, etc.

Another method of closing up these spaces is by placing barbs on the surface of the expansion arch in such mesial positions that they will, through the ligatures, direct the teeth toward the center in their forward movement.

If the resistance of the second molars in the movement of the anterior teeth, forward, should prove to be insufficient, as indicated by their becoming unstable, or moving too rapidly or too far, the intermaxillary elastics may be attached from the distal ends of the lower molar anchor tubes to hooks placed upon the sides of the upper expansion arch, and thus inhibit further instability and allow of the continuation of the anterior movement of the lower incisors, cuspids, etc., through this re-enforcement, until such time as the distal movement of the molars may require a reversal of the anchorage.



FIG. 437.

Tipping Up Molars.—In cases like that just described, the second molar in its assumption of the first molar space, often tips forward to a considerable extent, requiring an adjustment of the anchorage, especially to effect their restoration to upright positions during their distal movement.

The tubes upon the anchor bands should first be so aligned that the ends of the expansion arch may be easily inserted into them, the bow of the arch resting upon the necks of the incisor teeth, as in alignment of arch and anchor tubes for ordinary expansion.

The ends of the expansion arch should then be uniformly bent downward, beginning at a point just anterior to the nuts, as at G in Fig. 437, and the arch re-inserted into the anchor tubes, when the bow of the arch will lie somewhat below the necks of the incisors. By springing the front of the arch upward upon the necks of the incisor teeth and ligating them to the arch at the same time, an upward leverage will be exerted upon the second molar which will quickly restore it to an upright position, at the same time that it is being moved distally by the turning up of the nuts in front of the anchor tubes.

Rotation of Molars.—Several methods are in use for the rotation of molars in torso-occlusion. In the rotation of a molar which has

its mesio-buccal cusp farther buccally than the disto-buccal cusp, the expansion arch, bent as at E in Fig. 425, before slipping into the buccal tube on the clamp band encircling the molar, answers every purpose, especially as the desired change of position of the molar is in line with the buccal movement of the expansion arch, the distal end traveling farther buccally than a point on the arch opposite the mesio-buccal cusp of the molar.

The reverse of this position, or the molar with the mesio-buccal cusp farther lingual than the disto-buccal cusp, is not so amenable to change in the desired direction by the lingual bending of the ends of the expansion arch, since the tendency of the arch in its outward

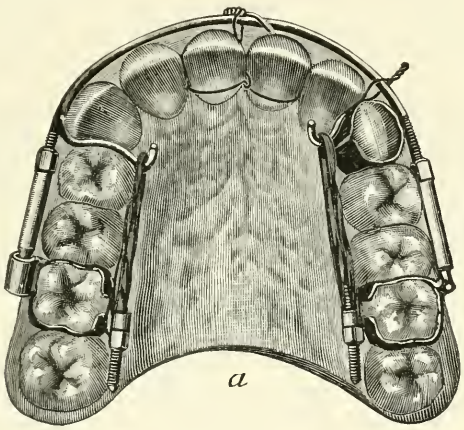

FIG. 438.

movement is to move the disto-buccal cusp farther buccally in relation to the mesial cusp, in spite of the lingual bending of the arch to prevent it.

A method devised by Dr. J. L. Young for effecting the rotation of the molar, is illustrated in Fig. 438, the two sides of the arch being treated slightly differently.

On one-half of the arch, a clamp band, with its lingual screw directed distally, is fitted to the molar in torso-occlusion, and on that part of the band corresponding to the mesio-buccal angle, a short tube is soldered parallel to the long axis of the tooth, as shown in position on the clamp band on the right side of the cut. A short wire fitting into this tube snugly, is then soldered at right angles to the surface or to the end of an arch or tube. The attachment, when in position, forms a hinged anchor tube for the expansion arch at the mesio-buccal angle of the molar, as illustrated.

The cuspid on the same side as the molar to be rotated is fitted with a band and a lingual hook pointing mesially, and a rubber band of sufficient strength attached from this hook to the lingual screw of the molar clamp band, as seen on lingual side of the arch in the figure. The cuspid should be firmly ligated to the arch so as to prevent its distal or rotary movement during the operation. When the nut on the expansion arch is tightened, the tendency to distal movement of the mesio-buccal angle of the molar, and the reciprocating action of the elastic, pulling the disto-lingual angle mesially, exerts the most positive rotating action upon the molar in the desired direction.

A slight variation from this method is illustrated on the other side of the same arch on the left side of the cut. The expansion arch

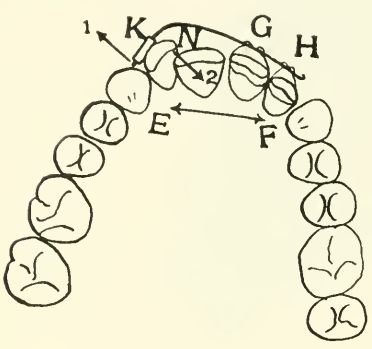

Fig. 439.

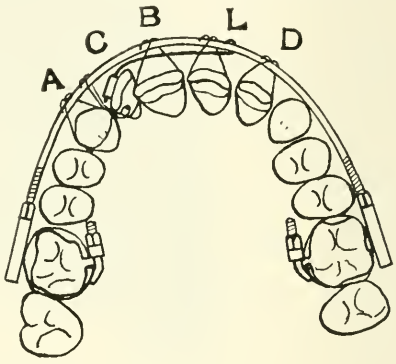

Fig. 440.

is attached to the mesio-buccal surface of the molar band by a ball and socket joint, allowing a little more freedom of movement of the molar in its rotary movement.

A rigid hook is soldered to the expansion arch, curving between the cusps of the cuspid and first bicuspid on the same side of the arch, and extending up close to the palate, with the end of the hook pointing mesially. A rubber band of suitable strength is next attached from this hook over the lingual screw of the clamp band on the molar to be rotated as shown in the same cut.

In this method, in which the attachments are all made to the expansion arch, the reciprocation of force is almost absolute from the mesio-buccal angle of the molar to the disto-lingual angle, in the rotary force exerted by the two opposite acting forces on each side.

The Lever.—The principle of the lever is a very old one in its application to the dental arch, but there is no doubt that its use alone

as a mechanical appliance for the correction of malocclusion is a misapplication of an efficient mechanical principle when properly used.

For example, the old method of using the lever, Fig. 439, did not recognize the principle of arch expansion to make space for a rotated tooth before attempting to turn it into position. The fulcrum of the lever is at N, the weight at K, and the *power* at G–H. The two arrows, 1 and 2, indicate the direction of the turning tooth, and it will be seen that the arch becomes more contracted, if anything, during the process, the distance, E–F, from cuspid to cuspid remaining the same, thus preventing the alignment of the incisors, whose combined mesio-distal diameters are greater than the arc of the arch from one cuspid to the other.

The proper use of the lever in this case should be as an auxiliary, the principle movements indicated being, first, general arch expansion, so that the incisors may have space for alignment; and second, rotation of individual teeth which are turned, as illustrated by the combination of expansion arch and lever in Fig. 440.

By ligating the incisors and cuspids to the arch, at A, C, B, D, etc., the space for the lateral in torso-occlusion is gradually made, while the arch lever, L, at the same time is turning the tooth into position of correct alignment. The arch lever may be made of German silver, or iridio-platinum, and should have a hook at one end to engage with the arch, so as to do away with tying it, Fig. 441.

Fig. 441.

Operation for Abnormal Frenum Labium.—The separation of the upper central incisors through the abnormal lingual attachment of the frenum labium, extending, as it does, between the teeth to the lingual tuft in some cases, usually requires simple operative treatment beyond the movement of the two teeth together, and their retention for a considerable period, for, in the latter case, the presence of the frenum is still a causative factor in the return of the space between them.

The plan of operative treatment usually followed, which was suggested by Dr. Angle, is that of splitting the ligament with a lancet, and cauterizing the wound with the actual cautery to obtain advantage of the cicatrization of the tissues which follows as well as by its inertness as an active force in causing separation of the teeth after they have been moved together.

The author's method of treatment of these cases varies but slightly from that described, except that the frenum is as nearly as possible dissected from its attachment between the central incisors, by making

incisions upon either side of it, and cutting it off with a pair of gum scissors slightly above the necks of the incisors.

The tissue is anesthetized as usual, and the teeth provided with cemented bands and spurs for the attachment of ligatures for drawing them together before performing the operation.

After cutting out as much of the tough ligamentous attachment as is deemed necessary, the actual cautery is passed into the wound,

FIG. 442.

when it is allowed to heal for a couple of days, and then the two centrals are ligated together from the spurs upon the labial surface of their cemented bands.

Their movement occupies but a short period of time, but even with the advantage of the shrinkage of the cicatricial tissue between them, their retention is a matter of a year's time even in the youngest cases. The two central incisor bands are usually soldered together and cemented in position for the retention of these cases.

Fig. 442 illustrates the casts of a case of this character showing the

operation performed in this manner, the patient being eight years of age.

Expansion of the Deciduous Arch.—Smaller molar clamp bands and a 17 or 18 gauge (B. & S.) expansion arch should be used for the expansion of the deciduous arch. Here the silk ligature covered with chloro-percha will be found especially useful, being much easier to adjust than the wire ligature.

A valuable addition to operative technique in the lateral expansion of deciduous cuspids and molars is embodied in a suggestion of Dr. C. A. Hawley's, illustrated in Fig. 443.

The clamp bands are reversed, with the lingual screws pointing distally, and lingual wires are soldered to their mesio-lingual angles,

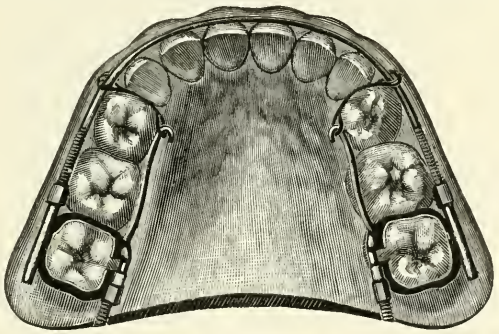

FIG. 443. (*Hawley.*)

extending along the lingual surfaces of the deciduous molars, and ending in a hook opposite the deciduous cuspids, where one wire ligatured to the expansion arch on each side controls the lateral movement of all the deciduous teeth in each lateral half of the arch.

Treatment of Infra-occlusion.—The most common form of infra-occlusion presenting in practice is that in which there is lack of occlusion of the anterior teeth, varying in degree from a slight infra-occlusion of one or more incisors to those cases in which the upper and lower incisors are more than half an inch apart when the molars are occluding.

The simple cases of infra-occlusion of the incisors may be easily managed by bending the expansion arch downward before placing it in position, as in dotted lines in Fig. 444, and then springing it upward to ligate the incisors to it after it is in position. The incisors may be banded, with labial spurs for more direct application of the force. Further treatment of infra-occlusion is described under treatment of Class I and II.

Early Treatment of Arrested Developmental Conditions in the Arches.—Any arrested or deficient development of the arches of teeth may be diagnosed in advance of the permanent dentition, and should be stimulated to normal growth and development as early as the age of the patient will allow the wearing of delicate arches and bands for the purpose.

Except for mesial or distal occlusion of the deciduous arches of teeth, the arrested lateral development of the arch is a condition most commonly demanding interference by the orthodontist.

The lack of mesial and distal spacing between the deciduous incisors and cuspids at about five or six years of age is a very certain indication of a lack of anterior development sufficient for the proper eruption of the permanent teeth succeeding them.

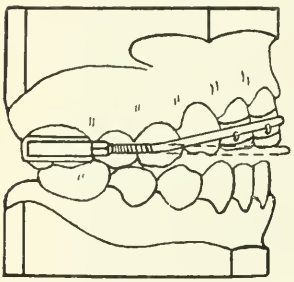

FIG. 444.

If the deciduous arch needs widening, it is better to perform this operation some little time before the roots of the deciduous molars have begun to absorb, since the crowns of the permanent bicuspids are enclosed within the roots of the deciduous molars, as may be observed in Fig. 445, and the result of the expansion will be to move the crowns of these permanent teeth as well as the deciduous teeth and surrounding alveolar tissues into a larger arc, at the same time affording a gentle stimulus to the normal development of the arch.

If treatment is delayed until just before the time for shedding of the deciduous first molars, the roots of these teeth being almost absorbed, can afford no resistance to the appliance in expansion, and the crown will be shed before any expansion can be accomplished in this region, which will then delay the widening of the arch in this region until the permanent bicuspids are fully erupted, there being no other means of anchorage in the meantime, except what may be possibly obtained through the ligation of the deciduous cuspid, which many times is prematurely shed.

The author has obtained the best results in arch development between the ages of six and eight years, and in some cases still younger, especially where a mesial or distal occlusion seemed inevitable.

It is reasonable to suppose, from the rapidity of development of the alveolar process during the primary stages of eruption of the permanent teeth, as illustrated in Fig. 446, that the movement of the deciduous teeth some little time previous to the period when absorption

of the roots of deciduous cuspids and molars is about to be initiated, conforms most nearly to a natural and physiological process, and that the amount of absorption of alveolar process in advance of moving

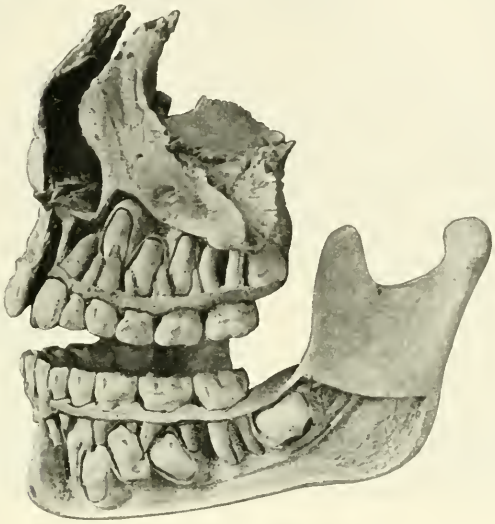

FIG. 445.

teeth is comparatively slight, the change in these structures being analagous to the natural developmental changes which would occur in case no arrest of development had been observed.

FIG. 446.

Ideal Treatment of a Practical Case.—Fig. 447 illustrates an arrested development of an upper arch of a child nine years of age, in which the deciduous cuspids and molars are still intact and firm in their positions, and capable of offering resistance to the appliance

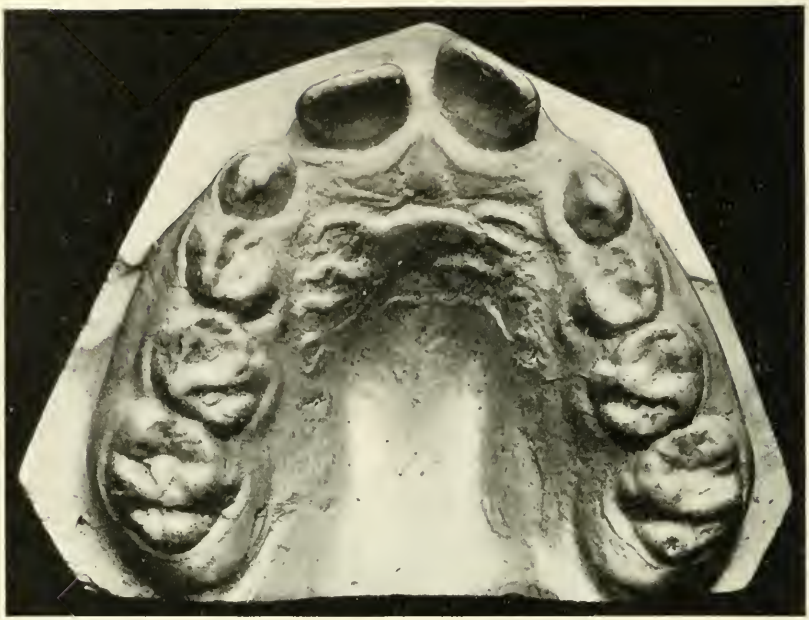

FIG. 447.

FIG. 448.

for lateral expansion of the arch, and of carrying with them the crowns of the permanent bicuspids, and surrounding alveolar structures.

Although the permanent central incisors and first molars have erupted, as far as development is concerned, it is still a deciduous arch, and the diagram for a .39 central indicates that considerable anterior and posterior expansion is necessary at this time in order to secure sufficient development for the accommodation of the permanent teeth yet to erupt.

The result of treatment of this arch, according to these indications, is exhibited in Fig. 448, in which the extent of the development is measured by the diagram of the pre-determined arch.

Further development of this arch can safely be entrusted to nature, provided that the amount of development already obtained is effectually retained as long as possible before the eruption of the permanent cuspids and bicuspids. The retention of this arch is illustrated in Fig. 575, in the chapter on retention, the deciduous teeth being utilized for resistance until such time as the absorption of their roots would render them unfit for such use.

Realizing the benefits of such early development of the dental arches, the orthodontia specialist prefers to operate upon the children in whose mouths, the presence of firmly implanted deciduous teeth offer resistance for development of the dental arch in advance of the eruption of the majority of the permanent teeth. In the last decade, the *personnel* of the specialist's practice has gradually changed from the adult to the child, with consequent greater possibilities of permanent benefit to the individual.

Advantages of Early Treatment.—Briefly detailed, the advantages of early treatment of malocclusion and arrested development of the dental arches are as follows:

1. Early treatment is undertaken at a time when the alveolar processes are more cartilaginous in character than later, the teeth being thus more readily moved because of lessened resistance than when the cartilaginous structures are fully calcified.

2. The restoration of the proper size and shape of the arches at an early age conforms more nearly to a physiological process or a stimulation to normal development, rather than a tearing down and rebuilding process which would be necessary at a mature age.

3. The function of the dental arches being restored early in child life, all developmental processes in relation thereto, such as the growth of the dental and maxillary arches and the nasal cavities, and the conformation of the muscles of mastication and expression, will have

the best chance for normal development, and the attainment of harmony in the profile become a possibility through such normal relationships.

4. The earlier treatment is undertaken, the less tendency exists for the return of the malocclusion, and the less the need of retention, as age only increases resistance to tooth movement, confirms the deformity in its relationship by long and improper function of occlusion and muscular expression, and by the initiation of structural changes in bony and muscular tissues which cannot be removed by treatment.

VII. CLASS-I-TREATMENT.

Etiology and Diagnosis.—In the first class of malocclusion, the teeth may be in any possible position of abnormality which would be consistent with a normal antero-posterior relationship of the arches of teeth. For example, any of the incisors and canines may be in labial or lingual occlusion, or the bicuspids and molars in buccal or lingual occlusion. There may be protrusions of the anterior part of the upper arch, or retrusions of the anterior part of the lower arch, without disturbing the normal antero-posterior relationship in the molar region.

The etiological manifestations and the variations in harmony in the facial profile are more varied than in any other class, and, taken together with the multiplicity of malpositions of the teeth, often simulating in general appearance the malocclusions of the other classes, make it the most misleading in its characteristics and difficult in its diagnosis.

The mouth-breather is not infrequently seen in this class of malocclusion, presenting many times a simulation of the mouth-breather of Class II, with protruding upper incisors, or a lack of anterior occlusion.

Among the etiological characteristics noted in this class are the prolonged retention of deciduous teeth, the premature loss of deciduous teeth, loss of permanent teeth, supernumeraries, abnormal frenum labium, lip-biting and thumb-sucking, and mouth-breathing.

Malnutrition, through the diminution of a proper lymph or blood supply, is responsible to a large extent for the undeveloped arches of teeth, which are chiefly noticeable in the class under consideration.

The diagnosis of this class is indicated by the normal mesio-distal relation of the first molars, which, having been determined, by noting the proper occlusion of first molar cusps on either side, renders the indications for treatment a restoration of the normal relationship of occlusal conditions anterior to the first molars, except in so far as

the lateral expansion of both arches may effect the bucco-lingual relations of these teeth.

Anchorage Requirements.—A study of the case should next be made with reference to the form and requirements of anchorage, having

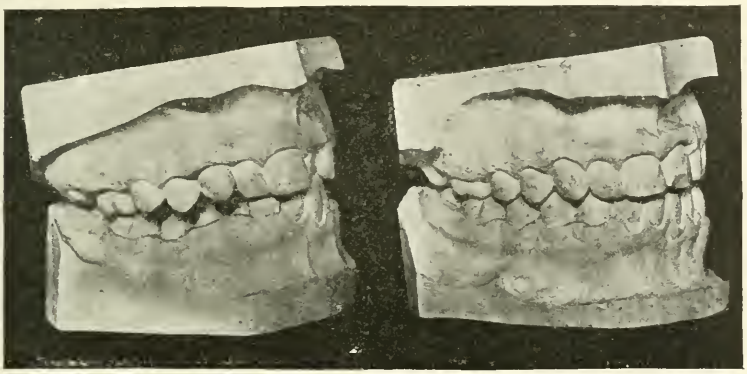

Fig. 449.

in mind that a combination of a number of different forms of anchorage may be necessary in the treatment of this class of cases, even to the extent of using a form of anchorage especially required for either Class II or III in certain cases.

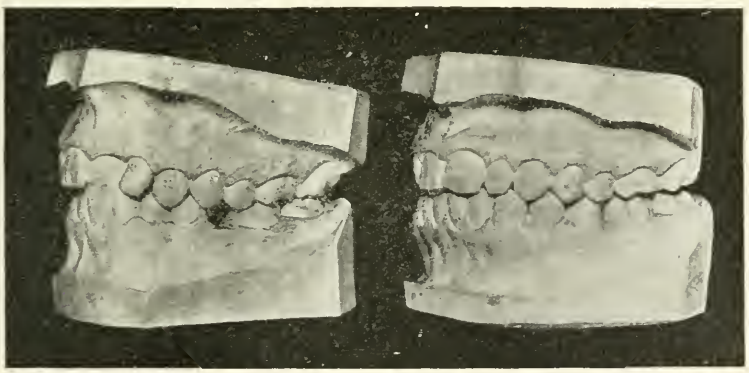

Fig. 450.

A pre-determination of the size of the completed arch by the method of arch determination previously described in the chapter on diagnosis, will aid in the plan for lateral expansion, indicating the size of the arc of the anterior portion of the expansion arch, and the alignment of the anchor tubes on molar bands to suit the case.

Extraction, as a beneficial procedure, should be excluded except in rare cases, and where it has already been resorted to, the restoration of lost space through contraction at the point of extraction, should be accomplished and retained by proper methods.

Symptoms of mouth-breathing should be immediately noted, and

Fig. 451.

the case referred to a competent rhinologist for examination of the nose and throat, and removal of nasal or pharyngeal obstruction if found present.

Treatment of Special Cases. – Fig. 449 represents the right occlusion, before and after treatment, of an average case of Class I, the

Fig. 452.

arches being contracted and the teeth anterior to the first molars in various positions of malocclusion previous to treatment, and afterward in normal occlusal relation, as noted in the model on the right of this figure.

The left occlusion, in Fig. 450, illustrates the movement of the

upper left central from lingual to normal occlusion, and the regaining of the proper space for, and eruption to normal position of the left lower second bicuspid.

Fig. 451 exhibits the restoration of the normal size and shape of the upper arch, the malposed teeth being placed in the line of occlusion, as noted in the cast on the right of the cut.

Fig. 452 presents the chief difficulties encountered in the case, in the extent of the contraction of the anterior portion of the lower arch and the attainment of the ideal in the size and shape of the arch as a final result. The lower unerupted bicuspid very quickly took advantage of its release from imprisonment between the first bicuspid and first molar, and erupted into occlusion without mechanical aid, lending its additional support as a keystone to hold the arch intact. The presence of the unerupted bicuspid in the process could be diagnosed by the swollen condition of the gum tissue overlying the tooth, without the use of the X-ray as is often necessary in these cases.

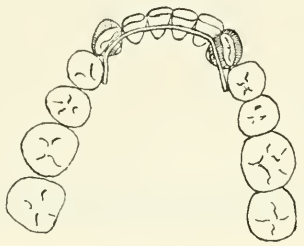

Fig. 453.

The appliances used in this case are the expansion arch and anchor clamp bands. In the upper arch, the left central was banded, and the ligature extended from a lingual spur to the arch, with the rubber wedge between the mesial angle of the tooth and the arch to assist in its rotation. Very little expansion was needed in the upper arch beyond that necessary for the accommodation of the left central.

In the lower arch considerable lateral expansion was necessary, and the adjustment of the appliances so as to obtain reciprocal anchorage from one side of the arch to the other through ligatures on the arch. The left lower first bicuspid was banded, and a ligature extended from a mesio-lingual lug on the band to a spur on the arch wire, so as to secure the two necessary movements of rotation and lateral realignment of this tooth.

The retention of the upper arch consisted of a single band upon the left central, with a distal spur extending over and touching the labial surface of the left lateral, which was worn for a few months only, as the occlusal inclined plane of the lower central and lateral incisors on that side effectually retained the central in position after that time.

The retention of the lower arch in this case, as seen in Fig. 453, was somewhat more complicated than the upper, yet the least number

of bands upon individual teeth that would meet the requirements of retention were used. The bands on each cuspid, united by a lingual wire, and having lingual wire extensions upon the surfaces of the first

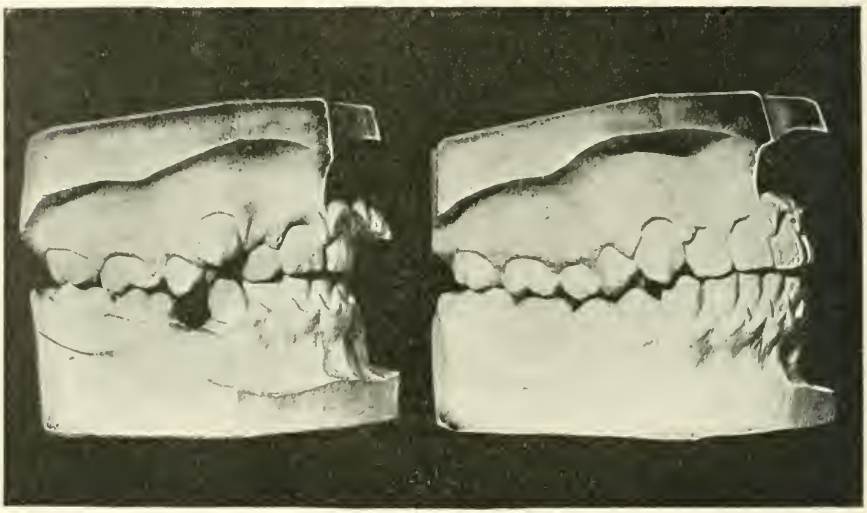

Fig. 454.

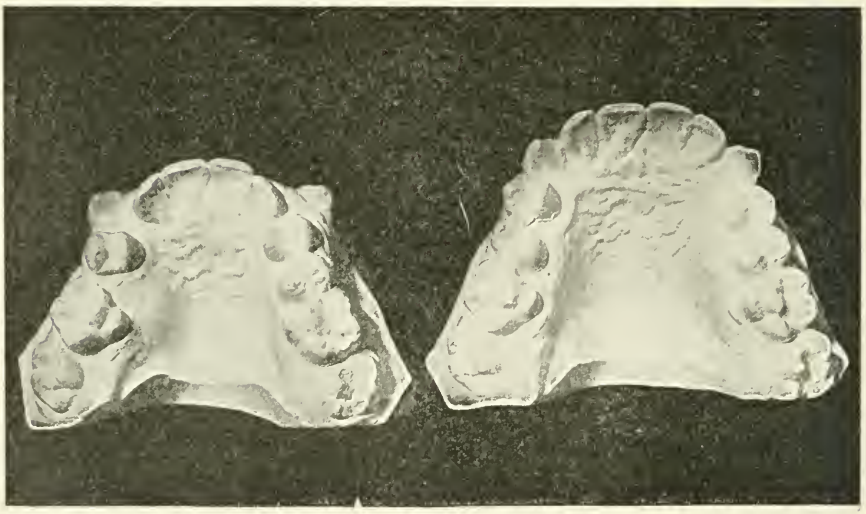

Fig. 455.

bicuspids, served to retain the lateral expansion of the arch as well as the alignment of the six anterior teeth. The extra band with labial spur on the first bicuspid on the left side was placed there to prevent

torsion of this tooth. The author has found it advisable to retain individual teeth which have been rotated to any extent, with single band and properly placed spurs, when they can not be advantageously banded in the construction of the general retaining apparatus.

The case just illustrated, although presenting some difficulties in the treatment of the lower arch, is simple compared with the problems of normal arch and occlusal restoration exhibited in the treatment of the next case, the right occlusion, before and after treatment of which is shown in Fig. 454.

The case is that of a boy fourteen years of age, and in the model on the left of Fig. 454 may be noted the contracted arch, and the closing up of the space for the upper second bicuspid and the partial closure of the space for the lower bicuspids, which are impacted in the alveolus just external to their positions in the arch.

The etiological factors in this case were obscure, in that the boy was a normal breather, of good history, and, beyond the premature loss of the deciduous cuspids and molars, as a mechanical factor in the causation of the undeveloped arches, very little could be learned of a pathological nature which might have affected the normal development of the dental arches.

The occlusal view of the upper casts, before and after treatment, in Fig. 455, exhibits a degree of expansion which would not have been believed possible by the uninitiated in the secrets of occlusal restoration. The upper second bicuspid on the right side was freed from impaction, and erupted to its proper position of occlusion, the cuspids also being restored to alignment, or rather the rest of the teeth in the anterior part of the arch to the cuspid alignment, as they were more nearly in their normal positions than any of the other anterior teeth.

The lower cast on the left of Fig. 456 exhibits the impaction of three teeth, two bicuspids on the right side and the second bicuspid on the left side, the release of which could never have been possible without the interference of the orthodontist. In the cast on the right, the successful accomplishment of the necessary expansion for the accommodation of these teeth in the arch may be noted. By comparison of the before and after casts of both upper and lower arches in this case, the unusual amount of lateral expansion may be observed, showing how far short nature came in her development of the arches, and the possibilities of applied science in the restoration of the normal in development and the ideal in occlusion and harmony of contour of the arches of teeth.

The picture of the left occlusion of the case before and after treat-

ment, in Fig. 457, needs no description. The result of ideally correct treatment without extraction is very evident, and the classic lines in

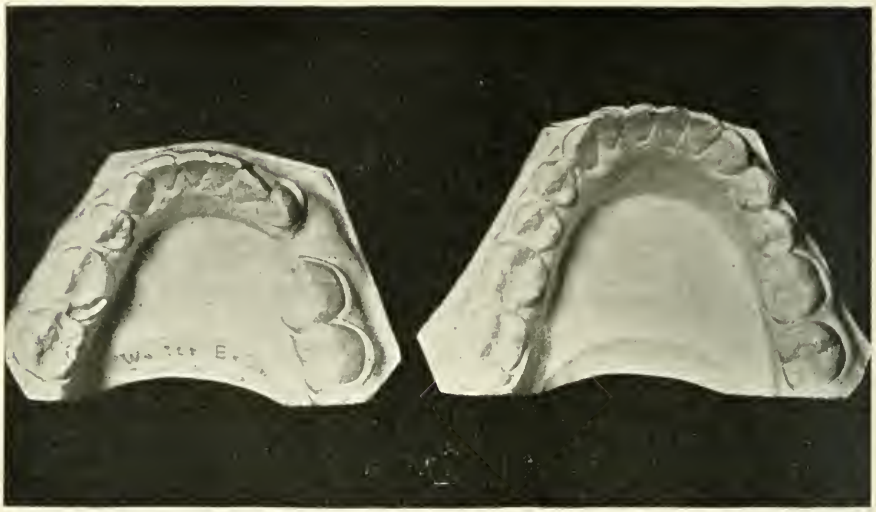

Fig. 456.

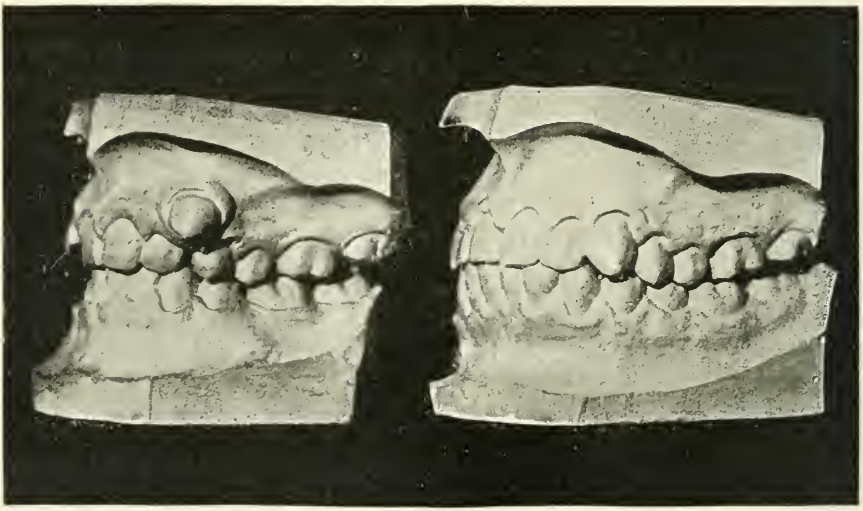

Fig. 457.

the after-treatment model can scarcely be excelled in beauty by any masterpiece of the sculptor's art. Notice the graceful curves of the arches, the symmetry and proportion of contour, the wonderful har-

mony which prevails in the arches through the perfect adjustment of each occlusal inclined plane of the antagonizing teeth to the requirements of normal occlusion.

The accompanying profile of this patient in Fig. 458 is shown to illustrate the fact that such an extensive operation of expansion of arches does not produce undue protrusion, as has been commonly supposed. The lower part of the face is entirely in harmony with the rest of the features, being proportionate for its type, and in its contour hardly suggestive that an operation of this extent had been performed upon the dental arches.

The appliances used in this case were similar to those in the previous case, and the treatment only differed in its extent of expansion carried out, and the opening of the greater number of spaces necessary for the accommodation of the teeth which were either partially or wholly unerupted.

Fig. 458.

Soldered spurs upon the arches guided the direction of the ligatures upon teeth contiguous to the spaces to be opened, some of which it was necessary to band, and provide with lingual spurs for the most positive action of the appliance to be exerted upon them.

In the upper arch, the lateral incisors and right first bicuspid were banded and ligated to the expansion arch from spurs attached to their disto-lingual angles.

In the lower arch, the teeth needing banding in a similar manner were the right cuspid and the left first bicuspid, as a most positive attachment of ligatures was necessary in order to reopen the adjacent spaces for the unerupted teeth.

The upper arch was retained anteriorly by uniting cuspid bands with a lingual wire, and posteriorly by a roofplate, Fig. 459.

The lower arch was retained anteriorly by a lingual wire attached to cuspid bands, from which spurs were extended to include the first bicuspids, Fig. 460.

A very interesting case of Class I in the peculiarity of its malocclusion, and in the combination of appliances and anchorage necessary for its treatment, is illustrated from the occlusal aspect of the

upper arch before treatment in Fig. 461, the feature of particular interest being the disto-lingual position of the upper right cuspid, which, on account of its extreme distal position opposite the interproximate space between the two bicuspids, is apparently secure in its malocclusion, presenting unusual obstacles to its restoration to the line of occlusion.

By a careful conservation of anchorage and operation of the appliances, the accomplishment of the desired result, as shown in the after-treatment cast of the upper arch in Fig. 462, was secured.

The primary anchorage and its usual re-enforcements by ligatures for expansion of the arch, is entirely inadequate to produce the desired results in a case of this kind, for although the space for the right cuspid

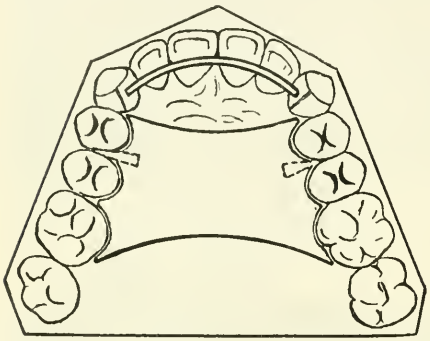

FIG. 459.

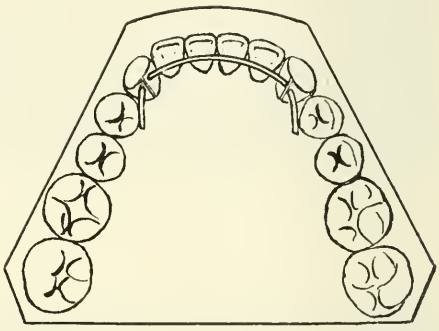

FIG. 460.

could be regained by a proper direction of ligatures on the expansion arch, the control of the cuspid in lingual occlusion in this same manner is impracticable.

The cuspid needed first to be moved forward opposite its regained space by means of a traction screw operating from the first molar anchorage, being attached to the lingual screw, as seen in Fig. 463, the right angled end operating in a horizontal tube soldered to the mesial surface of a band upon the cuspid.

The expansion arch was in operation at the same time enlarging the arch and making room for the cuspid, the incisors being directed toward the opposite side of the arch by spurs located toward the left side of the arch from each incisor, and the right lateral having a band with a lingual spur for more positive action of the ligature at this point.

It is evident that the combined distally reacting forces of the expansion arch on the buccal, and the traction screw on the lingual side of the first molar, would be greater than the resistance of the first molar without re-enforcement, and the use of intermaxillary anchorage

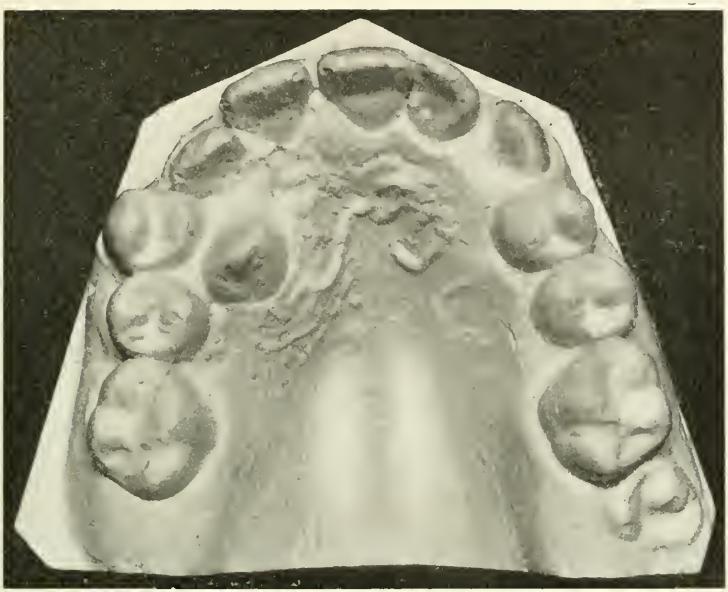

FIG 461

FIG. 462.

for this purpose as illustrated in Fig. 464 effectually counterbalanced the tendency to distal movement of the molar, so that the forces acting mesially from this base could operate without disturbing the stability of the anchorage.

The operation on the lower arch was comparatively simple, requiring lateral and anterior expansion to harmonize the occlusion with that of the upper arch, at the same time regaining the full space for

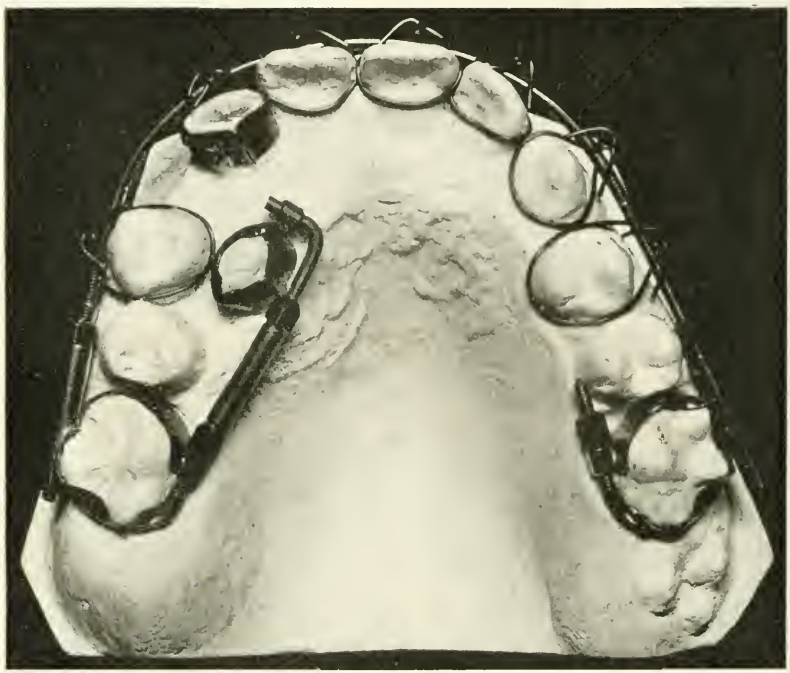

Fig. 463.

the lower right first molar, part of the mesio-distal diameter of which has been lost through caries.

The success of this combination of appliances may be noted in the right occlusion, before and after treatment, in Figs. 465 and 466, the cuspid occupying its normal position in the arch, and the occlusion of both arches being restored to harmonious cusp relationship.

Infra-occlusion of Incisors and Cuspids.—Lack of occlusion of the incisors and cuspids and often of the bicuspids is a condition not uncommonly found, usually in mouth-breathers, and varying in extent somewhat according to the aggravation of the habit. It occurs in all classes of malocclusion, and because of the less number of compli-

cations it presents in Class I, it responds more readily to treatment than in the other classes.

As this condition is essentially a lack of development of the premaxillary portion of the arches, and an abnormal development, in many cases, of the posterior part of the arches, cases presenting infra-occlusion

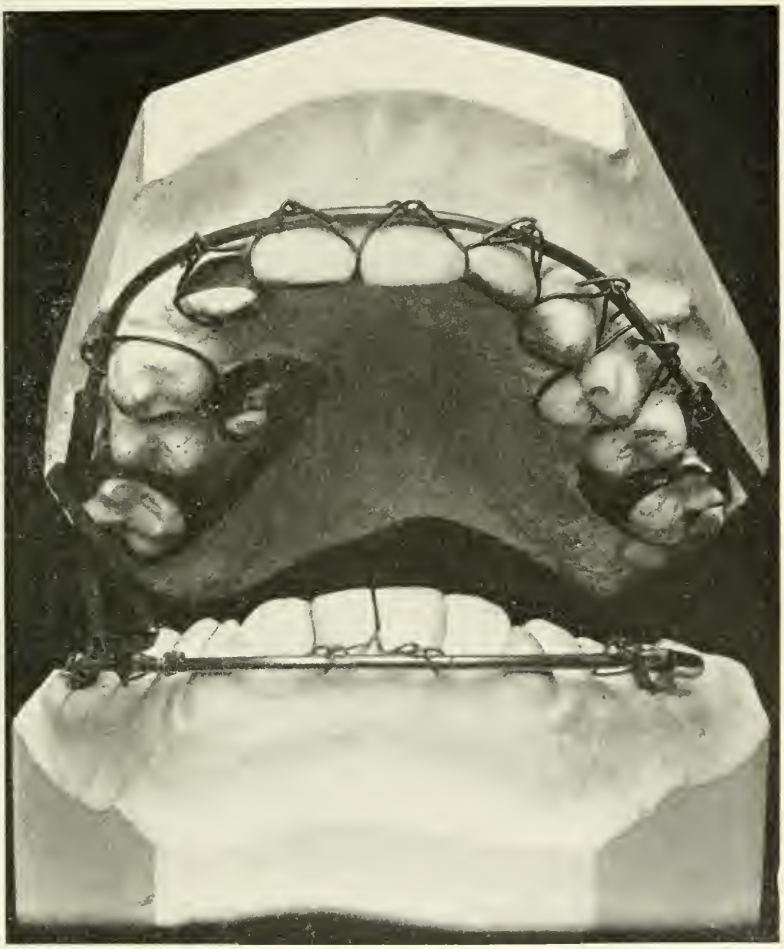

Fig. 464.

of the anterior teeth should be treated as early as possible, and especially normal habits of breathing restored at the same time so that development may be further unimpeded by any nasal or other respiratory obstruction.

Fig. 467 represents a case of this class in a mouth-breather eight years of age, before and after treatment.

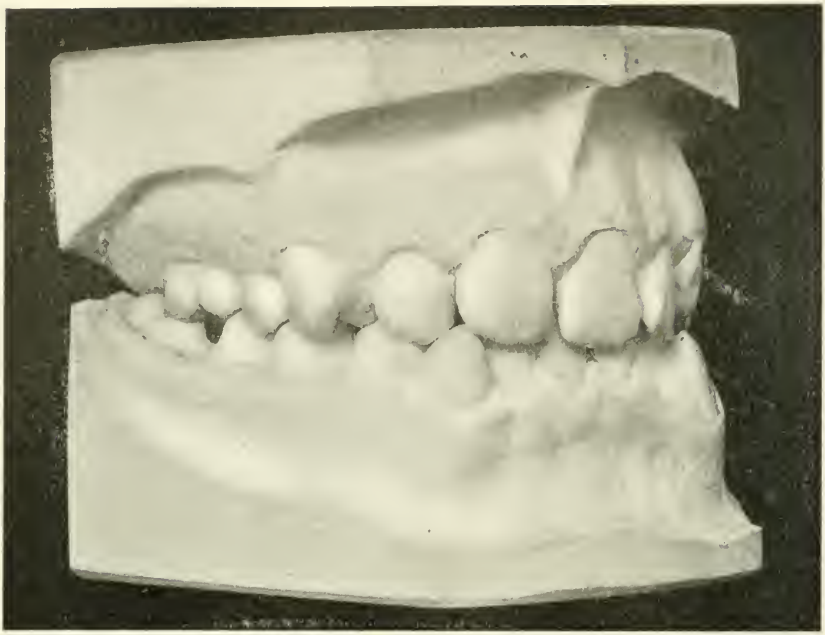

FIG. 465.

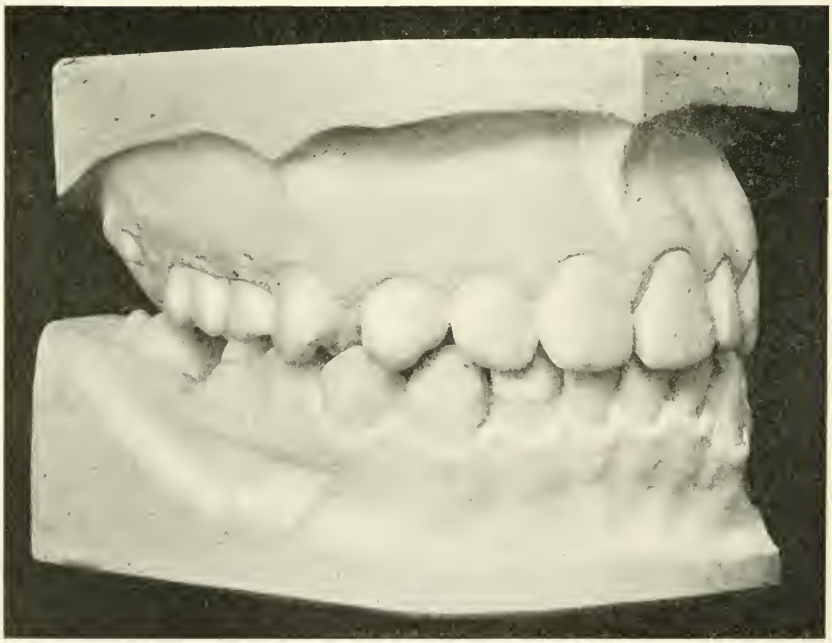

FIG. 466.

After removal of adenoids by a rhinologist, expansion arches were placed upon each arch, the incisors all banded, with spurs well up to-

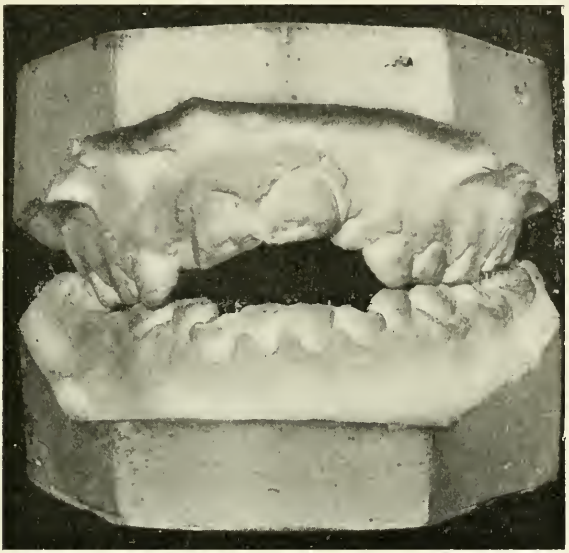

Fig 467

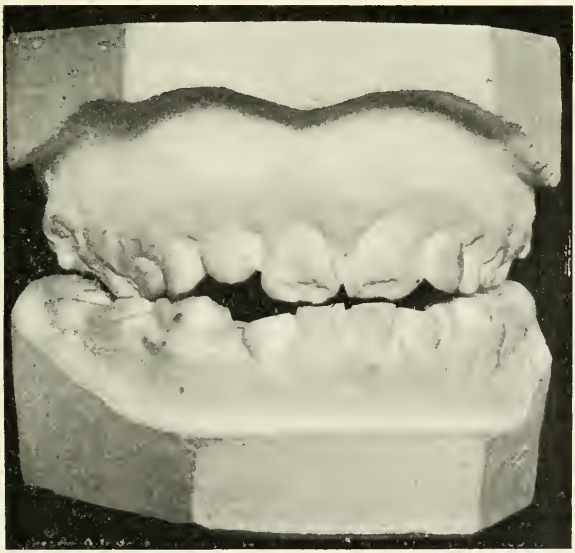

Fig. 467*a*.

ward the gingivæ, to which wire ligatures were attached from the anterior part of the arches, which were bent downward towards the

incisal edges so as to afford a downward spring on the upper, and an upward spring on the lower arch when ligated, as in Fig. 444, chapter on operative technique.

The retention of this case was effected by means of a lingual arch on the upper, Fig. 578, soldered to the ends of the lingual screws on anchor clamp bands fitted to the deciduous molars, the front of the arch engaging with lingual spurs on the incisors, and re-inforced by spurs extending over the occlusal surface of the first deciduous molars, the incisors being thus prevented from going back into their sockets. This retention was worn for about two years, until sufficient development in the premaxillary region had taken place. The retention of the lower arch was very similar to that of the upper. Cases of greater

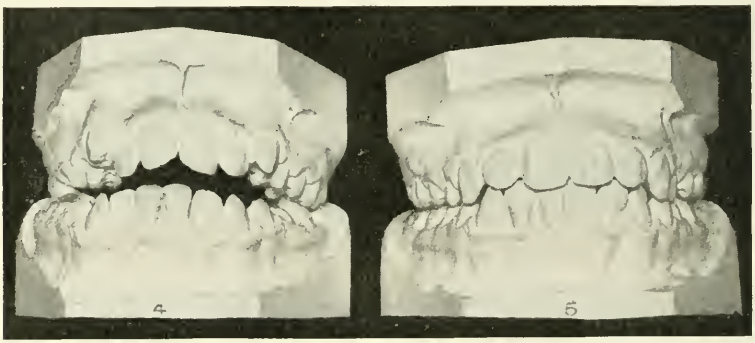

Fig. 468.

severity are not as simply treated as this one just described, the use of intermaxillary anchorage from the anterior part of each arch being required in order to overcome the greater resistance encountered, as illustrated in Fig. 511, chapter on treatment of Class II.

Fig. 468 illustrates a case of infra-occlusion of this class, from the practice of Dr. L. S. Lourie, and represents as near the ideal in treatment of these conditions as it is possible to attain.

After the age of development has passed, the difficulties attendant upon retaining the teeth in occlusion, even though the operation might be otherwise possible and feasible, render it advisable in many cases to perform the simpler operation of extensive grinding of the molars and bicuspids until occlusion is obtained, even if the vitality of one or more of the molars may have to be sacrificed in so doing.

The author has derived a great deal of satisfaction from this procedure in cases of adults, observing, however, great care that a certain amount of cusp articulation is preserved in order that the function of articulation and mastication may not be interfered with. In other words,

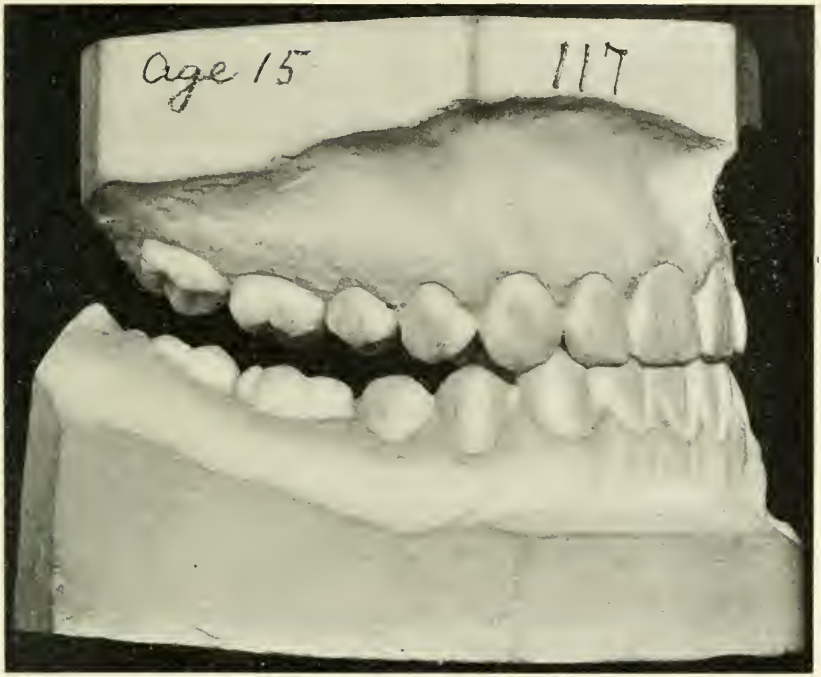

FIG 469.

FIG 470.

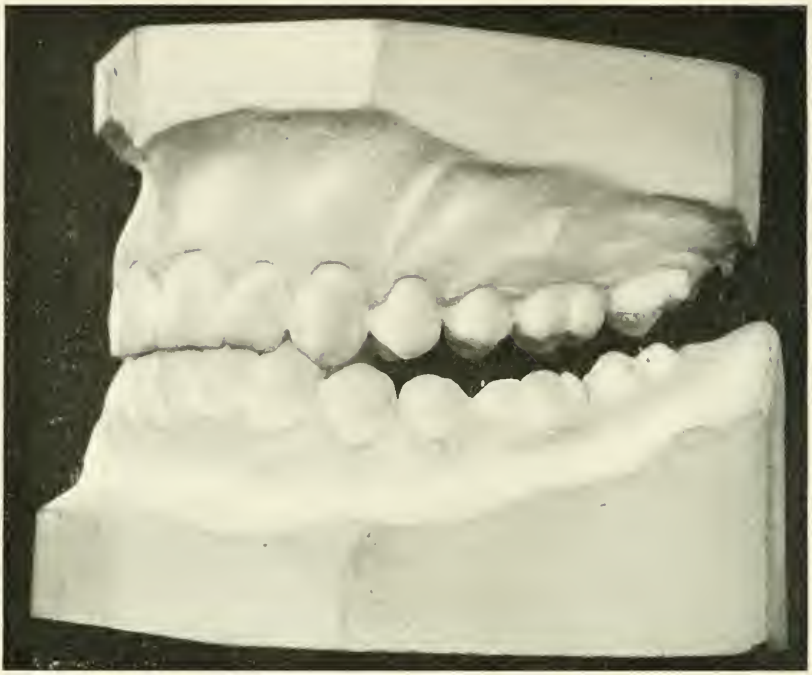

Fig 471.

Fig. 472.

the molars should not be ground off flat, but grooved for cusps as in grinding artificial teeth for articulation. The operation is a difficult one, in that it requires the greatest care not to grind too much upon certain teeth and not enough upon others. Occlusal contact points should be ground a little at a time, on one side of the arch and then upon the other, approximating the arches of teeth only a limited amount at each of several sittings until occlusion is obtained.

The shortness of the lips in these cases, especially the upper, is such as to preclude the idea of elongation of the incisors to occlusion, an unnatural length being unesthetic.

Infra-occlusion of Molars and Bicuspids.—Figs. 469 and 471 illustrate a Class I case of infra-occlusion of the molars and bicuspids from the practice of Dr. F. C. Kemple. This condition is a very unusual one, presenting as it does, with the incisor region in perfect normal occlusal relations and an entire lack of occlusion from the cuspid to the second molars on each side. The patient was fifteen years of age and the function of mastication was limited to the six anterior teeth, in each arch. Such peculiarities of abnormal development are hard to explain, yet the fact that they exist ought to bring to bear a much closer study of the underlying factors in development which produced them.

In the treatment of this case Fig. 473 expansion arches were adjusted to each arch, using the first molars as a primary anchorage for the clamp bands, banding the eight bicuspids, with spur extensions over the expansion arches above and below, and allowing the incisors and cuspids to remain free from ligation, as they were not to share in the movements to be undertaken.

Intermaxillary elastics were then adjusted between spurs on tubes of the molar clamp bands and from each expansion arch in the region of the first bicuspids.

The after-treatment models of the case are shown in Figs. 470 and 472, showing the molars and bicuspids have been drawn into occlusion with each other, and a very successful result obtained. The retention consisted of a continuation of the use of the intermaxillary force in connection with a more delicate and inconspicuous appliance for an indefinite period.

Use and Limitations of the Removable Appliance.—The author advocates the use of the removable appliances with the spring clasp attachments for anchorage only in the simpler cases of malocclusion.

The multiplicity of finger springs in the Jackson spring clasp appliances

when used in a complicated case where a great many individual tooth movements are required, is contrary to the law of simplicity in construction and operation of appliances, and the use of intermaxillary elastics in connection with upper and lower spring clasp appliances in Class II and III cases is of doubtful practicability, owing to the instability of the anchorage, and to the lack of control of the individual teeth in each arch, as compared to the use of the expansion arch and molar bands in the same cases.

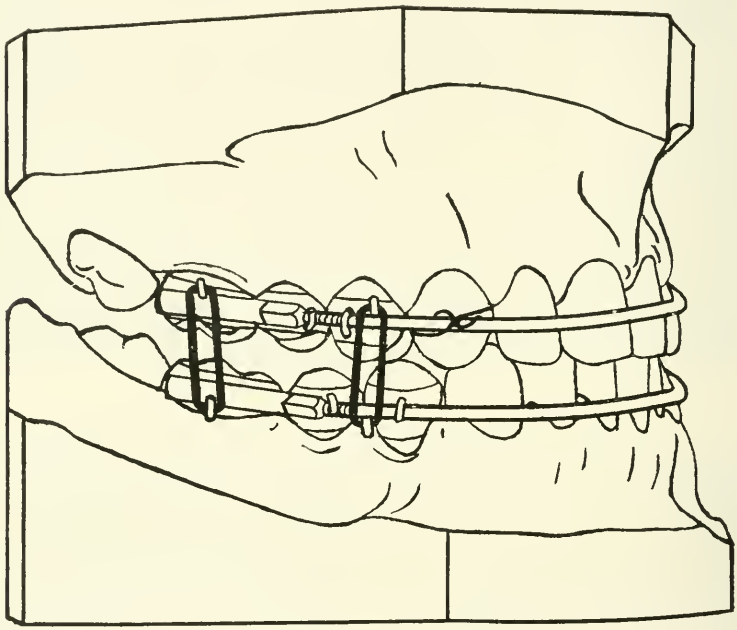

FIG. 473.

As an example of its consistent use in the treatment of a simple case of Class I, the spring clasp appliance shown in Fig. 474 is a fair specimen. It will be observed that but two teeth, the upper lateral incisors, are the objective of the finger springs of the appliance, and that there is sufficient space for the accommodation of these teeth in the arch.

The front view of this case, before and after treatment, is illustrated in Fig. 475, the operation having been accomplished in a few days, with no inconvenience nor discomfort. If properly made, the anchorage of the spring clasps and partial spring clasps is sufficiently stable for performing certain tooth movements, and the possibility of

removal by the patient is so infrequent in practice as to not seriously discourage the operator to make use of these appliances on this account.

In cases where teeth are out of the line of occlusion, in contracted arches, the removable spring clasp appliance is not the simplest in

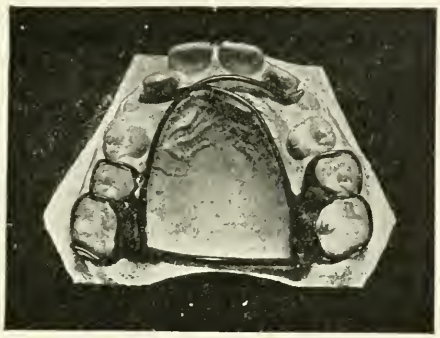

FIG. 474.

construction nor operation, nor is it efficient in comparison with a fixed appliance of the nature of the buccal expansion arch anchored to molar clamp bands.

Protrusions of Class I.—Fig. 476 illustrates an upper protrusion of Class I, which was treated by the use of intermaxillary anchorage,

FIG. 475.

allowing the upper expansion arch to be free in its distal movement by loosening the nut in front of the anchor tubes, so that all of the pressure from the intermaxillary force could be exerted against the labial surface of the upper incisors. At the same time, the ligation of the in-

cisors, cuspids and bicuspids to the arch assisted in restoring the normal line of occlusion.

An interesting feature of this case was a comparative test in the methods of treatment between a Jackson removable appliance with

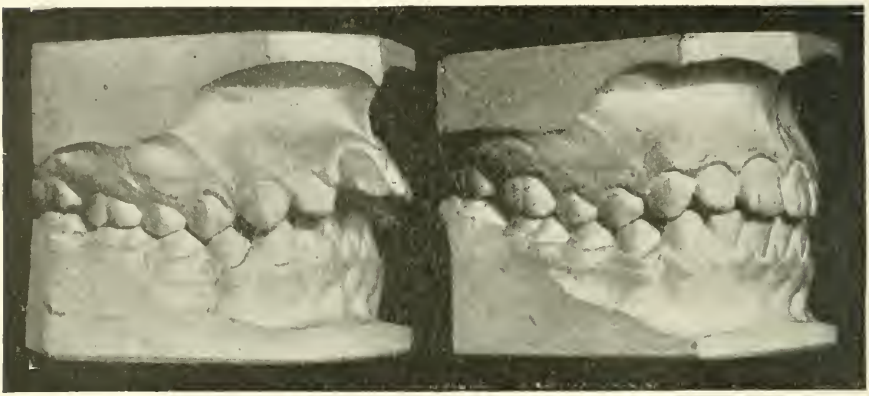

Fig. 476.

spring clasp attachments, as shown in Fig. 477, in position on the upper arch after completion, where it was finally used as a retainer, and the expansion arches in combination for the utilization of intermaxillary

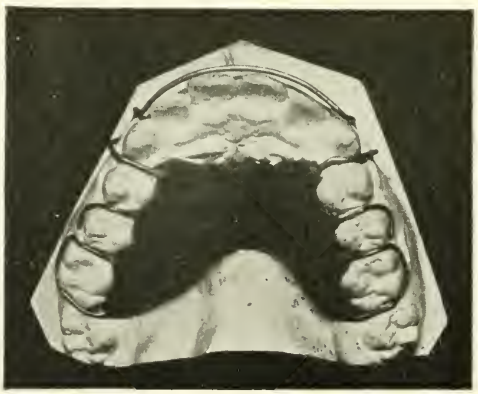

Fig. 477.

force in reducing the protrusion and restoring the normal occlusal relations of the anterior teeth.

The treatment with the removable appliance was inaugurated first, with the result that although the incisors were easily retruded up to a

certain point, the ineffectiveness of this appliance for completion of the case was distinctly noticeable, in that it had the effect of crowding the incisors together, or "buckling" them, with no remedy with except the possible making of a new appliance of the same pattern with a number of finger springs attached to overcome these tendencies, with the possibility of other changes in position of the individual teeth which might not be under control of these springs.

The application of the expansion arches, and the utilization of intermaxillary force and anchorage at this stage immediately alleviated all of the difficulties met with in the previous method of treatment and brought the case through to a successful completion.

The expansion arches in position (on the casts) with the intermaxillary elastic stretched from the distal end of the buccal tube on the lower molar clamp bands to the hooks on the upper expansion arch are illustrated in the drawing in Fig. 478.

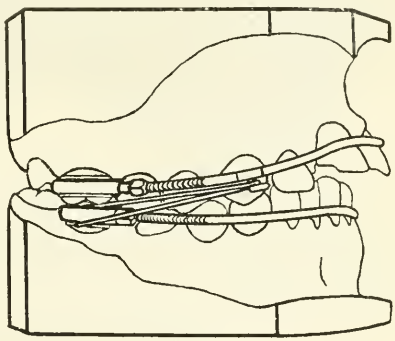

Fig. 478.

The resistance of the entire lower arch was enlisted by ligating all of the eight anterior teeth to the lower expansion arch, allowing the nuts to be unused except occasionally for slightly increasing the tension of the expansion arch to slightly widen the anterior portion of the lower arch.

By allowing the expansion arch to slide distally in the anchor tubes on upper molar clamp bands, all of the intermaxillary force was directed against the labial surface of the incisors, and by the use of ligatures in proper places, lateral expansion in the cuspid region was instituted, and the normal occlusion of the anterior teeth restored.

A similar protrusion of Class I to that just described but of greater severity, is illustrated in Figs. 479 and 480, before and after treatment.

In addition to the protrusion of the upper incisors, the lower arch was contracted in the region of the second bicuspid which was unerupted, and its space in the arch considerably diminished on account of the early loss of the second deciduous molar.

Exactly the same method was used for reducing the anterior upper protrusion as in the previous case, at the same time enlarging the lower arch and regaining the space for the unerupted bicuspid.

In the retention of the upper arch, a retaining plate similar to the

one used in the previous case was worn for three years, after which time no tendency to the return of the protrusion was apparent.

The lower arch needed retention only in the region of the unerupted bicuspids, and this was accomplished by bands upon molar and first

Fig. 479.

bicuspid on either side united by a soldered spur on the buccal surface, the bands being firmly cemented in position. The failure of the bicuspids to erupt after three years' retention required permanent bridgework for further retention of this space on either side, and the family

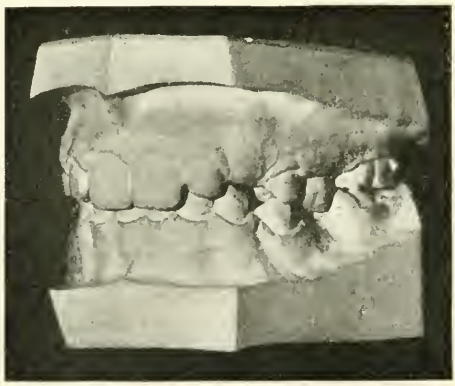

Fig. 480.

dentist constructed a permanent all gold denture on each side supported by the molar and first bicuspid as abutments.

The patient had been a mouth-breather in early childhood, but had been operated upon for the removal of adenoids early enough so that

through the restoration of the normal in occlusal relations of the arches of teeth, the asymmetry of the facial lines was completely overcome, as is evidenced from the photographs of the profile in Figs. 481 and

FIG. 481.

FIG. 482.

482. The asymmetry of the facial lines in this case is so similar to the most severe types of the first division of Class II, that a differential diagnosis cannot be made without a diagnosis of the cusp relationship of the arches of teeth in occlusion.

FIG. 483.

Fig. 483 illustrates a not uncommon case of this class in which the characteristics of Class III are simulated in the apparent protrusion of the lower arch, and the inharmony of the facial lines.

In the treatment of this case, anterior expansion of the upper arch alone was necessary, with bands upon the lateral incisors, and ligatures so directed and manipulated that the space for the unerupted cuspids was regained, after which a lingual retaining plate was used for retention, a buccal spur extending through the cuspid spaces.

The profiles of this patient, before and after treatment, in Figs. 484 and 485, show the result of the treatment in restoring harmony to the face, and contrasts the error of diagnosis from the facial lines alone, as

FIG. 484.

FIG. 485.

a casual observance of the profile alone would indicate a protrusion of the lower arch characteristic of Class III.

An unusually complicated malocclusion of Class I, the correction of which was successfully completed by Dr. M. T. Watson by the use of a unique appliance, is illustrated in Fig. 486 before treatment. The requirements of treatment were that the upper arch should be expanded on the left side, and the lower arch on the right side, and the use of the expansion arches in the ordinary way would have been impracticable.

Clamp bands were fitted to the upper left first molar, and first

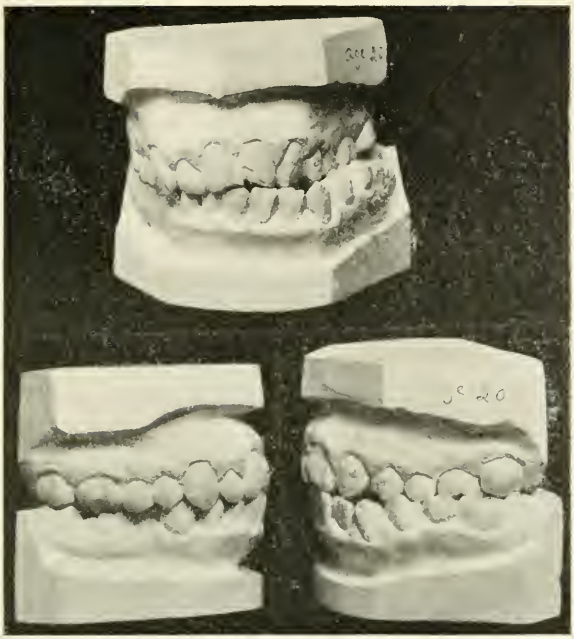

FIG. 486.

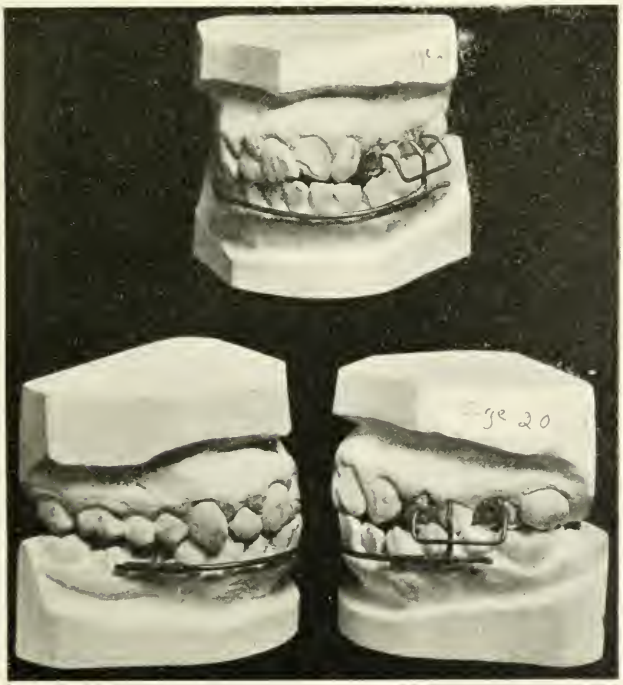

FIG 487.

bicuspid, to the buccal surfaces of which was soldered a rigid iridio-platinum wire, bent as shown in Fig. 487.

The lingual screws of these clamp bands engaged the lingual surface of the upper second bicuspid, so that the three teeth must move, buccally en masse, on application of lateral expansive force.

The lower right second bicuspid, which was itself in lingual occlusion, was used as base of anchorage for a lower expansion arch, which slipped into the buccal tube of a clamp band upon the bicuspid, and, extending around to the left side of the mouth, engaged with the upper appliance by means of a stiff upright bar of iridio-platinum, this latter having first been hard soldered to a short section of German silver tubing, which, in turn, was soft soldered to the expansion arch.

Bending the expansion arch so as to give it the greatest amount of lateral spring, the tendency of the appliance was to force the three upper teeth buccally, and to bring the lower right second bicuspid into line.*

A few weeks' wearing of this appliance restored the normal buccolingual relations on both sides, so that the case could be finished by the substitution of the expansion arches, and the treatment carried on in the usual way.

TREATMENT—CLASS II.

Etiology and Diagnosis of Class II.—The distinguishing characteristic of Class II in occlusal relations, is the bilateral or unilateral distal occlusion of the lower arch, the upper arch being narrow with protruding incisors in the first division, and retruded incisors in the second division.

The facial profile is deficient in contour in such a way as to be indicative of the malocclusion, the chin and lower lip receding, and the upper lip protruding, in the first division of this class, as illustrated in Fig. 500.

In the second division, a marked recession of both upper and lower lips and chin is noticeable, as in Fig. 523.

The habit of mouth-breathing, and the open and drooping mouth, the short upper lip, the receding chin and the facial expression, are peculiarly diagnostic of the first division of Class II, although it is

*A slight modification of this appliance was successfully used by Doctors Hoff and Burrill, on a little patient less than five years old who had lost a section of the lower jaw, extending from the cuspid region on the right, around to the ramus on the left. The remaining portion of the mandible on the right side, had become so much displaced as to be biting completely inside the upper teeth. Considerable difficulty was experienced in securely fastening the appliances to the deciduous teeth, but that was finally overcome, and occlusion established on that side of the mouth where teeth were present.

sometimes difficult to distinguish it from the mouth-breather of Class I by observance of the facial inharmony alone.

The presence of adenoids and enlarged tonsils is sufficient evidence of the causative factors underlying the mouth-breathing, which should receive early operative treatment by the rhinologist.

The study of the possible etiology of the particular malocclusion manifested in Class II cases is important to the diagnostician, as upon his ability to recognize the chief causative factors present in these conditions rests his success or failure in their treatment.

Following the history of this class of cases to a period when certain arrested developmental conditions were inaugurated, it may be stated that consecutively, arrest of development first occurred in one or both

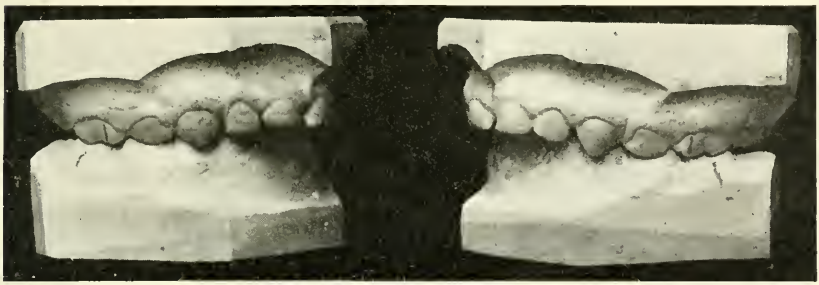

Fig. 488.

of the dental arches, and secondly, the later growth of the dental arches was along abnormal lines influenced by such factors as malocclusion of the inclined cusp planes, and in many cases by the habit of mouth-breathing, with its abnormal tension of muscles.

In a careful study of these conditions, the author believes that there is a predisposition to the malformation of dental arches and the distal occlusion in these cases long before the eruption of the permanent teeth to occlusion.

It has been stated by Dr. Angle that many cases of distal occlusion owe their inception to the abnormal influence of the inclined cusp planes of the first permanent molars in erupting, the exact period of their departure into the abnormal or distal occlusion being within a very short period after the touching of antagonizing cusps of these teeth. (See Angle—Malocclusion of the Teeth, seventh edition—pages 115, 116, 449, 454, Par. 3.)

The existence of distal occlusion of the deciduous arches ought to contradict this theory, in whole or in part, since certain persistent

factors other than any cusp influence must have been pre-operative in establishing these conditions in the deciduous arches.

That distal occlusion is not uncommon among children of less than six years of age is a fact which the model cabinets of the specialist in orthodontia can easily prove.

Treatment of these conditions of distal occlusion in the deciduous arches is established upon the same basis of normal restoration of occlusion and development as with the dental arches which contain at least the four permanent molars of the second dentition.

Fig. 489.

Figs. 488 and 489 illustrate a distal occlusion and facial profile of a child, two years and ten months old.

Not only is the distal occlusion of considerable extent, but the facial inharmony easily noticeable at this age.

It is the author's opinion that the large majority of cases of distal occlusions are initiated during the retention of the deciduous teeth, and the impress of arrested function and growth so made upon the developing structures of the maxillæ, that none but artificial stimulus could again restore the normal in developmental conditions.

It is possible that holding the mouth open in mouth-breathing

gives the mandible its distal pose in these cases, and it is certain that in those cases of Class II, Div. 1, presenting the shortened upper lip, the abnormal tension of the muscles is an etiological factor in the narrowing of the upper arch, which latter is, of itself, an effectual barrier to a forward pose of the mandible.

In the treatment of certain cases of Class II, Div. 1, it has been not infrequently observed that after a sufficient expansion of the upper dental arch, especially in children under ten years of age, the mandible moves forward of its own volition until the first molars are in correct mesio-distal relations.

Recognizing the possibility of arrested or deficient development of the maxillary arches being primarily due to such a general cause as malnutrition, or as caused by such local conditions as nasal stenosis and mouth-breathing, it will be admitted that the time the interference with development occurs will bear a certain definite relation to the period of deficiency in local associated functions of the oral and nasal cavities or of the general nutritive functions.

Dr Ottolengui very aptly states this theory in the following manner: "Malnutrition is the special cause of malocclusions of Classes II and III. The permanent teeth do not displace those of the primary set, but erupt into a larger, and what is more important, an entirely different arch, and the bony process is a new bone built about them during their eruption. Grant this hypothesis, and it is evident at once, that if, during this period of transformation, there be an interference with normal functions, there may and probably will be a lack of bone building nutriment. What will result? The permanent teeth, all larger than their predecessors, erupt into the same small arch which the temporary teeth had occupied, or into one insufficiently enlarged, because of insufficient nutritive elements."

"*Thus the consequent malocclusion of the teeth will be in nature and degree constantly related to the extent and time of the disturbance in nutritional functioning.*"*

Intermaxillary anchorage is secured by the attachment of the rubber ligatures from the hooks on the upper expansion arch to the ends of the tubes on the lower expansion arch, as illustrated in Fig. 490. In simple cases of this class the first permanent molars may be used for attachment of clamp bands in case the second molars are erupted, since the intermaxillary force can be made strong enough to move the upper molars distally and the lower molars mesially.

*Ottolengui, "A Contribution to the Etiology and Treatment of Class II" Transactions of the American Society of Osthodontists, 1907.

In extreme cases of this class, however, and especially those in which it is desired to move the upper molars distally, to any extent, the clamp bands should be placed on the upper second molars and shifted to first molars as soon as desired movement of second molars has been accomplished. During the use of intermaxillary force for shifting the molar occlusion, the front of the upper expansion arch should be kept free from the anterior teeth by tightening up the nut in front of the anchor tubes so as to apply the greatest amount of force directly to the molar teeth.

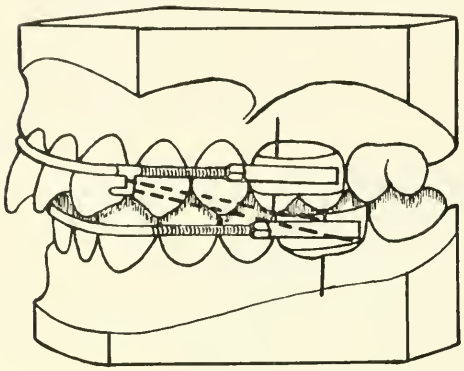

Fig. 490.

In the more severe cases of the first division of Class II, it will be necessary to remove the clamp bands from the upper first molars and place clamp bands on the upper second and even first bicuspids in succession for support of the expansion arch and further shifting of the occlusion in the bicuspid region.

The strength of the intermaxillary force can be increased by using a heavier ligature or a number of the same size, cut from French tubing. While these manipulations of anchor bands and expansion arches are being carried on in the upper arch, the entire lower arch may be used part of the time as resistance for the shifting of the upper molar occlusion, by the ligation of a sufficient number of teeth to the lower arch to insure its stability.

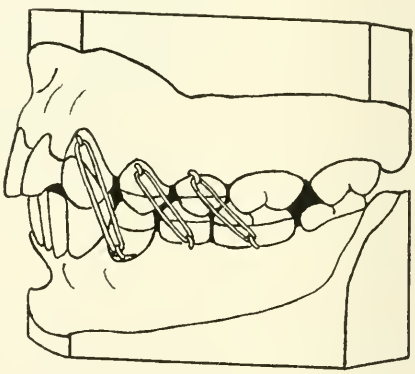

Fig. 491.

Again the lower incisors may be ligated to the expansion arch and moved forward, and successively, also, the cuspids and the bicuspids, to secure direct application of the force from the turning up of the nut in front of the lower anchor clamp bands, these teeth, in turn, being moved mesially by the intermaxillary force.

There is one very important detail in the manipulation of this

anchorage in Class II and III cases which ought to be described in this connection, and that is the tipping backward of the upper molars in Class II, and the lower molars in Class III—and the tipping forward of the lower molars in Class II, and the upper molars in Class III—which in turn shifts the expansion arch upward or downward, as the case may be.

To remedy this, and keep up the efficiency of the anchorage, the clamp bands should be removed and the angle of the inclination of the tubes changed according to the necessities of the case and the class. Fig. 598 A exhibits the tipping of upper molars and downward inclination of the expansion arch in a case of Class II, and B the restoration of the arch to position after realigning of the tube on molar clamp band. The technique of this operation is described in the chapter on constructive technique, being illustrated in Fig. 599.

In shifting the occlusion from distal to normal in some cases in which the permanent teeth are nearly all erupted, it will be found that although the molars may respond readily to the intermaxillary force, the cuspids and bicuspids, especially in the upper arch, may not be so easily moved in the desired directions through the application of the elastics from the hooks upon the upper expansion arch to the distal ends of tubes on lower molar clamp bands. In these cases, Dr. F. M. Casto has suggested the use of intermaxillary elastics between individual banded teeth of the upper and lower arch to overcome the difficulty, as in Fig. 491, and their use in this manner has been attended with very gratifying success.

Excessive Overbite.—A feature of no small importance in many cases of distal occlusion is the excessive overbite in the incisor region, which, if not overcome, will militate against the success of the treatment through the abnormal action of the inclined cusp planes of the incisors.

Often, the lower incisors will be completely hidden from view by the upper incisors, in some cases striking the gums lingual to the upper incisors and causing absorption of the soft tissues. Again, it will be observed that the lower incisors occlude with the gingival ridges of the upper incisors, enhancing their protrusion, and initiating an inflammatory condition of the peridental membranes of the upper incisors.

A rational method of treatment consists in the wearing of an appliance which will depress the incisors in their sockets through the opening of the bite by means of an inclined plane in the incisor region, which at the same time allows of natural elongation of the molars and bicuspids.

The bite plate with inclined plane and with flat metallic hooks extending over edges of upper incisors, illustrated in Fig. 492, is of value in these cases in which the upper and lower incisors need such depression in their sockets. This plate may be worn either before or after the application of the expansion arches.

An esthetic modification of this principle has been embodied by Dr. Norman Reoch in an inclined plane of 26 gauge clasp metal, soldered to the lingual surface of gold bands, cemented upon the upper central incisors, Fig. 493. Dr. Reoch also reports the shifting of the occlusion from distal to normal in two cases with this appliance, and its use for the retention of simple cases of distal occlusion after treatment.

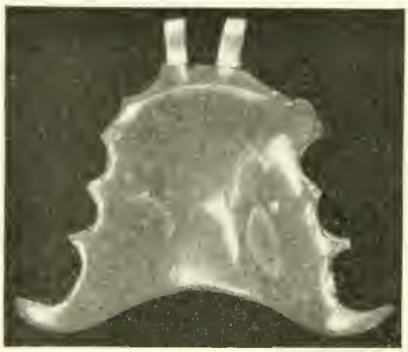

Fig. 492.

Treatment of Class II; General Considerations.—Inasmuch as mouth-breathing is so commonly co-existent with distal occlusion, its diagnosis in any case should be followed by an examination of the nasal and pharyngeal passages by a competent rhinologist, and removal of respiratory obstruction if found.

Tongue and lip habits should be noted and their effects counteracted as soon as possible.

Technique of Operative Treatment.—The operative treatment of Class II may be divided into two parts, the restoration of normal size and shape of the dental arches, and the shifting of the occlusal relations from distal to normal mesio-distal relations.

The restoration of the size and shape of the dental arches is secured by the application of the expansion arches as in Class I, and the shifting of the occlusion by the use of intermaxillary force and anchorage.

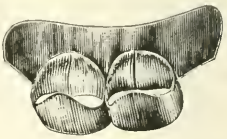

Fig. 493.

Treatment—Class II, Div. 1.—One of the most difficult cases of the first division of Class II which has come under the care of the author was that of a seventeen year old boy, the casts of whose teeth before treatment are illustrated in Figs. 494, 495, 496 and 497.

As will be observed, the occlusion of the lower arch was completely distal to normal, the upper arch narrow with protruding incisors,

and the lower incisors retruding and cutting into the gum tissue behind the upper incisors.

Mouth-breathing and abnormal lip function had assisted in perverting occlusal relations to such an extent that the possibility of their normal relationship seemed highly improbable. The expansion arches were adjusted as indicated in the treatment of this division of Class II, except that the upper molar clamp bands were placed upon

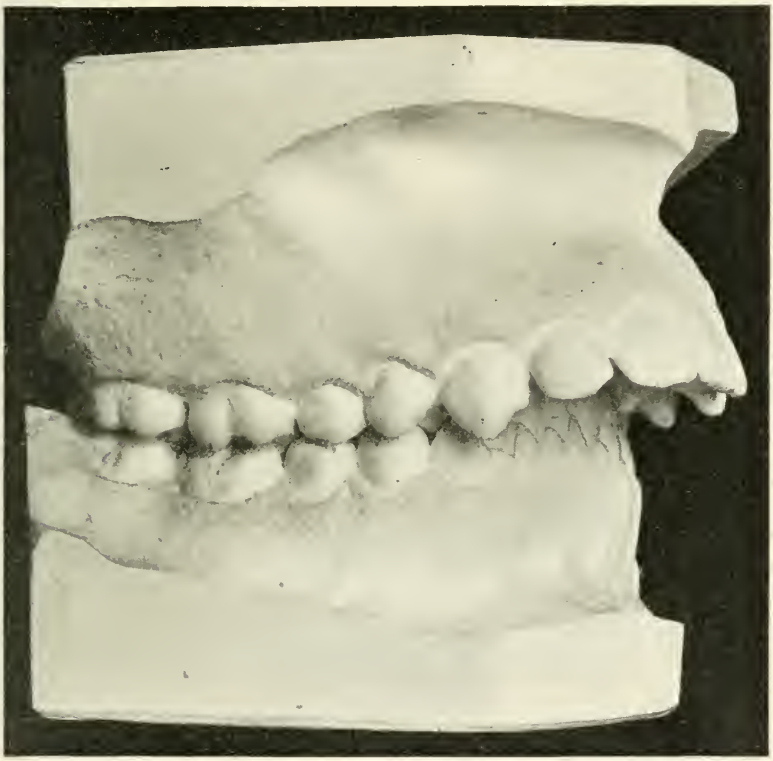

FIG. 494.

the second molars so as to accomplish their distal movement before that of the upper first molars, thereby conserving anchorage in the use of the intermaxillary force.

The lower first molars were used as anchorage for the lower expansion arch to which a sufficient number of the incisors, cuspids and bicuspids, were ligated to ensure the stability of the entire lower arch as anchorage in opposition to the distal movement of the upper second molars. After the upper second and first molars in succession

had been moved distally as far as it was deemed possible and practical, the upper second bicuspids were fitted with clamp bands and the intermaxillary force exerted upon them through the expansion arch resting in the tubes upon their buccal surfaces, the nuts in front of these tubes being kept tightened and the intermaxillary force being assisted in the distal movement of the bicuspids, as also in the previous movement of the first and second molars, by ligating the

FIG. 405.

upper incisors, cuspids and first bicuspids to the arch and turning up the nuts in front of the anchor tubes, thus pitting the anterior teeth en phalanx against the two teeth, either molars or bicuspids, which were being moved distally.

About this time, the greater part of the resistance in the distal movement of the upper teeth having been overcome, the necessity for the use of the entire lower arch as anchorage ceased, and operation for the labial movement of the lower incisors was begun by tightening

up the nuts in front of the tubes on the clamp bands upon the lower first molars, and this treatment was continued until the normal size of the lower arch was obtained.

A change in the adaptation of the lower expansion arch was then effected in order to depress the lower incisors and elevate the bicuspids, the expansion arch being sprung under hooks soldered to bands

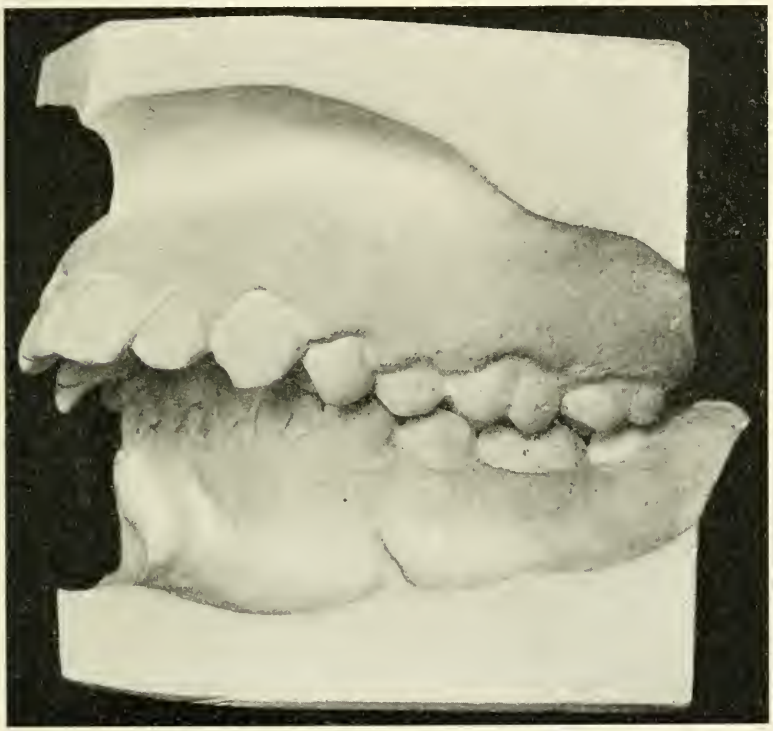

FIG 496.

upon these bicuspids, and over spurs soldered high up on the labial surfaces of incisor bands.

This change in the occlusal plane of the lower arch was effected in due time, and, in the interim, the upper first bicuspids and cuspids were successively fitted with clamp bands and moved distally, the expansion arch being shortened to fit the successively smaller arcs, and the incisors being allowed to share in the distal movement after they were no longer needed to re-enforce the anchorage.

Finally, it being found that the crowns of the lower incisors were inclining too much labially, their roots not moving forward enough

through ligating to a single arch, a partial second arch was hard soldered to the lower expansion arch, being dropped down by right angle segments until it was opposite to and about one-eighth of an inch labial to the necks of the lower incisors at the gingival line, and to this partial secondary arch the lower incisors were ligated, and through this leverage established, the incisal edges being firm against the primary

Fig. 497.

expansion arch, the apices of the roots of the lower incisors were gradually moved forward.

This completed the actual treatment of the case except for the adjustment of retaining appliances which consisted of the usual spur and plane upon the upper and lower first molars, as in Fig. 584, and a lingual arch retention for the upper incisors, as well as a special apparatus for retaining the lower incisor roots in their labial positions. The latter consisted of bands upon the two lower cuspids, connected by a lingual wire running across the lingual surfaces of the incisors below

the linguo-gingival ridge, and also connected by a labial wire extending across the labial surfaces of the crowns of the incisors near the incisal edges.

FIG. 498.

FIG. 499.

FIG. 500.

FIG. 501.

The perfect restoration of occlusion in this case may be noted in the after-treatment models in Figs. 495 and 497.

The remarkable improvement in the facial contour illustrated in Figs. 498, 499, 500 and 501, attest the value of perseverance and

persistence in the following out of a preconceived method of treatment, which, although similar for the majority of cases of this class, is of necessity somewhat varied according to the peculiar requirements of the individual case.

The treatment of this case covered a period of eight months' continuous wearing of the appliances, during which time the patient did not once complain of discomfort, attending school while in session, and during a stay of one month in the country gained several pounds in weight, the intermaxillary elastics being worn in the interval.

All retaining appliances were removed at the end of a year and a half, and a year after their removal, the occlusion was all that could be desired, having not shifted at all in its mesio-distal relations, and

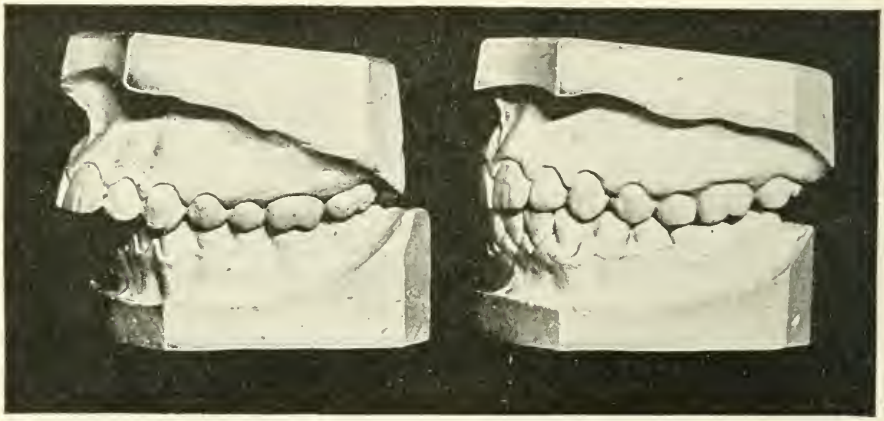

FIG. 502.

the subsequent development of the alveolar process around the roots of the lower incisors had effected a most desirable change in this region.

A very typical case of Class II, Div. 1, is illustrated in Figs. 502 and 503, the before-treatment models on the left exhibiting full distal occlusion of the lower arch, the protrusion of the central incisors in the upper arch, accompanied by all the displeasing and inharmonious facial lines of the mouth-breather as seen in the short upper lip, and the rolling of the lower lip under the upper incisors, illustrated in the front and profile pictures of the case before treatment in Fig. 504.

The expansion arches were adjusted to both upper and lower dental arches in a manner similar to the adjustment described in the case just preceding, except that considerable lateral spring was given to the upper expansion arch to obtain the effect of widening the upper arch posteriorly and retruding the upper incisors.

The treatment of the case was aggravated by the loss of the lower right first permanent molar, as it was necessary to regain this lost space by banding the second bicuspid and ligating it to the lower expansion arch by a spur soldered a little in advance of this tooth, and turning up the nut on the expansion arch until normal occlusal relations were established, the intermaxillary force on this side being made strong enough by doubling the elastics to resist too great a distal movement of the second molar.

The models on the right of Figs. 502 and 503 illustrate the very perfect occlusal relations which were established, and the pictures on the right of Fig. 504 exhibit the improvement in the profile as the result of treatment.

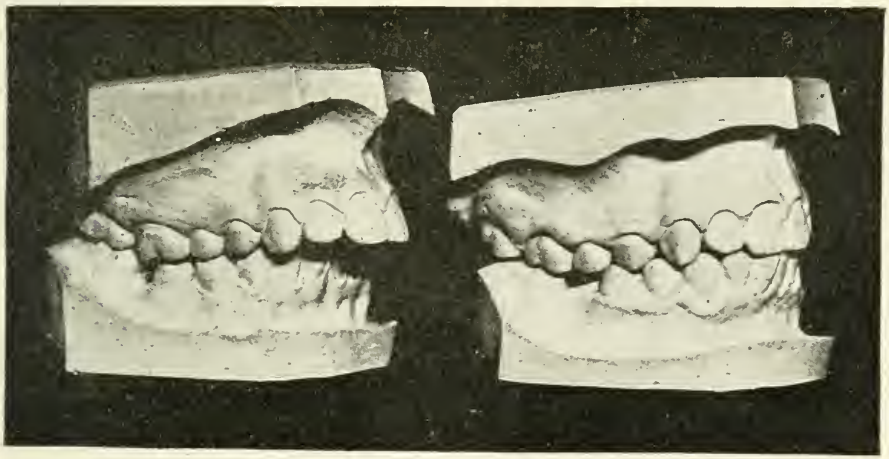

Fig. 503.

The retention in this case consisted of interlocking spurs extending from upper to lower molar clamp bands, the upper arch being also retained in its altered shape by a lingual arch connected with the upper molar clamp bands, and attached to incisor and cuspid bands.

Early Treatment of Class II.—The advantages of undertaking the treatment of Class II cases at an early age, about the time the first molars are erupted into occlusion, if not before, cannot be overestimated.

Much of the success of cases of this class treated at this early age is due to the careful oversight of the orthodontist during the shedding of the deciduous teeth and the eruption of their permanent successors.

A case of Class II, Div. 1, in which treatment was begun at nine

years of age, is illustrated in Fig. 505. The first permanent molars and the four incisors in each arch were the only permanent teeth erupted as indicated by the model at the top of the cut. In the treat-

Fig. 504.

ment of this case, besides the expansion and change of shape of the arches individually, the first permanent molars were immediately shifted in their occlusal relations until the correct relation of the arches

was established, as noted in the model on the left, making it possible for the normal eruption into occlusion of the remaining unerupted permanent teeth, which were very carefully watched during the retention period until their normal locking into occlusion was assured, and the final result, shown in the model on the right of the cut, obtained.

Of no small importance in the treatment of the cases of this class in which most of the deciduous teeth are still present is the development of the dental arches individually to a size which will be in better

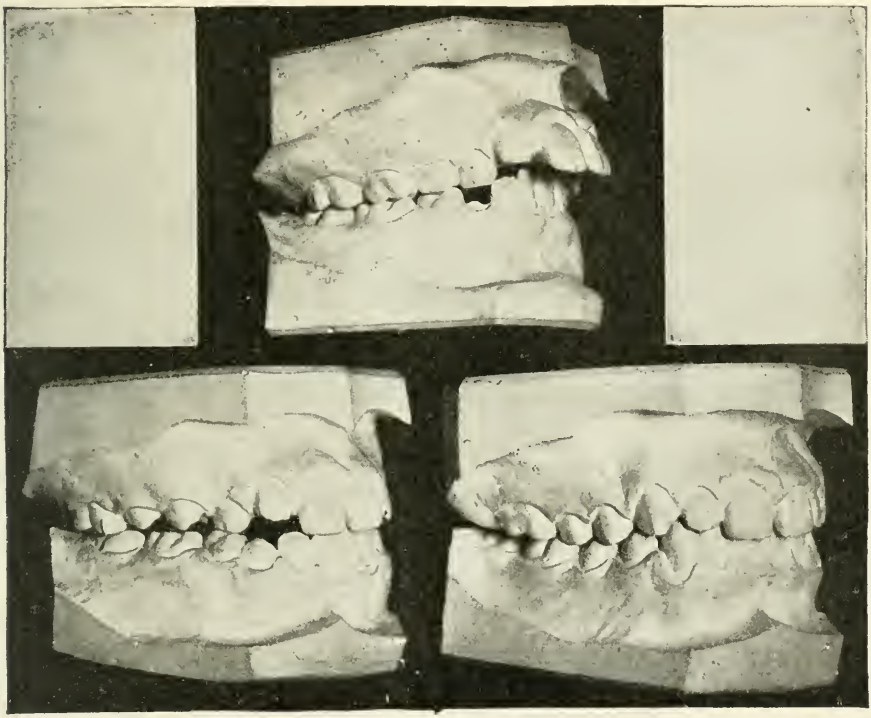

Fig. 505.

proportion to the arch of the permanent teeth as it should be when all of the permanent teeth are erupted. For example, in Fig. 506, the uppermost cast represents an upper arch of a case of bilateral distal occlusion in a child seven years old. Its uniform shape and size give no clue to the proper amount of development this arch should receive other than a slight anterior expansion for the accommodation of the lateral incisors. The treatment of this upper arch was carried out to the extent shown in the cast on the left of the cut while the occlusion was being shifted, and even at this stage, there was no indication

of the extent of development of this arch for the permanent benefit of the entire denture. At this time, the Hawley diagrams were called into use, that for .37 incisor being applied first to the cast before treatment, where it was seen that posterior expansion of the arch was indicated. Its reapplication to the second cast (on the left of the cut) revealed the fact that posterior expansion was indicated here, also, and lateral spring was used in the expansion arches until the measurement of the line of occlusion of the upper cast coincided with the pre-deter-

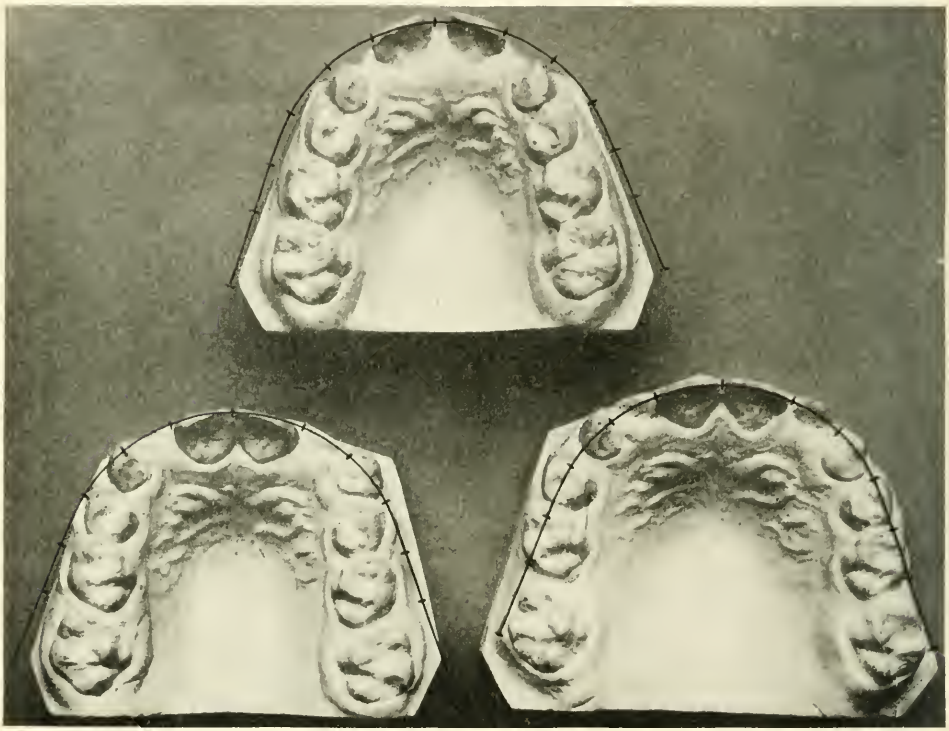

Fig. 506.

mined arch line of the diagram as seen in the cast on the right of Fig. 506.

The criticism might be made here that it would hardly seem advisable to enlarge an undeveloped dental arch in a seven year old child to a size which would correspond to that of an adult, but the results of added experience with this manner of development seem to bear out its advisability, especially when it is considered that there is some reaction during retention, and in those cases in which the arch is not over-expanded, as it were, appliances often have to be reapplied and added

expansion obtained for the accommodation of permanent teeth which still seem to be retarded in eruption for lack of space.

In the author's opinion, this is the ideal method of treating these cases, the lower dental arch being developed to correspond with the upper, and both retained during the period when the deciduous molars and cuspids are sufficiently firm to offer substantial resistance in retention, which would be during that period immediately following the eruption of the first permanent molars, and between the usual ages

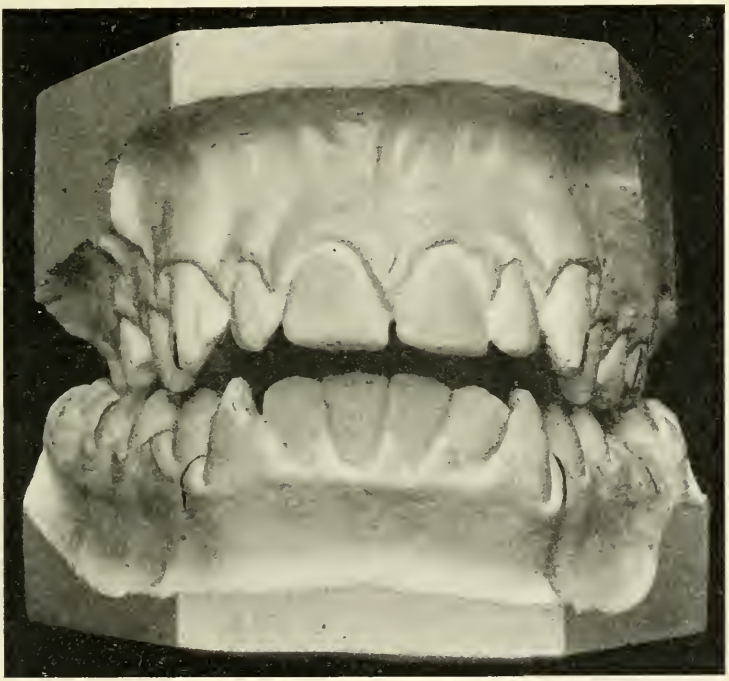

FIG. 507.

of six and eight years. During the period of shedding of the deciduous molars and cuspids, it is almost impossible to obtain proper lateral expansion of the dental arches, since the first permanent molars would be the only teeth at this time which could be laterally moved.

Class II, Div. 1, Infra-occlusion.—One of the most difficult complications occurring in any class of malocclusion is that of the open bite, or lack of occlusion extending from the central incisors distally sometimes as far as the first and second molars, the arches being separated anteriorly from one-sixteenth to one-half an inch, according to the degree of malformation present.

The inability to close the teeth anteriorly renders mouth-breathing more or less of a necessity, since lip function is almost entirely lacking in these cases, and the distortion of the features is much more displeasing than if only the distal occlusion were present.

The combination of open bite malocclusion and distal occlusion is such as to increase the difficulties of treatment, and sometimes to baffle the efforts of the most expert operator.

In the treatment of an open bite distal occlusion of the first divi-

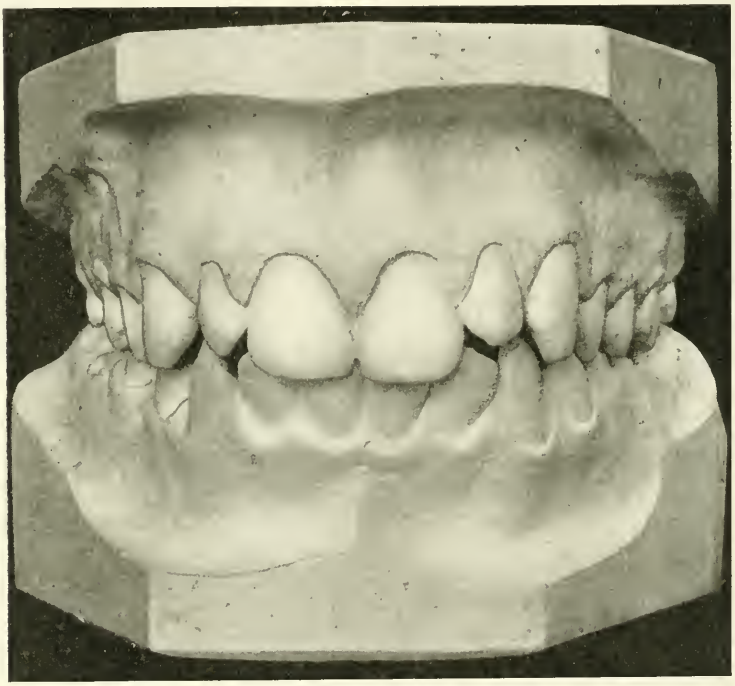

Fig. 508.

sion of Class II, the advisability of applying force for the restoration of the normal mesio-distal relationship simultaneously with or previous to the application of force for the closing of the bite, will depend largely upon the age of the patient and the extent of the separation of the anterior teeth.

In a child under twelve years of age, the greater possibilities of development and growth of the alveolar process and underlying bony tissues of maxilla and mandible, might call for much more ideal treatment than in a more mature person.

For example, the distal occlusion and open bite malocclusion would

respond readily to treatment, and if normal breathing and lip function were restored and an effectual retention of the restored occlusion be secured in the child under twelve, success in the attainment of ideal results may be somewhat assured.

In the adult the conditions for ideal treatment are very unfavorable, since, although it might be possible to restore the normal relations of occlusion and close the bite by the efficient use of intermaxillary force, the indefinitely continued use of the same force, with

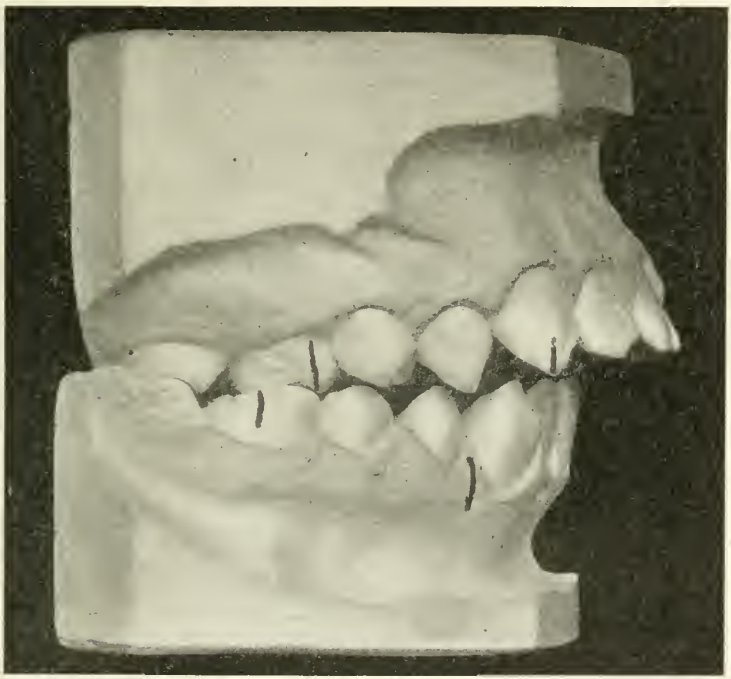

Fig. 509.

a multiplicity of bands and wires for the retention of the normal relationship, would render it somewhat unfeasible in the majority of cases.

However, there is a method of treating such a case which appeals to the author as reasonable and practicable, both from his own experience and from that of others, viz., to close the bite by grinding down the cusps of molars and bicuspids, allowing the front teeth to occlude.

To illustrate, in Figs. 507 and 509, is represented an open bite bilateral distal occlusion of a fifteen year old boy, an habitual mouth-breather, anemic in temperament, and with so few of the teeth in contact that mastication of his food was an impossibility. To add to the

difficulties of treatment, the upper right first and second molars were in lingual occlusion, and the lower left first molar was decayed away to the roots.

In order to be conservative of anchorage, the first step in the treatment was to bring the upper molars into buccal positions, and allow them to settle into occlusal relations with the lower molars before proceeding with the further treatment of the case.

The expansion arches and rubber elastics were then adjusted as in

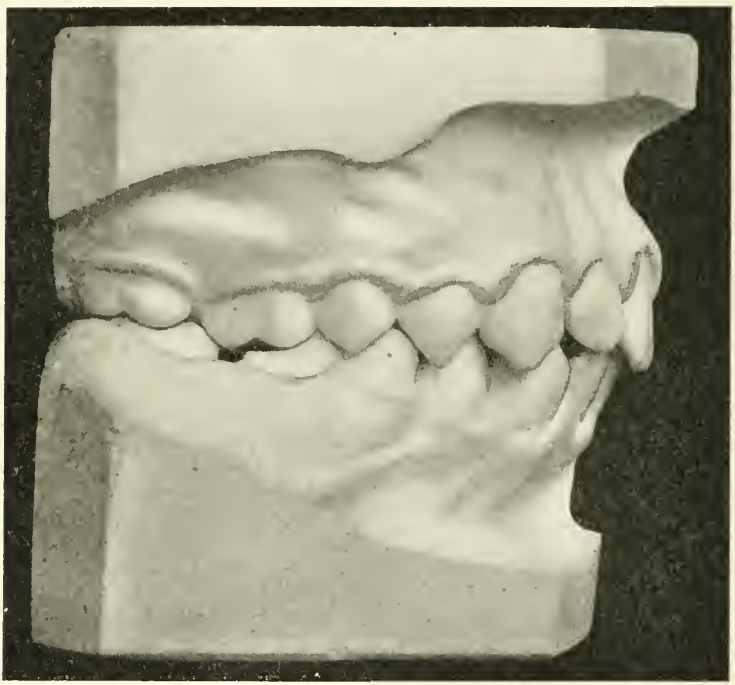

Fig. 510.

Fig. 490, for shifting the occlusion, which was successfully accomplished after a few months' treatment, but with the result that the anterior open bite was somewhat increased, as is usual in these cases.

Although not assured of successful retention of the mesio-distal relationship of the arches and the occlusion of the anterior teeth, intermaxillary force was applied between the upper and lower incisors, cuspids, and bicuspids, as in Fig. 511, with the result that although these teeth moved more or less readily into occlusion, the appearance was not as much improved as might be expected, the incisors elongating to an abnormal extent, and not carrying the process with them.

The intermaxillary force was withdrawn, and the anterior teeth allowed to settle back into their former positions, and the method of treatment changed in a manner that has proved of more permanent value.

The author conceived the idea of so grinding the molar cusps of both upper and lower molars to close the bite that the inclined planes could be made to act as a permanent retention for the restored mesio-distal relationship of the arches, and by very carefully grinding one cusp at a time, and exaggerating the distal inclines of the lower and the mesial inclines of the upper molar cusps, this desirable result was effected, having retained the normal mesio-distal relationship now for over six months without the aid of any appliance such as the interlocking planes usually used for the purpose.

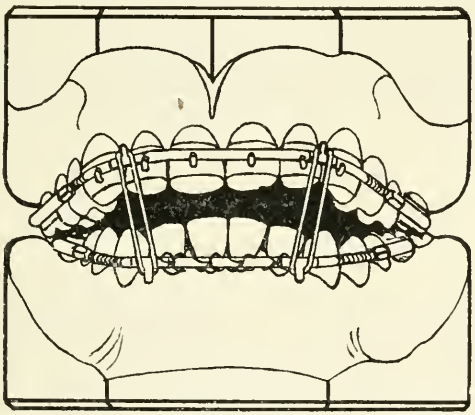

FIG. 511.

The front view of the restored occlusion may be seen in Fig. 508, and the effectual interlocking of inclined planes of the cusps of the molars and bicuspids in Fig. 510 is of more than passing interest in view of the difficulties surrounding this class of cases in which distal occlusion, open bite malocclusion, and the confirmed habit of mouth-breathing were such insurmountable obstacles to any other method of treatment.

One very gratifying feature of the treatment was that the boy had been examined by a rhinologist previous to coming under the author's care, and, although adenoids had been found, it was considered best to await the results of orthodontic treatment before they should be removed, and upon referring the case back to the nose and throat specialist, he was unable to find any adenoids, which was a surprise, as such an occurrence had not before been recorded.

The disappearance of these adenoids was no doubt due to the expansion of the upper arch, and restoration of normal occlusion, which gave better opportunities for normal breathing and better masticating function, so that the tonsillar growths were reabsorbed through a restoration of functions which meant increased metabolism and consequent improved nutrition.

The author has performed the operation of grinding the cusps of the molars and bicuspids in open bite malocclusions of the other two classes with very gratifying success, taking care that the inclined planes be preserved in the grinding, and be made to serve the purposes of articulation as well as occlusion by trying the articular movements of the mandible during the process, and seeing that the stress of articular mastication was properly supported by both buccal and lingual cusps of molars and bicuspids, as is done in the grinding of artificial teeth upon an articulator constructed upon the Bonwill principle.

In very severe cases of open bite malocclusion, it may be found necessary to devitalize the pulp of one or more of the molar teeth, since the pulp cavity will have to be partially encroached upon in order to do sufficient grinding to secure occlusion of the anterior teeth, and yet this need not be considered an objection in view of the benefits obtained through the proper performance of masticatory function, and the correction of the mouth-breathing habit.

Treatment of Class II, Div. 1, Subdiv.—The characteristics of the subdivision of Div. 1, Class II, are very similar in the general appearance of the dental arches to those of the full first division, the upper incisors being protruded, the upper arch narrow, and the facial disfigurement almost identical, the distinguishing feature of the subdivision being the unilateral distal occlusion, one lateral half exhibiting normal mesio-distal relations.

The treatment, therefore, follows along the same lines as if the occlusion was distal bilaterally, except that it is unnecessary to shift the occlusion on the normal side, although the intermaxillary elastics may be applied on that side to assist in balancing the forces on each side of the mouth.

Figs. 512 and 514 exhibit a case of Class II, Div. 1, subdivision, in which the right lateral half is in distal occlusion, the left being in normal mesio-distal relations in the region of the first permanent molars. The space for the eruption of the lower left second bicuspid being partially lost, through premature loss of the deciduous second molar, the lower left first bicuspid and cuspid drifted into this space until they occupied distal positions.

FIG. 512.

FIG. 513.

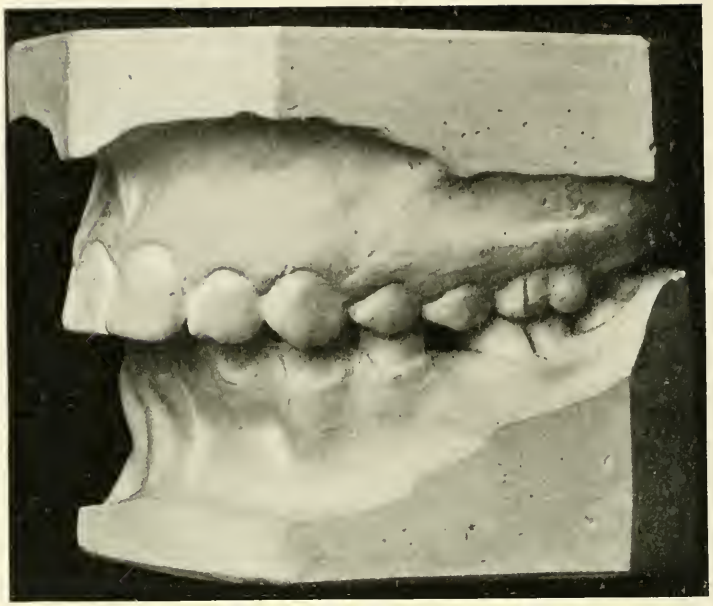

FIG. 514.

FIG. 515.

The expansion arches were applied in the same manner as described for the treatment of the full bilateral distal occlusion, the mesial force upon the lower left first molar being compensated by the distal force exerted by the expansion arch in forcing the lower left cuspid and first bicuspid mesially into their normal positions.

This latter movement was expedited by ligating from a lingual spur upon a band on the first bicuspid to a spur on the expansion arch slightly forward of the first bicuspid.

After restoring the size and shape of the individual arches, and

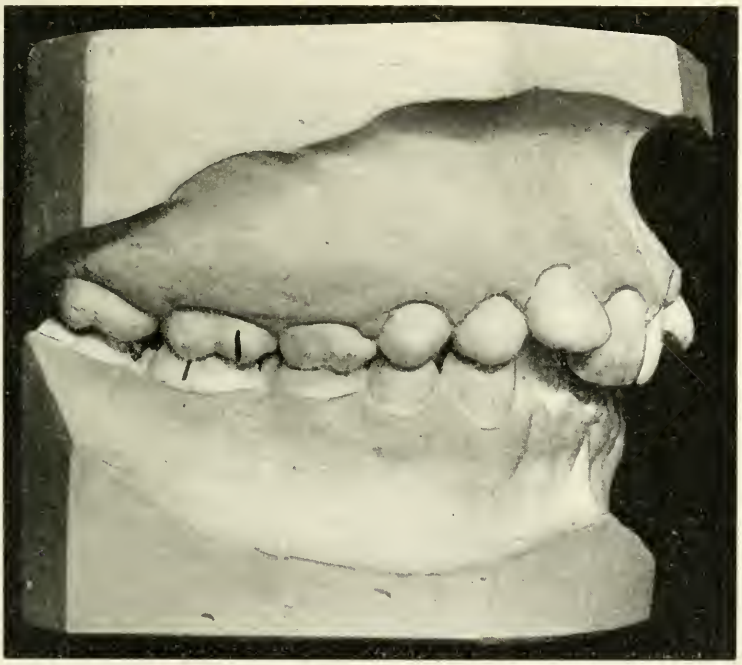

Fig. 516.

shifting the occlusion to normal relations, the result shown in Figs. 513, and 515, in right and left occlusion was obtained.

Intermaxillary retention was used in this case for a few months only, as the tendency of the dental arches was to remain in normal relations after normal occlusion and function of the occlusal planes had been restored.

Treatment, Class II, Div. 2.—The occlusal characteristics of the second division of Class II include a distal occlusion of both lateral halves of the dental arches, with contraction of the anterior portion of the upper arch, usually presenting with some of the upper incisors inclining lingually, or overlapping, as illustrated in the classification chart.

As with the first division of this class, the profile shows the effect of the distal occlusion, though not to such a marked degree, the lower third of the face being more uniformly receded from the normal pose.

Although cases of this division are usually normal breathers, it is not unusual to find mouth-breathers among them.

The distal occlusion in this division is probably in existence in the deciduous arches before the eruption of the first permanent molars, and the upper incisors are forced into lingual and overlapping positions through nature's effort to conform the arches to some uniformity in

Fig. 517.

size for better occlusion, the pressure of the lips being powerful factors in such arch conformation.

Fig. 516 illustrates the right occlusion of a case of bilateral distal occlusion in an eleven year old child, the upper central incisors inclining lingually and overlapped by the lateral incisors. In the treatment of this case, the intermaxillary elastics were applied for shifting the occlusion to normal mesio-distal relations, keeping the upper central incisors clear of the lower incisors by expanding the upper arch and moving the deflected central incisors towards their normal positions a little in advance of the mesial movement of the lower dental arch.

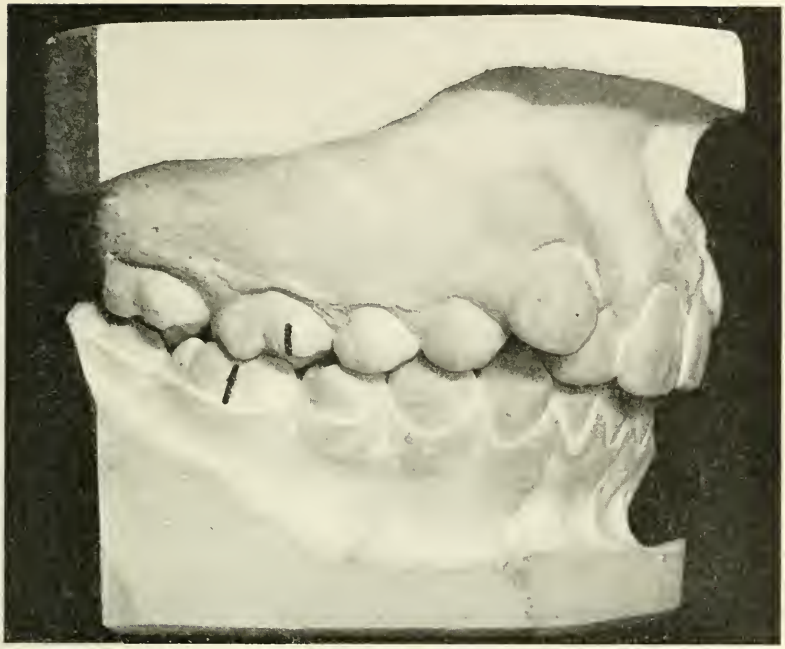

FIG. 518.

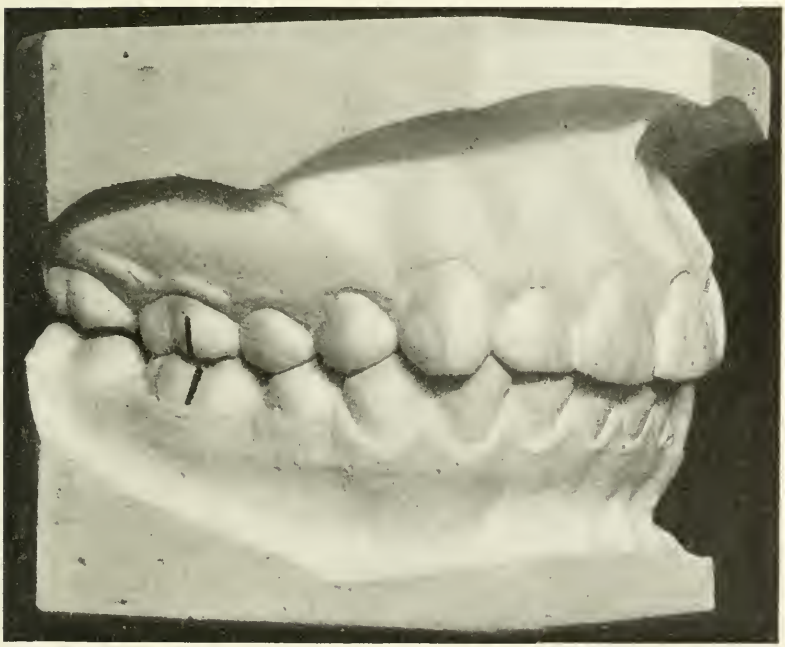

FIG 519.

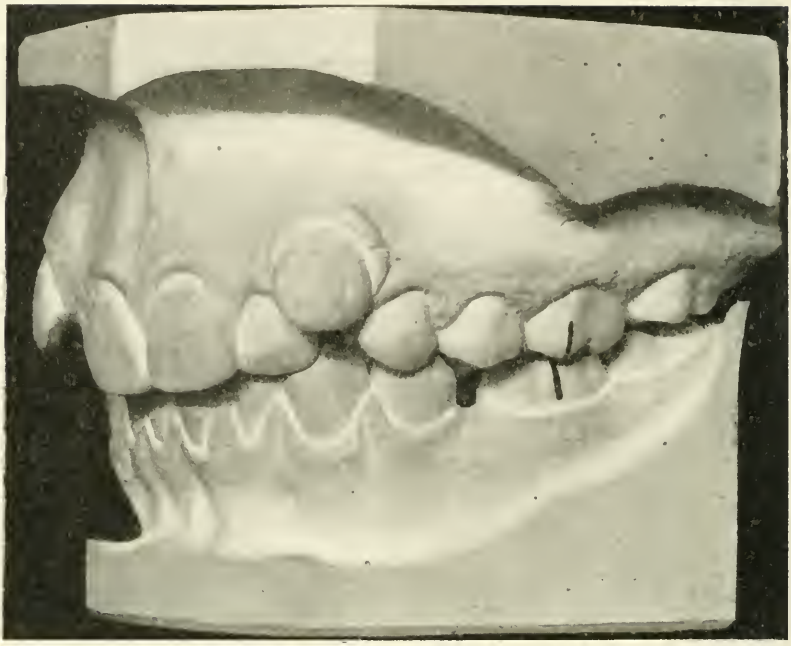

FIG. 520.

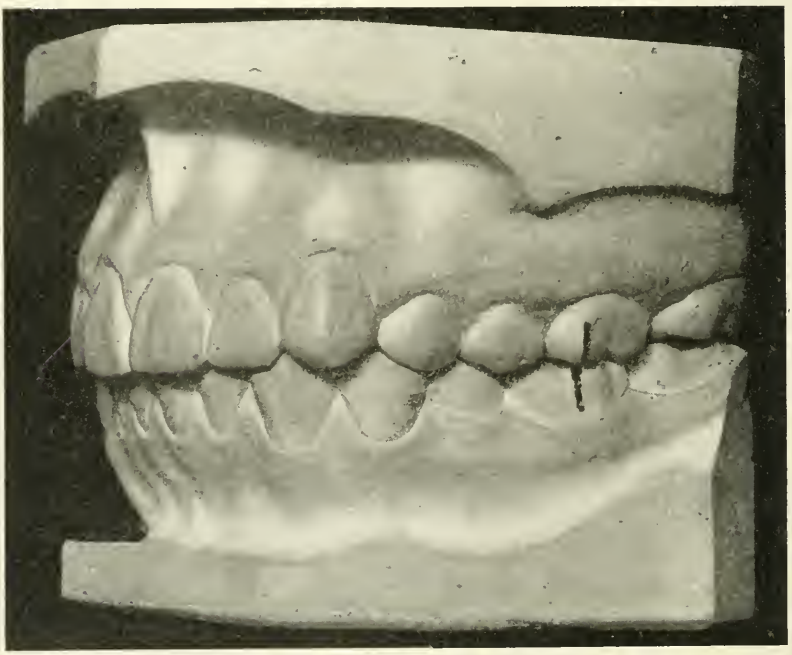

FIG. 521.

The restoration of normal relations of occlusion in Fig. 517 is of exceptional interest in that the mesio-distal relations of the arches were not artificially retained, the normal function of occlusal planes of the teeth being sufficient to hold the dental arches in their normal pose.

The only retaining appliance worn consisted of a lingual retainer for the upper central incisors, being attached to bands upon the lateral incisors.

Treatment of Class II, Div. 2, Subdivision.—The occlusal relations of one lateral half of the dental arches being normal in the sub-

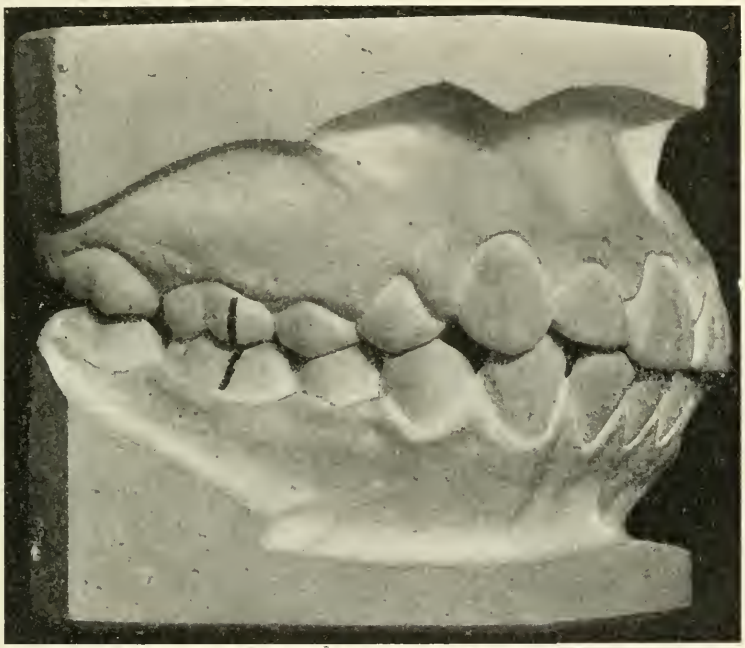

FIG. 522.

division of the second division of Class II, treatment for shifting the occlusion is necessary only upon the lateral half which exhibits distal occlusion.

Expansion of both arches, however, may be necessary, especially the upper arch.

A characteristic case of this subdivision is illustrated, before and after treatment, in Figs. 518 and 519, right occlusion, and 520 and 521, left occlusion.

The distal occlusion is on the right lateral half, and the apparent simulation of a distal occlusion on the left side is due to the closing up

of the space for the lower second bicuspid which is unerupted, allowing the first bicuspid to drift back until it is in contact with the first molar, carrying along with it by lack of anterior development, the cuspid and incisors on the left side.

An X-ray of the left side of the mandible revealed the presence of the second bicuspid in its proper place but, of course, unerupted.

Upon the adjustment of the expansion arches, the upper with hooks for the intermaxillary elastics, and the lower with a spur opposite the lower first bicuspid which was banded and ligated to the spur, the intermaxillary elastics were applied to both sides of the arches, that on the right being adjusted to shift the distal occlusion to normal,

Fig. 523.

Fig. 524.

and the one on the left to reenforce the lower molar anchorage which is to resist the force used to move the cuspid and bicuspid on that side forward in the line of the arch.

The treatment consumed nine months time, but in no other case has the author seen such apparent inclination of the teeth to movement into normal positions, and the arches to assume normal sizes and forms under the manipulation of the appliances as described.

Immediately upon the removal of the appliances, the case presented the appearance seen in Fig. 522, in which the anterior part of both arches seems to be abnormally protruded, a condition which it has been erroneously claimed the orthodontists of the "new school" are apt to obtain as a result of their treatment without extraction.

From four to six weeks after this model was made, the teeth had settled back through the guidance of the retaining appliances to the beautiful relations of occlusion shown in Figs. 519 and 521.

The before and after treatment profiles of this case, Figs. 523 and 524, show a decided improvement in the art relations of the face.

TREATMENT OF CLASS III.

Etiology and Diagnosis of Class III.—This class presents with bilateral or unilateral mesial occlusion of the lower dental arch, and, in the extreme, is probably the most disfiguring of any class of malocclusion.

The maxilla is usually considerably arrested in development, and the mandible protruded, with its incisors inclining lingually.

Most all of the cases of Class III are mouth-breathers, and nasal obstructions are unusually persistent.

Accompanying many of these cases is the condition of "open bite" malocclusion with its added difficulties of treatment.

The inception of mesial occlusion is during a very early period in child life, when it is least noticeable in the facial lines, and yet it is at this early period when the malocclusion should be diagnosed and the abnormal overcome conditions which are causative of it, if the most beneficial results are to be obtained.

In severe cases of this class, the angles formed by the rami and body of the mandible disappear, leaving almost a straight line from the chin to the ear.

These cases may usually be diagnosed from the profile, the mandible being protruded, and the upper lip receding, but they are simulated in appearance by the "apparent lower protrusions" of Class I.

The etiological factors are somewhat obscure, although it is believed that the habit of holding the mandible forward to assist in breathing has a strong tendency to cause the mesial occlusion.

The conditions of arrested development are usually persistent, the upper arch remaining small and undeveloped, and the lower arch changing in form according to the general direction of abnormal tension of muscles.

Technique of Operative Treatment.—The operative treatment of Class III may be divided into the restoration of the normal size and shape of the dental arches, and the shifting of the occlusion from mesial to normal relations.

The use of the intermaxillary force for shifting the occlusion is necessary, as in Class II, although the direction of the force and the

manipulation of the anchorage is exactly the reverse from that in the second class.

The direction and points of application of the intermaxillary force in treatment of Class III may be seen in Fig. 525, the elastics extending from the distal ends of the tubes on upper molar clamp bands, to the hooks on lower expansion arch.

The arches are illustrated without ligatures, so that the intermaxillary anchorage may be more clearly shown. In actual treatment, proper ligation of the teeth in both dental arches to the expansion arch should be made according to the tooth movements desired, and the degree of re-enforced anchorage necessary in either arch.

It is also necessary, in extreme cases of this class, to shift the anchor

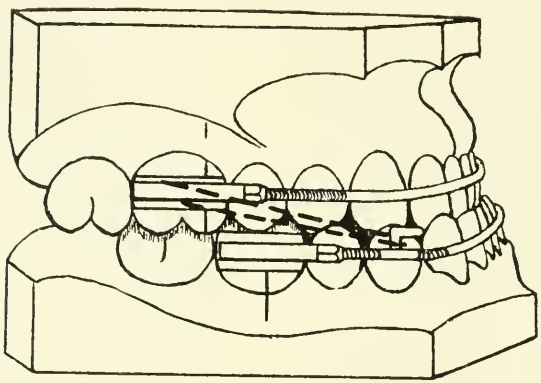

FIG. 525.

bands from first molars to bicuspids in the lower arch, in order to conserve anchorage and secure distal movement of the bicuspids.

Owing to the fact that mesial movement of the teeth requires less force than distal movement, appliances almost always operate to move the teeth of the upper arch mesially more than to move the teeth of the lower arch distally in these cases.

It is considered especially advantageous in this class of cases when there is present a deep overbite, or the overlapping of the upper over the lower incisors after shifting of the occlusion, as the increased length of the inclined cusp planes serve to more effectually retain the restored relations of occlusion than where but a short overlapping is present.

It is advisable to begin the treatment of this class of malocclusion as early as it is possible to manage the child, for with added years comes an exaggeration of the deformity, the mandible assuming a mere forward pose, and the shape of the bone and the relations of the muscles

becoming conformed to an abnormal condition which makes it much more difficult and sometimes impossible to completely overcome.

Treatment of Special Cases.—Figs. 526 and 527 illustrate

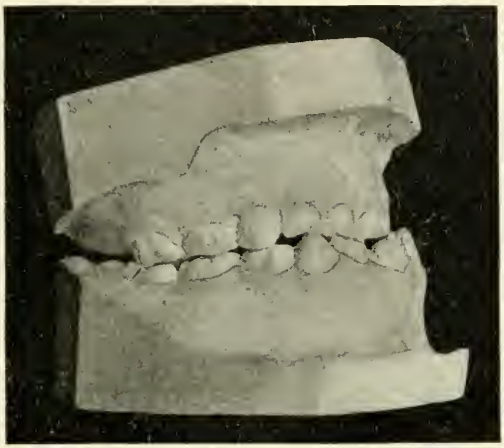

FIG. 526.

models of the case of the seven year old boy, from whose throat the adenoids and tonsils shown in Fig. 380 were removed at the beginning of treatment.

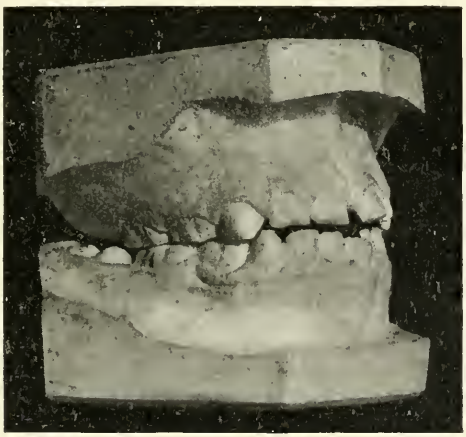

FIG. 527.

Small molar clamp bands were fitted to the diciduous second molars and the 17 gauge expansion arches adjusted as in Fig. 525, the intermaxillary elastics being attached well forward upon hooks on the lower expansion arch.

The occlusion was changed in a few weeks to that shown in Fig. 527 and a persistent retention by means of the buccal spurs was established, and the case dismissed to be seen only at intervals of a couple of months,

Fig. 528.

Fig. 529.

until the permanent teeth should erupt, in order that any untoward developments might receive immediate attention, should they arise.

The front and profile pictures are exhibited in Figs. 381 and 382 and 528 and 529.

After a year's retention, the development of the facial lines through

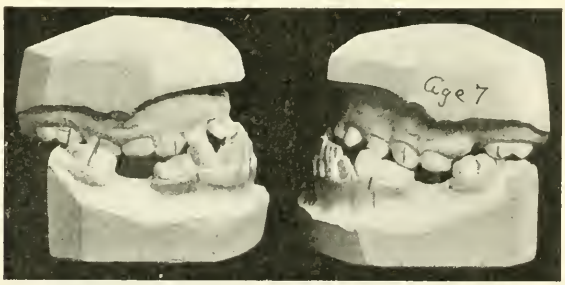

Fig. 530.

the establishment of normal functions of occlusion and respiration has been most gratifying.

Another case of this class, the before treatment models of which are shown in Fig. 530, and which was treated by Dr. M. T. Watson, is unusu-

ally interesting in view of the fact that the restoration of occlusion and facial lines was accomplished solely by means of the Angle chin cap and headgear, a combination which has fallen somewhat into disuse since the general adoption of intermaxillary force for the mesio-distal changes in occlusion.

FIG. 531.

Beginning with a very gentle elastic pressure for the first few days of treatment, two Number 33 Goodyear elastic bands were adjusted between headgear and chin cap on each side, followed in the course of a week by the substitution of a Number $000\frac{1}{4}$ for the lower of the

FIG. 532

two bands, which represented the maximum of force used in the treatment.

Aside from a slight crowding of the lower incisors, the results of about six weeks' treatment produced almost normal mesio-distal relations of the dental arches, the final occlusal relations established

being shown in Fig. 531. The necessity for the subsequent use of appliances inside of the mouth for perfecting the occlusal relations does not detract from the scientific value of the method just described for early treatment of this class of cases, especially as it is the only recorded case in which the treatment was confined solely to the use of the chin retractor, and therefore exhibiting "a change which must necessarily be confined to the shape of the mandible itself, or to a change in the temporo-maxillary articulation, or both, the latter probably being the case." (Watson.)

Fig. 532 illustrates the before and after treatment profiles of the case, the latter picture being taken about four months after the first one. The slight prominence of the lower lip in comparison with the

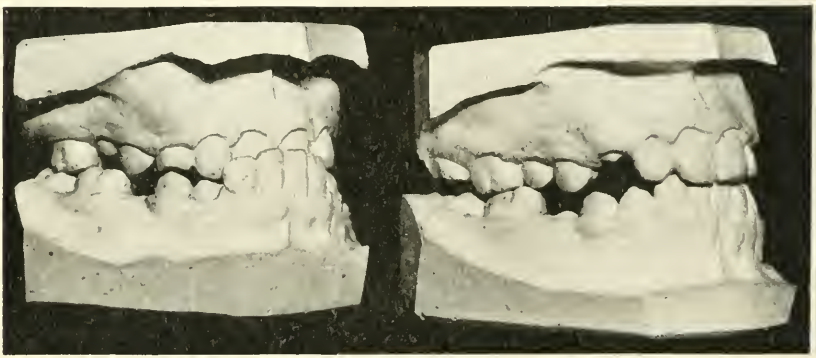

Fig. 533.

upper may be accounted for by the loss of the upper deciduous central incisors during the treatment, and the lack of the permanent centrals being sufficiently erupted to lend any contour to the upper lip.

A comparatively simple case of this class is illustrated in Fig. 533 before and after treatment (of the right side). This case was undertaken just as the bicuspids were erupting to occlusion and the change from mesial to normal occlusion as a result of treatment gave the cuspids and bicuspids an opportunity to complete their eruption into normal locking with the inclined planes of their antagonists.

The expansion arches were placed upon both upper and lower arches and the intermaxillary elastics stretched from hooks soldered well forward upon the lower expansion arch to the distal end of the buccal tubes upon the upper molar clamp bands, as in Fig. 525. When the upper incisors are but slightly distal to the lower incisors as in this case, the first effort should be directed to moving the upper incisors

into positions mesial to the lower incisors, so as to gain the advantage of the inclined planes of the lingual surfaces of the upper incisors acting upon the labial inclined planes of the lower incisors during the rest of the treatment, for until this change is made, the reverse action of the inclined planes of the incisors will tend to prevent a change in occlusion of the molars.

To accomplish this movement of the upper incisors, the lower expansion arch was securely ligatured to the lower incisors and bicuspids, and the lower arch used as a stationary anchorage, as it were. The upper incisors were then ligated to the upper expansion arch, the nuts in front of the anchor tubes turned up tight twice a week and the inter-

FIG. 534.

FIG. 535.

maxillary force being constantly in action, not only prevented the upper molars from distal movement, but hastened the mesial movement of the upper incisors.

After this change in the occlusion of the incisors was effected, the intermaxillary force continuing in action, produced the change from mesial to normal occlusion of the lower molars. It will be observed from the cut that some expansion of both arches was accomplished at the same time.

Even with such a slight change in occlusion as is exhibited in this case, a very decided improvement in the facial lines is seen in the comparison of the before and after treatment profiles in Figs. 534 and 535.

A much more difficult case than the one just described on account

of increased age and consequent greater density of alveolar tissues and conformation of occlusion and facial lines to abnormal conditions

FIG. 536.

FIG. 537.

is illustrated in Fig. 536, being the before and after treatment models observed from the left side.

Orthodontists have been cautioned against the possibility of ab-

normal eruption of the lower third molars during or after the period of distal movement of the lower second and first molars in cases of this class, and while it is advisable to observe unusual precautions to prevent any maleruption of these teeth, the experience of the author in

FIG. 538.

this case and other similar cases, leads him to believe that in the majority of cases the restoration of occlusion and consequent proper function of the maxillæ, may aid rather than interfere with the normal development of the third molars. The lower third molars in this case erupted

FIG. 539.

into their normal positions soon after treatment was finished, and with no more difficulty than if the operation had not been performed.

The change in the profile is apparent from a comparison of the before and after treatment pictures in Fig. 537.

Treatment of Unusually Complicated Cases of Class III.—

There are many cases occurring in practice which seem to be exceptionally difficult to diagnose and treat on account of the loss of many of the permanent teeth, and the consequent complications caused by the migration and elongation of remaining teeth in already contracted arches.

Fig. 540.

A case of this character, age twenty years, belonging to Class III, is exhibited in Figs. 538 and 539, before and after treatment of both right and left sides of the mouth. The loss of many of the teeth by caries and necessary extraction, and the elongation of teeth which had no

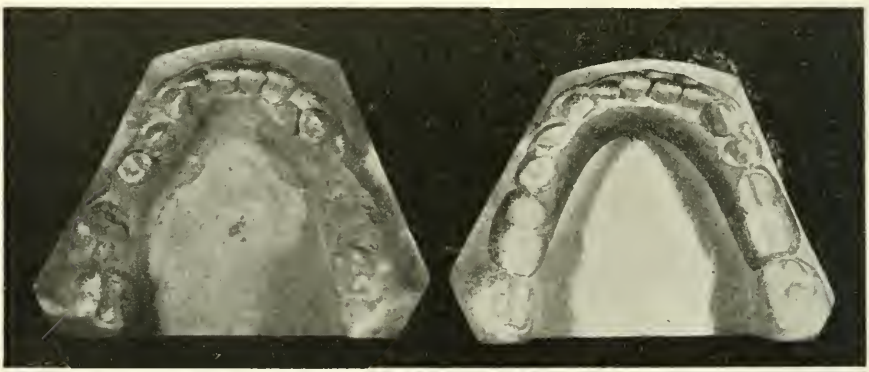

Fig. 541.

antagonists, rendered it exceedingly difficult to treat, especially as the problems of anchorage for the use of intermaxillary force seemed rather uncertain.

By a careful conservation of anchorage, however, the case was finally brought to a successful completion, the after treatment models being

shown on the right of Fig. 538 and 539, with retaining appliances in position.

In this case the plate plays a very important part, not only in retaining temporarily the spaces regained for permanent teeth, but also supplying artificial substitutes for the missing natural teeth.

A view of the upper casts of this case in Fig. 540 shows the retention of five of the anterior teeth with the lingual wire soldered to right cuspid and left lateral incisor bands, and a roof plate, with spring clasp attachments and three artificial teeth, effecting the retention of the rest of the teeth in the upper arch.

FIG. 542.

Another plate with spring clasp attachments and artificial substitutes for natural teeth, accomplishes the greater part of the retention of the lower arch as illustrated in Fig. 541.

The profile of this case, before and after treatment, is exhibited in Fig. 542, the improvement in contour being very pleasing.

At a later period, the plates were removed and bridge-work inserted for permanent retention and increased function of mastication which was attained.

The author would not advise undertaking the treatment of cases of malocclusion, especially of the most severe and complicated cases in this class, without the operator be assured from his own experience of successful results.

A case, for example, like that illustrated in Fig. 543, presents such difficulties in the way of treatment, that the operation of resection

of the mandible for the purpose of securing the best results in improved mastication and facial contour has not infrequently been recommended.

The infrequency of the operation of mandible resection, and the reports of a few failures in the hands of incompetent surgeons, has not aided in making it more desirable. The operation has been successfully accomplished by the general surgeon, and it is believed by the author that in the near future, it will be more commonly performed and by the trained oral surgeon, especially with the help of the orthodontist.

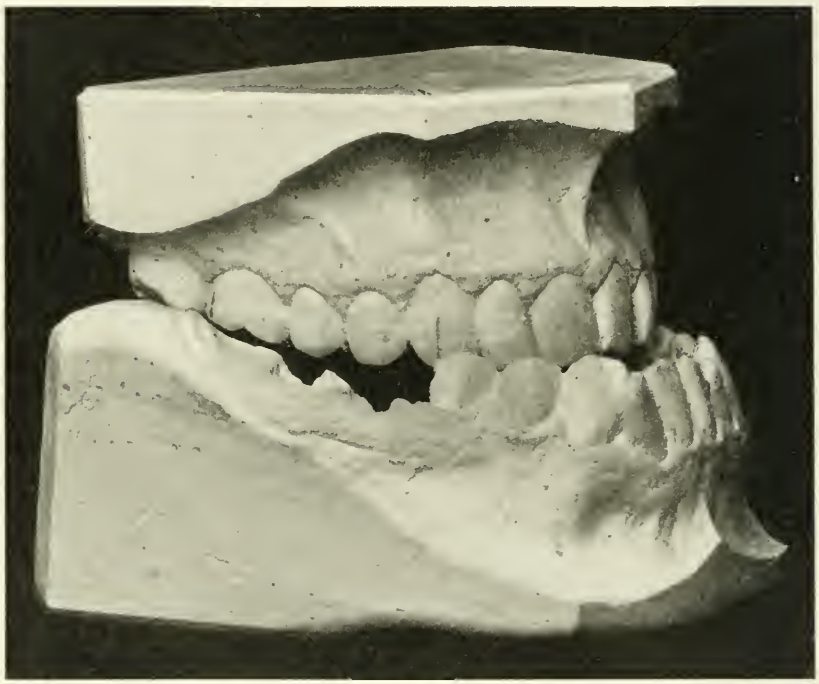

Fig. 543.

In the particular case illustrated in Fig. 543, the author performed an orthopedic operation which resulted not only in improvement in masticatory occlusion, but in a transformation of the disfigured facial lines into those of a most pleasing character, besides restoring the function of correct phonation in speaking.

The operation consisted in opening up an artificial space upon each lateral half of the maxilla, between the cuspid and first bicuspid, the width of a bicuspid tooth, moving the six anterior teeth forward to occlusion with the lower incisors, by a conservative use of intermaxillary force and special manipulation of the expansion arches.

At the same time, the teeth in the lower arch were moved distally as far as distal inclination of the lower incisors, and the accompanying movements of the upper teeth would allow, until the result shown in Fig. 544 was attained. The upper arch was retained by a fixed lingual arch soldered to bands upon the cuspids and first bicuspids, with buccal hooks upon the bicuspid bands, and with elastics extending from these to hooks on lower cuspid bands for a continuation of the intermaxillary force as retention.

FIG. 544.

Artificial teeth, soldered to the lingual retaining wire, artistically filled up the opened spaces until such time as permanent bridge-work could be substituted for the retention.

The improvement in the profile may be seen upon comparison of the before and after treatment pictures in Figs. 545 and 546.

Double Resection of the Mandible.—We are indebted to Dr. Max Ballin, of Detroit, Mich., for the first published illustrations of a successfully operated case of double resection of the mandible, the detailed description of which is given here in condensed form.

The patient was a young man twenty-two years of age, who pre-

sented himself to the surgeon on May 10, 1907, for possible surgical treatment of a protruded mandible, which orthodontic treatment had for some reason failed to remedy.

The extent of the protrusion measured one-half inch from the labial surfaces of the upper incisors to the lingual surfaces of the lower incisors, and the relations of the two dental arches in occlusion was such that it was almost impossible to masticate the food. (See. Fig. 547.)

The loss of several teeth from each lateral half of the mandible left spaces in which considerable resorption of the process had taken

FIG. 545.

FIG. 546.

place, and from which it was thought advisable to cut comparatively uniform sections of the mandible, and readjust and unite the anterior and posterior sections.

Previous to operating, Angle's fracture bands were fastened to the teeth on either side of the area from which the sections were to be cut, by Dr. Jackson, a dentist who was called in consultation. The operation was performed on May 20, 1907, at Harper Hospital, Detroit. Ether was administered, and the incision made in the soft tissues under the lower border of the body of the mandible. The soft tissues were separated from the buccal and lingual surfaces of the bone in the region to be resected, and the mucous membrane was detached from the alveolar process with a curved elevatory, care being taken not to make the slightest entrance into the oral cavity.

A trapezoid shaped piece was then resected from the mandible

with a circular saw driven by an electric engine such as is used for trephining. In repeating the operation upon the other half of the mandible, the old style chain saw was found to work much easier and took considerable less time. A Deschamps aneurysmal needle was used to lead the saw around the mandible. The base of the resected pieces

FIG. 547.

was about one-half inch in length and somewhat longer than the apices.

Holes were drilled through the lower edges of the remaining segments of the mandible, the segments were adjusted together, and silver wires were inserted from one segment to the other on each side. After suturing the external wound, the union of the segments was made more

secure by the ligating of the buttons upon the fracture bands within the mouth, from the teeth on the anterior segment to those upon the posterior segments.

The entire operation, with the exception of the ligation of the fracture bands, was performed outside of the mouth, so as to make it as aseptic as possible.

The patient made a quick recovery, being in the hospital about one week, the wound healing by first intention. The after treatment model and profile in Figs. 548 and 549 show a marked improvement over former conditions.

Dr. Ballin remarks: "In the first place, strict asepsis should be

Fig. 548.

Fig. 549.

a condition without which successful work is impossible. Therefore, opening of the oral cavity during the operation should not occur as this would certainly lead to suppuration and non-union of the bones. If the teeth are extracted during the operation, communication between the external incision and the extraction wound will always take place. I would recommend, therefore, to extract the teeth necessary to be removed for the resection, first, and then wait some months until the extraction wound is completely healed and atrophy of the alveolar process has taken place."

In commenting upon this operation, the author believes that Dr. Ballin has solved the difficulties in the way of preventing the inception of septic conditions, in operating entirely external to the oral cavity.

One suggestion made by Dr. Angle in regard to preparation for this operation seems an improvement in the technique and that is the resection of the previously made plaster cast of the mandible, and readjustment with the upper cast for the purpose of obtaining the best occlusion, and cutting out a section of the mandible which most nearly approximates the plaster section which was removed. In this way, the lines of direction for the chain saw might at least be approximated more perfectly than without any measurements, and the mandible better adjusted for occlusal relations.

In any event, the co-operation of surgeon and orthodontist seems advisable in working out the details of double resection of the mandible in order that the peculiar skill and experience of each may serve the purpose of obtaining the most beneficial and scientific results.

TREATMENT OF CLASS IV.

The characteristics in occlusion of Class IV being a mesial occlusion upon one lateral half, and a distal occlusion upon the other lateral half of the dental arches, as observed in the classification chart, the indications for treatment are a distal shifting of the occlusion in the former, and a mesial shifting of the occlusion in the latter.

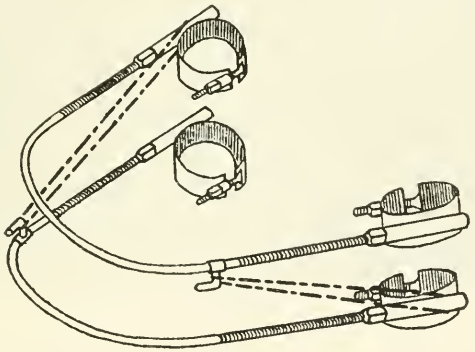

FIG. 550.

These movements may be secured at the same time by operating upon each lateral half as if they were independent of the other in their mesio-distal relationship, making use of the intermaxillary force as indicated by the attachment of hooks and elastics in Fig. 550, the elastic extending from a hook upon the upper expansion arch upon one side to the distal end of the lower tube on the molar clamp band, and from a hook upon the lower expansion arch to the distal end of the buccal tube on the upper molar clamp band upon the other side.

Dr. Norman G. Reoch has reported a case of this class in which the intermaxillary force applied in this manner brought the case to a successful completion.

Restoration of the Lateral Half of the Mandible after Unilateral Resection.—Occasionally, one lateral half of the mandible is resected by the surgeon because of diseased conditions which render it necessary to cut away a sufficiently large area to make reoccurrence

FIG. 551.

of tumors, or further breaking down of adjacent healthy tissues impossible.

If the remaining half of the mandible is not controlled by mechanical means, the contraction of the cicatricial tissue will draw the forward portion of the remaining section of the mandible to one side, and the unequal stress of muscular pressure will tip it inward, a case of this kind being represented in Fig. 551, the operation of resection having been performed seven years before presentation of the case to the author for orthopedic treatment.

The facial lines in this case were very much distorted, see Fig. 554,

the point of the chin being swung around or across the face from left to right, and the patient being unable to restore the mandible and chin to their median positions.

Various methods have been used to swing the mandible back to position in the median line, chief among which may be mentioned the lower partial plate hinged to the upper molar teeth upon the same side as the resection.

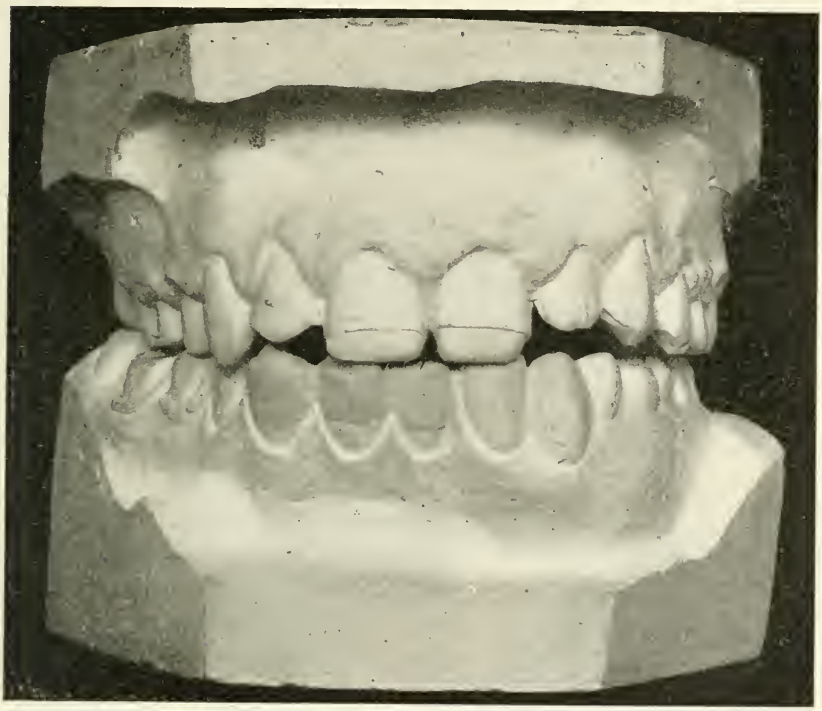

FIG. 552.

The author prefers the use of intermaxillary force, because of its power and directness, and quick accomplishment of results.

In this case, the intermaxillary elastics were applied as in Fig. 553, from a hook upon the right side of an expansion arch firmly ligated to the upper dental arch, securing as nearly as possible stationary anchorage, to another hook soldered to the mesial surface of a heavy gold band upon the lower central incisor, this band being reenforced by adjoining bands upon the lateral and cuspid, united with solder, and by one-half of an expansion arch extending from the lower first molar to the central incisor band, upon the surface of which it engaged

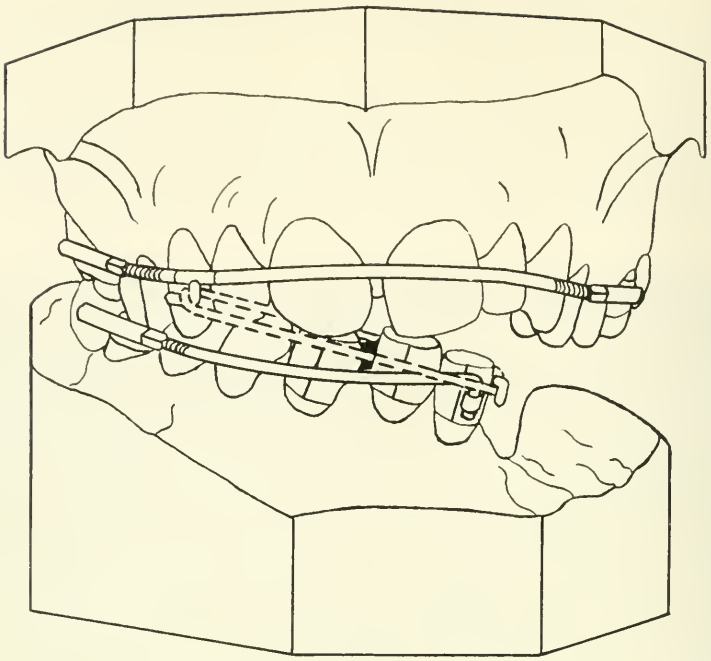

FIG. 553.

FIG. 554.

FIG. 555.

at right angles with a short vertical tube. The intervening teeth were ligated to this partial arch for further reenforcement.

As it was necessary to stretch the cicatricial tissue to some extent, it being composed of considerable fibrous elastic tissue, the size and number of the elastic used were varied until the resistance of this tissue was overcome, and the half of the mandible returned gradually to its proper median register, being at the same time tipped outwardly until the occlusal plane of the teeth was correct.

A removable vulcanite substitute with artificial teeth was made for the resected half of the mandible, the upper arch was expanded and formed into proper shape, and the resulting occluding position of the arches is seen in Fig. 552.

Fig. 555 illustrates the great improvement in the face consequent upon this operation.

These, and similar operations, are as much within the field of the orthodontist, as if the entire mandible were involved, and it is fitting that those who are unfortunate enough to possess these oral disfigurations should receive the benefit of the training of the experienced orthodontist.

THE PROBLEM OF EXTRACTION.

Extraction of the teeth of either deciduous or permanent set in orthodontia, must be viewed from a different standpoint than in general dental practice, since the whole aim of the orthodontist is the restoration of the dental arches in occlusion with the full complement of teeth, while the dentist is intent upon the restoration of contour, etc., of the individual tooth.

If the general practitioner could see his work through the light of occlusion, articulation and development, all of his cases for bridgework would be sent to the orthodontist for restoration of normal sized arches, and the regaining of spaces partially or completely, from which teeth have been extracted.

The radical departure from the older methods of treatment by the "new school" of orthodontia in the adoption of conservative methods of treatment, bases its assurance of propriety upon the premises that in the attainment of the normal and ideal in occlusion, all of the dental organs must be preserved in the correction of malocclusion.

This arbitrary standard is not made by the specialist, but it is indicated by the perfection of the occlusion in the normal and ideal, in which is recognized the value of the individual tooth as a factor in the preservation of the integrity and regularity of the arches of teeth,

the loss of one or more teeth from either arch causing deformity to just the degree of extraction to which it is resorted.

With this conception of treatment in orthodontia, extraction as a beneficial procedure, that is, towards restoring the normal in occlusion, is of course absurd, for with extraction comes mutilation of the arches, impairment of speech and mastication, and the formation of lines of inharmony in the face which are surely not desirable as a result of the efforts of the orthodontist.

A very large per cent of the deformed arches of teeth which present to the specialist, are caused by the premature extraction of deciduous teeth, or the unwise extraction of permanent teeth.

A very frequent question asked of the specialist by a parent is as to the advisability of extraction of one or more of the deciduous teeth

Fig. 556.

in the mouths of their children to "make room" for the permanent teeth. The acquiescence by the dentist in the unwisdom of this fallacious and pernicious idea has led to the wholesale extraction of deciduous teeth in the vain hope that the space thus created will allow the permanent teeth more room to erupt.

The result of such operations is just exactly the reverse of that which is intended, for the dental arch instead of being any larger, becomes still more contracted through the contraction of the space of the lost deciduous teeth, and the permanent teeth have **less room** to erupt than if none of the deciduous teeth had been extracted.

Results of Extraction of Deciduous Laterals.—For example, in the cast on the left of Fig. 556, the deciduous lateral incisors were removed in the belief that the two permanent centrals would have more

room for eruption, as they were apparently crowding somewhat in their effort to erupt. As a result of this treatment, the centrals erupted almost perfectly in alignment, but it will be noticed that their distal angles are almost in approximation with the deciduous cuspids, and that there is no space left for the eruption of the permanent lateral incisors, necessitating an operation for the restoration of these spaces and anterior development of the arch as seen in the cast on the right of Fig. 556, the deciduous laterals immediately erupting upon being released from imprisonment.

Results of Extraction of Deciduous Cuspids.—A Class I case, in which the lower deciduous cuspids have been prematurely extracted, with the complete loss of their space and anterior arrest of development in consequence, is illustrated in Fig. 557.

Fig. 557.

The lower incisors, having lost their support in the cuspid region, have become inclined lingually, and the upper incisors have been forced back against the lower incisors through the pressure of the lips and abnormal function.

The treatment of this case was undertaken at the time it presented with this condition of occlusion, and both arches were expanded, in the lower, the cuspid spaces being regained, as shown in the casts at the top of Fig. 558, and in the upper, the centrals moved forward, and the space for the right first deciduous molar regained, as shown in the casts in the lower part of Fig. 558 and this relationship established through proper retention until the eruption of the permanent cuspids and bicuspids.

A very noticeable improvement in the profile through this treatment may be seen in the central portion of Fig. 558, showing that the

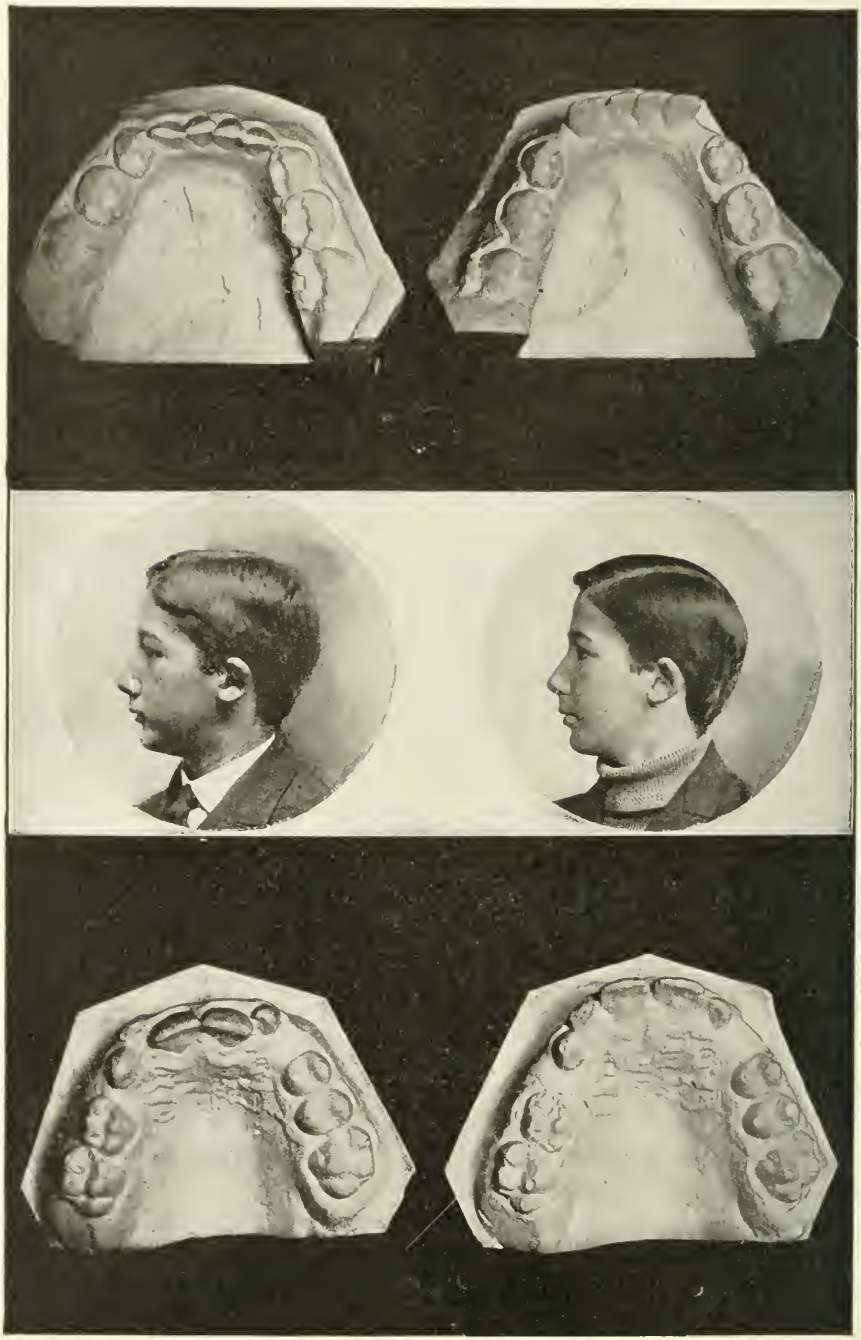

Fig 558.

harmony of the facial lines is effected by such apparently slight arrest of development as is caused by the loss of the lower deciduous cuspids and an upper deciduous molar.

Result of Extraction of Deciduous Molars.—The model on the left in Fig. 559 exhibits a case in which the lower deciduous molar was prematurely extracted, the subsequent closing up of its space, and arrested anterior development of the lower arch, with the dropping lingually of the upper incisors in an attempt on the part of nature to obtain a contact occlusion with the lower incisors. The model on the right illustrates the case after the space has been regained for the extracted molar, the arches harmonized anteriorly in occlusion, and a band and bar retention attached from cuspid to first molar in the lower arch, pending the eruption of the permanent bicuspids.

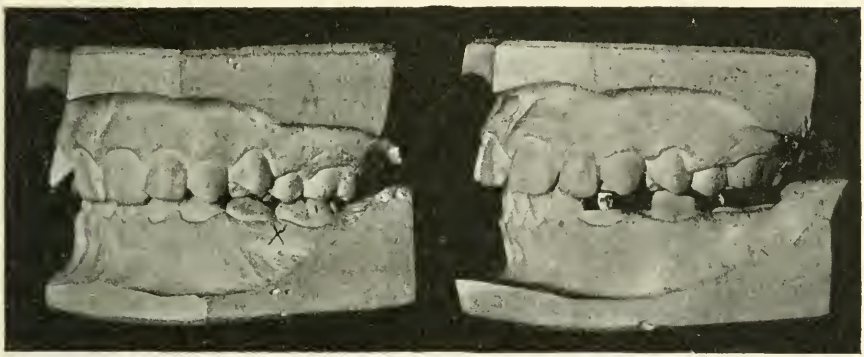

FIG. 559.

The loss by extraction of any of the deciduous teeth has a similar destructive effect upon the occlusion, the difference being only in degree.

In Fig. 384 is illustrated a case in which all of the deciduous teeth were extracted before the age of nine years, and the arrest of development of the arches is very plainly seen, although it is comparatively uniform throughout both arches.

Evil Effects of Extraction of Permanent Teeth.—In the loss of teeth by extraction from the second dentition, somewhat similar effects upon the dental arches are observed as those produced by extraction or premature loss of the deciduous teeth.

Successively, the results of extraction of one or more of the permanent teeth are the destruction of the integrity of the dental arches, the destruction of occlusion and articulation, and finally the marring of the facial lines.

The extent of the deformity is usually proportionate to the degree of the extraction, every additional tooth lost causing just that much more aggravation of conditions and change to the abnormal.

Relative value of First Permanent Molars.—In view of the prevalency of the extraction of the first molars it may be well to consider first their relative value and then the result of their extraction from the arch.

Some of the more important reasons for their preservation in the arch are as follows:

1. They are the first of the permanent molar teeth to erupt, and during the period of shedding of the temporary dentition, afford the broadest and best masticating surfaces in the mouth.

2. By reason of their great size and strength, they are the only

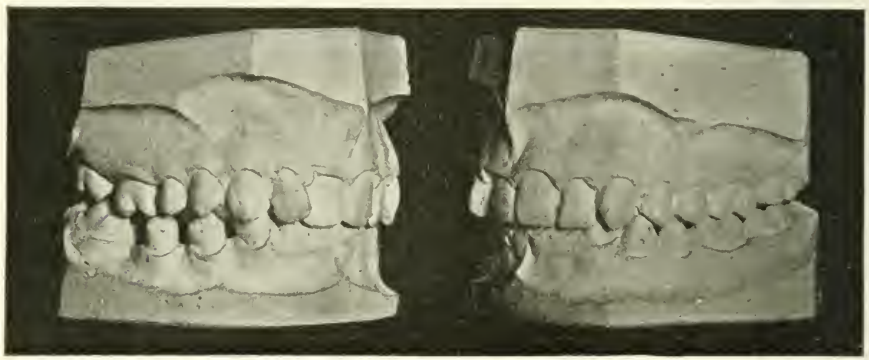

FIG. 560.

teeth that can serve as a means of preserving the normal relationship between the dental arches, and consequently the symmetry of the face, at a time when no other of the permanent teeth, except the incisors, are erupted to occlusion.

3. Their presence is an aid in the forward development of the mandible.

4. Statistics comparing the relative frequency of caries in the first and second molars prove the second molar more often carious than the first.

5. The first molar, on the average, is a better constructed tooth than either the second or the third molar.

6. Its extraction is the cause of a large percentage of cases of malocclusion, and consequent facial inharmony.

Results of Extraction of First Permanent Molar. The history

of the case of malocclusion in Fig. 560, dates its inception to the time of the extraction of the lower right first permanent molar, and the series of intricate changes in occlusion to the abnormal are commonly observed.

The model on the right of the cut represents the left side of the case in occlusion, exhibiting normal cusp relationship of upper and lower teeth as far forward as the cuspid.

The model on the left illustrates the destruction of occlusion and the shortening of the right lateral half of the dental arch as a result of the extraction of the first molar.

To the student of occlusion, the changes in occlusal relations after the loss of the first permanent molar are more or less familiar, and it is comparatively easy to follow the consecutive stages whereby

FIG. 561.

the ruination of otherwise beautiful dental arches has been accomplished.

Consequent upon the loss of the first molar in this case, ensued not only the tipping mesially of the second molar, but also the drifting distally of the second bicuspid into the space, followed by the distal movement of the first bicuspid, the cuspid and incisors, and the contraction of the whole arch.

The effect of this contraction upon the upper arch is noticeable in the lingual positions of the incisors, and the torsion of the right lateral incisor.

The closing together of the teeth in occlusion tends to force the lower right second molar still farther mesially, and to draw the right lateral half of the lower arch distally to a considerable extent.

The occlusal views of the upper and lower arches in this case, in Fig. 561, illustrate, from this aspect, the mutilated arches, both being

contracted and the upper arch flattened in the incisor region, producing this effect in the facial profile, as a consequence.

The author has observed a patient with a similar case of malocclusion, who was on the verge of nervous collapse as a result of such changes in occlusion as to make mastication painful and almost impossible.

A variation from these changes in occlusion as a result of the extraction of a lower second bicuspid is observed in Fig. 562.

Although not revealed by the picture, the second bicuspid on the right side of the lower arch was also extracted so that the change in occlusion was comparatively uniform bilaterally.

Fig. 562.

Result of Extraction of Second Bicuspids.—The loss of these teeth has caused an apparent protrusion of the upper arch in Fig. 562 as a result of the perversion of function of the occlusal planes and also of the lips, the lower lip tending to roll up under the upper incisors and force them still farther outward.

The first and second molars in occlusion have retained the normal mesio-distal relationship of the arches, and the contraction of the lower arch has been entirely anterior to the first molars, the second bicuspid spaces being almost entirely closed.

Complications in Treatment after Extraction of Teeth.—The treatment of cases of malocclusion caused, or mutilated, by extraction of the permanent teeth, is necessarily much more complicated than if the full complement of teeth were present, so that complete arch restorations as well as occlusal relations might be established.

As a rule, it is imperative that all spaces of teeth which have been

lost through extraction should be restored and artificial substitutes inserted in order to secure harmony in occlusion between the dental arches.

In the cast on the left of Fig. 563, it will be noticed that the lower

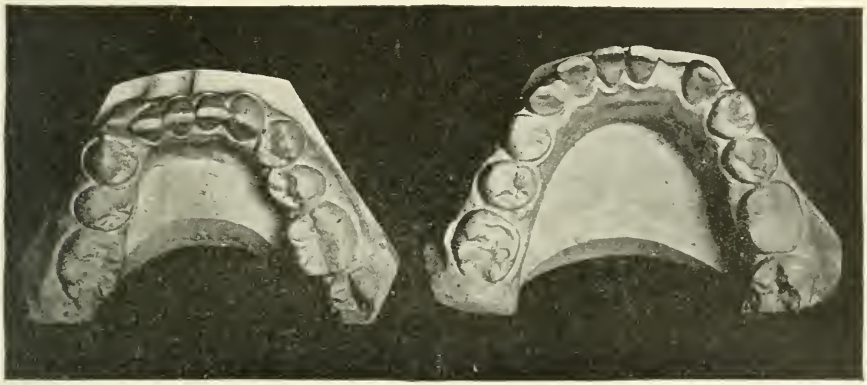

FIG. 563.

right lateral incisor is missing, it having been extracted for the purpose of "regulating" on account of its having been located in lingual occlusion.

In the restoration of this arch to normal size, the space for the right lateral was regained, as shown in the cast on the right of Fig.

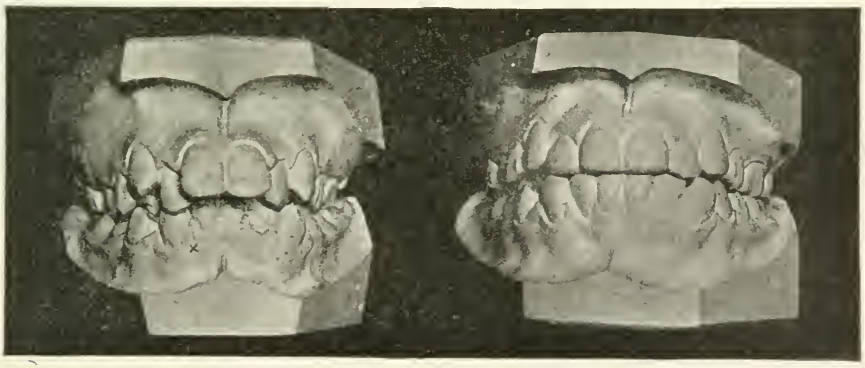

FIG. 564.

563. How much more scientific it would have been to have enlarged this arch to this extent when the case first presented with the lateral in lingual occlusion and to have restored it to its normal position in the arch. Here, indeed, is the clue to the proper solution of the case

and illustrates, in a nutshell, the impropriety of extraction either "to make room" or correct alignment.

The before and after treatment models of the case viewed from the front in Fig. 564 illustrate the necessity of regaining the space for the lateral incisor and providing an artificial substitute in order to restore the normal relations of occlusion.

If the upper arch only had been restored to its normal size and

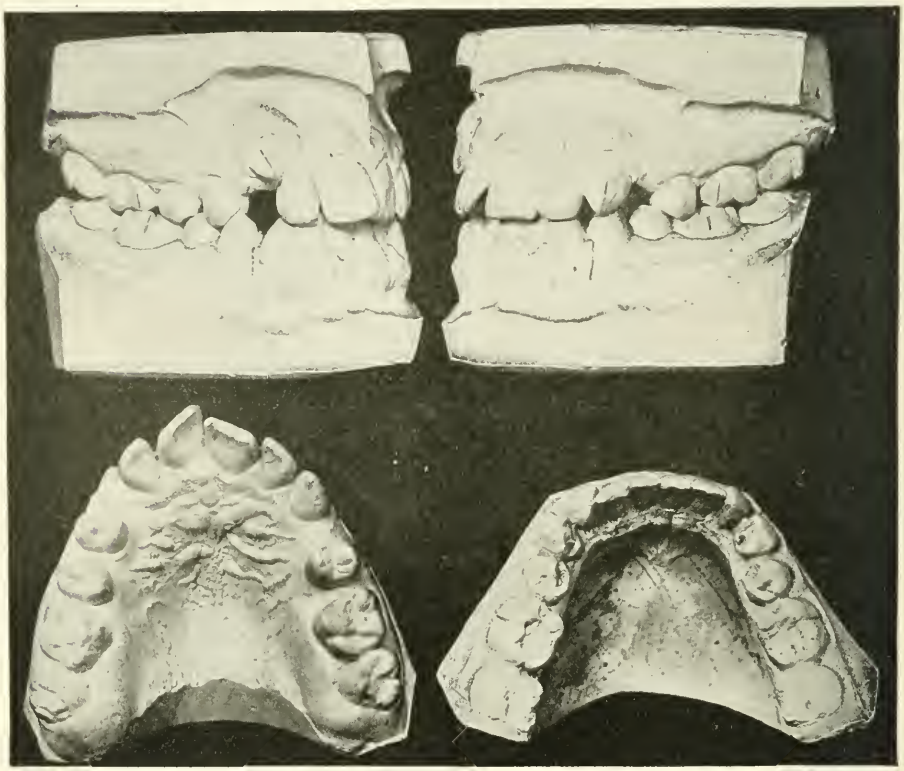

Fig. 565.

shape, it would have been larger than the lower by the width of the missing lower lateral incisor.

The illustration of a few practical cases in pairs, of the same class, one of the pairs having been treated by extracting, the other by restoration of normal occlusion, may serve, by comparison, to show the relative value of the two methods of treatment.

Fig. 565 exhibits a Class I case in which the dentist, who originally had it in charge, thought it necessary to extract the upper first bicus-

pid on the left side in order to "make room" for the eruption of the left upper cuspid which was formerly in a position similar to that of the right cuspid seen in labial occlusion in the model on the left of the cut.

The operation of extraction was performed as indicated, the upper left cuspid erupting into the space, partially, but so incompletely filling it that the patient was unwilling to have the same thing done upon the right side of the arch.

On examination of the occlusal view of the upper and lower casts in the same cut, it will be observed that the lower arch is contracted anteriorly, the cuspids being in torso-occlusion, and if an operation

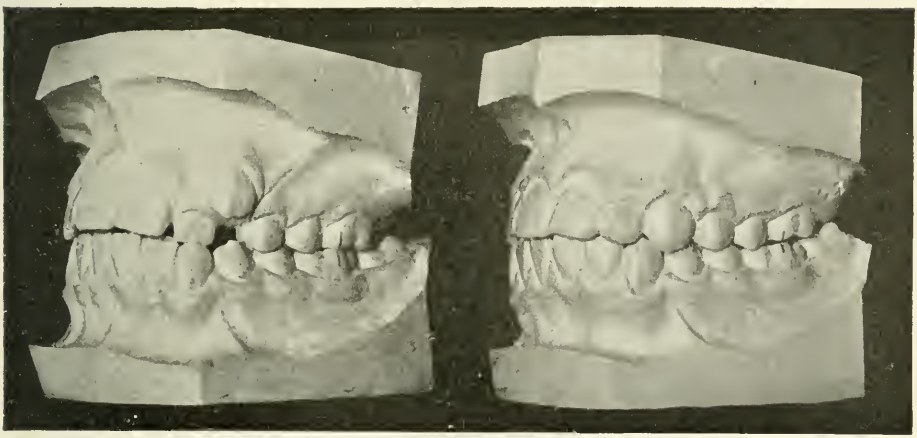

FIG. 566.

for expansion of both arches had been performed, normal occlusion could have been obtained.

Fig. 566 illustrates a precisely similar case, both as to etiology and diagnosis, except that the malocculsion is limited to the left lateral half of the arches.

The prognosis in cases of this kind is always favorable to treatment without extraction, and the diagnosis assures such splendid results as are shown in the after treatment model on the right of Fig. 566, the arches being restored to normal size and shape, and normal occlusal relations being established.

Fig. 567 exhibits a somewhat more severe case than the one just described, but it might have been governed by the same laws in its treatment if they had been understood.

Two mistakes were made in the treatment of this case, however.

one by the extraction of the upper second bicuspid, the other the neglect of the slight irregularity in the lower in the treatment of the case. The after treatment on the right shows alignment to a certain

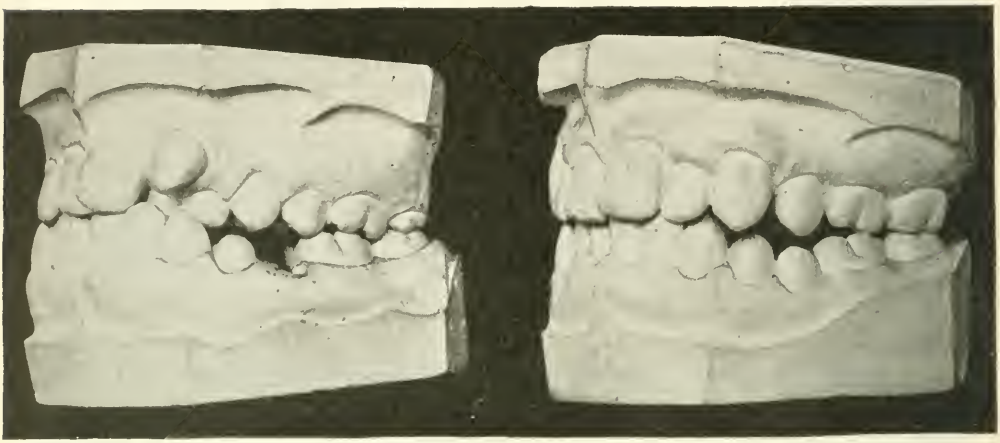

FIG. 567.

degree but it will be noticed that the arch is still crowded, and that the possibility of harmonizing the arches and restoring occlusion is forever lost. All that was needed was the regaining of some lost space in the lower arch and the harmonizing of the upper arch to it, saving all of the teeth.

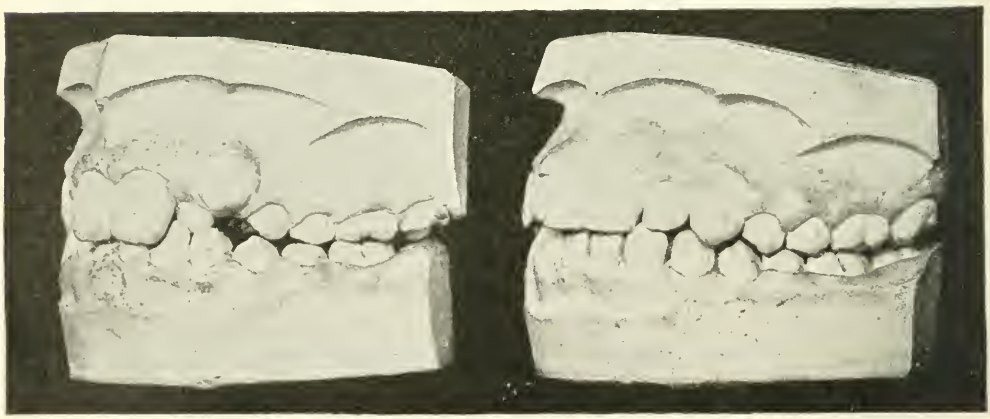

FIG. 568.

Fig. 568 illustrates a similar case in which the ideal has been attained in the restoration of normal occlusion without extraction, each occlusal plane having been moved into its correct relationship with its antag-

onist of the opposite arch, and the production of a harmonious result which is truly beautiful. These results were obtained some ten years ago when the principles of occlusion were much less known than now.

Coming now to another class of deformities in which extraction of one or more of the bicuspids has been advised as of value in the reductions of protrusions such as is here illustrated, Fig. 569, let us note in the case the results of such extraction upon the arch. The first bicuspid was extracted and the anterior teeth drawn distally until the space of the extracted tooth was closed, a very common operation extant among the profession for the correction of this deformity. The

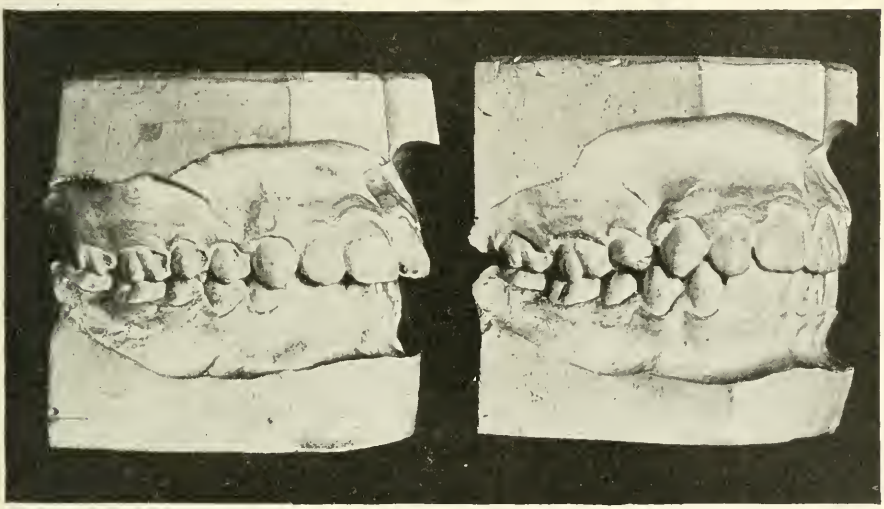

Fig. 569.

model of the completed case on the right exhibits no such harmony of contour as the models of the completed cases which are illustrated under the treatment of the first division of Class II. The curves are not graceful, the mutual support of the full complement of teeth has been lost, and a lame and crippled appearance is distinctly noticeable.

In the majority of cases in orthodontia, extraction of the teeth is not indicated, in fact, an almost iron clad rule has been established by some specialists operating from the basis of occlusion, condemning extraction in all cases.

While this rule is a safe one to follow in the majority of cases, to attempt to practice it in every case would be entirely unwise, as there are cases in which it is not only impossible to restore normal occlu-

sion, but in which extraction is indicated in order to obtain any sort of harmony of the occlusion.

These exceptions do not necessarily lower the standard of perfection which the restoration of the normal or ideal in every case might imply, since their very existence and the difficulty of their diagnosis should, by the nature of things, compel the operator to use his best judgment and follow a safe rule.

In what cases, then, is extraction advisable? The answer to this question is the knotty part of the problem, for although we are certain of the advisability of the procedure in some cases, to lay down a set rule for such cases would militate against the best results which might be obtained without extraction, for in two identically similar cases, extraction may be found necessary in one, while in the other, the restoration of the ideal in occlusal harmony may be easily diagnosed and obtained.

Exceptions to the general rule of occlusal restoration in which it is advisable to extract does not give license to extract promiscuously, and the only hesitation which the author feels in attempting to point out these exceptions lies in the possible exaggeration of the number of cases in which the novice, because of his lack of experience, and the charlatan, because of his indifference, might feel justified in extracting teeth unnecessarily because of any loophole which the knowledge of an exception to the general rule of non-extraction might give them.

But, the obligation laid upon the author, in the publication of a scientific work on orthodontia, which, to be scientific and most helpful to the general practitioner, should not be misleading, is so great, that to attempt to encourage the attainment of impossible results through non-extraction and futile attempts at occlusal restoration, would defeat the object of the promulgation of the truth which should be paramount in the building up of any science which tends in any way to benefit the human race.

It might be correctly stated that extraction is advisable in some few cases in which it is impossible to obtain a satisfactory result after an intelligent and persistent effort in following out the laws of occlusal restoration.

Or, in cases of monstrosities of tooth dentition, such as in extreme hypertrophy of the alveolar processes, where restoration of normal occlusal relations would only exaggerate the deformity and increase the inharmony of facial contour.

So seldom is extraction indicated that in the author's practice, it has been resorted to in but four cases in ten years, and a similar

record will be found in the practices of other specialists operating from a conservative basis.

In cases already mutilated by extraction, in which it is not advisable to restore normal occlusion by regaining all spaces lost by such extraction, it may be necessary to extract according to the requirements which are peculiar to the individual case, and for which no set rule may be established.

In these cases, the advice of a specialist of at least five years' experience in orthodontia ought to be sought, in order that an error in judgment may not be made through simple lack of experience.]

VIII. RETENTION.

The Scope of Retention.—A clear perception of the field of retention necessitates a proper understanding of the ultimate purpose of the treatment of arrested developmental conditions in the dental arches, which is the restoration of function, through the stimulation of structural development in the maxillary arches, and the attainment of the normal in occlusion and articulation.

It will be inferred from this statement that the development and restoration of the normal in shape and size of the individual dental arch is the primary, and the attainment of normal positions of inclined planes of antagonizing cusps of occluding teeth the secondary, consideration in treatment, these two phases being so related, however, that the consideration of the one without the other would be incomprehensive of the scope of orthodontia.

Necessity for Retention.—In all treatment in orthodontia, the resistive qualities of the osseous structures in which the teeth are implanted, and of the fibrous elastic membranes with which they are surrounded, are mechanical as well as physiological factors which are present until long after treatment is completed, and unless these reactive forces are inhibited for varying periods after the completion of treatment, more or less of a return of former conditions of imperfection of form, growth, and occlusal relations of the dental arches is inevitable.

Added to these untoward influences the possible abnormal habits of mouth-breathing, thumb- and lip-sucking, and the abnormal tension of the muscles of the tongue, lips and cheeks, and the abnormal influence of inclined cusp planes, present in many cases, the forces which tend to resist normal development and function may be considerable.

Retention *may be defined as the maintenance of such development of the dental arches and relations of occlusion as may have been established*

through treatment, by a proper antagonism of any forces which may interfere with these normal structural and functional conditions.

The establishment of mechanical resistance to these return tendencies through appliances attached to the teeth must be sufficient so that an equilibrium between the forces of reaction and the applied resistance is obtained. An insufficiency of resistance in a retaining appliance would result in a partial return of former conditions.

Retention, then, as in anchorage, is a measure of resistance values, the proper appreciation of which is essential to the permanence of results obtained in treatment.

Retention Classified.—Retention may be classified as follows: *Occlusal, simple reciprocal, intermaxillary, and occipital*, according to the quality of resistance used in opposing the return forces.

Of especial importance is the influence of the inclined planes of the cusps in retention, their normal function ending in occlusion and articulation, to preserve the integrity of the arches.

Occlusal retention *is the maintenance of the normal occlusal positions of the teeth, individually or collectively, through the normal functional influence of the inclined planes of the cusps, and the contributory forces gained through restoration of arch integrity.*

In order to secure the harmonious working of the inclined planes it is necessary that not only should the full complement of teeth be present, perserving individual arch integrity by proximate contact, but that the normal size and shape of the arches be restored, which would include the restoration of articulating planes and compensating curves, etc. Experience will prove that articulating planes can be only approximately obtained in the correction of malocclusion, so complicated is the mechanism of articulation, and the lack of development of the arches in malocclusion so disturbing the harmonious working of the laws of articulation that accurate arch and cusp protection in articular movements is outside the range of possibility of treatment, except in special cases.

In malocclusion there is abnormal function of occlusal inclined planes of cusps, often of respiratory mechanism, and tongue or lip insufficiency, and abnormal muscular pressure, which if not corrected will still continue their abnormal influence upon the arches of teeth.

The nearer the approach to normal occlusion and articulation in the treatment of any case of malocclusion, the less need will there be for mechanical retention beyond that afforded by the normal action and reaction of the inclined planes of the cusps.

It must be remembered however, that the restoration of the

normal functions of occlusion and articulation does not counteract the tendency of the fibers of the peridental membrane and the alveolar process to assume their former relations of abnormality, except to to a slight degree, otherwise there would be very little need for mechanical retention of teeth and arches.

The normal relations of occlusal inclined planes in the attainment of normal occlusion, cannot be depended upon alone, for retention, until after varying periods of fixed retention of the teeth and arches with mechanical appliances, except in simple and special cases.

An upper incisor tooth, moved from lingual to normal occlusion, if there is sufficient overbite, will be retained by the action of the lingual incline of the upper incisor upon the labial incline of the lower incisor.

The same effect will be observed where there is sufficient overbite in any of the upper teeth which have been moved into their line of occlusion from lingual occlusion and restored to the normal action of the inclined planes.

To a lesser degree, also, the restoration of upper bicuspids and molars in buccal occlusion, lower incisors and cuspids in labial occlusion, and lower bicuspids in lingual or buccal occlusion, will be retained by the restoration of the normal influence of their inclined planes in occlusion.

Infra-occlusion of the teeth demands long and persistent retention of corrected occlusion.

Teeth which have been rotated, unless at a very early age, as during their eruption, will always need retention by mechanical appliances for varying periods of time.

Anterior and posterior expansion of arches will also usually need retention for periods of time varying according to the degree or extent of the expansion, the age of the patient, the peculiarities of the case, etc.

Extensive cases of Classes II and III, will always demand a very persistent mechanical retention, often for several years.

Simple cases of Class II, especially of the second division, and its subdivision, and of Class III, are often retained by normal cusp influence alone, as far as the mesio-distal relations of occlusion are concerned.

Figs. 516 and 517 is an example of bilateral distal occlusion, Class II, Div. 2, which was retained in its mesio-distal relations entirely by the interdigitation of the cusps of bicuspids and molars, although the upper incisors were retained by bands and spurs for a short time.

Usually the retention of a corrected malocclusion is a matter of

more than a few weeks in point of time, many cases requiring months, and some of the more severe, several years of fixation in order to overcome the resistance of the fibers of the peridental membrane, and the tendency of the arches to contract or assume their original forms and relationships after having been restored to a normal condition of occlusion, or after being mechanically developed up to a physiological limit.

The retention of the deciduous teeth is a process of temporary fixation for the development of the arch alone, while the retention of the permanent teeth is often a necessity for their maintenance in their relative positions in the arch, although developmental changes are still going on.

The length of time of retention of the arches of deciduous teeth, at the most, can only last until the eruption of the permanent teeth, in whole or in part.

Permanent teeth, which have been moved into their normal lines of occlusion during eruption or immediately after, need retention for a far shorter time than if they have been confirmed in their abnormal positions for some time before being corrected.

It is a well known fact in orthopedic and orthodontic practice *that the rapidity of the restorative or building up process in bony tissues, as after setting of fractures, is proportionate to the degree of fixation of the parts during the period immediately following the corrective operations.*

To the end, therefore, of shortening the time of retention, as well as obtaining a more perfect development and greater strength of the tissues surrounding the moved teeth, and avoiding the possibility of any loss from contraction of arches after expansion or regaining of spaces, the fixed retaining appliance, with cemented bands, is generally to be preferred to any other.

Simple retention *is the antagonism of the forces of reaction by the support of the resistance of one or more teeth in the same arch which have not been moved, or which afford a comparatively stable resistance in opposition to these forces.*

For example, in Fig. 570, A, the central incisor which was in lingual occlusion is retained in position by cementing upon it a band with labial spur extending over the labial surface of each adjoining tooth, as shown at B in the same figure. The adjoining teeth may have shared in a general expansive movement to a slight degree, but would still afford a comparatively stable resistance for retaining the lingual tendency of the central incisor which was in lingual occlusion.

A torso-mesial occlusion of the one central may be retained

by the cemented band and lingual spur over the lingual surface of the other central which may, or may not have been moved to a slight extent labially or lingually. An absolutely stable resistance in single tooth movements is, of course, to be preferred for retention purposes.

Reciprocal retention *is the counterbalancing of the return tendencies of two or more teeth in the same arch or in opposite arches by the antagonism or opposition of their reactive forces.*

Simple reciprocal retention would be represented by the antagonism of the reactive tendencies of two teeth which have been moved in opposite directions, as illustrated in Fig. 571 the two centrals being

FIG. 570.

rotated in opposite directions, and the retention consisting of two bands soldered together, and cemented upon the centrals.

Compound reciprocal retention would be represented by the antagonism of the tendencies to return of several teeth in the same or opposite opposite arches.

Intermaxillary retention may be compound reciprocal retention between teeth of opposite arches

In the retention of the expanded arch, as in Fig. 575, the resistance of one lateral half is pitted against that of the other, and is an illustration of compound reciprocal retention.



FIG. 571.

Another example of simple reciprocal retention is illustrated in Fig. 572, the lateral incisor and first bicuspid being reciprocally antagonized in their return tendencies by the band and spur method.

Intermaxillary retention *consists of the continuation of the use of intermaxillary force in cases of mesial or distal shifting of occlusion in such a manner that a reciprocation of force and resistance is established which is capable of the retention of the mesio-distal changes in occlusion.*

In persistent cases of Class II or III, the necessity for the use of the intermaxillary force for a considerable time after treatment,

in order to retain the mesio-distal relations of the dental arches, is evident to the experienced orthodontist.

This form of retention is illustrated in Fig. 585, in a case of the first division of Class II.

Occipital retention *consists of a continuation of the wearing of the headgear and traction bar for counteracting the resistance offered by the incisors to being held in lingual positions.*

In general, the field covered by retention may be divided as follows: Corrected malocclusions of individual teeth, expanded or contracted arches, and mesial or distal changes in occlusion.

To a certain extent, then, the retention of any given case is indicated as much by its classification as is the treatment, and it is evident

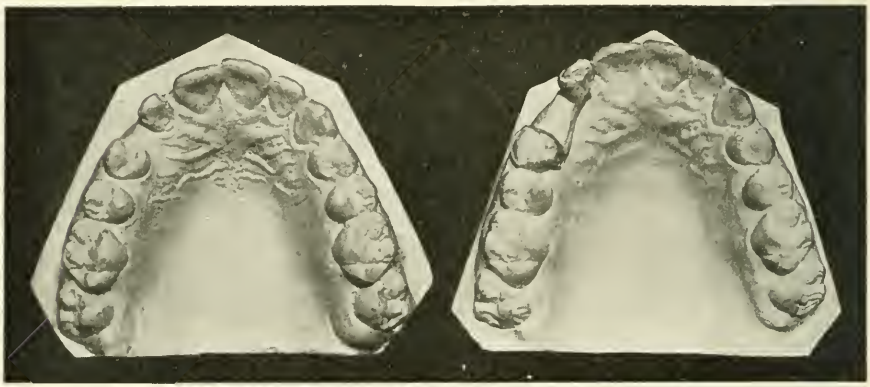

FIG. 572.

that a favorable prognosis can not be made without a foreknowledge of the possibilities of a successful retention.

Retention of the Expanded Arch.—The age at which treatment is begun, and the number of permanent teeth erupted, will necessarily require a variation of forms of retention according to the demands of the individual case.

If uniform development of the dental arch has occurred during treatment, that is, the arch being expanded in the molar as well as the incisor region, the retention will have to be so applied that this expansion will be uniformly retained.

It has been customary in a large percentage of cases of expanded arches to retain the anterior portion of the arches by a fixed appliance, and to pay little attention to the molar region, many times allowing the molars to settle back into the same arch form as before treatment.

While this may be done in some cases with impunity because of the lack of necessity of much expansion in the molar region, the author is convinced that in the large majority of cases, not only does the dental arch need expansion in the molar reigon, but a fixed retention as well.

The Deciduous Arch.—The earliest indications for retention in the deciduous arch are after a certain amount of expansion of the anterior portion of this arch for securing development enough for the eruption of the incisors and cuspids, and possibly the bicuspids.

The need for a fixed retention of a part or of the entire deciduous arch, during a varying period of natural development and including

FIG. 573.

the eruption of the permanent teeth provided for in the retention, is apparent.

Retention of Anterior Part of Developing Arch.—An appliance which will effectually retain the anterior part of the arch during the developing period and attached entirely to the deciduous teeth, is shown in Fig. 573, being the retention of the anterior portion of the expanded arch shown in Fig. 446, chapter on operative technique.

The deciduous cuspids are banded and connected by a lingual wire of 18 or 19 gauge, B & S., and short spurs are extended distally from the lingual surface of the cuspid bands upon the lingual surface of the deciduous molars. A great amount of strength in a retaining appliance attached to the deciduous teeth is never necessary because of the slight resistance they offer to the action of force appliances in their movement, due to their small short roots, and the cartilaginous nature of the alveolar process.

If more development of the anterior portion of the arch is required after the expansion has been carried on as far as possible, the retainer may be constructed as in Fig. 574, in which the lingual wire slips into short tubes soldered to the cuspid bands, and by pinching with the wire stretching pliers, as suggested by Dr. Angle, the arch may be still further expanded in this region during the period of retention. The lingual wire in this case should be constructed of platinized gold sufficiently soft to be easily stretched in this manner without breaking.

Retention of the Entire Deciduous Arch.—In case that the deciduous arch has been uniformly developed by expanding anteriorly and posteriorly, an immediate need exists for the retention of all the increased width and length of the arch which has been gained in the treatment.

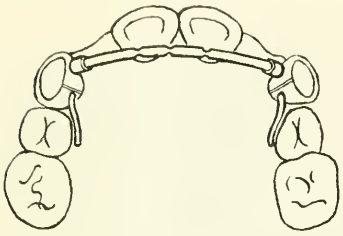

Fig. 574.

To illustrate, the upper arch in Fig. 447, although the permanent central incisors and first molars are present, is still the same in width as the deciduous arch, and in development is still a deciduous arch. The central incisors being .39 inch wide, require, according to the Hawley measurements, an arch considerably larger than the average.

Having been expanded during a period when the deciduous teeth present were comparatively firm in their attachments, the crowns of the permanent teeth being moved laterally through their envelopment by the roots of the deciduous molars, the indicated retention in the case is a fixed retention of the entire deciduous arch until such time as the natural developmental processes have been completed so that the eruption of the remaining permanent teeth may take place in a sufficiently enlarged arch.

According to these indications, the retention exhibited in Fig. 575 was adjusted, bands of irido-plantium being fitted to the deciduous cuspids and second molars, and connected by a lingual retaining wire of 19 gauge, B. & S., iridio-platinum, soldered to their lingual surfaces, and extending across the lingual surfaces of the first permanent molars.

In order to secure a more accurate fit, the lingual wire was adjusted and soldered to the bands upon the plaster cast, the bands having been removed with the impression. The central incisors were retained with two iridio-platinum bands united with solder, and cemented in position.

A slight lateral spring may be given to the lingual retaining wire to assist in further stimulus to lateral development of the arch if necessary.

Retention after Anterior Expansion.—Where the arch has been expanded anteriorly, it is an essential that the increased width of the arch should be retained for some time, so as to allow the development of the alveolar process and the overcoming of the forces of reaction. For example, if the arch has been expanded anteriorly to allow the centrals or laterals to be rotated, etc., the retention of these individual teeth in their lines of occlusion is not sufficient in most cases, as the

Fig. 575.

reactive force in the contractive tendency of the arch will soon cause a malocclusion to appear, such as the overlapping or torsion of one or more of the incisors.

It is advisable, therefore, to always retain the positions of the six anterior teeth by means of a fixed retaining appliance which will hold the width gained between the cuspids, such as is shown in Fig. 576, adding a lingual spur to the first bicuspids when they have also been included in the lateral expansion.

Fig. 577 illustrates the expansion and retention of the anterior portion of an upper arch, in which space was made for the eruption of

the cuspids. Bands were cemented upon both of the first bicuspids having previously been united with the strong 16 gauge bar of platinized gold extending along the lingual surfaces of the incisors, and having spurs of 21 gauge gold wire bent around the distal angles of the lateral incisors to the liabial surfaces to hold the four incisors intact.

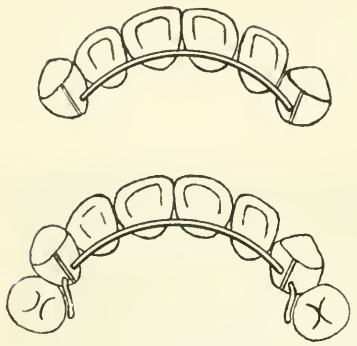

Fig. 576.

This appliance is as simple and esthetic as can possibly be constructed for a case of this character, and it might well be used as a standard retention for similar cases in which no rotation of any extent is necessary in the incisor region.

The Lingual Arch Retainer.—The use of the lingual arch retainer, as suggested by Dr. Lourie, invites many possibilities of practical and esthetic retention of the dental arches, because of its efficiency and inconspicuousness.

Consisting of an iridio-platinum wire closely adapted to the lingual surfaces of the incisors, cuspids and bicuspids, and attached at either end to the ends of the lingual screws of the molar or bicuspid clamp bands, see Fig. 578, it is correct in principle since it provides

Fig. 577.

for complete retention of the entire dental arch after general expansion, at the same time providing for such retention of the individual teeth as may be necessary.

The retention of teeth which have been moved labially or lingually, extruded or intruded, may be accomplished with this method by attaching hooks to the lingual surfaces of individual bands upon the

teeth, and bending these hooks above or below the lingual arch, and in such positions as will tend to overcome the particular resistance required.

In Fig. 578 its use in retaining the extrusion of the incisors in a former case of openbite malocclusion is effective, especially with the spurs over the occlusal surfaces of the deciduous molars, enlisting their resistance in supporting the lingual arch in position which in this instance is attached to clamp bands upon the deciduous molars.

In Fig. 584 the lingual arch presents a feature of additional value

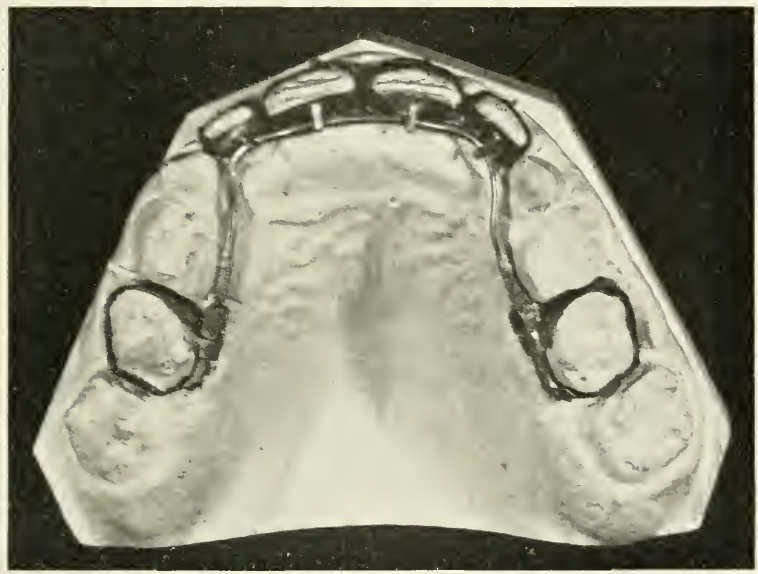

FIG. 578.

in its prevention of the tipping or rotation of the teeth which support the buccal spurs for retention of the mesio-distal relations of the arches.

Anterior and Posterior Arch Retention.—A very ingenious and efficient retaining appliance, designed by Dr. Henry Baker, of Boston, for anterior and posterior retention is illustrated in Fig. 579.

In effect, it is a lingual arch, KL, of clasp wire, 17 gauge B. & S., closely adapted to the lingual surfaces of the incisors, cuspids, and bicuspids, soldered anteriorly to the lingual surfaces of gold bands upon the cuspids, with its distal ends engaging in rings upon the lingual surfaces of gold bands upon the molar teeth.

The labial wire, F, extending from one cuspid band to the other, is

designed to retain the incisors from a return to positions of torsal or other malocclusion.

For greater accuracy of adaptation, this appliance is preferably made upon a cast, the four bands having been previously constructed upon the natural teeth, and an impression taken of the arch with them in position.

The molar bands, M and N, are first cemented into place, and then,

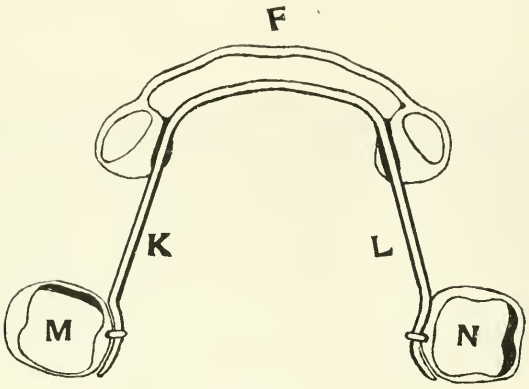

Fig. 579.

after filling the cuspid bands with cement, the distal arms, K and L, are slipped into the lingual rings on the molar bands, and the anterior portion of the appliance forced into position upon the anterior teeth, there being enough play in the lingual molar rings for this downward movement of the appliance.

Retention of Mesio-distal Changes in Occlusion.—As cases of the second and third classes of malocclusion present the greatest

Fig. 580.

difficulties in the way of treatment, so also do they require exceptionally difficult retention, for in addition to the necessity of retaining each dental arch in its corrected form and size, including the malposed teeth which have been restored to normal positions, it is almost always essential that the mesio-distal change in occlusion shall be persistently retained for some time after treatment, varying with the age of the patient and the extent of the mesio-distal malocclusion.

Occasionally a case presents in which the restoration of function of the occlusal inclined planes needs no other retention than the normal action and reaction of these inclined cusp planes upon each other in occlusion and articulation. A case of this kind belong-

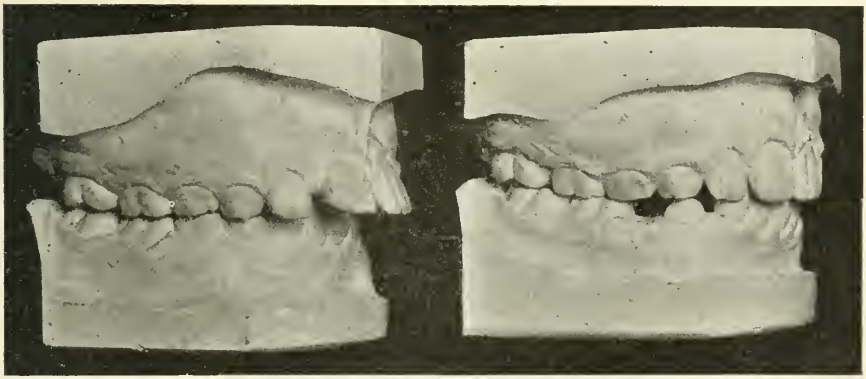

FIG. 581.

ing to the second division of Class II is described under treatment of this class and illustrated in Figs. 516 and 517.

As illustrative of the fact that mesio-distal retention upon the molars is not always necessary after treatment in the divisions of Class II, in early treated cases, Dr. Norman Reoch reports a case in which the

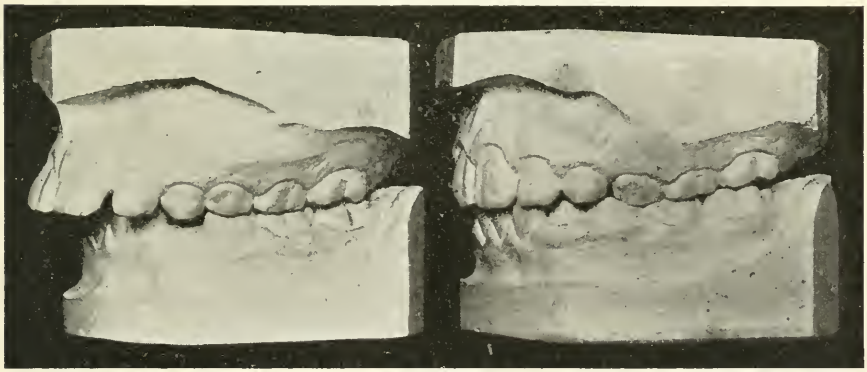

FIG. 582.

retention consisted simply of an inclined plane of gold attached to the upper central incisors, illustrated in Fig. 493, tending by its action at each closure of the mouth to cause normal locking of occlusal planes.

Antagonizing Spurs.—The simplest retention of the normal

mesio-distal relations of the dental arches after shifting the occlusion is by means of spurs soldered to the buccal surfaces of upper and lower molar clamp bands, which are so related that they act as an inclined plane continually forcing the occluding molars into their proper cusp relationship during each closure of the jaws.

Fig. 580 illustrates the positions of the buccal spurs for the retention of the mesio-distal relations established after treatment of a case of Class II.

In retention of the mesio-distal relations after treatment of Class III, the positions and angle of inclination of the buccal spurs should be reversed from that described for Class II.

The buccal spurs upon the molar bands are constructed of square wire, preferably of platinized gold or iridio-platinum, giving flat

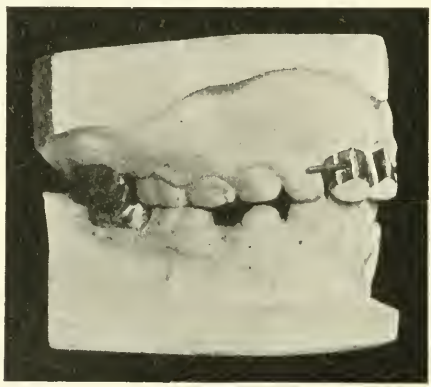

Fig. 583.

surfaces for the antagonizing of the two spurs in occlusion. These spurs are adjusted after a method suggested by Dr. M. T. Watson, being a modification of the spur and plane method used by Dr. Angle.

Occasionally it will be found that the buccal spur on the upper molar clamp band in Class II may be dispensed with, allowing the lower buccal spur to antagonize the plane of the mesial angle of the mesio-buccal cusp of the upper first molar, especially in cases in which the permanent bicuspids are unerupted.

The buccal spurs are also effectual in retaining single molar or bicuspid teeth which have been moved buccally or lingually into proper occlusion, as described by Dr. Angle.

Figs. 581 and 582 illustrate the right and left occlusion of a case of Class II, Div. 1, before and after treatment. It is useless in cases

in which the upper incisors are protruded to the extent shown in this case to expect that restoration of function of the inclined planes of the incisors will be sufficient to retain the normal relations of occlusion which have been established in the incisor region, and it is advisable to retain the mesio-distal change in occlusion until the eruption of the permanent bicuspids in a case undertaken as early as this one.

A buccal and occlusal view of the retaining appliances used in this case is shown in Figs. 583 and 584, the antagonizing spurs upon upper and lower molar bands serving to retain the normal mesio-distal relationship established between the arches, and the lingual arch, acting in

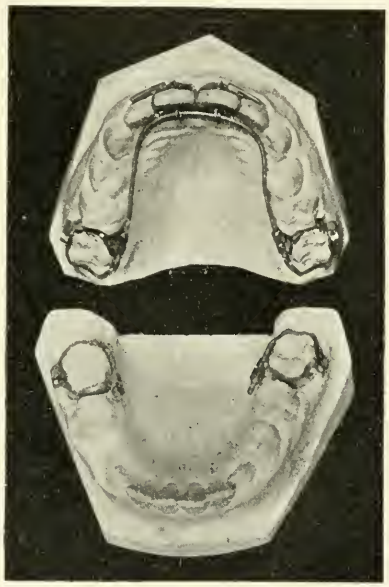

Fig. 584.

conjunction with bands upon the incisors, attached with lingual hooks, effectually retains the upper arch in its normal form and the upper incisors in their normal positions.

In severe cases of Classes II and III, it is always advisable to use intermaxillary retention in a continuation of intermaxillary force so gauged that it will not carry treatment farther, but simply balance the resistance in either arch.

In Fig. 585, the application of this force for the retention of a case of the first division of Class II, a lingual bar extending across the incisors from one cuspid band to the other, and soldered to bands upon the central incisors, having a hook at the disto-labial angle of each cuspid

band, the intermaxillary elastics extending from these hooks to similar hooks upon the buccal surface of clamp bands upon the lower first molars.

The expansion of either arch may be retained at the same time by lingual arches of iridio-platinum, attached to the cuspid bands and

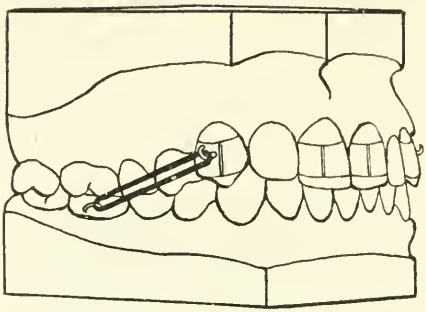

Fig. 585.

extending from the lingual screw of one clamp band to that of the other in the upper arch, and supported by such additional bands in the incisor region as may be necessary. The use of the lingual arch retainer in the lower dental arch is very similar to that in the upper, its attachments varying with the necessities of the case.

IX. CONSTRUCTIVE TECHNIQUE.

Advantages of Technique Instruction.—The author has long held the idea that a technique course in the construction of certain parts of orthodontia appliances is an essential training to the student in the mechanical treatment of malocclusion, and that the orthodontist of the future must be a constructive orthodontist.

At almost every sitting of the patient, there is an opportunity to mechanically readjust some part of the appliance, to make a band for one tooth, with spurs for more direct application of the force, to provide for rotation in another, and such other changes or additions as suggest themselves to the mechanically trained operator as being of value in shortening the time or increasing the comfort of the operation.

While it is unnecessary to construct the expansion arch and molar bands, and the traction screw, since they have been standardized and adaptable in the average case, it must be remembered that the angles of the tubes on molar clamp bands need to be frequently changed to suit the requirements of anchorage, and the breaking of such thin bands is not an uncommon occurrence, necessitating the repairing of the broken part if for no other reason than an economy of material.

Assuming, however, that the simpler cases of malocclusion need little, if any, construction work, in addition to the standard appliance which only needs adjustment, the field of retention, with its unlimited possibilities in the mechanical construction of retention appliances requiring a combination of art and esthetics in the production of an efficient and inconspicuous apparatus, looms up before one with a demand for the most consummate skill in the art of construction.

To the lover of the art of orthodontia, in the varied characteristics of mechanical construction in retention, where the ready-made appliance is of little, if any use, the mechanical and esthetic features present such scope for skill and originality as is not found in the same degree in any other part of the work.

Materials for Construction of Appliances.—The first consideration in a material for the construction of appliances to be used in the mouth should be the selection of a metal or alloy that will be the least affected by the fluids of the mouth, and which in turn will least affect the surfaces of the teeth with which it comes into contact.

Any orthodontia appliances in the mouth interfere more or less with the natural cleansing action upon tooth surfaces of the saliva, and the tongue and cheeks in mastication, and an appliance should not only be simple in design and application, but should be constructed of materials which will give the greatest immunity from caries.

Providing the quality of efficiency is not impaired by such a selection of material, the choice of metal or alloy for appliance construction is of paramount importance, the manner of its application and subsequent adjustment being of less moment.

Choice of Metals for Appliances.—So many different metals have been advocated in the past for the construction of appliances that it is necessary to point out from the standpoint of clinical experience those metals or alloys which are of the greatest advantage for use in the mouth, where physiological conditions must be taken into account.

German silver has occupied the field of orthodontia to the exclusion of almost every other metal or alloy for over fifteen years in the United States, and for mechanical efficiency in the possession of the requisite tempers for the manufacture of arches and bands, is almost an ideal material for the purpose.

From a physiological standpoint, however, there is much to be desired in a combination of metals for appliances to be used in the mouth than is possessed by the alloy of German silver.

A material which will not discolor nor corrode, and which is not attacked by the fluids of the mouth, at the same time possessing the

requisite temper for all the parts of an appliance, is much to be preferred.

The alloys of gold and platinum possess all these requisite qualifications, and the author has succeeded in obtaining such perfection in these alloys that any degree of temper, from the hardness of iridioplatinum to the softness of pure gold or pure platinum, may be secured.

German silver is acted upon by sulphuric, hydrochloric, and nitric acids; even a weak acid like acetic acid will attack it, forming a combination of the basic acetates of copper, which at least is not desirable. Pyrozone and iodine attack it vigorously.

In the mouth German silver discolors and in a large number of cases corrodes upon the surface, sometimes to the extent of perforating a molar clamp band. The pits formed by this corrosion become breeding places for bacteria, retaining, as they do, a certain amount of the soft foods in their cup-like pockets.

Potassium sulfo-cyanate, which is normally present in the saliva, which gives immunity to caries when present in sufficient quantity, badly discolors German silver.

German silver will sometimes leave a metallic stain upon tooth surfaces, which is difficult to remove, unless careful prophylactic measures are taken during the treatment of a case.

The alloys of gold and platinum will neither corrode, discolor, nor be affected by any acid or alkalie, except aqua regia.

The fusing point of platinum is 1775° Cent., of gold, 1075° Cent. An alloy composed of 90 per cent gold and 10 per cent platinum fuses at a temperature of 1130° Cent., which is very significant, proving that *pure gold* may be used as a *solder* upon this alloy without danger of fusing the latter, since the fusing point of the alloy is 55 degrees higher than the fusing point of *gold*.

An alloy of gold, 84 per cent, and platinum, 8 per cent, with a small percentage of copper, forms an alloy that may be graded in temper by the variation in the percentage of copper to a degree of hardness not attainable by any workable alloy of German silver.

Perhaps the most important feature of this alloy is that *hard soldered attachments may be made to an expansion arch of this combination without destroying the temper,* a process which the German silver arch will not stand without having its temper taken out, and making it inefficient as an appliance.

The point of chief importance in a gold alloy for appliance construction is that it shall contain sufficient platinum so that the fusing point

will be so high that the ordinary blowpipe flame will not melt it while soldering.

Gold alloys without platinum can be used, but invariably when soldered attachments are made to the arch in these alloys, if anything higher than 18k solder is used, the gold alloy is in danger of being melted.

With platinum alloyed with the gold in proper proportion, the author has soldered attachments to an arch of the alloy with 22k solder and even pure gold, an advantage that more than makes up for the slight difference in cost.

The Molar Clamp Band.—This same alloy of gold, platinum, and copper, offers the most advantages for the construction of the parts of the molar clamp band, with perhaps the exception of the nut on the lingual screw, which does not need protection by having a high fusing point, and may be made of a gold alloy without the admixture of platinum.

Iridio-platinum is also very useful for the band part of the clamp band.

Plain Bands.—Iridio-platinum in very thin sheet form, .005 inch, is an admirable material for the construction of plain bands, as it has every advantage of non-fusibility, lack of discoloration and corrosion in the mouth.

Retaining Wires.—Iridio-platinum wire, in gauges from 20 to 16, B & S., may be used for retaining wires, varying in diameter according to the stress. On account of its extreme rigidity, smaller and more delicate wires may be used in iridio-platinum than in gold or German silver.

Where extreme softness is desired in a retaining wire, platinum offers this quality in perfection, and when combined with gold, the temper may be varied to any degree to suit, at the same time retaining the high fusing point, which renders failure in soldering operations impossible.

As far as expense is concerned, the author has found the use of the noble metals for appliances an investment, since their value as "scrap" alone is considerable at the end of a year.

If the advantage of the "all gold" appliance is explained to the prospective patient, he is usually willing to pay the difference between its cost and that of the German silver appliance.

In the author's estimation, the adoption of the "all gold" appliance has done more to raise the standard of orthodontia than any other recent advance in the science.

The esthetic appearance of the appliances in the mouth gives the

operator himself a better appreciation of his own work than if they were constructed of the base metals, and presented a discolored and unsightly appearance, and thus insures a greater interest in his work, which is the only stimulus towards advance in methods of treatment.

The adoption of the "all gold" appliance is related to and is as imperative an advance in practice as sterilization of instruments, and prophylaxis, and the conformation of dental and orthodontic practice to their demands is only a question of time.

Soldering Technique.—The attainment of skill in constructive technique in orthodontia lies chiefly in one's ability to perform difficult soldering operations in a rapid and efficient manner, involving a training of the eye as well as the hand in the approximate relationship of the aggregated units of a given appliance, without waste of time or effort.

The workbench of the orthodontist is not complete without every facility for easier and more rapid methods of soldering than are obtainable by the investment of pieces to be united, or the approximation of parts by the use of bulky tweezers , and the use of the large flame of the Bunsen burner.

The requirements for this class of soldering operations are as follows:

1. A blowpipe flame of proper fineness and easily controllable.
2. Clean, bright surfaces on parts to be united.
3. Easy flowing solders, cut to graded sizes for various purposes.
4. A quickly acting flux in convenient form to apply.
5. Perfect approximation and fixation of parts to be united.

Taking up these requirements in order, the form of blowpipe should receive the first consideration.

The necessities of the work require that a blowpipe should not be more than a few inches in height, the burner to be upon a substantial base, and having attached to it easily adjustable valves for both gas and air, the tip of the burner being so constructed that a continuous fine, needle point flame of sufficient intensity may be obtained, and varied in size and intensity by valve control to suit the needs of the varying size and bulk of appliances to be soldered.

The Kerr Blowpipe.—The most perfect blowpipe which answers these requirements, is the Kerr blowpipe, suggested by Dr. J. Lowe Young, and is illustrated in Fig. 586.

While a compressed air outfit is most desirable in connection with a blowpipe of this kind, the ordinary bellows will answer the purpose, providing it is large enough, so that the foot does not have to be used in pumping except at long intervals.

A clean, bright surface is always essential to a successful attachment of solder, and oxidized surfaces should be carefully polished with a fine sandpaper disk in the engine before soldering, or boiled in alum solution and polished on the lathe.

The tendency to use too large pieces of solder may be overcome by grading the size of the pieces according to the size of the parts to be united, the larger parts requiring correspondingly larger pieces of solder than the smaller ones.

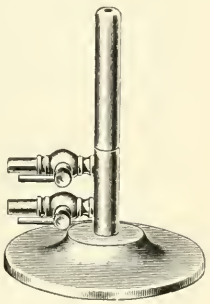

FIG. 586.

The four sizes of pieces of German silver solder illustrated in Fig. 587, being respectively one-sixteenth of an inch square, one-sixteenth by one-eighth inch, one-eighth inch square, and one-eighth by three-sixteenths of an inch in size, will be found most convenient for all ordinary purposes.

The smallest size may be used for soldering on spurs at right angles to bands, and the threaded portion of the anchor clamp band to the end of the band. The next larger size is adaptable for uniting spurs to bands parallel to the surface of the bands, the next larger pieces for uniting the short tubes of the anchor clamp clands to the bands, as well as in other places in which an equal bulk of solder is indicated, while the largest pieces of solder may be used in uniting the large buccal tubes of the anchor clamp bands to the bands, also useful in such unions as the buccal retaining spurs of heavy wire on the anchor clamp bands in Class II retention.

It is possible in the use of German silver to perform a number of soldering operations in close proximity, using the same low fusing silver solder for each one without seriously endangering the fixation of previously soldered parts, if the flame is used fine enough and directed only upon that part of the appliance to be soldered last.



FIG. 587.

The high fusing silver solder is a little contrary and the occasion for its use is seldom found.

In the use of gold solder, on account of its thickness, the size of the cut pieces should not exceed the next to the smallest size shown in Fig. 588 for the maximum.

The use of more than one grade of solder is especially valuable, for example, in constructing the plain band, which often requires a spur soldered so close to the line of union of the two ends of the band that in the second soldering operation for the spur attachment, the first union may easily become unsoldered where but one grade of solder is

used for both. Again, in construction of retaining appliances, the advantage of the use of several grades of solder is apparent.

Easy flowing solders of either gold or silver are obtainable at the depots, and in the use of the gold solders, for making attachments upon gold or platinum appliances, an intelligent use of the higher carats in the uniting of primary parts, with the consecutive use of a lower carat for secondary attachments, will give assurance of the success of each soldering operation in their order, and if the degree of heat is properly gauged, the union of a number of very small parts in close approxima-

Fig. 588.

tion may be much more safely accomplished than if but one grade of solder were used.

Next in importance in soldering operations is the use of a flux which will quickly cleanse the oxidized surfaces so that the solder will flow readily. Borax is the usual constituent of all fluxes for hard solders of either gold or silver, and when properly calcined and prepared for convenient use, will answer every purpose. A favorite method of some operators is to have a specially prepared borax slate with various sizes of solder mixed with creamed borax on its surface, ready for immediate use. Considerable time is consumed in mixing the borax before every soldering operation in this manner, and the displacement of the sol-

Fig. 589.

der from position when placed in the flame is an annoying and not infrequent occurrence.

To alleviate these difficulties, the author has had prepared and placed upon the market a specially prepared wax soldering stick, of the size and shape shown in Fig. 588, and containing a calcined borax flux, which is not only instantaneous in application, but by means of the wax body, fixes the piece of solder in position so that it cannot be displaced before it fuses. The only caution necessary in its use is that the surface to be soldered should be slightly warmed, and not heated to redness, before touching with the wax stick.

A pair of solder tweezers of the size and shape shown in Fig. 589, should be use for picking up the pieces of solder, and its points should be kept clean and out of the soldering flame in order to be in proper condition to use.

For cutting the solder into convenient sizes, a pair of small shears with especially strong blades, such as is illustrated in Fig. 590, is especially adapted for use at the operating bench, being preferable to the larger laboratory shears for the purpose.

A number of years ago, the author devised a set of delicate clamps for the approximation of the various parts of bands and appliances while being united with solder, and the ten years of constant use and improvement have brought them up to a standard of perfection which

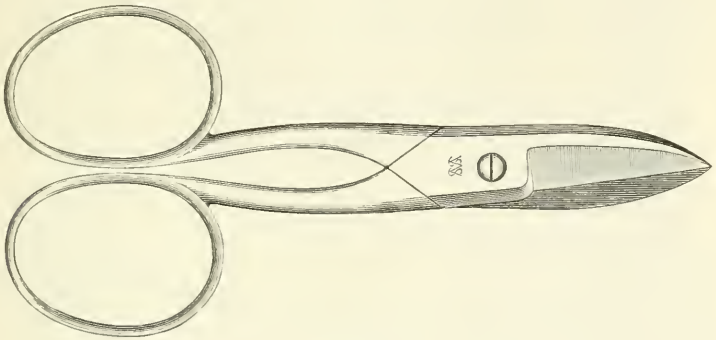

Fig. 590.

makes the operation of soldering extremely simple, accurate and rapid, as well as saving in time, patience, and nerves from the old finger method.

There is hardly a single practical combination of appliance parts that cannot be perfectly adjusted in these clamps, the original set of which is shown in Fig. 591.

The Magill Band.—One of the most important adjuncts to the direct application of force to the upper and lower ten anterior teeth, is the Magill band, or plain band as it is sometimes called.

It may be constructed of gold, platinum, iridio-platinum, platinized gold, gold alloyed with platinum, or German silver according to the particular qualities desired. The author prefers the iridio-platinum, constructed of sheet iridio-platinum of about 36 gauge, B. & S., and the platinized gold band of the same gauge.

The construction of the Magill band in the precious metals is similar to that in German silver except that the gold solders of varying grades are used in the former.

German silver band material may be found at the depots in three thicknesses, according to the degree of strength required, being fur-

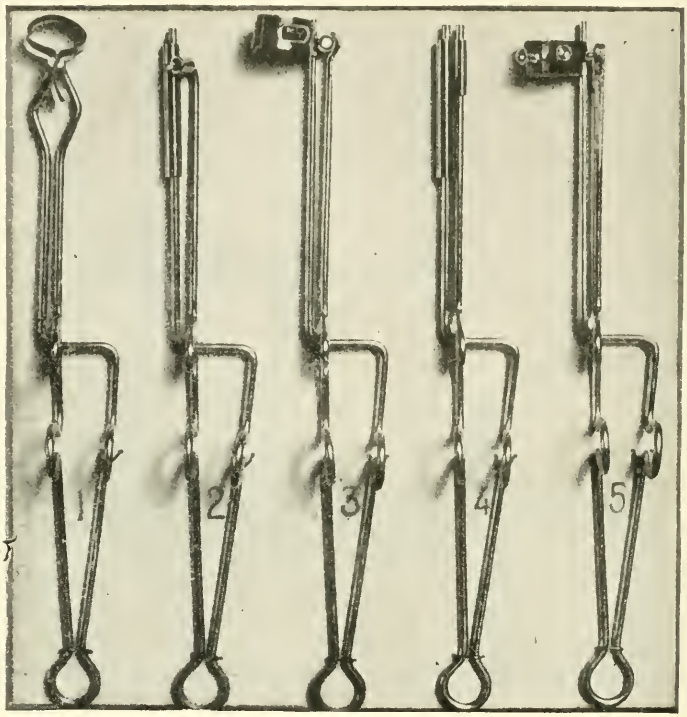

FIG. 591.

nished in coils, convenient for ready use, which represents that which is sold with the Angle appliances. The heavier or thicker form of band material is used where great strength and durability is required,

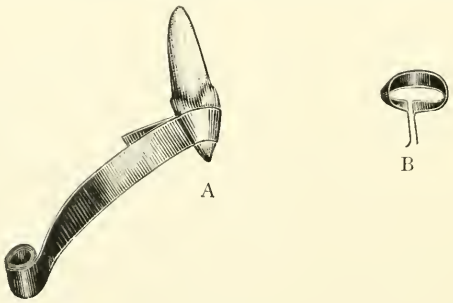

FIG. 592.

as for cuspid and bicuspid bands, and for retention; the thinner material where strength and durability may be sacrificed for incon-

spicuousness and neatness of appearance and fit, as in the banding of lower incisors, and for temporary retention.

The band material should first be formed into a loop with the fingers, and the two sides of the loop forced between the mesial and distal approximating surfaces of the tooth to be banded and the adjoining teeth, forcing it well up toward the gingivæ, and after pulling it taut on the lingual surface, pinching the ends of the loop together close to the tooth surface, as at A in Fig. 592, with the Angle band forming pliers, shown in Fig. 593. The ends of the band material should meet at right angles at the point of union, so as to form a continuous inner surface of the band when soldered, as in B in the same cut.

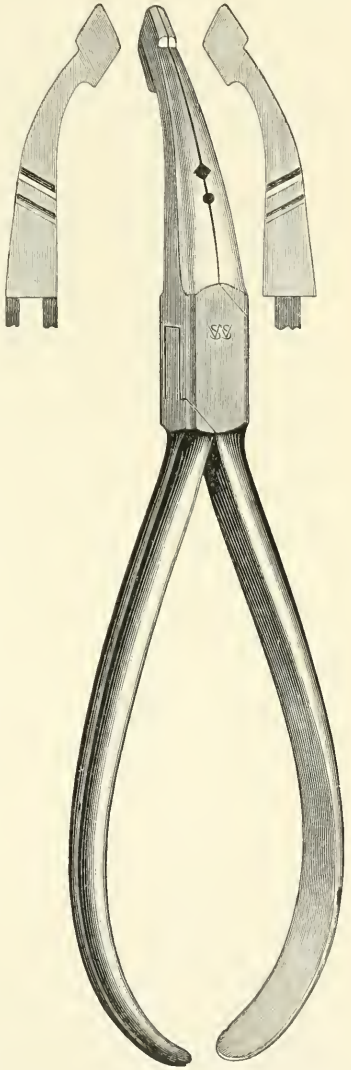

Fig. 593.

The Magill band should not be fitted too closely to the tooth surface, for some looseness is necessary to provide space in order to contain the cement in sufficient bulk for proper fixation of the band and protection of the tooth surface. The burnishing of the margins of the band may be done after it is in position and the cement still soft. A slight trimming of the upper mesial and distal margins so as to not encroach upon the gum tissue is permissible.

Oftentimes, especially in the case of the cuspid band, it is advisable to unite the band upon the labial surface of the tooth, a notch in the projection of the united ends making a convenient spur for the arch to rest in or for the ligation of the cuspid when in infra-occlusion, etc.

Soldering The Band.—In uniting the ends of the Magill band with solder, they should be held by a No. 1 soldering clamp, and a piece of solder one-eighth of an inch square placed in the seam, where it is

held in position by the pressure of the clamp, as in Fig. 594, and after touching the wax stick to the slightly warmed seam so that a small portion of the flux is melted into it, the ends to be united should be held in the needle flame of the blowpipe until fusion occurs. The surplus ends are next cut off, and the ridge which remains polished smooth with the sandpaper disc, after which the band is transferred to a boiling solution of alum to deoxidize it, and then polished and plated. If it is not to be cemented on at once, it should be properly ticketed and filed until the next sitting.

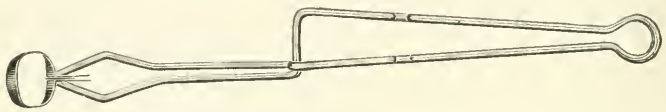

Fig. 594.

Accessories to the Magill Band.—As the Magill band is usually utilized for the more direct attachment of ligatures, and for retaining appliances, as well as for lever tubes and traction screw tubes, the various methods of making these attachments should be carefully studied. Where the banded tooth does not need rotation, but simply a direct movement toward the arch, a notch in the seam of the band will prevent the ligature from slipping, as in A, Fig. 595.

Lingual spurs for rotation may be attached as in B and C, Fig. 595, the pinhead spur being soldered with the No. 5 pinhead clamp of the set of soldering clamps, the clamp itself requiring the use of but

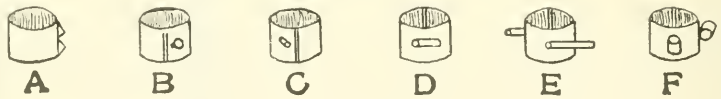

Fig. 595.

one hand, as it automatically holds the pinhead in exact position at any desired point on the band.

For soldering on wire spurs the procedure is somewhat different; the band should be held in a No. 1 clamp in the left hand, and a length of spur wire which has a ball of solder attached to its end adjusted with the right hand, the third fingers of each hand touching so as to give support and steadiness while the parts to be united are held in the flame.

The retaining spurs shown in E, Fig. 595, are attached very similarly to the ligature spurs, except that the wire is held against the band lengthwise, with the right hand, the surface of the band having had

a small piece of solder about one-eighth of an inch square fused upon it previously.

The lever tube, in D, Fig. 595, is cut off the desired length and held in approximation with the surface of the band by the No. 3 clamp alone, or the band may be held by No. 1 clamp, while a long piece of lever tubing is attached with solder to the band surface and afterwards cut off and polished.

Larger sized tubing for the ends of the traction screw, as at F Fig. 595, may be adjusted to position with the Nos. 2 and 4 clamps, as illustrated in the photograph in Fig. 591. The short tubes may be held in the tip of the No. 4 clamp at any desired angle to the band while being soldered, being especially useful in the attachment of the tube at one corner of a cuspid band for the end of the traction screw.

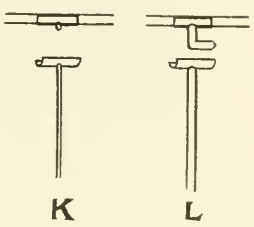

FIG. 596.

Spurs and Hooks for Expansion Arch.—For convenience in use, and saving of time at the chair, a number of pieces of iridio-platinum, platinous gold or German silver wire of two different sizes, 18 and 21 gauge, B & S, about four or five inches long, should be made up, having a ball of solder attached at both ends.

The spur for the expansion arch should preferably be made of the 21 gauge wire, as it does not need to extend as far from the surface of the arch as a spur of larger diameter.

If made of German silver, a piece of band material is first bent around the arch, forming a loop, to the convex surface of which the spur wire is soldered, as in K, Fig. 596. The band material is then trimmed down so that it will encircle about one-half of the circumference of the arch, and after polishing the concavity of the half cylindrical piece, with the sandpaper disc, a small portion of soft solder is melted into it, fluxing with phosphoric acid, and then it is united to the clean surface of the arch at the desired point. In fusing the soft solder, the parts should not be held in, but above the flame, so as not to take the temper out of the expansion arch.

The hook for the attachment of rubber elastics to the arch, is constructed in a similar manner, bending it into a hook and finishing the point so as to avoid irritation, after soldering it to the arch, as illustrated at L, Fig. 596.

In making a hook for a platinous gold arch, a piece of 21 gauge, B & S iridio-platinum or platinous gold wire may be soldered directly to the expansion arch with an 18k gold solder and afterward bent into

hook form and cut off the requisite length, the temper of the arch not being affected by this process.

Assembling the Parts of Molar Clamp Band.—The molar clamp band is made up of a short piece of band material, and a lingual



Fig. 597.

screw passing through a short tube soldered at one end of the band, adjusted with a nut turned upon the lingual screw.

Although it is not essential that the operator make his own clamp bands, it is often necessary that he reconstruct clamp bands which have broken under some unusual stress.

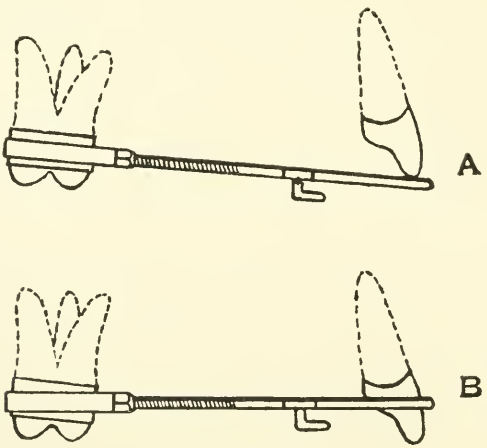

Fig. 598.

For easily and quickly soldering the band and the lingual screw, the author makes use of a special clamp, illustrated in Fig. 597, which holds the two parts in adaptation during the soldering operations. The solder and flux are always placed between the parts to be united before placing in the flame.

The short tube is held in apposition with the other end of the band with a No. 2 clamp of the set previously described, as in Fig. 591.

The band is formed in a circle, the screw thrust through the lingual tube and the nut adjusted to it, when it is ready for the attachment of the buccal tube.

Soldering Buccal Tube on Molar Clamp Band.—This operation is one that is frequently done and requires so much exactness that the aid of special clamps is almost indispensable to facilitate rapid and correct soldering of these parts.

Almost two-thirds of the "German silver" molar bands purchased at the depots have to be subjected to a change in the position of the tube so as to secure proper alignment of the arch wire, see Fig. 424, and to look attractive, must be replated before placing in the mouth.

During the treatment of Class II and III cases, the tipping of the anchor teeth distally and mesially requires a realignment of the anchor tubes occasionally to keep up the efficiency of the anchorage. To prevent the expansion arch from dropping below the edges of the incisors, as at A, Fig. 598 in a Class II case, the anchor clamp-bands should be removed and the buccal tubes realigned so that the expansion arch will rest upon the surfaces of the incisors as at B, Fig. 598.

The technique of this operation is as follows:

The molar clamp band is held in a vice like grip in the dog jaw of special clamp No. 6, Fig. 599, on the opposite side from the threaded wire extension with nut as to enable this clamp to be held in the fingers of the left hand, while those of the right control clamp No. 7, which engages the buccal tube, with the sheath end toward the handle of the clamp.

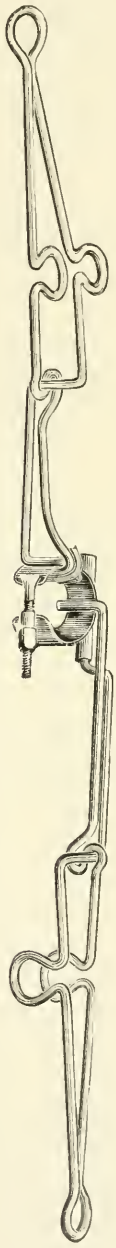

Fig. 599.

Having previously fastened a piece of solder about one-eighth of an inch square on the buccal side of the surface with the wax flux, at the point at which the tube is to be joined, and placed some of the wax flux on the center of the side of the tube, the right angle arm of the No. 7 clamp is placed on the lingual side of the band, and the arm holding tube is allowed to drop down into position on buccal surface of the band, pinning the solder and flux underneath. The tube is aligned horizontally with edge of band, and

then the clamp band and tube are held in the flame of blowpipe until solder flows perfectly.

The Pivotal Anchor Tube.—It will be found valuable to solder a short piece of 14 gauge, B & S round wire between the buccal tube and the clamp band, as in Fig. 600, forming a pivotal anchor tube, which possesses sufficient strength for the support of the arch under all conditions, and at the same time will allow of sufficient change of inclination of the anchor tube by upward or downward twisting, with a pair of pliers for any arch alignment desired, doing away with the necessity of removing cemented bands and unsoldering the anchor tubes to realign them.

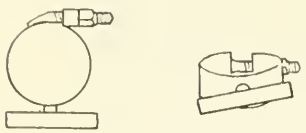

FIG. 600.

The short piece of wire should be of German silver for the German silver clamp band and of platinum for the gold clamp band.

X. PLASTER TECHNIQUE.

Necessity for Accurate Models.—The primary importance of diagnosis in the consideration of the possibilities of treatment of malocclusion, renders it necessary that accuracy in the models of the teeth should be an essential feature.

The casts of each dental arch in occlusion should represent, to the minutest degree, the exact variation of the occlusion from the normal, the depth of cusps and length of overbite, the compensating curves, and separately should exhibit all the fine lines of the anatomical structures which it is intended they should copy, such as the rugæ and stipples of the gum tissue, the form and attachment of the frenum labium, the height and width of the palate, abscess, fistulas, and pathological conditions such as hypertrophy of the gingivæ, the degree of development of the arch well up to the line of demarcation of the cheek and gum tissue, and especially the perfection or imperfection of every tooth surface, including developmental grooves and inclined planes, and the facets of the cusps, which latter, to the experienced eye, tell a story, which can be learned in no other way, of the articular movements of the mandible.

Reference to the model during and after treatment of a case is of value in indicating the changes in development of the alveolus, and the influence of inclined planes in determining normal cusp relationship when working in harmony with normal sized arches and normal occlusion and articulation.

A collection of finely made models serves not only as a library

of reference and study, but also as an accurate indication of the individual skill of the operator, both in the making of the models themselves, and in the perfection of treatment which they exhibit.

Were the laity possessed of sufficient knowledge of the possibilities of treatment of malocclusion, they might, by comparison, choose the more expert orthodontist by the results which are exhibited in his model collection, which, to a degree, show his skill, his experience and his artistic ability.

The model serves as a guide to arch determination and indicates the proper relations of retaining appliances upon completion of the treatment.

Medico-legally, the plaster reproduction of the teeth in the model is an accurate record of fact, which is accepted as evidence in a court of law, thereby ensuring some protection to the operator from the unappreciative and dishonest who resort to questionable methods in the evasion of their just obligations.

Impression Materials and Methods.—Plaster-of-Paris has long been recognized as the ideal material for taking accurate impressions of the teeth, casts from which are absolutely accurate in detail of reproduction, as in surgery, its use in the reproduction of internal or external structural anatomy has not been superceded by any other material.

Dr. E. H. Angle was the first to place model making in the list of the arts by the introduction of a method, which in its main characteristic, is still followed, the improvement in technique and detail which have been suggested by others in the same field being here described.

As the impression in plaster will reproduce the finest lines of tooth surfaces, care should be taken that all hard and soft deposits be removed, and the teeth thoroughly cleaned before the impression is taken.

The Impression Tray.—The Angle impression trays, illustrated in Fig. 601, are especially adapted for taking full impressions of either arch, having high rims, and being so shaped and polished that they may be removed soon after insertion in the mouth by a slight manipulation, leaving the setting plaster in the mouth to be sectioned and fractured and removed in several pieces.

Trays should be selected according to the size of the mouth, large enough to allow for at least one-eighth of an inch of plaster between the teeth and the sides of the tray, which will admit of a slight bending for such adaptation.

These trays are provided in graded sizes 21, 21½, 22, 22½, and 23 in the upper set, and in corresponding sizes 24, 25 and 26 in the lower set. A few more intermediate sizes are still desirable.

The surfaces of the impression trays should never be scratched or indented, as any marring of the surface prevents easy removal of the tray from the impression in the mouth. It will be found an economy

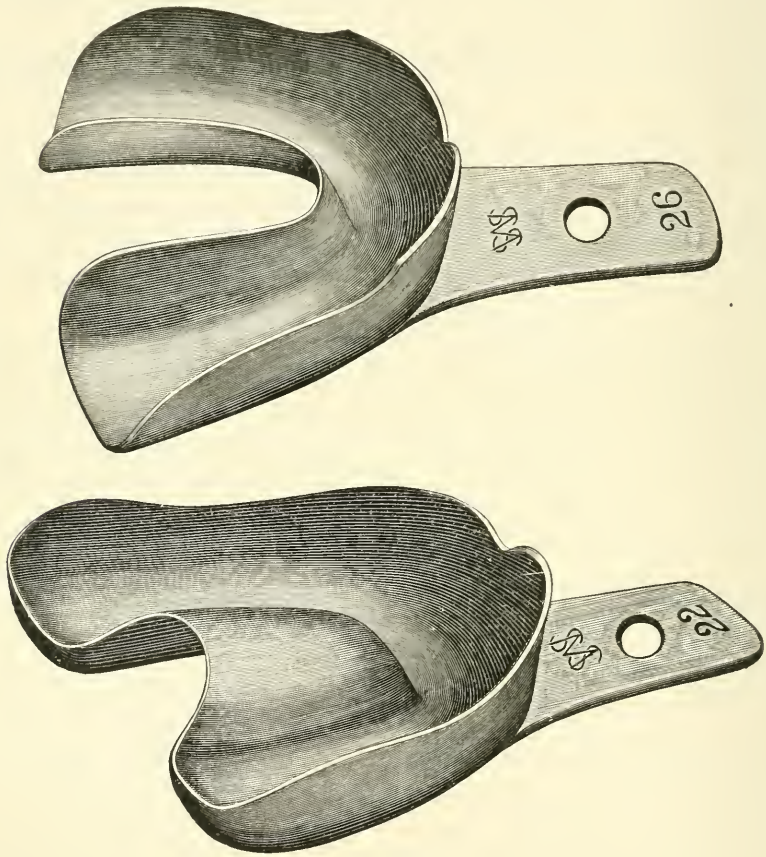

Fig. 601.

of time and money to replace slightly marred trays with new ones from time to time.

Mixing of the Plaster.—On account of the quick setting of impression plaster, the use of salt or potash for hastening this process is unnecessary in the plaster mix, in fact, they are detrimental to the securing of a perfect impression because of the haste necessary in manipulation, and the coarseness of crystallization of the plaster, which is destructive of the fine lines on the surface of the impression.

Distilled water at a temperature of about 70° F. is preferred for obvious seasons.

The quantity of water necessary for the usual mix should be somewhat accurately gauged, and the plaster gradually sifted in until it absorbs the water completely, when it is ready for immediate pouring into the tray which has been selected a little larger than the arch of which an impression is desired.

Only the best impression plaster should be used, French's plaster as furnished by the depots in a metallic can with tightly fitting cover being preferable, as it may be kept perfectly clean and dry in this receptacle.

Distribution of Plaster in the Tray.—If the impression is to be of an upper arch, the palatal portion of the tray should not be covered with the plaster, the rest of the tray being about three quarters filled, and a small surplus allowed to rest upon the handle to be forced under



Fig. 602.

the lips. If necessary, the buccal and labial spaces may be first filled, using a bone or glass spatula to carry the plaster to place, as suggested by Dr. A. P. Rogers.

The tray is then inserted in the mouth, and pressed quickly into position, taking care that the teeth are about equally distant from either side and the bottom of the tray. While being held in position with the middle finger of the left hand, the surplus plaster may be cleaned from the tray with the tweezers and cotton.

The impreession should be allowed to harden until it will fracture properly, when the tray should be removed by exerting a slight and uniform downward pressure upon the handle, and surplus pieces removed from the mouth with the tweezers and cotton.

The impression should next be grooved vertically, usually over the cuspid region, on both sides with the knife shown in Fig. 602, which is best adapted for reversal in grooving both upper and lower impressions without danger of cutting the lips, the short curved blade being admirably shaped for skillful manipulation.

By prying from the bottom of one of the grooves with this same knife, after the plaster is hard, the central section of the impression may be removed easily, and the two buccal portions by exerting an

outward prying motion with the thumb against the anterior edge, leaving the palatal portion to be gently pried out with an instrument.

Fig. 603.

The pieces are then placed in a small box upon which is marked the name and date and age to be copied later upon the posterior surface of the cast.

Fig. 604.

The lower impression differs from the upper only in the detail of the manipulation of the tray, care being taken not to allow of an excess of plaster in the distal ends of the grooves.

Figs. 603 and 604, loaned by Dr. Rogers, represent very perfect lower and upper impressions of the teeth after the fractured pieces have been assembled.

Assembling the Impression.—The fractured pieces should be thoroughly dried, over night usually, although they may be quickly dried by placing them upon a piece of tin over a burner, and then assembled, beginning with the larger pieces, adding one at a time, and dropping a small bead of hard sticky wax upon the outside of the impression at intervals of about one-quarter of an inch along the lines of fracture, as illustrated in Fig. 605. The edges of the fractured pieces should be cleaned of crumbled pieces before uniting them.

Fig. 605.

Occasionally, it will be of advantage to replace broken pieces in the tray but, as a rule, better results are obtained without doing so.

Varnishing the Impression.—After being properly assembled, the impression should be varnished with a solution of shellac allowed to dry for half an hour, and then varnished with a solution of sandarac, repeating the last varnish again in another half hour. These solutions are so thin that they do not leave any perceptible coating upon the surface of the impression, although rendering it easily separated from the cast, the shellac giving a color line to cut to, and filling the pores, and the sandarac simply filling over the surfaces of the pores, so that capillary attraction cannot take place.*

*According to Angle, these solutions should be prepared in the proportions of 1 ounce of shellac to $3\frac{1}{3}$ ounces of alcohol, for the shellac varnish and 1 ounce of sandarac to $2\frac{1}{2}$ ounces of alcohol for the sandarac varnish.

Filling of the Impression.—The varnishes being thoroughly dried, the impression may be placed in a basin of clean water to become infiltrated from the outside with water, while the plaster is being mixed ready for its pouring.

A slow setting model plaster is preferred for the cast, although many have used the impression plaster with good results, its fineness giving a very beautiful surface.

The plaster should be mixed in the same manner as for the impression, and a small portion placed in the heel of the impression and carefully worked forward from one tooth cusp to another with the camel's hair brush, until all the cusps are perfectly filled, when the remainder of the impression may be quickly filled with the plaster knife, which should be of platinoid so as to prevent rusting.

A large portion of the plaster should be placed upon a clean glass slab and the impression inverted thereupon, and pressed down so that

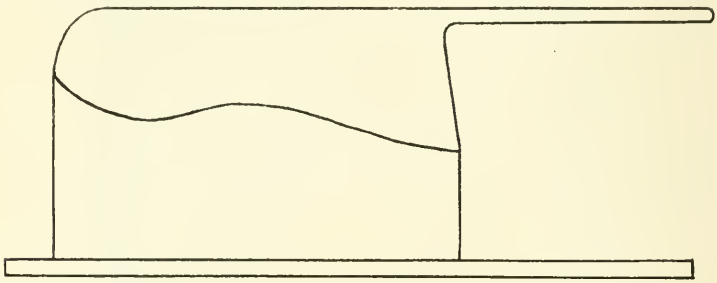

FIG. 606.

the anterior edge is within one-half inch of the glass surface, preserving a parallel between the bottom of the impression, or tray, if present, and the horizontal line of the glass slab, as in Fig. 606. The surplus plaster is then trimmed away with the plaster spatula, and the plaster allowed to harden for about twenty minutes before it is ready to be again touched.

Sectioning and Removal of Impression.—The impression is more easily removed from the cast within half an hour from the time of its filling, as it then contains the greatest amount of moisture. However, it should be immersed in water again for a few seconds to still further soften the surface before attempting to separate the impression from the cast.

The small beads of wax should be cut off and the portion of the cast extending above the impression roughly trimmed with the larger of the two plaster knives shown in Fig. 607, to approximately the shape to which it is intended to conform when finished.

The sides of the impression may then be vertically and horizontally grooved as in Fig. 608 using the smaller knife shown in Fig. 607, the two knives being suggested by Dr. Rogers.

The depth of the grooves should not be greater than the brown color of the shellac varnish, which appears as the bottom of the groove approaches the surface of the cast.

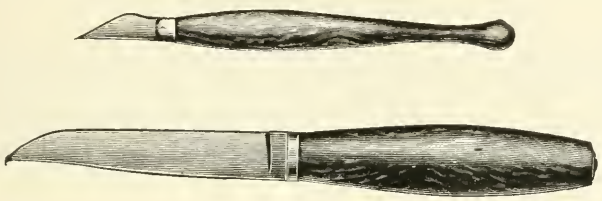

FIG. 607.

Beginning at the heel of the impression, one section at a time is pried away with the grooving knife, removing the upper sections first.

The author prefers to shave down the surface above the occlusal surfaces of the teeth until the brown color above the prominent tooth cusps begins to appear before making the vertical and horizontal

FIG. 608.

grooves in most cases, and many times a single vertical groove in the region of the cuspid on each side is sufficient for the easy removal of the sections extending from these grooves to the heel of the impression. The front of the impression should almost always be horizontally grooved to prevent accidental injury to the cast in removal.

Oftentimes, the lines of fracture, which may run along the cusp

surfaces of the teeth, will facilitate the removal of the impression very materially.

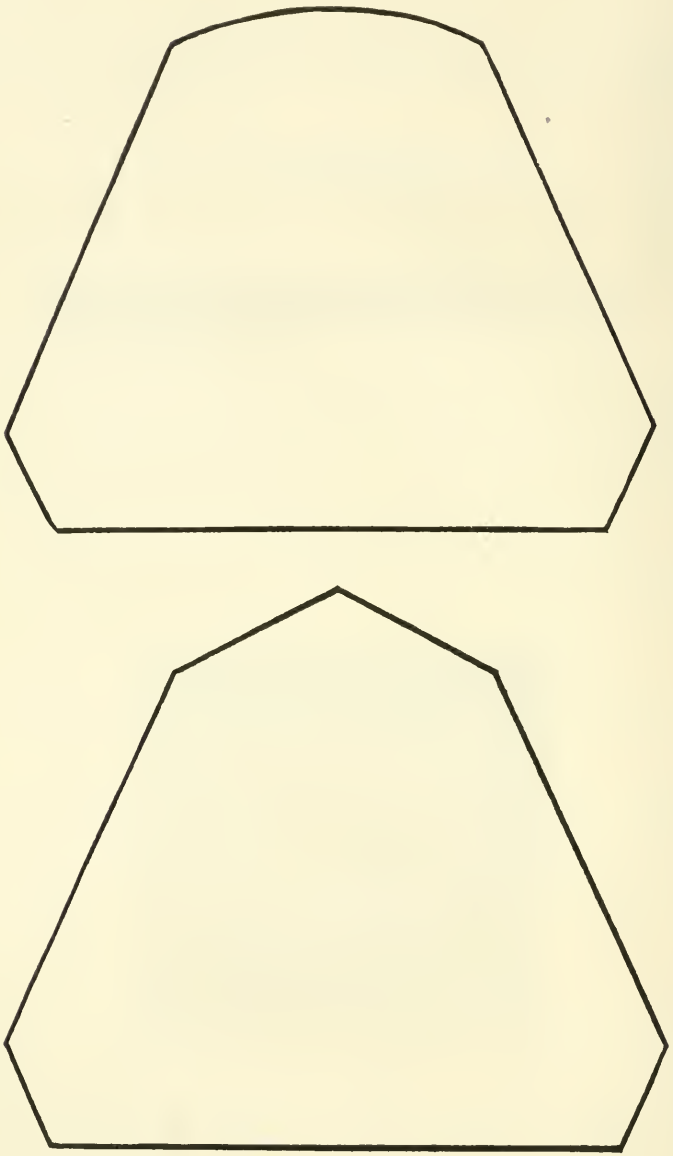

Fig. 609.

It will almost always be found necessary to groove the lingual surface of the impression upon a lower cast before it is possible to remove it.

In an upper impression also, it will often be necessary to make a groove lengthwise of the palatal section of the impression and then remove one-half of the palatal portion at a time.

It is well to mark on the surface of an impression, before pouring, the positions of teeth in labial or lingual occlusion, to prevent marring them in the sectioning process.

Trimming of the Model.—After the removal of the casts from the

Fig. 610.

impressions, they should be moistened in clean water, and then roughly trimmed to the geometrical outlines which have been accepted as most artistic and harmonious for each cast, the base, for the lower cast, being carved to the design at the top of Fig. 609, with slightly rounded front, and the upper cast, to the pattern at the bottom of this figure, being precisely similar, except for the pointed front, which not only affords extension for a frenum labium of varying sizes, but gives a pleasing and distinctive variation to the capital of the model.

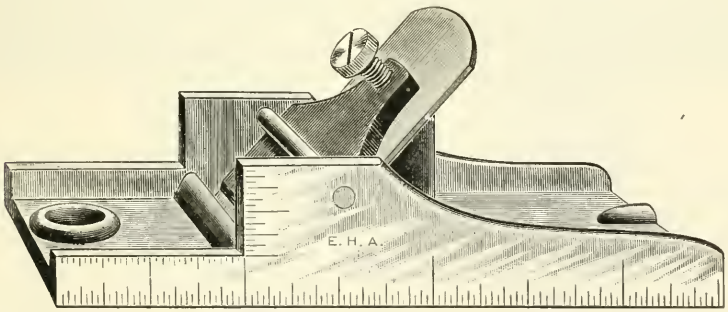

Fig. 611.

From a geometrical standpoint, the two patterns present the forms of two triangles with equiangular basal angles which have been clipped by lines parallel to the lateral lines of the triangle from one-quarter to one-half an inch in length, and the anterior angle cut across from intersections directly over the cuspids on the lateral dimensions by the curve on the lower cast and the obtuse angle on upper cast.

Constructed upon these lines, the base and capital present almost

similarly formed designs, with the long sides of the triangles parallel to the buccal surfaces of the bicuspids and molars, and the median line of the anterior sections equidistant from the cuspids, except where there is much divergence of the anterior teeth mesially or distally, when the median line of the capital may be made to coincide with the central line of the cast as indicated by the rugæ.

Proceeding first with the rough approximation of these patterns with a broad bladed plaster knife of hardened steel and an edge so sharpened that the flat surface of the blade is a perfect plane on either side, as in Fig. 610, the lower cast, or base of the model, should be so carved that the plane of the occlusal surfaces of the teeth should be as nearly as possible parallel to the horizontal.

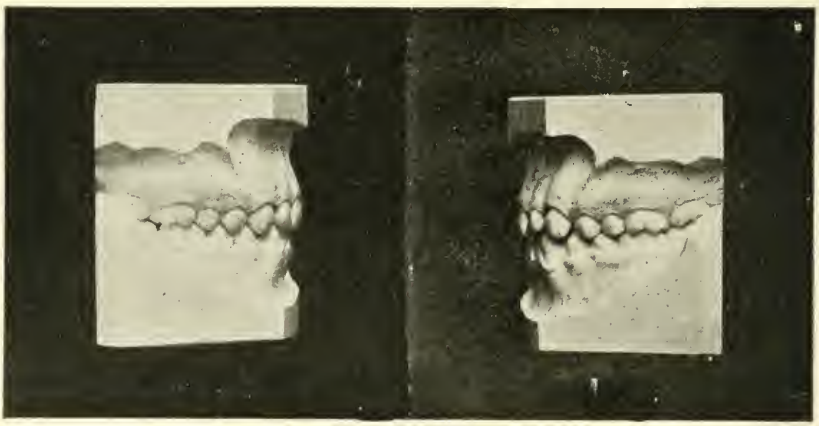

Fig. 612.

In cases in which the compensating curves are very marked, the plane of occlusion might be represented by the plane passing through or touching the tips of the distal cusps of corresponding molars on either side and the edges of the central incisors.

The under surface of the base of the model should be evened with a small plaster plane having a very sharp blade as is shown in Fig. 612, representing the Angle plaster plane. The angles which the anterior and lateral planes make with the base should all be right angles, and the planes which they enclose will then all be vertical ones.

The thickness of the mechanically finished portion of the cast is determined somewhat by the size of the anatomical portion, but should seldom, in a cast of the permanent teeth, be less than one-quarter of an inch in the height of the anterior vertical planes.

After the lower cast is properly aligned and finished to form the

base of the model, the upper cast is cut to approximate the pattern shown on the right in Fig. 609, and is then placed in occlusion with the base so that all surfaces and angles of the capital may harmonize with those of the base.

Fig 613.

The upper surface of the capital should be planed down until it is parallel with the horizontal, unless it is too thin, in which case the required thickness may be secured by inversion of the occluded model, capital downward, upon a small quantity of fresh plaster upon a glass

Fig. 614.

slab, it being necessary only to manipulate the model so that the base of the model will be in the horizontal plane as judged by the eye.

The planes of the sides of the capital should be all vertical planes, and the posterior vertical planes should coincide, if possible, giving

an accurate guide to the occlusion if it should not have been marked on the cusps, as shown in Fig. 612.

The small brass plane with bronze blade, illustrated in Fig. 611, is very useful for trimming model surfaces, especially as much more accurate surfaces can be made with it than with the knife.

The mechanically finished surfaces of the model may be made still smoother by finishing with a fine broad, flat, jeweler's file after the casts are perfectly dry, as suggested by Dr. A. P. Rogers.

A slight bevel cut around the entire edge of both capital and base adds to the artistic finish, and preserves the model from chipping of otherwise sharp angles in handling.

The trimming of the capital and base according to certain definite

Fig. 615.

geometrical lines, is not only the most artistic and best proportioned conformation of otherwise ungainly reproductions, but it serves the very practical purpose of a standard for uniformity which enables the busy orthodontist to more quickly and consecutively follow out the definite rules for obtaining esthetic effects than by the old and less accurate methods of model trimming.

The anatomical portions of the model should represent perfectly the parts which they are intended to reproduce, and will be perfect in proportionate degree to the care which has been taken in the consecutive steps of its production.

Marking and Numbering of Models.—When such infinite pains have been taken and artistic skill used in securing a beautiful and harmoniously proportioned model, it should not be ruined by marking the

name of patient, the age and the date of commencement of treatment upon every surface of the mechanical portion, as is often done.

Each model needs its serial number for the cabinent, which may be marked with india ink upon the labial surface of the base of the model and the posterior surface of the capital, leaving all other anterior surfaces of the model void of any marks whatever. The name, date, age, etc., may be noted on either of the posterior surface of the capital or base.

In numbering, it is advisable to select alternate odd numbers for treatment models, leaving the alternate even numbers for the after-treatment model.

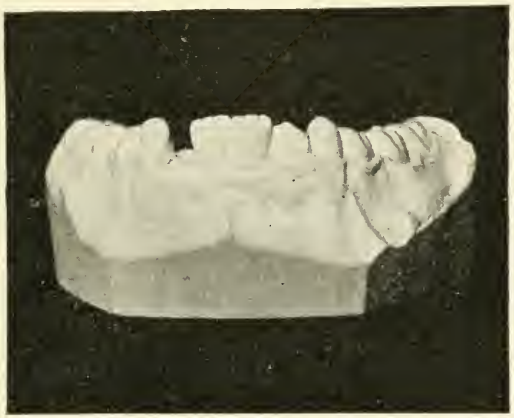

FIG. 616.

Repairing Defects.—If a good impression has been first secured and the detail of assembling of the fractured portions, the varnishing, pouring and removal of the cast, carried out according to the instructions previously given, very little, if any, retouching will be necessary upon the anatomical portion of the cast.

But, at least, the amateur is liable to get a few air bubbles or other imperfections upon the surface of some of his casts, which will need some little skill in the use of the camel's hair brush to render them unnoticeable.

Air bubbles and other indentations such as are often caused by the knife blade in separating, are filled with plaster in the following manner: First, moisten the cast or the portion of it needing repair, then with the camel's hair brush carry a small quantity of very thinly mixed plaster into the bottom of the air bubble, repeating until it is a

little more than full, when the correct contour is obtained by a twisting, wiping motion of the slightly moistened brush over the surface.

Fig. 617.

Fig. 613 represents an upper cast which has a considerable number of air bubbles caused by carelessness in pouring the impression, and the loss of contour of some of the cusps of the teeth make the cast rather unsightly. A little practice with the brush and plaster will enable the operator to restore the contour as in Fig. 614, which illustrates the same cast as in the previous figure after it has been treated by this method.

Fractured teeth and cusps are somewhat differently treated, since it is almost impossible to force plaster of any consistency into a crack such as is visible on adjusting two fractured portions of a tooth together.

One of the surfaces of the fracture should be carved out to a crescent shape, not touching the periphery of the cusp or tooth, however, as this will be needed to place it in register, after which the groove thus made may be filled with thin plaster in the same manner as the air bubbles. This method of uniting fractured pieces is very artistic in effect and the result permanent, being preferred to cement which causes a line of demarcation which is especially noticeable in a photograph.

Fig. 615 represents a badly fractured cast, the right cuspid, both centrals, and the left lateral having been accidentally broken off. Fig. 616 exhibits the same cast after the fractured pieces have been reunited by this method. The right central was restored in contour entirely with the brush, since the fractured portion was lost. It is possible to restore even such a delicate part as the frenum labium, which seldom escapes fracturing in separating, but a knowledge of the minute anatomy of the parts is essential to the attainment of artistic and esthetic results in attempting the reproduction of lost portions of the anatomical part of the cast.

The lines of fracture of the impression are reproduced in the cast, and should be carefully burnished down with the spoon blade of a wax spatula adapted for the purpose, such as is illustrated in Fig. 617, being an S. S. White No. 7 double bladed spatula.

The smaller blade may be sharpened upon one edge to be used in

removing any superfluous plaster contiguous to the festoons of the gums on the cast, also in carving out any surplus plaster from the embrasures of adjoining teeth, and the cusps of bicuspids or molars which are imperfect. Any attempt at carving beyond the shaving of superfluous plaster, quickly shows its artificiality and should be avoided.

XI. PROPHYLAXIS.

During the wearing of appliances in the mouth, the greater liability of food collecting around the teeth, and the lessened activity of the oral fluids in performing their natural cleansing function makes it imperative that especial prophylactic measures be instituted.

The patient's teeth should be thoroughly cleaned before the commencement of operations, and during treatment instructions should be given for the frequent use of the tooth brush, preferably after each meal and upon arising.



Fig. 618.

A tooth brush with one row of bristles, called the Rolling Tooth Brush,* shown in Fig. 618, is much better adapted to cleansing above and below the expansion arch than the brush with several rows of bristles.

Occasionally, the expansion arch should be removed, and the teeth cleansed carefully with pumice and the rubber cup. It is of still greater benefit to have the patient referred back to the family dentist for more detailed prophylactic treatment, especially with the orange wood stick and pumice.

The compressed air spray in connection with antiseptic mouth-washes, is most beneficial in these conditions, being used at each visit of the patient throughout the treatment.

Dr. H. C. Ferris has recently recommended a combination of sprays which have certain peculiar reactions which make them of exceptional value, being both chemical and mechanical in their action.

The first of the series of sprays contains the active agent iodine in combination with potassium iodide, which acts germicidally to destroy the spores and parent cells in albuminous material, which it readily penetrates, staining the bacterial plaques so that they are visible upon tooth surfaces.

* Manufactured by the Rolling Tooth Brush Co., Boston, Mass.

The second spray consists of a starch solution which absorbs the stained plaques, forming a flocculent precipitate, which is readily removed by the third spray which is a simple solution of sodium carbonate, having the power to decolorize the precipitate previously formed, at the same time freeing the surfaces of the teeth still further by saponifying the fats.

The antiseptic and beneficial value of these sprays, used consecutively, is not excelled by any other at present known methods of oral antisepsis.

The series of sprays are given below in the order of their use, it being necessary to have separate nozzles for each spray, which also must be used at the temperature noted in order to have the desired effect.

I.

℞—Iodini, ♏ xxx.
Potassii iodidi, ♏ xix.
Aquæ dest. ad. q. s. ℥ iv.
Sig.—To be used in spray under high pressure at the temperature of 98° F.

II.

℞—Starch, gr. xxxviii
Aquæ menth. pip. ℥ iv.
Oleum menth. pip. ♏ xx.—M.
Sig.—To be used at the temperature of 115° F. In making this compound, mix the first two ingredients and let stand for five minutes, then boil for five minutes, then add the flavoring.

III.

℞—Sodii carb., gr. xxxviii.
Aquæ gaultheria, ℥ iv.
Olei gaultheria, ♏ xxx.—M.
Sig.—To be used at the temperature of 115° F.

INDEX.

Guide to the Index.—The index has been arranged with a view to direct the reader to his subject without delay. All readers do not think of the same subject matter in the same form, therefore the same subject will be found indexed in various forms. For instance:

"Preparation of cavities:"
"for fillings, 161"
"Cavities:"
"preparation of, for fillings, 161"
"Fillings, preparation of cavities for, 161"

Where a — appears before a line it indicates that the indexed line relates to the sub-heading above it.

Abnormal arch development, 527
Abnormal frenum labium, 547
operation for, 603
Abscess, acute alveolar, 352
chronic alveolar, 354
pericemental, 362
pocket, secondary, 361
with sinus, 354
without sinus, 354
Absorbed root, 360
Absorbents, the use of, 157
Accessories to the Magill band, 726
Adaptation of the arch, 583
Adenoids, 539
Adjusting the rubber dam, 148
Adjustment of anchor clamp bands, 588
Advantages of early treatment (orthodontia), 609
Adventitious growths, removal of, 541
After-pains of extraction, 434
After-treatment of extraction, 435
Alveolar hemorrhage from the extraction of a tooth, 432
Amalgam, 240
Amalgam and cement, 252
Analgesics, 222
Anatomy of the human teeth, 1
Anatomical parts of the teeth, 2
Anchorage:
first molar, 577
intermaxillary, 578
uses of, 579
occipital, 580
primary, 577
reciprocal, 573
re-inforced, 573
requirements, 611
secondary, 578
simple, 573
summary of principles, 581
Anchor clamp bands, adjustment of, 588
teeth, bodily control of, 585
tube, the pivotal, 730
tubes, adjustment of, bucco-lingual, 589
Anesthesia, local, 385
Anesthetization and devitalization of pulps, 317
for removal of pulps, 318
Anesthetizing the pulp, method of, 396
Angle of the tooth, 2
Anodynes, 222
Antagonizing spurs, 713
Anterior and posterior arch retention, 711
Antrum, 361
Apex, 2
Apical foramen, 2
Appliances:
choice of metals for (orthodontia), 717
efficiency of (orthodontia), 572
materials for construction of (orthodontia), 717
Arch:
development of, 505
integrity, preservative forces of, 511
predetermination, 554
retainer, lingual, 710
Arches:
case reciprocating, 576
of temporary teeth, 506
Arrangement of light in the operating room, 85
Arrested developmental conditions in the arches, early treatment of, 606
Arsenical poisoning, 332
Articulation, 513
Artificial roots, 449
Asepsis in the operating room, 89
Assembling the impression (orthodontia), 735
parts of molar clamp band (orthodontia), 728
Assistants in the office, 490
Associated anatomical structures, development of, 514

Badly decayed root, 351
Band:
accessories to the Magill, 726
assembling parts of molar clamp, 728
driver, 589
Magill, 723

Band:
soldering the, 725
soldering buccal tube on molar clamp, 729
Bands, plain, 719
Beauty, physical relations of, 517
Bibs, 156
Bicuspids:
lower first, 27
—buccal surface, 27
—cervical margin, 29
—distal surface, 29
—lingual surface, 27
—mesial surface, 29
—occlusal surface, 27
—pulp cavity, 30
—root, 30
second, 30
upper first, 19
—buccal cusp, 19
—buccal surface, 20
—cervical margin, 23
—distal surface, 22
—lingual surface, 21
—mesial surface, 22
—occlusal surface, 19
—pulp cavity, 23
—root, 23
second, 24
Bilateral infra-occlusion of bicuspids and molars, 553
Blood-vessels of the pulp, 82
Blowpipe, the Kerr, 720
Bodily control of anchor teeth, 585
Bonwill's diagram, 553
Bromids, 222
Buccal cavities, 268
Bucco-lingual alignment of anchor tubes, 589
Burs, 181

Cabinet, the dental, 91
Calculus, 108
Capping the pulp, 312
Card system, 497
Caries, pathology of dental, 117
Casualties attending tooth extraction, 431
Causes and treatment of discolorations of teeth, 367
Cavities:
division of, 164
examination of teeth for discovery of, 127
fissure, 166
instruments for preparation of, 178
management of large proximo-occlusal, in pulpless bicuspids, 212
large, in pulpless molars, 212
nomenclature, 161
of internal parts of, 163
preparation of, in bicuspids and molars involving the occlusal surface, 207
—buccal and labial, 268
—for fillings, 161
—for inlays, 267
—for restoration of incisal tips, 272
Cavities:
preparation of simple proximal cavities in incisors and cuspids, 270
—in occlusal surfaces of bicuspids and molars, 275
—involving the proximal and occlusal surfaces of bicuspids and molars, 273
—proximal cavities involving the incisal angle, 270
—proximal in incisors and cuspids involving incisal angle, 198
steps in formation of, 164
Cement, 246
for inlays, 288
Cemental fusion of roots, 431
Cementoblasts, 82
Cementum, 72
Central incisor, lower, 10
upper, 3
Cervical clamps, 154
Characteristics of normal occlusion, 509
Chemical constituents of enamel, 62
—composition of saliva, 99
Chemistry of pulp decomposition, 341
Children's teeth, treatment of, 377
Chisels, 179
Chloroform, 222, 223
Choice of metals for appliance (orthodontia), 717
Chronic alveolar abscess, 354
Clamp bands, adjustment of anchor, 588
Clamps, 153
Classification of cavities, 162
chart (orthodontia), 550
malocclusion, 548
Closing up spaces between incisors, 597
Coagulating agents, 347
Cocain, 219
hydrochlorid, 390
Cold, 217
Combination fillings, 251
amalgam and cement, 252
cement and gutta-percha, 253
gold and amalgam, 252
gold and cement, 252
gold and tin, 252
platinum and gold, 251
Comparative measures of resistance (orthodontia), 573
Complications incident to removal of pulp, 330
in treatment after extraction of teeth, 694
Conditions necessitating removal of pulp, 317
Construction of gold inlays, 301
difficult cavities filled by the Taggart method, 304
posts for cast gold inlays, 305
Co-ordination of normal functions, 516
Corrected radius (orthodontia), 562
Cotton for separating, 135
Crown, 2
Cuspid, the lower, 17
cervical margin, 18

Cuspid, cusp, 18
distal surface, 18
labial surface, 17
lingual surface, 18
mesial surface, 18
pulp cavity, 18
root, 18
the upper, 14
Cuspid, elevation of (orthodontia), 597
Cusps, 2
Cutting of the flap, 445

Daily records, 495
Deciduous:
arch, 707
cuspids, results of extraction of, 689
expansion of arch, 605
laterals, results of extraction of, 688
lower central incisors, 56
lower cuspid, 57
first molar, 57
lateral incisor, 57
second molar, 58
molars, results of extraction of, 691
teeth, materials for filling, 379
premature loss of, 544
prolonged retention of, 544
pulps and abscesses in, 359
upper central incisor, 54
cuspid, 55
first molar, 55
lateral incisor, 54
second molar, 56
Decomposition of the pulp, 341
Deductions from early symptoms of developing malocclusion, 525
Definition of matrix, 255
Dental:
cabinet, 91
caries, 117
engine, 180
pulp, 75
Dentin, 68
histological constituents of, 68
treatment of sensitive, 215
Dento-facial orthopedia, 516
Denture, normal human, 1
Denuded end of root, 359
Deposits, 107
removal of, 113
serumal, 111
Details as to manipulation of matrix, 216
Development of associated anatomical structures, 514
Developmental spaces (orthodontia), 507
Deviation of the nasal septum, 538
Devitalization of dental pulp, 526
Diagnosis:
class II, 636
orthodontia, 547
pyorrhea, 457
Diagram, Dr. Bonwill's, 555
Dr. Hawley's, 556
Discolorations of teeth, causes and treatment of, 367
Discomfort in mastication, 380
Disease (orthodontia), 527
Dislocation of lower jaw, 431
Distal movements of molars, 598
Distance between holes in rubber dam, 147
Distribution of plaster in the tray (orthodontia), 733
Divided expansion arch, 586
Division of teeth and cavities, 164
Double resection of the mandible, 679
Drilling of the socket, 445
Drug irritants, 335
Dynamics:
anchorage, 567
of the expansion arch, 569
of traction screw, 570

Early treatment of arrested developmental conditions in the arches, 606
Efficiency of appliances (orthodontia), 525
Electric current, 217
furnace, 296
Elevation of cuspid (orthodontia), 597
Employment of matrix for gold restorations, 261
Enamel, 61
chemical constituents of, 62
rods, 63
strength of, 68
wall, proper bevel and polish of, 174
Encystment of root, 360
Engine, the dental, 180
Environment (orthodontia), 525
Epithelial structures, 82
Erosion, 471
treatment of, 479
Erosions, 108
Eruption of the teeth, 408
Escape of a tooth into the larynx or pharynx, 431
Escharotics, 218
Establishing sinus, 357
Ether, 222
Ethyl chlorid, 222, 386
Etiology:
and diagnosis of class I, 610
and diagnosis of class II, 636
and diagnosis of class III, 667
orthodontia, 525
pyorrhea alveolaris, 452
Eugenol, 221
Examination of teeth to discover cavities, 127
cleanliness, 128
concluding notes, 130
conditions for examination, 128
diagnosis, 127
dryness, 128
gingival, 127
lines of union, 127
marginal, 128
physical exploration, 127
proximal, 127
records, 130, 491
regional divisions for, 127
at stated periods, 127
system and method, 128
systematic record, 127

Excessive overbite, 641
Excision of root, 361
Exclusion of moisture from teeth during operations, 145
Expanded arch, retention of, 706
Expansion:
arch, spurs and hooks for, 727
vertical alignment of, 590
of deciduous arch, 605
retention after anterior, 709
Extension for prevention, 167
External anatomy, relations of (orthodontia), 519
Extraction, 399
after-pains of, 434
after-treatment of, 435
alveolar hemorrhage from, 432
casualties attending, 431
complications in treatment after, 694
deciduous, 408
—cuspids, results of, 689
—laterals, results of, 688
—molars, results of, 691
first permanent molars, results of, 692
permanent, evil effects of, 691
problem of (orthodontia), 687
roots, 428
shock during, 432
sterilizing instruments for, 435
under anesthetic agents, 435
of wrong tooth, 431
Eye-strain, 87

Facial asymmetry, 520
—profile, 517
—symmetry, 517
Faucial tonsil, hypertrophy of, 538
Fees, 502
Fibroblasts, 82
Filling:
deciduous teeth, 379
the impression (orthodontia), 736
large canals, 364
materials, 225
the matrix for inlays, 280
root canals, 347, 363
small canals, 365
the use of the matrix for, 255
Fillings, preparation of cavities for, 161
Fissure cavities, 166
preparation of, 182
Floor of pulp chamber, 24
Force and resistance (orthodontia), 567
appliances for producing, 568
Forcing teeth or roots into antrum, 432
Forms of the matrix, 256
Fracture (extraction):
of alveolar process, 431
of crown of tooth, 431
of jaws, 431
Frenum labium, abnormal, 547
operation for, 603
Full bimaxillary infra-occlusion, 554
Functional influences (orthodontia), 526
Furnaces, 294
electric, 296
Furnaces, gasoline, 298
Fusing porcelain, 281
Fusion of the roots, cemental, 431

Gasoline dental furnace, 298
Gassing, 296
Gelatinous plaques, 121
General anodynes or analgesics, 222
Gingival margin, 2
Gold, 252
and amalgam, 252
and cement, 252
and platinum, 251
and tin, 252
inlays, construction of, 301
Green stain, 108
Gutta-percha, 249
and cement, 253
fillings, 262
for separating, 134
Gum lancets, 430

Hand matrix, 259
Harmony of facial profile, 517
Heat, 216
Heredity (orthodontia), 525
Histological constituents of dentin, 68
Histology of the human teeth, 59
Holes in rubber dam, 146
distance between, 147
location of, 148
Hooks for expansion arch, 727
Human denture, normal, 1
teeth, the anatomy of, 1
—the histology of, 59
Hygiene of the mouth, 97
in operating room, 85
Hypertrophy of faucial tonsil, 538
of turbinated bones, 538

Ideal treatment of a practical case (orthodontia), 607
Immunity to decay, period of, 152
Implanting teeth, 442
Impressions (orthodontia):
assembling the, 735
filling the, 736
materials and models for, 731
sectioning and removal of, 736
tray, 731
Incisor:
lower central, 10
—cervical margin, 12
—deciduous, 56
—distal surface, 12
—incisive edge, 12
—labial surface, 10
—lingual surface, 11
—mesial surface, 12
—pulp cavity, 13
—root, 13
lateral, 13
—deciduous, 57
mesial and distal movements of (orthodontia), 598

Incisor:
upper central, 3
—cervical margin, 6
—cervical ridge, 4
—cingulum, 4
—deciduous, 54
—distal surface, 5
—labial surface, 3
—lingual surface, 4
—mesial surface, 5
—pulp canal, 6
—pulp cavity, 6
—pulp chamber, 6
—root, 6
lateral, 7
—cervical margin, 9
—deciduous 54
—distal surface, 9
—incisive edge, 9
—labial surface, 7
—lingual surface, 8
—mesial surface, 9
—pulp cavity, 10
—root, 9
Incisive edge, 2
Indications for the planting of teeth, 443
Inequalities of growth (orthodontia), 520
Infant, oral hygiene of the, 97
Inflammatory changes in alveolar tissue, 527
Influence of the pituitary body, 525
Infra-occlusion, 553
bilateral of bicuspids and molars, 553
class II div. I (orthodontia), 653
full bimaxillary, 554
of incisors, cuspids and bicuspids, 553
and cuspids, 620
of molars and bicuspids, 625
treatment of, 605
variations of, 553
Inharmony of the profile, 521
Inlays, 263
gold, construction of, 301
indications for use of, 263
porcelain, 277
posts for cast gold, 305
preparation of cavities for, 267
the Taggart method, 302
Irritants, drug, 335
mechanical, 336
Instruments:
employed for extraction of teeth, 410
for preparation of cavities for fillings, 178
—chisels, 179
—cutting edge, 179
—handle, 179
—hatchets, 179
—shank, 179
—spoons, 179
sterilization of, 93, 435
Intermaxillary, anchorage (orthodontia), 578
retention, 705
Internal anatomy, relations of (orthodontia), 519
Intra-uterine influence upon arch development, 524

Kerr blowpipe, 720

Lancets, 430
Large canals, filling of, 364
Lateral incisors:
deciduous lower, 57
upper, 54
the lower, 13
the upper, 7
Layer of Weil, 77
Lever, 602
Ligating the teeth, 150
Ligatures, 592
variety of, 594
Light, 217
Limitations of the removable appliances (orthodontia), 627
Line of occlusion (orthodontia), 565
Lingual bar and ligature, 596
arch retainer, 710
Lip-biting, 545
Local anesthesia, 385
anodynes, 219
Location of holes in rubber dam, 148
Lower cuspid, 17
first bicuspid, 27
molar, 44
second bicuspid, 30
molar, 49
third molar, 52

Magill band, 723
accessories to, 726
Malocclusion, 509
classification of, 548
local factors in, 544
nomenclature, 512
Management of large proximo-occlusal cavities in pulpless bicuspids, 212
in pulpless molars, 212
of an office practice, 483
Mandible:
double resection of, 679
restoration of lateral half of, 684
Mastication, discomfort in, 380
Materials for construction of appliance, (orthodontia), 717
for filling deciduous teeth, 379
Matrix:
definition of, 255
details as to manipulation of, 260
employment of, for gold restorations, 261
filling of, for porcelain inlay, 280
the hand, 259
introduction and management of, 260
materials and forms of, 256
mechanical, 256
for porcelain inlay, 277
removal of, 261
the use of, in filling teeth, 255

Mechanical:
advantage (orthodontia), 570
irritants, 335
separator, 138
advantages of, 141
Medication (pyorrhea alveolaris), 467
Menthol, 221
Mesial and distal movements of incisors, 598
Metals for appliances, choice of (orthodontia), 717
Method of anesthetizing the pulp, 396
Methods of removing the pulp, 318
Mixing of plaster, 732
Models (orthodontia):
marking and numbering of, 742
necessity, for accurate, 730
trimming the, 739
Moisture, exclusion of, from the teeth, 145
Molar:
clamp band, 719
assembling parts of, 728
soldering buccal tube on, 729
deciduous, 55, 56, 57, 58
distal movements of (orthodontia), 598
lower first, 44
—buccal, 47
—distal, 48
—lingual, 48
—mesial, 48
—occlusal, 44
—pulp cavity, 49
—roots, 48
second, 49
—buccal, 50
—distal, 50
—lingual, 50
—mesial, 50
—occlusal, 49
—pulp cavity, 52
—roots, 50
third, 52
—pulp cavity, 52
—roots, 52
—surfaces, 52
upper first, 31
—buccal, 34
—cusps, 32
—distal, 36
—fossæ and grooves, 33
—lingual, 35
—mesial, 35
—occlusal, 31
—pulp cavity, 37
—roots, 36
second, 38
—buccal, 39
—distal, 40
—lingual, 40
—mesial, 40
—occlusal, 38
—pulp cavity, 41
—roots, 41
Molar:
third, 41
—buccal, 42
—distal, 43
—lingual, 42
—mesial, 43
—occlusal, 42
—pulp cavity, 43
—roots, 43
Mouth-breathing, 531
Mouth, hygiene of, 97
Mouth-wash, preparation for, 105, 106
Muscular action, normal (orthodontia), 526
Mutilation of the maxillary tuberosity, 432

Nasal breathing, obstructions to, 536
Nasal septum, deviation of, 538
Nearly exposed pulps, treatment of, 311
Necessity, for accurate models (orthodontia), 730
for retention (orthodontia), 701
Neck of the tooth, 2
Nerves of the pericementum, 83
Nerves of the pulp, 78
Nitrous oxid, 222
Nomenclature:
cavity, 161, 163
of malocclusion, 572
Normal arch development (orthodontia), 506
Normal human denture, 1
Normal muscular action (orthodontia), 526
Normal occlusion, characteristics of, 509
Notification of patients, 499
Novocain preparation, technique of injection of, 393

Obstructions to nasal breathing, 536
Obtundants, 460
Occipital, anchorage, 580
retention, 706
Occlusal:
relations, 507
—of perment teeth, 508
retention, 702
surface, 2
—cavities, preparation of, 207
Occlusion:
line of (orthodontia), 565
normal, 509
—characteristics of, 509
Office practice, management of, 483
Oil burners, 299
Oil of cloves, 221
Operating chair, the window in front of, 86
Operating room, asepsis in, 89
hygiene and arrangement of light in, 85
Operation for abnormal frenum labium, 603
Operative:
technic (orthodontia), 582
treatment, technic of (orthodontia), 667
Opium, 222
Oral hygiene of the infant, 97
Ordinary pericementitis, treatment of, 335

Orthodontia, 505
scope of, 521
Orthopedia, dento-facial, 516
Osteoblasts, 82
Osteoclasts, 82
Oxidation method (discolorations), 372

Pathology of dental caries, 117
Pericemental abscess, treatment of, 362
Pericementitis, 335
Pericementum, 79
Period of immunity to decay, 122
Permanent teeth, during childhood, treatment of, 381
evil effects of extraction of, 691
Personal treatment of patients, 489
Phenol, 218, 221
Physical:
agents, 216
explorations of teeth, 127
relations of beauty, 517
Pit and fissure cavities, preparation of, 182
Pituitary body, influence of, 525
Pivotal anchor tube, 730
Plain bands (orthodontia), 719
Planes, relation of inclined, 510
of the teeth, 164
Planting of teeth, 439
Plaster:
mixing of, 732
technic, 730
Platinum and gold, 251
Porcelain:
bodies, 292
inlay, 277
section attachment, 286
Position of operator and patient (extraction), 409
Posts for cast gold inlays, 305
Post-natal factors in arch development, 525
Practical case, ideal treatment of, 77
Preparation of cavities:
in bicuspids and molars which involve in the occlusal surface, 207
in bicuspids and molars which do not involve the occlusal surface, 205
buccal and lingual margins, 167
bevel and polish of enamel wall, 174
burs for, 181
cavity nomenclature, 161, 163
classification of cavities, 162
definitions, 161
dental engine, 180
developmental grooves, 167
divisions, of cavities, 164
—of the teeth, 164
extension for prevention, 167
for fillings, 161
fissure cavities, 166
general conditions of outline form, 164
for inlays, 267
instruments for, 178
lower incisor and cuspid cavities, 197
management of large cavities in pulpless molars, 212
management of large proximo-occlusal cavities in pulpless bicuspids, 212
proximal cavities in incisors and cuspids which involve the incisal angle, 198
proximal cavities which do not involve the incisal angle, 190
pulpless incisors having large proximal cavities, 204
resistance form, 171
retention form, 173
sharpening of instruments, 182
smooth surface cavities, 182
steps in cavity formation, 164
Preparation for mouth wash, 105, 106
Precautions in planting teeth, 443
Premature loss of deciduous teeth, 544
Preservative forces of arch integrity (orthodontia), 511
Prevention of thumb-sucking, 546
Primary anchorage (orthodontia), 577
Problem of extraction (orthodontia), 687
Procedure for planting teeth, 444
Profile, in harmony of, 521
Prognosis, caries, 126
in planting of teeth, 442
Prolonged retention of deciduous teeth, 544
Proper bevel and polish of enamel wall, 174
Prophylaxis, 745
Protrusions of class I, 629
Proximal surface, 2
Proximo-occlusal cavities in pulpless bicuspids, 212
Pulp, 75
anesthetization and devitalization of, 317, 318, 326, 396
capping the, 312
complications incident to removal of, 330
conditions necessitating removal of, 317
methods of removing, 318
nerves of, 78
partially alive, 351
removal and subsequent treatment of, 317
treatment of putrescent, 347, 349
Putrescent pulp in deciduous teeth, treatment of, 259
Pyorrhea alveolaris, 451
diagnosis of, 457
etiology and pathology of, 452
medication for, 467
obtundents for, 460
retainers for, 460
subsequent treatment, 469
surgical treatment, 462
systemic treatment, 470
treatment of, 457

Qualifications of appliances (orthodontia), 582

Reception of patients, 488
Reciprocal anchorage, 573
Reduction method (discolorations), 372

Re-inforced anchorage (orthodontia), 573
Relations:
of beauty, physical, 517
of external and internal anatomy, 519
of inclined planes, 510
Relative value of first permanent molar, 692
Removal:
of adventitious growths, 541
of deposits, 113
of impression (orthodontia), 736
and subsequent treatment of pulp, 317
—anesthetization for, 318
—complications, incident to, 338
—conditions necessitating, 317
—methods of, 318
Removable appliance, use and limitations of, 627
Repairing defects in impressions and models (orthodontia), 743
Replanting teeth, 439
Resection of the mandible, double, 679
Resistance, form for prepared cavities, 171
comparative measures of (orthodontia), 573
values in anchorage (orthodontia), 571
Restoration of lateral half of mandible, 684
Results of extraction of deciduous cuspids, laterals and molars, 688, 689, 691
of first permanent molar, 692
of second bicuspids, 694
Retainer, the lingual arch, 710
Retainers (pyorrhea alveolaris), 460
Retaining wires, 719
Retention form for prepared cavities, 173
Retention (orthodontia), 701
after anterior expansion, 709
anterior and posterior arch, 711
anterior part of developing arch, 707
classified, 702
expanded arch, 706
of entire deciduous arch, 708
mesio-distal changes in occlusion, 712
necessity for, 701
occipital, 706
occlusal, 704
reciprocal, 705
scope of, 701
simple, 704
Röntgen rays, 566
Root, 2
absorbed, 360
artificial, 449
denuded end of, 359
excision of, 360
encystment of, 360
Root canals, filling of, 363, 364, 365
Rotation of molars (orthodontia), 600
Rubber dam:
the use of, 146
adjusting, 148
cervical clamps, 154
clamps, 153
distance between holes, 147
holes, 146
ligating the teeth, 150
location of holes, 147
Rubber dam:
number of teeth isolated, 148
rubber cups, cotton rolls, napkins, 156
saliva ejector, bibs and accessories, 156
size and shape of, 146
use of absorbents, 157
Rubber for separating, 136

Sajou's theory, 539
Saliva, chemical composition of, 109
ejector, 156
Scope of orthodontia, 521
retention (orthodontia), 701
Screw post, technique of inserting, 213
Secondary abscess pocket, 361
anchorage, 578
Sectional development (orthodontia), 508
Sectioning and removal of impression, (orthodontia), 736
Sensitive dentin, treatment of, 215
Separation of teeth, 133
cotton for, 135
gutta-percha for, 134
miscellaneous conditions requiring, 142
rubber for, 136
tape for, 137
wood for, 137
Separator:
the best, 140
the mechanical, 138
Serumal deposits, 111
Shading, 290
Sharpening instruments, 182
Shock during tooth extraction, 432
Silver nitrate, 219
Simple anchorage, 573
retention, 704
Simplified method (orthodontia), 557
Smooth surface cavities, 187
Socket, drilling of the (planting), 445
Soldering the band, 725
the buccal tube on molar clamp band, 729
technic, 720
Spaces, developmental (orthodontia), 508
Spurs, 592
for expansion arch, 727
pliers, 593
Stationery, 503
Steps in cavity formation, 164
Sterilization of instruments, 93, 435
Sterilizing agents, 449
Stomatitis, 102
Subsequent treatment (pyorrhea), 469
Summary of anchorage principles, 581
Superficial defects, 166
Supernumeraries, 546
Surfaces of teeth, 2
buccal, 3
labial, 2
lingual, 3
proximal, 2
Surgical treatment (pyorrhea), 462
Symmetry of the face, 516, 517
Symptoms of developing malocclusion, deductions from, 523

Syncope, 431
Systemic treatment (pyorrhea), 470

Table of average measurements, 559
Taggart method, cast inlay, 302
  difficult cavities filled by, 304
Tape, 137
Teeth:
  anatomy of the human, 1
  anatomical parts of, 2
  arches of temporary, 506
  deciduous, 53
  eruption of, 408
  examination of, to discover carious cavities, 127
  extraction of, 399
    —deciduous, 408
    —prognosis of (orthodontia), 697
  forcing into antrum (extraction), 432
  histology of the human, 59
  implanting of, 442
  materials for filling deciduous, 379
  neck of, 2
  occlusal relations of permanent, 508
  planting of, 439
  replanting of, 439
  separation of, 133
  transplanting of, 442
  treatment of discolorations of, 367
  treatment of putrescent pulps and abscesses in deciduous, 359
  use of matrix in filling, 255
Technique:
  instruction, advantages of (orthodontia), 716
  of inserting a screw post, 213
  of novocain, injection, 393
Temporary teeth, arches of, 506
Therapeutics for obtunding sensitive dentin, 216
Thrush, 104
Thumb-sucking, 541
Tin, 245
Tipping up molars (orthodontia), 600
Tooth:
  alveolar hemorrhage from extraction of, 432
  angle of, 2
  casualties attending extraction of, 431
  escape of into larynx or pharynx, 431
  extraction of the wrong, 431
Treatment:
  of children's teeth, 377
  of discolorations of teeth, 367
Treatment:
  of exposed or nearly exposed pulps, 311
  of infra-occlusion, 605
    —advantages of early (orthodontia), 609
    —complications in, after extraction of teeth, 694
    —early of class II, 649
    —of a practical case, ideal, 607
    —of arrested development, early (orthodontia), 606
    —of class I, 601
    —of class II, 636, 642
    —of class II, div. I, 642
    —of class II, div. I, sub. div., 658
    —of class II, div. II, 660
    —of class II, div. II, sub. div., 664
    —of class III, 667
    —of class IV, 683
    —of special cases, 612, 669
    —of unusually complicated cases, class III, 675
    —technic of operation of, 642, 667
  of permanent teeth during childhood, 381
  of pyorrhea alveolaris, 457
    —erosion, 479
    —subsequent, 669
    —surgical, 462
    —systemic, 470
  of sensitive dentin, 215
Trichloracetic acid, 218
Trimming the model (orthodontia), 739

Use and limitations of the removable appliance (orthodontia), 627
  of the matrix, 255
  of the rubber dam, 146
Uses of intermaxillary anchorage (orthodontia), 579
Utilization of time in the office, 490

Variations of infra-occlusion, 553
Variety of ligatures, 594
Varnishing the impression (orthodontia), 735
Vertical alignment of expansion arch, 598

Weil, the layer of, 77
Window in front of operating chair, 86
Wood for separating, 137
Wrenches, 588

Zinc chlorid, 218

RK501 J62
Johnson